UNIVERSITY OF TORONTO
3 1761 [illegible] 28 3

MP
T

V. 2 pt. 1-3

UNIVERSITY OF LONDON
FRANCIS GALTON LABORATORY FOR NATIONAL EUGENICS

EUGENICS LABORATORY MEMOIRS. XXVIII

OF TORONTO LIBRARY

THE TREASURY OF HUMAN INHERITANCE

EDITED BY KARL PEARSON, F.R.S.

NAME AND SUBJECT INDEX TO VOLUME II

D

PREPARED BY

JULIA BELL, M.A., M.R.C.P.

1-3

47915A
22.9.48

CAMBRIDGE UNIVERSITY PRESS
LONDON: FETTER LANE, E.C. 4
ALSO
H. K. LEWIS & CO., LTD., 136 Gower Street, London, W.C. 1
Bombay, Calcutta, Madras: MACMILLAN & CO., LIMITED
Tokyo: MARUZEN COMPANY, LTD.
1933

Price Nine Shillings net

The Cambridge University Press, Fetter Lane, London, E.C. 4, and their Agents, are now the sole Agents for the sale of the following publications of the Biometric and Galton Laboratories, University of London.

EUGENICS LABORATORY PUBLICATIONS.

Memoir Series.

I. **The Inheritance of Ability.** By EDGAR SCHUSTER, D.Sc., Formerly Galton Research Fellow, and ETHEL M. ELDERTON, Galton Fellow. *[Out of print*

II. **A First Study of the Statistics of Insanity and the Inheritance of the Insane Diathesis.** By DAVID HERON, D.Sc. *[Out of prin*

III. **The Promise of Youth and the Performance of Manhood.** By EDGAR SCHUSTER, D.Sc. *[Out of print*

IV. **On the Measure of the Resemblance of First Cousins.** By ETHEL M. ELDERTON, Galton Research Fellow, assisted by KARL PEARSON, F.R.S. *Price 5s. net.*

V. **A First Study of the Inheritance of Vision and of the Relative Influence of Heredity and Environment on Sight.** By AMY BARRINGTON and KARL PEARSON, F.R.S. *Price 5s. net.*

VI. **Treasury of Human Inheritance (Pedigrees of physical, psychical, and pathological Characters in Man).** Parts I and II (double part). (Diabetes insipidus, Split-Foot, Polydactylism, Brachydactylism, Tuberculosis, Deaf-Mutism, and Legal Ability.) *Price 14s. net.*

VII. **On the Relationship of Condition of the Teeth in Children to Factors of Health and Home Environment.** By E. C. RHODES. *Price 9s. net.*

VIII. **The Influence of Unfavourable Home Environment and Defective Physique on the Intelligence of School Children.** By DAVID HERON, M.A., D.Sc. *[Out of print*

IX. **The Treasury of Human Inheritance (Pedigrees of physical, psychical, and pathological Characters in Man).** Part III. (Angioneurotic Oedema, Hermaphroditism, Deaf-Mutism, Insanity, Commercial Ability.) *Price 10s. net.*

X. **The Influence of Parental Alcoholism on the Physique and Intelligence of the Offspring.** By ETHEL M. ELDERTON, assisted by KARL PEARSON. *Second Edition. Price 6s. net.*

XI. **The Treasury of Human Inheritance (Pedigrees of physical, psychical, and pathological Characters in Man).** Part IV. (Cleft Palate, Hare-Lip, Deaf-Mutism, and Congenital Cataract.) *Price 10s. net.*

XII. **The Treasury of Human Inheritance (Pedigrees of physical, psychical, and pathological Characters in Man).** Parts V and VI. (Haemophilia.) *Price 15s. net.*

XIII. **A Second Study of the Influence of Parental Alcoholism on the Physique and Intelligence of the Offspring.** By KARL PEARSON, F.R.S., and ETHEL M. ELDERTON. *Price 6s. net.*

XIV. **A Preliminary Study of Extreme Alcoholism in Adults.** By AMY BARRINGTON and KARL PEARSON, F.R.S. *Price 6s. net.*

XV. **The Treasury of Human Inheritance.** Dwarfism, with 49 Plates of Illustrations and 8 Plates of Pedigrees. *Price 15s. net.*

XVI. **The Treasury of Human Inheritance.** Prefatory matter and indices to Vol. I. With Frontispiece Portraits of Sir Francis Galton and Ancestry. *Price 5s. net.*

XVII. **A Second Study of Extreme Alcoholism in Adults.** With special reference to Inebriate Reformatory data. By DAVID HERON, D.Sc. *Price 6s. net.*

XVIII. **On the Correlation of Fertility with Social Value.** A Cooperative Study. *Price 7s. 6d. net.*

XIX—XX. **Report on the English Birthrate.** Part I. England, North of the Humber. By ETHEL M. ELDERTON, Galton Research Fellow. *Price 9s. net.*

XXI. **Treasury of Human Inheritance.** Vol. II (Nettleship Memorial Volume). Heredity of Eye Anomalies and Diseases. Part I. *Price 45s. net.*

XXII. **Treasury of Human Inheritance.** Vol. III. Part I. Hereditary Disorders of Bone Development. By PERCY STOCKS, M.D., and AMY BARRINGTON. *Price 45s. net.*

XXIII. **Treasury of Human Inheritance.** Vol. II (Nettleship Memorial Volume). Part II. Colour Blindness. *Price 45s. net.*

XXIV. **The Treasury of Human Inheritance.** Vol. II (Nettleship Memorial Volume). Part III. Blue Sclerotics and Fragility of Bone. *Price 36s. net.*

XXV. **On the Relative Value of the Factors which influence Infant Welfare.** By ETHEL M. ELDERTON. (Reprinted from *Annals of Eugenics.*) *Price 21s. net.*

XXVI. **The Treasury of Human Inheritance.** Vol. II (Nettleship Memorial Volume). Part IV. Hereditary Optic Atrophy (Leber's Disease). *Price 36s. net.*

Lecture Series.

I. **The Scope and Importance to the State of the Science of National Eugenics.** By KARL PEARSON, F.R.S. Third Edition. *Price 1s. 6d. net.*

II. **The Groundwork of Eugenics.** By KARL PEARSON, F.R.S. Second Edition. *Price 1s. 6d. net.*

III. **The Relative Strength of Nurture and Nature.** Much enlarged Second Edition. Part I. The Relative Strength of Nurture and Nature. (Second Edition revised.) By ETHEL M. ELDERTON. Part II. Some Recent Misinterpretations of the Problem of Nurture and Nature. (First Issue.) By KARL PEARSON, F.R.S. *Price 2s. 6d. net.*

IV. **On the Marriage of First Cousins.** By ETHEL M. ELDERTON. *Price 1s. 6d. net.*

V. **The Problem of Practical Eugenics.** By KARL PEARSON, F.R.S. Second Edition. *Price 1s. 6d. net.*

VI. **Nature and Nurture, the Problem of the Future.** By KARL PEARSON, F.R.S. Second Edition. *Price 1s. 6d. net.*

VII. **The Academic Aspect of the Science of National Eugenics.** By KARL PEARSON, F.R.S. *Price 3s. net.* (Sold only with Complete Sets.)

VIII. **Tuberculosis, Heredity and Environment.** By KARL PEARSON, F.R.S. *Price 1s. 6d. net.*

IX. **Darwinism, Medical Progress and Eugenics.** The Cavendish Lecture, 1912. By KARL PEARSON, F.R.S. *Price 1s. 6d. net.*

X. **The Handicapping of the First-born.** By KARL PEARSON, F.R.S. *Price 2s. 6d. net.*

XI. **National Life from the Standpoint of Science.** (Third Issue.) By KARL PEARSON, F.R.S. *Price 1s. 6d. net.*

XII. **The Function of Science in the Modern State.** (New Issue.) By KARL PEARSON, F.R.S. *Price 2s. net.*

XIII. **Side Lights on the Evolution of Man.** By KARL PEARSON, F.R.S. *Price 3s. net.*

XIV. **The Right of the Unborn Child.** By KARL PEARSON, F.R.S. *Price 3s. net.*

Noteworthy Families. By FRANCIS GALTON, F.R.S., and EDGAR SCHUSTER. *(Reissue.) Price 9s. net.*

Life History Album. By FRANCIS GALTON, F.R.S. *Second Edition. (New Issue.) Price 12s. net.*

E

Digitized by the Internet Archive
in 2013

http://archive.org/details/treasuryofhumanv2p1t3pear



Frontispiece

Copyright in
the Gainsborough Studio

UNIVERSITY OF LONDON
FRANCIS GALTON LABORATORY FOR NATIONAL EUGENICS

THE TREASURY OF HUMAN INHERITANCE

EDITED BY KARL PEARSON, F.R.S.

VOLUME II

NETTLESHIP MEMORIAL VOLUME

BY

JULIA BELL, M.A., M.R.C.P.

CAMBRIDGE
AT THE UNIVERSITY PRESS
1933

HQ
750
A1 T7
v.2
pt. 1-3

PRINTED IN GREAT BRITAIN

PREFATORY NOTE

THIS volume, the second of the *Treasury of Human Inheritance*, was designed as a memorial to my friend and co-worker Edward Nettleship. No more enthusiastic believer in the importance of hereditary studies than Nettleship has ever arisen among our English ophthalmologists. The movement largely set going by him has borne good fruit, and will bear still more as the years go by. Sight is, perhaps, our most valuable possession both individually and racially, and a study of the material contained in this volume will undoubtedly enable its readers to appreciate how much remains to be done if we are to limit the spread of painful individual inefficiency and to check national ophthalmic degeneracy. Prevention is often feasible, but cure is nearly always doubtful, and not infrequently impossible.

In carrying out the design of the Nettleship volume I was indeed fortunate since I succeeded in enlisting the services of such a thorough and energetic inquirer as Dr J. Bell. The many years of laborious research involved in the preparation of this work mark a very noteworthy achievement. *Exitus acta probat.*

K. P.

April 30, 1933.

CONTENTS OF VOL. II

PAGE

PREFATORY NOTE iii

MEMOIR OF EDWARD NETTLESHIP. By J. B. LAWFORD, LL.D., F.R.C.S. . . ix

PART I

RETINITIS PIGMENTOSA AND ALLIED DISEASES

Historical 1

Signs and Symptoms 7

The Pathology of Retinitis Pigmentosa 11

Diseases and Defects found in Association with Retinitis Pigmentosa . . . 15

Racial and Geographical Distribution of Retinitis Pigmentosa 20

Statistical Observations. Consanguinity 21

Diseases Allied to Retinitis Pigmentosa 25

Congenital Stationary Night-Blindness 29

Chronological Bibliography: Retinitis Pigmentosa, Allied Diseases and Congenital Stationary Night-Blindness 34

Name Index to the Chronological Bibliography and to the Recorders of Pedigrees . 46

Descriptions of Pedigree Plates. Figs. 1—297. Plates I—XXII. Retinitis Pigmentosa and Allied Diseases 48

Descriptions of Pedigree Plates. Figs. 300—332. Plates XXIII—XXV. Congenital Stationary Night-Blindness 104

Glioma Retinae

General Account 112

Bibliography of Glioma Retinae 116

Name Index to the Chronological Bibliography and to the Recorders of Pedigrees . 118

Descriptions of Pedigree Plate XXII, Figs. 298, 299, and Plate XXVI, Figs. 333—366 119

PART II

COLOUR-BLINDNESS

(i) *Colour Vision and its Anomalies*

Introductory and Historical 125

Normal Colour Vision 136

The Solar Spectrum 142

The Structure of the Human Retina 147

On the Association of Retinal Structure and Function in Man and in Animals . 152

The Neuro-epithelial Layer of the Retina 156

Colour Vision in Animals 158

(ii) *Total Colour-Blindness*

A. Congenital total Colour-Blindness 163

B. Acquired total Colour-Blindness 174

PAGE

(iii) *Congenital Colour-Blindness*

Introductory Remarks 181
Frequency and Geographical Distribution of Colour-Blindness . . . 183
Description of Dichromatic Vision 185
Congenital Colour-Blindness in Women 195
Inheritance of Colour-Blindness 196
Name Index to Chronological Bibliography and to the Recorders of Pedigrees . 200
Chronological Bibliography 201
Descriptions of Pedigree Plates. Figs. 367—601. Plates XXVII—XLI . . 218
Addendum with extra pedigree (Fig. 602) 267

PART III

BLUE SCLEROTICS AND FRAGILITY OF BONE

Name Index to Text, Bibliography and to the Authors of Pedigrees . . iv *facing* 269
Historical 269
Bone Fragility 272
Association of Blue Sclerotics and Fragility of Bone 276
Nature of Blue Sclerotics 279
Sex Incidence of the Disease 281
Inheritance of Blue Sclerotics 283
On Defects found in Association with Blue Sclerotics 285
Conclusions 287
Descriptions of Illustrative Plates A—O 288
Chronological Bibliography 290
Descriptions of Pedigree Plates. Figs. 602—703. Plates XLII—XLVII . 296 and 324

PART IV

HEREDITARY OPTIC ATROPHY (LEBER'S DISEASE)

Introductory 325
Sex Incidence of the Disease 327
The Character of the Onset of the Disease and the Age at which it occurs . . 330
Clinical Signs and Symptoms of the Disease 335
Course and Prognosis of Hereditary Optic Atrophy 339
On Disabilities found in Association with Hereditary Optic Atrophy . . . 343
The Hereditary Character of the Disease and its mode of Transmission . . . 345
Name Index to the Chronological Bibliography and to the Recorders of Pedigrees . 350
Chronological Bibliography 351
Descriptions of Pedigree Plates. Figs. 704–911. Plates XLVIII—LXIII . . 357

PART V

ON SOME HEREDITARY STRUCTURAL ANOMALIES OF THE EYE AND ON THE INHERITANCE OF GLAUCOMA

Introductory 425

(i) *Anomalies in the Size of the Eye* 425
Hereditary Microphthalmos 428
On Defects Associated with Hereditary Microphthalmos 430
Symmetry and Asymmetry in Microphthalmos 434
Vision in Cases of Hereditary Microphthalmos 436
Hereditary Megalocornea 438
Hereditary Buphthalmos 443

PAGE

(ii) *Hereditary Glaucoma* 448
Historical and Preliminary 448
Sex Incidence in Glaucoma 454
The Age of Onset in Glaucoma 455
On the Size of the Eye in Glaucoma 461
Inheritance in Glaucoma 463

(iii) *Congenital Anomalies of the Iris* 464
Introductory 464
A. Aniridia 466
Defects found in Association with Aniridia 469
Sex Incidence and Inheritance of Aniridia 471
B. Coloboma iridis 472
Asymmetry in Coloboma iridis 475
Sex Incidence and Inheritance of Coloboma iridis 476
C. Hereditary Ectopia lentis 477
Inheritance of Ectopia lentis 481
Name Index to the Chronological Bibliography and to the Recorders of Pedigrees . 483
Chronological Bibliography 484
Descriptions of Pedigree Plates. Figs. 942—1249. Plates LXIV—LXXVI . . 495
Descriptions of Illustrative Plates P—T 554

Erratum. There are *two* Figures 602, that on p. 267 a colour-blind pedigree, and that on Plate XLII described on p. 296; the latter is a blue-sclerotic pedigree and should have been Fig. 602bis.

KEY TO PLATES

Pedigree Plates

Plates	Figs.	Disease or Anomaly	Page
I—XXII	1—297	Retinitis pigmentosa and Allied Diseases	
XXIII—XXV	300—332	Congenital Stationary Night-Blindness	123
XXII, XXVI	298, 299, 333—366	Glioma Retinae	
XXVII—XXVIII	367—405	Total Colour-Blindness	
XXVIII—XLI	406—601	Colour-Blindness	267
XLI	591—601	Anomalous Trichromatism	
XLII—XLVI	602—670	Blue Sclerotics and Fragility of Bone	324
XLVII	671—702	Fragility of Bone	
XLVIII—LXIII	704—941	Hereditary Optic Atrophy	423
LXIV—LXVI	942—982	Microphthalmos	
LXVI	983—992	Megalocornea	
LXVI—LXVII	993—1022	Buphthalmos	
LXVII—LXIX	1023—1090	Glaucoma	555
LXX—LXXI	1091—1146	Aniridia	
LXXI—LXXII	1147—1173	Coloboma iridis	
LXXIII—LXXVI	1174—1249	Ectopia lentis	

Illustrative Plates

Plate	Subject	Page
–	Portrait of Nettleship (Frontispiece)	—
–	Portrait of John Dalton	125
–	Portrait of Theodor Leber	325
β	Fundi in Case of Choroideremia (in colour)	27
–	"Blue Sclerotic Peggy" (in colour)	269
A	Blue Sclerotics with Osteogenesis imperfecta (in colour)	324
B—D	Osteogenesis imperfecta; deformities in living subjects of	,,
E	Osteogenesis imperfecta; skeleton of a new-born child	,,
F	Osteogenesis imperfecta; skeleton of a hydrocephalic boy	,,
G	Osteogenesis imperfecta; adult skeleton	,,
H	Osteogenesis imperfecta; skiagram of lower limb	,,
,,	Osteogenesis imperfecta; amputated and sectional limb	,,
I	Osteogenesis imperfecta; skiagram of a new-born child	,,
J—M	Osteogenesis imperfecta; skiagrams of limbs	,,
N	Osteogenesis imperfecta; skiagram of skull in Norma occipitalis	,,
O	Osteogenesis imperfecta; skiagram of skull in Norma lateralis	,,
P	Types of Coloboma iridis and Aniridia (in colour)	555
Q	Cases of Anophthalmos or mal-development of the Eyes	,,
R	Cases of Coloboma iridis, Microphthalmos and Buphthalmos	,,
S	Cases of Coloboma of the Choroid, Aniridia and Corectopia	,,
T	Cases of Buphthalmos and Megalocornea	,,

PREFATORY NOTE

THE publication of the pedigrees of hereditary eye diseases and anomalies was planned in 1911, but owing to the War the issue of the *Treasury of Human Inheritance* had to be suspended entirely, and now that the work is taken up again the difficulties are far greater than in 1911. In a labour of this kind there are two primary factors, the provision of highly trained research workers and the publication of their researches when they have been completed. The War left the Galton Laboratory in a precarious condition with regard to funds both for payment of research workers and above all for publication expenses. Owing to assistance granted during the last two years by the Medical Research Committee it has been possible for Dr Julia Bell to continue collecting data for the section of the *Treasury* dealing with eye diseases and anomalies. We have to record our gratitude to the Medical Research Committee for the aid provided, and to express a hope that the work as completed will be considered to have justified their support.

The death at a comparatively early age of Edward Nettleship was a severe blow not only to his personal friends but to all workers in the Eugenics and Biometric Laboratories. After retiring from private practice his aid had been most invaluable to us. His friendly help and sympathy could always be reckoned upon, especially in investigations that required accurate and cautious "field work" in the pursuit of hereditary characters, and none knew better than his colleagues in the preparation of the *Monograph on Albinism* issued by the Biometric Laboratory, how keen, suggestive and helpful Nettleship always was: we realised early in our relationship the extreme and unabating activity he would devote to the discovery of missing members of a pedigree, or to the recording of the exact nature of the disease or anomaly in individual cases. He was a born genealogist in the scientific sense, wherein genealogy means a record of characters rather than an index of names.

The one branch of medical science wherein the importance of hereditary studies has been fully appreciated and wherein splendid work has been done during the last decade is undoubtedly ophthalmology, and none can hesitate to admit that the main incentive towards this great achievement was the inspiration provided by Nettleship.

The loss of that inspiration was a great blow to those who were studying heredity with a view to its bearing on human progress. At first it appeared irreparable, and the only way to carry on the tradition seemed to be to show the full force of Nettleship's revelations by publishing a complete edition of his papers. But as the years went by this seemed less and less possible, and to some extent less necessary. For it became clear that Nettleship had created a school of ophthalmological geneticists and that his work would go on without such a stimulant. It then occurred to the Editor of the

Treasury that the best way to honour Nettleship's memory was to issue a volume of the *Treasury* devoted not only, as it must be, to Nettleship's own work and to that of his immediate students and friends, but to the work of all ophthalmologists who had contributed to our knowledge of hereditary diseases and anomalies of the eye. He felt sure from what he knew of Edward Nettleship during their conjoint work on Albinism, that he would much have preferred a *thesaurus* of all men's work to a special emphasis of his own contributions. The fitting memorial therefore seemed to be a comprehensive volume on the hereditary diseases and anomalies of the eye; and in that sense this section of the *Treasury of Human Inheritance* is issued as the Nettleship Memorial Volume. In this way the monument to Nettleship's inspiration and research will reach a wider audience and be of a more permanent character, for it shows not alone what Nettleship did but what he inspired other men to do as well.

While the field of this memorial volume has been thus extended, it is only fitting that it should contain some account of Nettleship's work and personality. Unfortunately the writer of this prefatory note could only speak of Nettleship after he had retired from active practice—of his enthusiasm, of his perseverance and of his suggestiveness in those days he can speak authoritatively—but he felt that more was needed than this, and it was with great gratitude and pleasure that he found Dr J. B. Lawford willing to supply an account of Nettleship's life and work. The volume when completed will also conclude with a bibliography of those papers of Nettleship which do not deal directly with heredity and accordingly are not included in the bibliographies of the separate sections of this volume.

We have most gratefully to acknowledge permission to reproduce pedigrees occurring in the *Transactions of the Ophthalmological Society of the United Kingdom*, the *British Journal of Ophthalmology*, the *Royal London Ophthalmic Hospital Reports*, the *Ophthalmic Review*, etc., from the various authorities concerned. In every case the original source is stated and the reader can easily refer to the fuller material there provided.

Of those who have aided with advice in the preparation of this work the Editor has to thank especially Mr C. H. Usher, who has always been most helpful when difficulties have arisen, and has given assistance of a most varied character in a number of important points. Professor W. Bulloch also kindly consented to read the introductory matter and made valuable suggestions for its improvement.

Lastly the long-standing indebtedness of the Galton Laboratory to Miss H. Gertrude Jones has been still further increased by the arduous task she voluntarily undertook of drawing the whole of the twenty-six plates of this instalment of the *Treasury*. This is a contribution to the success of the volume that only those who are familiar with much of the published pedigree work will fully appreciate. One of the chief difficulties in a volume of this kind is to ensure accuracy and clearness in the pedigree plates, and we are confident that the maximum of what is possible in this direction has been achieved in the original beautiful drawings of Miss Jones.

One last word to the numerous subscribers and other friends of the pre-war *Treasury* must be spoken here. The Editor has waited and hoped in vain for a substantial fall

in the post-war cost of publishing a work of this kind. The cost is practically three times what it was when we started the *Treasury*, and although it seems impossible to hope that the work will ever pay its way, it has been absolutely necessary to raise the price of issue to such an amount that the loss is not prohibitive of any further publication at all.

Several other sections of the work are in progress and the rapidity of their issue entirely depends on the sympathy this resumption of publication meets with.

K. P.

The Galton Laboratory,
University of London.
September 4, 1922.

I believe when the truth of heredity as respects man shall have become firmly established and be clearly understood, that instead of a sluggish regard being shown towards a practical application of this knowledge, it is much more likely that a perfect enthusiasm for improving the race will develop itself among the educated classes.

FRANCIS GALTON.

EDWARD NETTLESHIP, F.R.S., F.R.C.S. 1845—1913

By J. B. Lawford, LL.D., F.R.C.S.

Edward Nettleship, born at Kettering, Northamptonshire, was the fourth son of Henry John Nettleship, solicitor, of that town. His mother was Isabella, daughter of the Rev. James Hogg, Rector of Geddington, and sometime Head Master of Kettering Grammar School. His paternal ancestry has been traced through six generations to one John Nettleship, of Bole, Notts, whose will was proved in 1730/1. John had two sons by his first wife, from one of whom, Richard, is descended the line which so far as sons are concerned has been terminated recently by the death of the only survivor of Edward Nettleship's sibship. John and his son Richard lived at Bole, but the succeeding four generations were resident in Gainsborough, where Henry John Nettleship, Edward's father (the eldest of a large family) was born in 1807. The house of Edward's grandfather in Gainsborough, where his widow and her five daughters were living, is referred to in Vol. I of Mozley's *Reminiscences of Towns, Villages and Schools* as "A Sunlit Spot," and the mother and daughters are described in eulogistic terms. Edward Nettleship was one of seven children, six of whom were boys. The only girl died in early infancy and the youngest boy died at the age of fifteen. Of the five brothers who grew to manhood, four, including the subject of this memoir, became distinguished in their several professions. The eldest, Henry Nettleship, held the Corpus Professorship of Latin, at Oxford, for fifteen years, and was a man of high attainments and wide interests. The second son, John Trivett Nettleship, achieved reputation as an animal painter, and as the author of the first serious study of Browning's poetry. The fifth son, Richard Lewis Nettleship, Fellow and Tutor of Balliol College, Oxford, was a man of remarkable personality and unusual gifts; his untimely death in 1892, from exposure in the Alps, cut short a career of great promise. All three died before their brother Edward.

Henry John Nettleship (Edward's father), described as rather shy and reserved in character, was a man of considerable intellectual power, with a developed taste for poetry and music; both these traits were manifest in varying degrees in his sons, especially in the eldest who was an accomplished pianist. His wife, who at her death at Oxford, at the age of 81, was alluded to as the "mother of the Nettleships" was a woman of strong character, and although physically an invalid her will dominated the household. She was a firm believer in strenuous intellectual exercise, which she preached and practised in the training of her sons: her strongly marked asceticism led to her sons being debarred from all forms of social frivolity and even from many outdoor games during their boyhood, though they were permitted, and had facilities for, such amusements as riding. Edward Nettleship received his early education as a day boy at Kettering Grammar School. His three elder brothers had obtained scholarships at

their respective public schools, but his parents considered that Edward was better suited for studies other than classics or mathematics. The Head Master of the Grammar School at that time, Mr Turle, was an enthusiast in natural history, and imparted his enthusiasm to his pupil who had already manifested a liking for such pursuits. One result of this was that the lad led rather a solitary life out of school, spending his Saturdays and half-holidays in exploring the woods near his home, becoming familiar with the habits of birds and other woodland creatures. Geddington Chase, near Kettering, was a paradise for the young naturalist and the head keeper, whose cottage was in the midst of the wood, was a firm friend and ally and gave him welcome assistance in his search for birds' nests and other objects of interest. Cranford Rectory, near Kettering, which had a large half-wild garden was also a favourite haunt. The boy's love of outdoor pursuits led to the decision that he should become a farmer, and after leaving the Grammar School in 1861 he spent some months on a farm at Kimbolton. Thence he went to the Royal Agricultural College at Cirencester. His record for the next few years is one of extraordinary activity and the accomplishment of a prodigious amount of study. In 1863 he became a member of the Royal Agricultural College. He then entered as a student at the Royal Veterinary College, Camden Town, and at King's College, London; and in 1867 obtained the diploma of Licentiate of the Society of Apothecaries. In the same year he became a member of the Royal College of Veterinary Surgeons, and shortly afterwards was appointed professor of Veterinary Surgery at the Cirencester College, in succession to Mr William Hunting, but did not retain this post for more than a year. In 1868 he obtained the membership and in 1870 the fellowship of the Royal College of Surgeons. Shortly before this he had joined the London Hospital where he became a dresser and at a later date assistant to Sir (then Mr) Jonathan Hutchinson. This was the beginning of a long and intimate friendship which was terminated only by Hutchinson's death not many months before that of his former pupil.

In 1867 or 1868 Nettleship began to give special attention to ophthalmology. He entered as a student at Moorfields Eye Hospital, becoming one of Hutchinson's clinical assistants and an associate and close friend of Waren Tay, acting in the same capacity. In later years Nettleship and he were colleagues on the staff of the hospital. In May 1871 Nettleship was appointed curator of the museum and librarian to the hospital and held this post for $2\frac{1}{4}$ years. Ocular pathology was then in a comparatively early stage and the large amount of material at Moorfields afforded abundant scope for investigation. Nettleship made good use of his opportunities and published several papers of importance. The "Curator's Report" in Vol. III of the *Ophthalmic Hospital Reports* appears to be the earliest of his writings upon ophthalmic subjects. In 1873 he was appointed medical superintendent of the Ophthalmic School at Bow opened by the Local Government Board, in an unused workhouse, for the reception and treatment of cases of ophthalmia and other chronic diseases, drafted from the West Surrey District Schools at Anerley: this was a very difficult post and only his tact and organising power enabled him to fill it successfully. A year later he was asked by the L. G. B. to inspect and report upon the Metropolitan Poor Law Schools in

reference especially to the prevalence of ophthalmia and the measures for dealing with it. This report was published in 1874 and led to some much-needed reforms in the care of pauper children. About the same time he wrote a long and valuable paper embodying the results of his investigations concerning Granular Conjunctivitis, which was published in the *British and Foreign Med.-Chir. Review* for 1874–75.

Nettleship's first appointment on the staff of a hospital was at the South London Ophthalmic Hospital (now the Royal Eye Hospital). He resigned this post in 1878, when he was elected ophthalmic surgeon to St Thomas's Hospital and lecturer on ophthalmology in its medical school, in succession to R. Liebreich. The latter, appointed ophthalmic surgeon to St Thomas's when the new buildings on the Thames Embankment were opened in 1871, was the first specialist in charge of the eye department. During his tenure of office the clinic increased rapidly and was attended by a large number of patients. Under Nettleship's *régime* it became more widely known and by his efforts was brought to a degree of perfection previously unequalled in this country. Nettleship remained on the staff of the hospital until 1895. His work there was carried out with conspicuous ability and his reputation as an ophthalmic surgeon and as a teacher became firmly established. His merits and business capacity were so highly esteemed by his colleagues that in 1888 he was asked to accept the position of dean of the medical school at a somewhat critical period in its history. Although an exceptionally busy man, he undertook the heavy additional duties which this office entailed and carried them out with his usual thoroughness for three years. His name and reputation are still cherished and honoured by those who were associated with him in the hospital and school either as colleagues or pupils.

The next important incident in Nettleship's professional career, and one peculiarly gratifying to him, was his election as assistant surgeon to Moorfields Eye Hospital in 1882. His was the last election to the staff of that hospital conducted on the old plan, whereby every governor of the hospital (there were several hundreds) had to be provided with a copy of the candidate's application and testimonials. The writer of these lines remembers very well assisting Nettleship in this onerous task. Five years later Nettleship became surgeon to the hospital and remained on the active staff until 1898. On his retirement he presented a considerable sum of money to the committee of the hospital to be expended in the purchase of instruments or apparatus for pathological or physiological investigation. Other hospital appointments held by Nettleship, though for comparatively brief periods, were those of ophthalmic surgeon to the Hospital for Sick Children, Great Ormond Street, and assistant surgeon to the Hospital for Skin Diseases, Blackfriars.

Early in 1880 a number of surgeons and physicians interested in ophthalmology decided to found a society for the advancement of this branch of medical science, and the Ophthalmological Society of the United Kingdom came into being, with Mr (subsequently Sir) William Bowman as its first president. Nettleship took a prominent part in the preliminary arrangements and became the first surgical secretary, his medical colleague being Dr (afterwards Sir) Stephen Mackenzie. From the outset Nettleship took a keen and active interest in the society and never relaxed his efforts to further

its success. Many of his most important papers were read before the society and are published in its *Transactions*. In 1895, after serving as a member of council and as vice-president, he was elected president of the society and filled this post with distinction for two years. He was interested in the formation of the Section of Ophthalmology of the Royal Society of Medicine in 1912, and was one of the vice-presidents chosen at its foundation. He read several papers before the section and took an active part in its proceedings.

In 1881 the International Medical Congress was held in London; the ophthalmologists had a large and successful section presided over by Sir William Bowman. Nettleship was one of the secretaries of this section (his colleague being the late W. A. Brailey) and contributed largely to the success of the meeting. The Congress met again in London in August 1913; on this occasion Nettleship was a vice-president of the ophthalmological section and took a keen interest therein. He also entertained some of the visiting members of the Congress at Hindhead. Little more than two months later he had passed away. In 1897 Nettleship was chosen as president of the Ophthalmological Section of the British Medical Association for the annual meeting held in Montreal.

In 1909 he delivered the Bowman lecture before the Ophthalmological Society "Upon some Hereditary Diseases of the Eye." In 1910 he was appointed a member of the Board of Trade Departmental Committee on Sight Tests for the Mercantile Marine. After two years of arduous investigation and experiment the Committee's Report was issued in 1912. From that date until his death Nettleship was a member of a special board which sat at South Kensington for the examination of candidates for the mercantile marine who appealed from the decision of the Board of Trade examiners in colour vision.

For some years after he obtained his medical qualifications Nettleship assisted his former teacher Jonathan Hutchinson in his hospital and private practice. In 1875 he began practice independently in Wimpole Street, where he continued to live, although not in the same house, until 1902. His professional knowledge and skill soon became recognised by the public as well as by the medical profession, and patients in large numbers sought his advice. In spite of the demands of hospital attendance and a large private practice he found time (one is tempted to say he *made* time) to write a students' text-book on diseases of the eye of which five editions were published. Throughout his professional career Nettleship was a voluminous writer, his papers covering almost the whole range of ophthalmic science, more especially from the clinical side. They were invariably characterised by accuracy of statement and evidence of extreme care in observation. It is a tribute to his ability and to the punctilious care with which he prepared material for publication that there is scarcely a paper among them which even now will not repay perusal and has not some permanent value. His knowledge of ophthalmic medicine and surgery was extraordinarily wide and very accurate; although not very conversant with languages other than his mother tongue, he kept well abreast of French and German ophthalmic literature, and his large clinical experience and retentive memory gave him a familiarity with rare or unusual types of disease which

few if any of his colleagues could equal. In private practice Nettleship was very successful, and his fame as an ophthalmic surgeon was world-wide, his opinion and advice being largely sought by his professional *confrères*, as well as by the public.

In 1902, when at the height of his professional success, he decided to retire from practice and left London to reside permanently at Hindhead, where he had spent week-ends and holidays for many years. This retirement from practice was but the starting-point of renewed activity in scientific pursuits. He intended and indeed began to carry out some pathological research, but he soon relinquished this and devoted all his time and energy to the study of heredity in disease, a subject to which he had given much attention for some years. During the next ten or eleven years he accomplished a prodigious amount of work of a very high standard, "working in such a way that his pedigrees are models of orderly observation and recording." The value of these researches was recognised by his election to the fellowship of the Royal Society in 1912. Further reference to his labours on heredity, by the writer of these lines, would be superfluous in a journal dealing specially with this subject.

"The esteem and regard in which Nettleship was universally held by his pupils and colleagues found definite expression at the date of his retirement from practice. The fund then collected was, in accordance with his own desire, devoted to the establishment of a medal 'for the encouragement of scientific ophthalmic work.' This prize is in the custody of the Ophthalmological Society and is awarded triennially. In 1909, to the great satisfaction of all, it was awarded to Nettleship himself in recognition of his researches upon heredity in diseases of the eye." (*Lancet*, Nov. 8, 1913.)

The foregoing paragraphs chronicle the main events in Nettleship's professional career and convey some idea of the strenuous life he led from the time he left school until he relinquished his work as a hospital surgeon and teacher and retired from practice. It is comparatively easy to compile such a record, especially of one who went steadily forward from one success to another; it is largely a statement of facts. A task, far less easy, is to write of his character and personal attributes.

As no member of Nettleship's family is now living but little information concerning his boyhood is forthcoming. By reason of his devotion to natural history, especially bird-life, his brothers nicknamed him "Birdbearing Ned" and there is a story told by an elder brother that once, when as a small boy he had been studying botany, he came in fatigued with his ramble, and flinging himself down exclaimed—"I will now become sessile upon an ordinary chair." From other sources comes the information that even in his early days, as so notably in later life, he was a keen enquirer and investigator, laying the foundations of that extreme accuracy of observation and statement which characterised his work in after years.

A relative who knew his home in Kettering in the late fifties, writes: "It was a small but roomy house, where his father had his office; it was truly the abode of plain living and high thinking, with all the essentials of a cultured country life."

At an early stage in his medical career, as already mentioned, Nettleship had the good fortune, to which he often referred, to be intimately associated with Jonathan Hutchinson, one of the most astute and industrious clinical observers of the nineteenth

century. This association encouraged and abetted his zeal in the investigation of disease, and probably confirmed his habit of note-taking of which Hutchinson was a past master. To the end of his professional career Nettleship took abundant notes of every case of interest or importance which came under his observation, notes which, as the writer knows well, are models for any medical man.

Although Nettleship's reputation as a surgeon and a scientist is permanently established, his place in the memory of many men was gained by his ability and attractiveness as a teacher. As a lecturer in a class-room or theatre he was not at his best; he was not eloquent and his voice was not sufficiently powerful; as a clinical teacher of the individual, or of a group of students, he had few equals; he excelled especially in post-graduate teaching. During the active period of his service at Moorfields Hospital, his qualities as a teacher became widely recognised; these added to his magnetic personality attracted many of the best students to his side, most or all of whom soon became imbued with his spirit and with his assiduity in the investigation of disease, and were infected by his enthusiasm. He did not suffer fools gladly and had no use for the man whose clinical work was slovenly or inaccurate. Ignorance, provided the desire for knowledge was evident, was no bar, and no genuine seeker ever failed to obtain his help. Few if any of those who worked with him at St Thomas's or Moorfields will ever forget the splendid example in the methods of clinical enquiry set by their teacher.

In practice Nettleship gained and retained the confidence and loyalty of his patients to a remarkable degree. He was far from being all things to all men, but his obvious sincerity and straightforwardness, and his genuine kindness and sympathy were quickly recognised by the large majority. The writer has had many opportunities of learning from former patients how greatly they valued his advice and friendship.

In Nettleship's personal character there was much that was noteworthy and much that called forth admiration. Broad-minded and well-informed he possessed to an unusual degree the judicial mind, and his judgment in complex questions was seldom at fault; high ideals, scrupulous integrity and hatred of everything false or untrue were prominent traits. His natural reserve masked in some degree his decision of character, his determination and his unbounded energy.

Throughout his life Nettleship was an indefatigable and tireless worker, and accomplished a great deal while others slept, his habit being to rise very early and work when all was quiet. To those who gained his confidence he was a staunch and loyal friend, and many of his acts of kindness were known only to the recipients. He exerted a remarkable and far-reaching influence for good on many who were brought into contact with him, both young and old, and had no more devoted admirers than children and young persons. Some of these now well advanced in years have expressed in grateful terms their indebtedness to Nettleship's example and precept. The writer, who had the privilege of a long and close association with Nettleship, has had for many years an unbounded admiration for the true nobility of his character and a deep appreciation of his warm-hearted and sympathetic nature. These qualities were, naturally, even more fully realised by those in his immediate circle; of this there has been abundant testimony in letters from relatives and intimate friends. In 1869, before his medical

studies were completed, Nettleship married Elizabeth Endacott, daughter of Mr Richard Whiteway, of Compton, Devon; they lived at first in Grafton Street in furnished rooms: subsequently for a period of eighteen months, they shared a house in Finsbury Pavement with his friend and colleague, Mr Waren Tay, and then, in order to be near the London and Moorfields Hospitals, they took "a little old-fashioned creeper-clad house with a garden" at Stepney, where they had two students living with them. Their stay in this pleasant abode was followed by a dreary year of residence in the Bow Ophthalmic School referred to above, after which they moved to Wimpole Street.

When visiting the Hutchinsons at Haslemere, the beauty of that part of Surrey captivated Nettleship and his wife, and in 1885 he bought land at Hindhead on which he built a charming house, completed in 1887. Here, whenever his work permitted, Nettleship spent many happy days, working in the garden and the woods which were to him a constant source of delight. His love of country life, birds, trees and flowers, grew with advancing years and probably he was never happier than at Hindhead. Many of his friends retain most pleasant memories of the kindness and hospitality of himself and Mrs Nettleship in their Surrey home. In 1910 they moved to a smaller house pleasantly situated on the side of a hill with a beautiful outlook across a valley. In this house, surrounded by the trees and flowers he loved, Nettleship died; and here his widow still resides.

This sketch would be very incomplete without a brief reference to Nettleship's partner in life, one who cheerfully shared the struggles of his early days, and rejoiced in his well-deserved success. Few men have had so loyal and devoted a helpmeet, and it is easy to imagine how greatly the companionship of one so gifted with womanly charm and true sympathy helped to smooth the rough places on life's pathway.

SECTION I

RETINITIS PIGMENTOSA AND ALLIED DISEASES

CHAPTER I

GENERAL ACCOUNT

This title must inevitably recall the name of Nettleship to all interested in the inheritance of eye disease, it was taken from his writings, and was indeed chosen in order to emphasise his pioneer work on the subject and the stimulus which he provided to the younger ophthalmologists of his day to work in the same field. We have again, with Nettleship, included as diseases allied to retinitis pigmentosa, retinitis pigmentosa sine pigmento, retinitis punctata albescens, gyrate atrophy of the choroid and retina, choroideremia, and the two distinct types of congenital stationary night-blindness.

Nettleship included choroideremia in his group for clinical reasons believing it to be improbable that this condition, which he described as 'developmental rather than pathological,' bore any relation to retinitis pigmentosa, but the extraordinarily interesting pedigree published by Smith and Usher (see Fig. 119) showing choroideremia in a boy whose mother and one sister had retinitis pigmentosa and whose father had congenital stationary night-blindness, definitely links it up with one or other of these conditions and Zorn's pedigree (see Fig. 262) showing its occurrence in the same family with atypical retinitis pigmentosa and possibly gyrate atrophy of the choroid and retina suggests that choroideremia is in fact allied to retinitis pigmentosa, and we happily do not longer need to make any apology for including it under our title; indeed it is now well recognised that retinitis pigmentosa itself is a developmental defect, the exact nature of which is still obscure. For congenital stationary night-blindness the case is different; both types of this condition are undoubtedly due to some developmental defect but nothing is known of the nature of the defect and we have no reason other than convenience for placing either type of the condition under our title, the common symptom of night-blindness being the only link between this disease and retinitis pigmentosa, and this symptom though very usual in the latter disease is by no means invariably present.

It is greatly to be regretted that we still as in Nettleship's day have to admit a complete ignorance of the pathology of congenital stationary night-blindness, no *post-mortem* examination having yet been made on the eye of any person suffering from it; this omission is explained by the rarity of the condition and by the fact that it never leads to a need for excision of the eyeball during life; but such ignorance should not be for ever insurmountable.

(*a*) *Historical.* It is evident that before the invention of the ophthalmoscope we could expect to find no differentiation of the various conditions included under our title, unless it were to distinguish between retinitis pigmentosa, characterised by its

progressive nature leading to blindness and by its contracted fields of vision even in bright daylight in advanced cases, as opposed to the stationary night-blindness associated with no disability of vision by day; but congenital stationary night-blindness is a very rare condition now and we have no evidence that it has ever been less rare, and it may easily have escaped detection as a clinical entity in the days when there were only very few writers on ophthalmology; it is perhaps more remarkable that retinitis pigmentosa, with its frequent hereditary nature, its train of symptoms and the very characteristic attitude of its victim who ultimately has only direct vision and peers round to look at everything as a result of his contracted fields, should have escaped recognition as an entity by, say, such an astute observer as Hippocrates. A careful search through the works of a large number of early writers has failed to reveal anything more suggestive of the existence of retinitis pigmentosa or stationary night-blindness in their days than the statement made by some of them in discussing the symptom of night-blindness that occasionally the condition has not responded to treatment, or has progressed to complete loss of sight.

It may be well here to consider for a moment the symptom of night-blindness which has been variously described as nyctalopia, lusciosus, hemeralopia, dysopia tenebrarum, amblyopia crepuscularis, as moon-blindness by sailors from the belief that it was produced by the action of moon-beams falling on the eyes of those who were exposed to them during sleep, and finally as hen-blindness from the fact that hens were believed to be normally night-blind and to go to roost when the sun sets because they could no longer see to pick up grains of wheat. There has been much discussion and controversy as to whether or no Hippocrates and other early writers used the word 'nyctalopia' in the sense of night-blindness or day-blindness and the doubt has led to much confusion. The point was discussed exhaustively by Greenhill (see Bibl. 109) and by Tweedy (see Bibl. 116) and the general opinion is in favour of night-blindness as the correct translation, though the cautious reader would hesitate to pledge himself to a diagnosis of the condition described by Hippocrates in the following words—"Nyctalopia is most apt to attack young persons, either males or females, and to pass off spontaneously on the fortieth day or in seven months, and in some cases it endures for a whole year. Its duration may be estimated from the strength of the disease and the age of the patient. They are relieved by deposits which determine downwards, but these rarely occur in youth. Married women and virgins that have the menstrual discharge regular are not subject to the complaint. Persons having protracted defluxions of tears who are attacked with nyctalopia, are to be questioned whether they had any previous complaint in the head[1]."

However this may be, the symptom of night-blindness has been recognised and described by writers of all ages in all countries but in most cases temporary night-blindness only was referred to even as late as the nineteenth century; it has been noted in association with malnutrition, nerve exhaustion, xerosis conjunctivae, choroiditis syphilitica, rheumatism, lead colic, hysteria, scurvy, onanism, pregnancy, ergo-

[1] The genuine works of Hippocrates, translated by Francis Adams, London 1849, *Appendix to The Book of Prognostics*. Vol. I., p. 267.

tism, cholera, helminthiasis, malaria, disorders of the stomach, liver or kidney disease, with "weakness in the head and especially a thickening of the optical pneuma and of the other humours and membranes of the eye," it has also been described as a result of living in marshy places and was noted in certain cases of ague in the Lincolnshire fens, finally it has been noted as a result of dazzling. In all cases the cure for night-blindness prescribed with extraordinary persistence throughout the ages all over the globe has been very much as follows—"Nyctalopic persons should be treated, if robust, with venesection at the elbow and at the corners of the eyes, but when the humours are corrupt, by purification with a proper purgative. Then, after the general evacuation of the body, gargles should be employed and purification should be practised through the nose and sneezing excited..... Goats'[1] liver appears to be of use to these patients with salt but roasted without oil and eaten very hot. Others however are accustomed to anoint the eye with the broth which exudes from the liver during the roasting; others during the roasting have the eyes held open in the uprising steam and so foment them.....[2]." This last prescription of liver for night-blindness is of great antiquity[3], and appears to date as far back as the famous 'Book of the Eyes' in the Egyptian Papyrus of 1500 B.C. found between the bones of a mummy in the Theban Necropolis, which came into the hands of Ebers in 1872 and was deciphered by him; in this work the roasted liver of an ox is prescribed for some unnamed disease of the eyes and this treatment has been thought to suggest that the unnamed disease was night-blindness and that thus this disability was recognised in Egypt some 3400 years ago. Guthrie in 1794 gives an interesting account of epidemic "hen-blindness" in Russia following the lenten fasts and of its rapid cure by means of an infusion of *centaurea cyanus* (corn flower); he refers to it as a curious disease of Russia which he never remembers to have been treated by any British physician[4]. Bampfield writing in 1814 described night-blindness associated with scurvy in sailors which he proceeded to cure by means of blisters[5].

A great number of similar references might be given and if we search amongst them for signs of a failure to cure, and thus for possibly early references to retinitis pigmentosa though unrecognised as such by the writers, we find a condition described by Bontius[6] in 1642 which may or may not have been night-blindness but has been frequently cited as such; to quote from a translation of his work by a Physician in 1769 "The people who sail to Amboyna and the Molucca Islands are often troubled with a weakness of sight and even a total blindness arising from thick and viscid humours stuffing the head and brain and obstructing the optic nerves: which blindness,

[1] The liver of a goat was prescribed from the belief, as Pliny reports, that this animal sees by night as well as by day. See Bibl. No. 2.

[2] Taken from Aëtius of Amida who lived 502—574 A.D. Translated by Shastid in article on "The History of Ophthalmology" in *The American Encyclopedia of Ophthalmology*, Vol. XI., pp. 8664—65, Chicago 1917. For early reference see Bibl. No. 4.

[3] And has survived the ages, for cod liver oil, or even liver to be eaten are still prescribed in certain cases of night-blindness though we no longer specify that the liver should be from a *he*-goat or from a black cock, or black swine, etc.

[4] Bibl. No. 22. [5] Bibl. No. 23. [6] Bibl. No. 13.

however, is not perpetual but often ceases upon a change either of air or better diet. The inhabitants of these islands impute it to eating hot rice." Bontius then proceeds to describe how he cures the condition by purges, sternutatories, masticatories and bleedings, and adds that the grand specific in this disorder is our old friend the liver, this time, of the fish *Lamia* eaten crude with salt; he says finally—"upon the whole though this blindness is often transitory yet if neglected and an improper diet be persisted in with an unseasonable use of arrac, it often degenerates into a total deprivation of sight of which everywhere here we meet with instances." Etmuller[1] in 1701 writes "Nyctalopia si interdiu recte, vesperi parum aut nihil videtur, raro curatur." Maitrejean[2] in 1707 refers to the night-blindness which can be cured and the night-blindness which cannot be cured and infers that it is only possible to determine which case is being dealt with by watching the effects of treatment. From this date onwards the knowledge that night-blindness cannot in all cases be cured and may under the most favourable conditions progress to complete blindness by day also, becomes more general, though as late as 1814 Bampfield is found to state that night-blindness only progresses to complete blindness as a result of a failure to receive proper treatment.

It may by no means be taken for granted that the condition of temporary night-blindness occurring with its varied associated diseases is totally without interest to us writing of retinitis pigmentosa and allied diseases; little is known of the mechanism of its production, indeed we do not even know whether it is of central or of peripheral origin. A great number of people live in low-lying unhealthy districts without becoming night-blind, and yet Zimmermann[3] in 1883 describes a family of four children living in such a district who all became night-blind and remained so until they moved to a healthy district when they all recovered; may there then be a family predisposition to develop temporary night-blindness under certain conditions? A case described by La Serre[4] in 1688 (see Plate XXII, Fig. 291) has been quoted as the earliest recorded case of inherited night-blindness; this was also a case of temporary but recurrent night-blindness which occurred every year towards the month of May and persisted for three or four months; a paternal aunt of the patient and two children of this aunt were affected in the same way.

It would be of interest to know whether normal members of stocks in which retinitis pigmentosa or congenital night-blindness occurs tend to become night-blind under conditions apparently favourable to its production more readily than do members of normal stocks. When we look for early references to the inheritance of permanent night-blindness the information is very scanty. The first definite record we have found is due to Ovelgün[5] as late as 1744 when he reports a history of night-blindness in a brother and sister and in the sons of two of their mother's paternal uncles (see Plate XXII, Fig. 292); he also gives some evidence to suggest that the case was one of retinitis pigmentosa. From this date we find no further reference until 1830 when Richter[6] describes congenital night-blindness in three members of a sibship of nine whose parents and other relatives were free from the defect (see Plate XXII, Fig. 297).

[1] Bibl. No. 16. [2] Bibl. No. 17. [3] Bibl. No. 127.
[4] Bibl. No. 18. [5] Bibl. No. 19. [6] Bibl. No. 24.

Eight years later we find the pioneer work of Cunier[1] describing the famous Nougaret family with its history of congenital stationary night-blindness in six generations. This pedigree was brought up to date and extended to ten generations in 1907 at the suggestion of Nettleship[2], who went over to Vendémian himself and examined certain members of the family with the ophthalmoscope for the first time, thus being able to pronounce the case to be one of congenital stationary night-blindness and not one of retinitis pigmentosa or any condition involving changes in the fundus (see Plate XXIV, fig. 317). Cunier's work must have appeared as a rather startling announcement to the ophthalmologist of his day, and it is surprising that it did not stimulate the immediate production of other family histories, but we find no further pedigree of the kind until nine years later when Stiévenart[3] in 1847 publishes an interesting history of congenital stationary night-blindness affecting both sexes, as in Cunier's case, and extending this time through four generations (see Plate XXIII, fig. 305). This was the last case of inherited night-blindness found in the literature before the invention of the ophthalmoscope, indeed so far were the authors of that day from a true recognition of the intensity of inheritance for these conditions that a writer whose works on surgery extended over four volumes was able to state—"...l'amaurose peut être congéniale; quelques observations, incomplètes à la vérité, porteraient à croire qu'elle est quelquefois héréditaire," or again "On trouve dans les Ephémérides des Curieux de la Nature, décade II. ann. 6, obs. 79[4], un fait qui porterait à croire que l'héméralopie est quelquefois héréditaire, si un seul fait suffisait pour prouver l'action d'une telle cause[5]."

And now we come to the invention of the ophthalmoscope in 1851, when pigmentation of the retina could first be seen in the living subject and it became possible to classify cases in which night-blindness was a symptom on the basis of the condition found on an examination of the fundus. Pigmentation of the retina had been described post mortem, under the name of 'melanosis retinae,' by Langenbeck[6] in 1836, and von Ammon[7] in 1838 gives a coloured illustration of the condition in his atlas; but there was at this time no recognition in the clinic of the correlation of pigmentation of the retina with the symptoms of what we now describe as retinitis pigmentosa. The acquisition of the ophthalmoscope completely revolutionised the work of the ophthalmologist and immeasurably widened his scope and knowledge, though it is sad to have to admit that, so far as our group of diseases is concerned, the benefit from the discovery was chiefly if not entirely limited to the ophthalmologist, and has contributed little or nothing to relieve the gloomy prospect for the patient to this day.

It becomes clear then that since cure is not to be expected prevention is the all-important problem and a knowledge of the etiology of the condition and numerous illustrations of its varied degree of inheritance become of great urgency.

It was perhaps the recognition, conscious or unconscious, of this position, stimulated doubtless by the beauty and interest of the picture revealed by the ophthalmoscope, which contributed to the production of what we might almost describe as an

[1] Bibl. Nos. 27, 28. [2] Bibl. No. 243. [3] Bibl. No. 30. [4] La Serre's case.
[5] Boyer, P. *Traité des maladies chirurgicales.* Paris 1847. T. IV., p. 602 and p. 616.
[6] Bibl. No. 25. [7] Bibl. No. 26.

epidemic of inaugural dissertations, theses or journalistic articles on retinitis pigmentosa in the latter half of the nineteenth century, some of which were excellent, some bad and others indifferent; the story was told and repeated and again repeated of how van Trigt[1] in 1853 first described the disease, in a case at the Donders clinic at Utrecht, as seen through the ophthalmoscope; how von Graefe[2] at about the same time described the disease in Berlin under the name of *morbus Arianus*, having observed it in a patient, the Spanish Marquis Ariani; of how Donders[4] first named the disease retinitis pigmentosa in 1857, a bad name suggesting that the disease is of inflammatory origin as indeed for many years it was believed to be. Again it is told and retold how Leber[4] first described *retinitis pigmentosa sine pigmento*; how Mooren[5] in 1882 first described and named *retinitis punctata albescens*; how Fuchs[6] in 1896 first described and named *atrophia gyrata chorioideae et retinae*; how Mauthner[7] in 1872 first described a case of choroideremia; and how Leber[8] as late as 1877 first described congenital stationary night-blindness. All writers at this period described cases and fully recognised the need to inquire into the family histories and to consider the question of associated diseases or defects; they provide much valuable information, often very scanty so far as individual cases are concerned but throwing much light on the significance of the various factors concerned, when all available material is collected and classified.

The need for collecting and classifying all available information was realised and carried out exhaustively by Nettleship[9], whose interest in the inheritance of eye disease was, we suspect, possibly stimulated originally by Jonathan Hutchinson: so thorough was the collection of data made by him in 1907—8 from which we take our title that we have been able to find extremely little of interest or significance, bearing on the subject and published before that date, which is not included either in his text or his bibliography; in addition to this Nettleship certainly contributed more fully worked out pedigrees from the patients who consulted him than any other writer up to his date.

And since the date of Nettleship? Well, the reader has only to glance for a moment at Plate VIII, Fig. 119 and at Plates IX—XVII, Figs. 133—173, in order to grasp something of the nature of the contribution of Usher[10], the pupil and friend of Nettleship, to our subject. Other recent contributions which appear to the writer to be of rather special interest are the lecture by Doyne[11] in 1910 emphasising some of the more obscure and less generally recognised signs and symptoms of retinitis pigmentosa; the extremely suggestive and perhaps revolutionary paper by Treacher Collins[12] on the etiology of retinitis pigmentosa published in 1919; the pedigree of congenital stationary night-blindness in an American family, published by Newman[13] in 1914; and the pedigree by Mücke[14] of retinitis pigmentosa which presents many points of interest.

[1] Bibl. No. 31. [2] Bibl. No. 47. [3] Bibl. No 36. [4] Bibl. No. 72.
[5] Bibl. No. 114, p. 217. [6] Bibl. No. 187. [7] Bibl. No. 78. [8] Bibl. No. 98.
[9] Bibl. No. 251. [10] Bibl. Nos. 301, 310. [11] Bibl. No. 268. [12] Bibl. No. 318.
[13] See Plate XXIV, fig. 321. Bibl. No. 300. [14] See Plate XIX, fig. 212. Bibl. No. 327.

(β) *Signs and Symptoms.* The three classical symptoms of retinitis pigmentosa, which are very generally described as diagnostic of the disease but are not invariably present, are night-blindness, contraction of visual fields and ophthalmoscopically visible pigmentation of the retina; other characteristics are the early, or in some cases congenital, onset of the disease and its slow maturity progressing to complete blindness in middle age but retaining relatively good central vision until an advanced stage of the disease; the disease is usually bilateral; signs of atrophy of the disc are usually present and narrowing of the retinal vessels, the larger of which may degenerate into mere threads and the smaller vessels may disappear altogether. Further, more obscure and less generally recognised symptoms of retinitis pigmentosa noted by Doyne[1] are as follows: i. the persistence of images; ii. in advanced cases there is often a marked preference of the patient for a particular degree of artificial light; iii. he describes a momentary sensation of bright light circling round the periphery of the visual field; iv. there is a zone of greyish infiltration situated immediately inside the main pigmented zone characteristic of the disease; v. a layer of fine opalescent vitreous opacities may almost always be detected lying immediately anterior to the retina.

To consider some of these symptoms in more detail. Night-blindness is perhaps the first symptom to appear and is very generally present, it is present however to a varying degree, every grade being described between the case of the patient who becomes absolutely blind in a dim light and the patient who does not know that he sees less well than other people in the dark and in whom the defect is only demonstrated on an estimation of the light sense by means of a photometer; or again this symptom may in rare cases be absent altogether. Thus Marlow[2] describes a case of retinitis pigmentosa with extreme contraction of the visual fields and without night-blindness; Axenfeld[3] reports several cases in which night-blindness was not complained of and in one case could not be detected by the use of a Förster's photometer; Hutchinson[4] describes a case of retinitis pigmentosa in an advanced stage which had been progressing during twenty years or more in which night-blindness was not present. Illustrations of cases in which night-blindness has not been demonstrated or is not of a marked order may be seen in the following pedigrees of our series: Plate II, Fig. 5; Plate V, Fig. 65; Plate VI, Fig. 89; Plate VII, Fig. 116; Plate VIII, Fig. 119; Plate X, Fig. 137; Plate XIII, Figs. 147, 150, 152; Plate XIV, Fig. 155; Plate XV, Fig. 160; Plate XVIII, Figs. 190, 199, 200; Plate XIX, Fig. 215; Plate XX, Fig. 249; and Plate XXII, Fig. 288[5].

The determination of the exact form of the visual fields in retinitis pigmentosa is of some difficulty owing to the varying results obtained at different times and under different conditions of lighting, and owing also to the fact that a certain amount depends upon the intelligence of the patient, but it is in the opinion of some clinicians of great diagnostic importance and aids in the differentiation of primary retinitis pigmentosa from that type of the disease which is secondary to a chronic disease of the choroid. Von Graefe[6] first drew attention to the fact that a greatly contracted visual field with relatively good central vision was a special feature of retinitis pigmentosa,

[1] Bibl. No. 268. [2] Bibl. No. 178. [3] Bibl. No. 257. [4] Bibl. No. 66.
[5] See *Description of Pedigree Plates*, p. 47 *et seq.* [6] Bibl. Nos. 35, 38.

he noted that the retraction might be excentric and that ring scotoma might be present. Gonin[1] after careful investigation concludes that the retraction of visual fields in this disease is not really concentric; that the first disturbance of vision takes place in an equatorial zone and spreads from there in a direction centrifugal and centripetal, and that the functions of the extreme periphery and of the macular region are maintained until a relatively late stage of the disease; he concludes further that in most cases the peripheral zone of vision is lost before the central field, also that the presence of a ring scotoma is the rule and not the exception as is maintained by some observers. Other interesting observations on the subject have been described by Hepburn[2] and by Usher[3]. Most authors merely describe a *concentric* contraction of fields but there has been, and indeed still appears to be, some difference of opinion on this point between authors who have done a considerable amount of work on the subject.

The ophthalmoscopic picture of pigmentation of the retina in typical cases is very characteristic. The visible deposits of pigment have migrated from the pigment epithelium into the internal layers of the retina; they collect chiefly along the vessels and may be found in their perivascular sheaths[4]; when the vessels branch a typical deposit is formed, which has been likened to a bone corpuscle, with fine processes which interlace to form a coarse network; deposits in the macular region change their character from the absence of vessels there and are seen merely as granules. In an early case pigment is seen characteristically in the equatorial zone only, but with the progress of the disease the distribution extends peripherally and centrally until the whole fundus may appear to be covered with a coarse black net. With the migration of pigment from the epithelial layer of the retina the choroidal vessels become visible and give a tesselated appearance to the fundus. The condition however presents every variety in intensity from a dense or diffuse distribution extending from the extreme periphery to the macula itself, to a total absence of pigment in the internal layers of the retina, and although pigmentation extending to the macula is perhaps always associated with extreme contraction of fields and severe visual defect, the converse is by no means the case, for cases are on record in which the fields are contracted to the fixation point with severe defects of central vision without a trace of pigment becoming visible. Such cases are known as *retinitis pigmentosa sine pigmento*. Cases are more frequently described in which no pigment is visible on a first examination but typical deposits are seen to appear at a later stage of the disease.

Pedigrees of our series in which cases occur showing little or no pigment relatively to the stage of the disease as indicated by other signs and symptoms may be seen as follows: Plate II, Figs. 7, 8, 9, 11, 12, 16; Plate III, Figs. 21, 25; Plate IV, Fig. 33; Plate VI, Fig. 72; Plate XI, Figs. 140, 142; Plate XIII, Fig. 150; Plate XIV, Fig. 158; Plate XVI, Fig. 166; Plate XVII, Figs. 175, 178, 179; Plate XIX, Figs. 212, 215, 217; Plate XX, Figs. 223, 227, 235, 239, 241, 242; Plate XXII, Fig. 294[5]. An examination

[1] Bibl. Nos. 215, 218, 222. [2] Bibl. No. 249. [3] Bibl. No. 301, pp. 137—145.

[4] Nettleship says "when visible vessels are ensheathed in pigment such vessels are in my experience always veins, i.e. the pigment travels in the direction of the blood current." See Bibl. No. 263, p. xcix.

[5] See *Description of Pedigree Plates*. See also Bibl. Nos. 87, 158, 258, 285.

of these histories may suggest that in some cases *retinitis pigmentosa sine pigmento* is merely an early stage of typical retinitis pigmentosa, but this cannot be assumed and is certainly not true of all cases. Of interest in this connection is the case described by Hocquard[1] of a man aged 21 whose right fundus showed one oval spot of pigment only, lying along the trajectory of a vein, his left fundus showed two or three small pigment deposits of typical shape; the man died of malignant scarlet fever and a *post-mortem* examination of his eye by Poncet[2] revealed a pigmented zone 15 mm. in width in the external layers of the retina[3].

To consider now the age of onset of the disease, the rate of maturity and the age at which blindness ensues. The information on these points is vague and perhaps inevitably so in most cases, but from the examination of reports it may we think be accepted that the onset is at an early age in the great majority of cases and is a rare occurrence after the age of 20 years; also we think it may be accepted that sight is very frequently lost before the age of 40 years[4]. It would be of interest to investigate whether there is not a tendency for the age of onset and age at which blindness ensues to be roughly constant within the stock, for we do find that in certain families the disease is described as congenital in all the affected members, in other families the onset is invariably late and again a very rapid course may be a characteristic feature in certain stocks.

The sort of series which can be obtained from our material omitting certain cases where the diagnosis is uncertain are as follows:

Time of Onset		Age of Blindness* in Retinitis Pigmentosa	
Congenital, before earliest recollections, or in infancy	75	0—4 years	17
In childhood	23	5—9 „	10
In school period	14	10—14 „	8
In youth	8	15—19 „	9
Or where age is actually stated:		20—24 „	9
0—4 years	7	25—29 „	6
5—9 „	19	30—34 „	5
10—14 „	24	35—39 „	4
15—19 „	17	40—44 „	12
20—24 „	5	45—49 „	6
25—29 „	5	50—54 „	13
30—34 „	3	55—59 „	4
35—39 „	4	60—64 „	2
40—44 „	2	65—69 „	1
45—49 „	1		
50—54 „	0		
55—59 „	1		

* Blindness for this table includes those who were described as nearly blind, those whose vision was reduced to finger counting and those whose vision was reduced to hand movements only.

[1] Bibl. No. 89. See also Fig. 7. [2] Bibl. No. 91.

[3] This case very possibly represents an early stage of retinitis pigmentosa.

[4] Nettleship summarises the available information on this point. See Bibl. No. 251, pp. 350—6.

Retinitis pigmentosa is only exceptionally asymmetrical in its manifestations, even when the distribution of pigment is atypical and confined to one or other quadrant of the fundus it is very generally described as being the same in both eyes of the patient, nevertheless undoubted cases of unilateral retinitis pigmentosa do exist in which cases the one eye may be in all respects typical of the disease and the other eye perfectly normal. It is of course possible that more cases of unilateral defect from this source may exist than is recognised, for amongst the working class population the slow progressive loss of vision, in one eye only, may easily escape notice unless some difficulty with the sound eye brings the patient to an ophthalmological clinic, for the majority of people only consult the medical profession when they are in pain or their daily routine is being hampered in some way. Nevertheless we feel assured that there is no appreciable amount of undetected unilateral retinitis pigmentosa. The following cases are all we have been able to find in the literature illustrating the condition. Nettleship[1] in 1908 reviewed previously published cases and reports a case of his own in a woman aged 30 who had "perfectly typical and very abundant retinitis pigmentosa affecting the right eye only"; he also describes in some detail the case reported by Pedraglia[2] in 1865, by de Wecker[3] in 1870, by Baumeister[4] in 1873, by Derigs[5] in 1882, by Ancke[6] in 1885, by Reinecke[7] in 1894, by Rosenbaum[8] in 1900 and by Gonin[9] in 1902. Of this series Baumeister's case is of special interest as the patient, a man aged 44, was not only blind in his left eye from typical retinitis pigmentosa but had been deaf since childhood in his left ear; his right eye was normal and not night-blind, his right ear was not deaf. Nettleship considered that there was no reason to suspect syphilis either from the history or from the ophthalmoscopic appearances in the cases quoted by him. Pagenstecher[10] in 1861 describes an atypical case associated with deafness in a girl aged 20; he regards her condition as primarily a choroidal affection; the right eye only was affected; three of her maternal aunts were deaf and night-blind. The case published by H. Schmidt[11] in 1874 is of interest in this connection; a peasant aged 55 had atrophy of the disc and some narrowing of the retinal vessels on the right side only, he had seen badly with this eye since childhood and it was now blind except for a small portion of the outer quadrant of the field of vision where he could still see to count fingers; his left eye was normal; two of his children had typical retinitis pigmentosa which in each case was more advanced in the right eye than in the left. Günsburg[12] in 1890 described a case of typical retinitis pigmentosa in one eye only; the patient in this case had a history of an apoplectic fit at a relatively early age.

Wilbrand and Saenger[13] in 1909 report a case of unilateral retinitis pigmentosa in a man who at the age of 46 years had V. $= \frac{6}{9}$ for the left eye which was ophthalmoscopically normal whilst his right eye could count fingers only, and had posterior cortical cataract with retinitis pigmentosa; the patient's sister was reported to be nearly blind and deaf. Jennings[14] in 1911 describes a woman aged 35 years whose right field of

[1] Bibl. No. 251, pp. 164—6. [2] Bibl. No. 51. [3] Bibl. No. 160. [4] Bibl. No. 79.
[5] Bibl. No. 112, p. 19; Plate XX, Fig. 236. [6] Bibl. No. 132. [7] Bibl. No. 179, p. 11. [8] Bibl. No. 213, p. 17.
[9] Bibl. No. 218, Case 19. [10] Bibl. No. 44; Plate XXI, Fig. 252. [11] Bibl. No. 88; Plate XVIII, Fig. 200.
[12] Bibl. No. 161. [13] Bibl. No. 264; Plate VII, Fig. 111. [14] Bibl. No. 273.

vision was contracted to within 8° of the fixation point, the disc was pale, the vessels narrowed, at the extreme periphery two or three typical deposits of pigment could be seen; her left fundus was perfectly normal; for this patient the family history was good, the parents were unrelated and three brothers had normal vision.

Mohr[1] in 1921 describes unilateral retinitis pigmentosa in a patient aged 38 who had only noticed five years previously that he saw badly with his left eye; he had posterior cortical cataract, was night-blind, and the fundus was typical of the disease in all respects in his left eye only; the right eye was absolutely normal. There was no history of syphilis and the Wassermann test was negative; the parents were unrelated and no other case of the disease was known in the family. This patient also was deaf.

It may be of some interest to mention here also the case of unilateral idiopathic night-blindness described by Magnus[2] in 1886.

Many cases might be cited in which though both eyes are affected the conditions of vision and the ophthalmoscopic appearances differ markedly in the two eyes; for example Mooren[3] in 1867 describes a case in which visible pigmentation was present in the left retina only, but the right eye of this patient had a contracted field of vision and showed other signs of degeneracy. There are not however more of these cases than are consistent with our statement that retinitis pigmentosa is only exceptionally asymmetrical in its manifestations.

To conclude this brief statement concerning the signs and symptoms of retinitis pigmentosa we must call attention to the fact that perhaps of all the signs enumerated that of narrowing of the retinal vessels, which we have not discussed in any detail, is the most universally present, and we doubt whether any case has been diagnosed in which this sign is not present to a more or less degree; moreover, it may generally be taken that the severity of the disease is in direct proportion to the lumen of the retinal vessels which gradually decrease in size, or disappear altogether in the case of the smaller vessels, as the disease progresses.

(γ) *The pathology of retinitis pigmentosa.* The subject of signs and symptoms leads us to consider the source of these manifestations of disease, how can their development be explained? In short, what do we know of the pathology of retinitis pigmentosa?

There are in this connection three alternatives to be dealt with: i. Is the disease inflammatory or degenerative in nature? ii. Is the seat of the disease originally in vascular or in nervous structures? iii. Is the disease primarily of the retina, or are the retinal manifestations only secondary to a defect of the choroidal tunic of the eye? The two latter alternatives are to some extent interdependent. Two types of evidence are available for this discussion, the evidence obtained from *post-mortem* examinations of eyes affected by the disease, and experimental evidence. We propose to consider first the evidence we have from *post-mortem* examinations of eyes affected by retinitis pigmentosa.

It is perhaps surprising to find how many anatomical examinations of this disease

[1] Bibl. No. 326. [2] Bibl. No. 143. [3] Bibl. No. 59.

have been made, for it is a condition which in itself leads to no need for excision of the eye during life, and considering the rapidity with which retinal tissues degenerate after death there are difficulties to be overcome in such an event. These very facts make it evident that some other condition is probably present, in addition to retinitis pigmentosa, in all cases upon which anatomical examinations have been made and presumably may in some respects have influenced the microscopic picture. However this may be there is a uniformity in the descriptions of certain characteristic features which is reassuring.

Amongst the many discussions of the pathology of retinitis pigmentosa based in most cases upon anatomical investigations, we would mention those of the following authors: Maes[1], Donders[2], Junge[3], Schweigger[4], Bolling Pope[5], Leber[6], Windsor[7], Landolt[8], Poncet[9], Hosch[10], Lister[11], Gonin[12], Ginsberg[13], Stock[14], Parsons[15], Knape[16], Doyne[17], Suganuma[18], Greeves[19], McKee[20], and Treacher Collins[21]. Of the cases examined by some of these investigators—Leber's patient died of typhus; one of Landolt's cases died from cirrhosis of the liver and kidneys; Poncet's case died of malignant scarlet fever and is of some special interest as being the same case as that described by Hocquard (see Plate II, Fig. 7) which showed during life a very slight development of pigment in the retina; Lister's case is of interest from the fact that the patient had been totally blind for some years before his death at the age of 60 years, and thus the disease is seen in a very advanced stage; the case described by Gonin was unilateral; Ginsberg's patient died from tuberculosis; Stock's case was associated with syphilis; Knape's case had a detached retina and there was a development of pigment on the detached portion of the retina; Suganuma examined an eye which had had to be removed on account of a hypopyon ulcer and so on.

The chief features of the microscopic picture, described very constantly as being present to a more or less degree dependent upon the age of the patient and stage of the disease, in these and other cases are:

i. Disease of the retinal vessels; the walls are thickened, sclerosed and deeply pigmented, the lumen partly or altogether obliterated; the smaller vessels may be reduced to fibrous cords embedded in hypertrophied connective tissue.

ii. Atrophy of the nervous elements of the retina. This condition is the most advanced in the external layers of the retina and increases in intensity from the centre towards the periphery. In a severe case, such as Lister's, the layer of rods and cones was everywhere absent and was replaced by laminated fibrous tissue in which numerous oval nuclei could be seen; outside the central area of this case all traces of the normal structure of the retina were lost.

iii. Hyperplasia of the connective tissue framework of the retina.

[1] Bibl. No. 43. [2] Bibl. No. 36. [3] Bibl. No. 39. [4] Bibl. No. 41. [5] Bibl. No. 46.
[6] Bibl. No. 68. [7] Bibl. No. 70. [8] Bibl. No. 77. [9] Bibl. No. 91.
[10] Bibl. No. 90. [11] Bibl. No. 225. [12] Bibl. No. 222. [13] Bibl. Nos. 221, 247.
[14] Bibl. No. 255. [15] Bibl. No. 252. [16] Bibl. No. 250. [17] Bibl. No. 268.
[18] Bibl. No. 286. [19] Bibl. No. 280. [20] Bibl. No. 293. [21] Bibl. No. 318.

iv. Pigmentation of all the layers of the retina which is especially marked along the course of the blood vessels; the pigment arises from the migration and proliferation of the cells of the pigment epithelium and all that remains of the pigment epithelium as such, in advanced cases is a short row of pigment cells here and there. Wherever pigmentation is found there the rods and cones are absent and the retina is atrophied, but the converse does not hold and it is by no means the case that where the retina is atrophied there migratory deposits of pigment will be found. Hence it may be assumed that pigmentation may follow upon degeneration but does not precede it.

v. Adhesions between the atrophied retina and the choroid.

vi. Choroidal changes. The changes which may be seen in the choroid are degeneration, amounting in some severe cases to total disappearance of the chorio-capillaris, and sclerosis of the large choroidal vessels; but the observations in these respects are by no means constant, they differ markedly from case to case and in some specimens the choroid is reported to be absolutely normal.

The deductions from these observations have varied from time to time; the earlier authors, for example Donders, Landolt, Bolling Pope, Windsor, De Wecker[1] and others believed the lesion to be primarily of a chronic inflammatory nature, they considered that the seat of the lesion was in or around the walls of the retinal vessels and explained the atrophic condition of the retina as the result of a gradually failing blood supply. This view came to be almost entirely discarded as it was recognised that certain distinctive features of inflammation were absent and indeed many observers have definitely stated that they find no trace of inflammation. (See Gonin, McKee, Suganuma, Aubineau[2], etc.) For many years it has been almost unanimously agreed that the disease should be regarded as of an atrophic or degenerative nature, but opinion is by no means agreed as to whether the degenerative process originates in the chorio-capillaris, the layer of the choroid which is entirely responsible for the nutrition of the outer layers of the retina, whether it originates in the nervous elements of the retina itself, manifesting first in the layer of rods and cones, or whether some defect of the retinal vessels precedes the degeneration of the nervous elements of the retina.

For a period the theory that the chorio-capillaris was the most probable source of the retinal disease was held by the majority of inquirers and was consistent with the fact that the external layers of the retina show severe changes at an early stage of the disease; Nettleship held this view, also Gonin and others; and on the whole *post mortem* appearances had justified this conclusion, even though certain observers, of whom we may mention Schweigger, had found that deposits of pigment in the retina could and did occur quite independently of any changes in the choroid. More recently, as material has accumulated, the growth of opinion has been in favour of the defect being regarded as a primary atrophy of retinal elements, and we would advise all interested in the subject to read the very suggestive paper by Treacher Collins from this point of view; he points out that a number of microscopic examinations have been made in which the choroid was entirely normal, and he considers that only by a

[1] Bibl. No. 58. [2] Bibl. No. 219.

destruction of the rods and cones, thereby leaving gaps in the external limiting membrane through which pigment grains, attracted by the action of light, can migrate and so reach the internal layers of the retina, can the mechanism of pigmentation of the retina be explained. No theory yet advanced seems to entirely satisfy all conditions, and repeatedly the situation has arisen of another "beautiful theory killed by a nasty little fact."

Doyne's remarks on the pathology of retinitis pigmentosa are also very interesting; he felt convinced that the condition was not a simple atrophy, and gives many reasons for this statement: he suggests some exudative infiltration of the retina as the source of the defect, and considers the possibility of some abnormal condition in connection with the mechanism by which visual purple is secreted.

To consider now what experimental evidence is available bearing on the subject.

Four investigations along these lines may be mentioned—Wagenmann[1], Berlin[2], Krückmann[3] and Capauner[4]—who cut posterior ciliary arteries in the rabbit, guinea-pig or frog, leaving the retinal vessels intact. This operation was followed by atrophy of the corresponding part of the choroid and by degeneration and pigmentation of the outer layers of the retina over that part of the choroid which had been supplied by the cut vessels; Capauner observed changes in the case of the rabbit three days after the operation had been performed. On cutting only the retinal vessels, leaving the posterior ciliary vessels intact, no degeneration or pigmentation of the outer retinal layers took place.

These experiments demonstrate the dependence of the outer retinal layers upon the choroidal circulation for their nutrition, they further demonstrate that pigmentation of the retina can be produced by interference with the choroidal circulation in certain animals, but they do not prove that retinitis pigmentosa in man is produced primarily by a defect in the choroidal blood supply.

Pigmentation of the retina with disturbances of the corresponding region of the chorio-capillaris has also been observed to develop as a result of optico-ciliary neurectomy in man[5].

The little that we know of the determining factor in the production of the early and marked symptom of night-blindness does not contribute much to our knowledge of the pathology of retinitis pigmentosa, yet it is not without interest in this connection. Schultze[6] first suggested that the rods of the retina were concerned with the sense of light and space, and the cones with colour vision; Parinaud[7] then developed the theory that night-blindness was due to a change in the visual purple and in the rods. The tradition that hepatic organo-therapy was of specific value in certain cases of night-blindness, combined with the observed reaction between bile pigment and visual purple in the test-tube, appeared to support this theory. Hess[8], however, in an extremely interesting paper, strongly opposes this view and pronounces that night-blindness is not due to a lesion which is confined to the rods; further, Hess broke down the popular

[1] Bibl. No. 164. [2] Bibl. No. 71. [3] Bibl. No. 204. [4] Bibl. No. 173.
[5] See Studer, Bibl. No. 236, and Treacher Collins, Bibl. No. 318.
[6] Bibl. Nos. 57, 73. [7] Bibl. No. 130. [8] Bibl. No. 269.

tradition that hens were night-blind and was unable to bring about night-blindness in hens by means of artificial icterus produced by ligature of the bile duct; he found also that such artificial icterus in the rabbit left the visual purple unchanged.

Though the source of night-blindness may be regarded still as somewhat obscure, it is of significance that on examination of the retina in animals it is found that rods are more numerous in cave dwelling animals than in those living in the open and that in night birds rods preponderate. The retina of the lizard and snake are said to have cones only.

Thus the knowledge which we have of the pathology of retinitis pigmentosa tends to emphasise the complex nature of the condition, and perhaps suggests that the group of cases diagnosed as such may not be really homogeneous, even though there is great unanimity in the clinical picture of the cases described and in the slow progressive nature of the disease terminating inevitably in blindness provided the patient lives long enough. Experience is invariable also in reporting the result of treatment to be in all cases unavailing, if we except the improvement after trephining reported by Mayou[1] and by Kirkpatrick[2] and some temporary improvement noted occasionally after use of the constant current.

(δ) *Diseases and defects found in association with retinitis pigmentosa.* The significance of the presence (or absence) of associated defects in all cases of inheritable disease is only gradually becoming recognised, and from this point of view the Usher series of pedigrees is of great value, for the author has systematically enquired for information on this point from his patients and their relatives. It is only permissible to make very rough estimations of the frequency and character of associated defects from our material as a whole, because the majority of authors make no statement on the subject, and we feel sure in many cases have not investigated the facts. We have heard repeatedly from Karl Pearson and other writers of the pedigrees of general degeneracy in which an inherent mental instability expresses itself in a variety of ways in the different members of the stock—thus one member may be insane, another irritable and passionate, another a somnambulist, an alcoholic, a suicide and so on—the manifestations of the defect are varied, but we may take it that the tissue or cells in which they originate are the same, and we have no reason whatever to expect that in such a pedigree certain other inheritable defects, say haemophilia, will occur. May we expect to find cases of retinitis pigmentosa noted in such a pedigree?

Again to turn to pedigrees of more definite structural developmental defects such as hare-lip and cleft palate; we are at once struck by the number and character of the associated defects[3] which here again are markedly restricted to structural defects in the development of limbs or organs or parts of the body, produced in many cases we know by amniotic adhesions and in other cases perhaps by some other, not necessarily

[1] Bibl. Nos. 305, 309.

[2] Colonel Kirkpatrick trephined one eye for a man suffering from retinitis pigmentosa who was so much benefited that he returned two years later asking for the operation to be performed on the second eye.

[3] For an analysed table of deformities reported in association with hare-lip and cleft palate see *Treasury of Human Inheritance*, Vol. I., pp. 93—107.

mechanical, arrest or interference with the normal development of normal tissues into their characteristic forms. We should expect in such pedigrees to find such eye defects occurring as microphthalmos, anophthalmos, coloboma iridis and others; we should not expect to find more than a chance case of haemophilia. Should we expect to find retinitis pigmentosa?

In the case of haemophilia there appear to be no characteristically associated inheritable defects, and we are sure that if such existed they would not fail to be indicated in the memorable section in the first volume of this publication by Bulloch and Fildes. We may however refer here to the very interesting suggestion thrown out by Voorhoeve[1] as a possible explanation of a pedigree in which the frequently related blue sclerotics, brittle bones and easily dislocated joints are seen associated with haemophilia and other defects; he considers the possibility of an inherent defect in the mesoblastic tissue showing itself in a variety of structures developed from it. The theory is ingenious and worth bearing in mind, though so far as the association with haemophilia is concerned it seems unlikely that a true haemophilic who repeatedly broke his bones and dislocated his joints would live to talk about it.

The extremely illuminating experimental work of Stockard[2] on the production of structural defects by varying the developmental rate at certain critical periods is of interest in this connection. He is able to produce a great variety of associated defects, the character of which are in direct relation to the particular moment in the development of the organism at which his interference (which concerns itself with temperature and oxygen supply) is applied. He comments on the frequency and variety of defects in the eyes thus obtained. The paper is teeming with interesting suggestions, but it is only possible here to quote from it a few passages to indicate the possible application of the author's observations to our problems. Thus on pp. 233—4 "When the optic vesicle does not grow out from the brain at a definite developmental moment it is subsequently unable to grow out and develop normally or it may be unable to grow out at all. I have definitely inhibited development during this period in a large number of experiments and have either suppressed or modified the development of the eye. It may be concluded that such an organ as the eye is not only derived from a definitely located primordia, but must also be derived during a limited moment of development." And again on p. 243 "The periods of arrest necessary to induce the eye and the brain modifications are so close together or so nearly the same, that one generally finds combinations and mixtures of the defects among the same experimental groups of embryos. Arrests at the earlier moment give a majority of eye conditions, many without brain involvements, while arrests at the slightly later stage give a majority of brain modifications, a few with fairly well-formed eyes. The individual variations in developmental moments among the embryos of a group also tend to contaminate the results and give mixtures of the two classes of deformities."

From the nature of the case the defects obtained experimentally must be of a rather gross character, but it is evident that finer shades of interference at critical moments for certain organs might well produce such defects as we are familiar with

[1] Bibl. No. 315. [2] Bibl. No. 328.

in human development. Is it then conceivably possible that the origin of the defect in the case of some of our inheritable diseases is in an inherent tendency to delay or antedate the critical moment of development for certain structures?

Thus it is of considerable interest to examine what other defects are found in association with retinitis pigmentosa and to enquire whether they throw any light on the condition with which we are dealing.

The first point which strikes one on looking through the material is the number of pedigrees in which no associated defects have been noted, and we draw especial attention in this connection to the extensive pedigree worked out by Nettleship (Plate I, Fig. 1B) in which no fewer than 19 sibships contain affected members, the total number of affected individuals in the stock numbering 39; the author made a special note of the fact that all members of this stock were free from any other defect. Other examples of pedigrees in which retinitis pigmentosa is extremely prevalent and is not apparently associated with any other defect may be seen in Fig. 3 and Fig. 5. If we glance at the Usher series in which we know this factor has been considered throughout we find that on the whole the view is supported that a considerable amount of retinitis pigmentosa occurs in sibships which are free from all other inheritable defect. On our whole series, omitting certain very atypical or doubtful pedigrees, we find 656 individuals (out of a total of 919), taken from 329 sibships, affected with retinitis pigmentosa without a single case of associated disease *noted* in them, or in their normal siblings so far as information concerning them is given but too frequently all statement of the siblings is omitted or is very incomplete, and we feel assured that in a large number of cases associated defects in the affected individual have not been inquired for and that with more complete information the numbers given above would be perhaps markedly reduced.

When we consider what associated defects have been observed the only two conditions which are found to occur with any marked frequency in association with retinitis pigmentosa are deafness, often deaf-mutism, and idiocy or some type of mental defect or defect of the central nervous system, and of these the question of associated deafness is of rather special interest from the fact that the observed high degree of association is concerned rather with retinitis pigmentosa in the individual pedigrees in which it occurs than with retinitis pigmentosa as a whole.

There are in our material 96 cases of retinitis pigmentosa associated with deaf-mutism or deafness out of a total of 919 cases; that is to say, on the whole series 10·4 % of our cases have these two defects.

If now we consider only those pedigrees in which deafness occurs as a complication in at least one case of retinitis pigmentosa we find that for this series of pedigrees no less than 74·3 % of our cases are either deaf-mutes, or are deaf. And if we further examine the Usher pedigrees in which we know that the presence of deafness was definitely inquired for we find that if we take only the pedigrees in which one case of deafness occurs as an associated defect, 100 % of the cases of retinitis pigmentosa from such pedigrees are so associated. Further, we notice that the degree of deafness, or at any rate its time of onset, appears to be more or less constant within the stocks in

which it occurs, for where mutism is also present, which we take it means that deafness was complete before the age of 7 years, then mutism is present in all cases within the stock in which deafness occurs. The case of Baumeister already referred to, in which the combined defects were present in the left eye and ear only, is of special significance in this connection as indicating the intimate nature of the association. When we consider whether deafness may occur in the members of an affected sibship who are free from retinitis pigmentosa we find seven such cases reported, see Figs. 83, 95, 110, 201, 213, 239 and 246, but in some of these the information was very scanty and the eyes of the otherwise normal deaf members had apparently not been examined. We think we may fairly conclude that where deafness occurs in relation with retinitis pigmentosa in any member of a stock this defect will almost invariably be associated with any case of retinitis pigmentosa that occurs in the same sibship and will tend to be associated also with cases which occur in other sibships of the stock.

An anatomical examination of the ear from a case of deafness associated with retinitis pigmentosa would be of great interest and would possibly throw much light on the question of the etiology of the disease; so far as we have been able to discover no such examination has yet been made.

The double defect of deaf-mutism and retinitis pigmentosa must undoubtedly tend to be a bar to marriage but it is a little surprising to find that omitting the extremely doubtful case of Oakley's (see Fig. 86) we have only one case of associated deaf-mutism for which the parents were not both normal; this occurs in a case described by Chaillous (see Fig. 177) in which a man with retinitis pigmentosa married a normal unrelated woman and had one child, a deaf-mute son with retinitis pigmentosa. There are a few cases on record in which persons with this combination of defects have married and were reported to have normal children, and one case, described by Nettleship (see Fig. 87) in which a woman so afflicted married an unrelated normal man and had two children, a normal son and a daughter with retinitis pigmentosa. There is a markedly higher percentage of consanguineous marriages amongst the parents of these doubly afflicted persons than exists for the parents of our general population of affected sibships; we shall return to this point again later when discussing the influence of consanguinity on the production of retinitis pigmentosa.

If we take now the group of associated defects comprising idiocy, epilepsy, and any form of mental defect or defect of the central nervous system we find a rather similar state of affairs to a much less marked degree; our information concerning such a group is probably even more incomplete than in the case of deafness but such positive information as we have gives us 37 cases in which one or more defect of this group is associated with retinitis pigmentosa. If then we consider the affected members of our whole series this gives us a percentage of 4·0 cases in which this combination of defects occur; if on the other hand we consider those pedigrees only in which at least one affected individual has a further associated defect from this group we find for the affected members of these pedigrees a percentage of 34·6 cases in which this combination of defects occur. The impression given by a cursory examination of the occurrence of defects of this group in the pedigrees, is that they tend to occur more in the normal

members of the affected sibships and to be to a far less degree confined to the affected members or even to the affected sibships than is the case with deafness.

It is not possible on the evidence available to give any opinion as to whether the occurrence of defects of this group in the normal members of the pedigrees indicate or do not indicate a degeneracy latent in the stocks of which the retinitis pigmentosa is only another manifestation.

A rarely associated defect which has received an amount of reference out of all proportion to the frequency with which it occurs is polydactylism, but the relationship is of interest as indicating that the link when it does occur is of great intimacy as in the case of deafness. Thus we have in our pedigrees nine cases of polydactylism associated with retinitis pigmentosa as well as two cases of polydactylism, in the siblings of one patient, who died before the condition of the eyes was known, in five small pedigrees[1]; two cases of retinitis pigmentosa in these stocks were not polydactylous. Further similar histories of this combination of defects in isolated cases are given by Herrlinger[2], Stör[3], and others.

The only other disease or defect which occurs in association with retinitis pigmentosa with sufficient frequency to be of any interest here is glaucoma, the combination is relatively rare but such cases as we have been able to collect in which it occurs may be seen in the description of Figs. 244, 245, 246, 247, 248, 249, 250 and 251, where eleven cases of glaucoma are described in patients suffering from retinitis pigmentosa and two cases of glaucoma in the siblings of such patients.

We think we may fairly conclude that retinitis pigmentosa occurs largely as a single affliction unaccompanied by other disability; the fact that this is the position in some of our fully worked out pedigrees in which the disease occurs with marked prevalence through several generations perhaps explains the existence of such pedigrees, and it may well be that stocks in which cases occur in association with further defects tend rapidly to die out.

We may further conclude that wherever deafness is found in association with retinitis pigmentosa the link is a very close one and the two disabilities may with a high degree of probability be expected to occur inseparably within the stock.

It is of interest, in consideration of the theory that atrophy of the chorio-capillaris, the exclusive source of the blood supply to the external layers of the retina, is primarily responsible for the disease, to search for other defects of the vascular system within such stocks but we can find no widespread or significant evidence of such an association. Nettleship has collected all available cases in which the onset of the disease had been attributed to severe haemorrhage and Usher made frequent enquiries for such a history, but such cases are very rare and may have quite other explanations; there is no evidence of early or severe arterio-sclerosis in these stocks, if we omit Bordley's[4] entirely anomalous case (see Fig. 6); there are isolated and rare cases described of senile gangrene, or Raynaud's disease, or cold hands and feet or chilblains all of which are perhaps defects of the vaso-motor system due to hyperactivity of the sympathetic

[1] See Figs. 24, 96, 114, 205, 237. [2] Bibl. No. 203, Case 14. [3] Bibl. No. 52. [4] Bibl. No. 245.

constrictor nerves rather than primarily vascular defects. And further there is no evidence of any associated heart disease apart from the again anomalous case of Dor[1] (see Fig. 256).

Certain cases have occurred which have led to the suggestion that acute illness or infections or nervous shocks may determine the onset of the disease which would have otherwise remained latent, or may conspicuously produce an exacerbation of symptoms and modify its course. The story described by Nettleship[2] (see Fig. 215) in which the disease followed scarlet fever in five siblings is the most significant of these cases; other interesting histories by the same author writing on *Some of the exciting causes of retinitis pigmentosa* bear on this point. For further cases amongst our series which have been attributed to maternal shock, or fright, or to some acute illness or severe haemorrhage, or at any rate were associated with one or other of these conditions, see *Description of Pedigree Plates*, Figs. 10, 17, 79, 99, 140, 148, 151, 163, 168, 172, 184, 215, 217, 235, 247. No doubt many of these cases are merely coincidences for the average patient with his relatives likes to be able to attribute any disabilities which occur to a definite cause; an example of this may be seen in Fig. 173 where there was a difference of opinion as to whether retinitis pigmentosa in two siblings was the result of their snowballing or was due to slaps on their heads administered by a drunken father. Nettleship was of the opinion that there were enough of these associations on record to warrant a careful investigation with regard to their possible significance on the part of subsequent investigators; he suggests the possibility that such cases might be an indication of the existence in certain stocks of an hereditary tendency to disease of small arteries, say of the choroid, which may under favourable conditions remain latent through life but which might become patent if the resistance of the individual be lowered by toxic illness or by loss of blood.

We are of the opinion that Usher's investigation does not give much support to the view that there may be any significance in these associations.

(ϵ) *Racial and geographical distribution of retinitis pigmentosa.* It is not possible to give any definite statement as to the relative frequency of retinitis pigmentosa in different races or countries; the lack of published accounts of the disease in any particular country may by no means be taken to indicate the rarity of the disease in the corresponding race. We may probably take it that the condition occurs more or less uniformly in the countries of Europe. In America there is some indication that perhaps the disease may be less prevalent; at a meeting of an American Ophthalmological Society, reported in the *Ophthalmic Record* for 1911, p. 267, Saxl said "cases of retinitis pigmentosa do not seem to be frequent in this country"; Owen agreed that it was an uncommon condition, Loeb had seen two cases in 250 patients since his hospital clinic had started. We can attach little importance to these vague statements but, added to the fact that we have relatively few American cases in our collection, they suggest that further information on the subject would be of interest. We think it may possibly be accepted that the condition is rare in the coloured races of America; omitting Bordley's extremely interesting though anomalous case in the negro we can find very

[1] Bibl. No. 267. [2] Bibl. No. 251, pp. 159–61. [3] Bibl. No. 245, Fig. 6.

little evidence of the disease amongst these races, it must however be borne in mind that races differ markedly in the way they tolerate an affliction, to some, illness when it comes, particularly if it be of a slow progressive nature, tends to be borne in silence and to be accepted as the hand of fate; such cases are not taken to the hospital to be treated nor do accounts of them reach the medical press. Ayres[1] writing in America in 1892 describes retinitis pigmentosa in a negro and states that it is the only case he has ever seen in a coloured race; Jones[2] makes a similar statement on describing the condition in a mulatto girl.

Roy[3], writing on the African negro, states that they see very well at night and that he has noticed this characteristic also in the Indo-Chinese, Malays, Redskins and even in Hindoos; we should like to see the result of some definite test for light sense in these races. Junker writing in 1866 says that he has never seen a negro affected with night-blindness[4].

The case of China also is of interest for it has been repeatedly stated that night-blindness is more common in China than in Europe on the basis, we believe, of a report to this effect taken from Jesuitical literature and published by Bergen and Weise[5] in 1754. We hope to be able to obtain some information on the prevalence of retinitis pigmentosa in China before going to press. With regard to India, Kirkpatrick[6] writes "Retinitis pigmentosa is extraordinarily common in the east and accounts for 21 °/₀ of all diseases of the choroid and retina; a history of consanguinity can be obtained in 87 °/₀ of the cases"; he states further that the pigmentary and atrophic changes found are probably more extreme than those met with in Europe and that the whole of the fundus is involved at a comparatively early date. Kirkpatrick's report is very interesting but we must remember that the Indian patient may have to save up for years in order to have money enough to take the journey to the nearest hospital, and that the medical officer there is thus likely to see only the severe cases. Well authenticated retinitis pigmentosa has we believe only twice been recorded in animals; as early as 1864 van Biervliet and von Rooy[7] observed it in horses and more recently Magnusson[8] has reported an exceedingly interesting pedigree of the condition in dogs[9]; the consanguinity in the matings for this experiment was much closer than anything that can ever occur in man, thus of the three affected sibships one was the offspring of half siblings, one the offspring of siblings and the third was the offspring of an affected mother mated with her grandfather who was the father of both her parents. Night-blindness was first noticed in these dogs at about the age of 6 months and one dog became completely blind in four years; a *post-mortem* examination in one case showed a condition very similar to that described for man.

(ζ) *Statistical Observations. Consanguinity.* It has been the custom for this publication to collect material for the student of heredity and to give some general description of the condition which is to be investigated. The subsequent analysis of

[1] Bibl. No. 169. [2] Bibl. No. 314. [3] Bibl. No. 320.

[4] Bruns saw three cases of retinitis pigmentosa in 1113 negro patients at an eye clinic in two years. Bibl. No. 185. [5] Bibl. No. 20. [6] In Elliot's book, Bibl. No. 322, p. 390.

[7] Bibl. No. 48. [8] Bibl. No. 276. [9] Fig. 185.

the material must be a heavy task and before any attempt at a numerical estimation of the intensity of inheritance be attempted a critical survey of each pedigree will need to be made. Pedigrees in which single cases alone occur should be omitted; we do not wish to underestimate the value of such pedigrees which may throw much light on the nature of the affection when all the associated defects and the characteristics of the stock are noted as fully as in Usher's cases, but in them the defect is not an inherited one and may well be secondary to a toxaemia or to some defect of other organs in the individuals, indeed from what we know of the range of variability in all organs in the general population we should expect that in certain exceptional cases an extreme variation from the normal in some respect may occur in the development of any tissue which may well be incompatible with the needs of the functioning organ developed from it. Such isolated cases occur in every inheritable disease as we know from albinism, cataract, phthisis and diabetes to give only a few examples, they in no wise weaken the importance and clinical significance of the hereditary nature of such diseases in certain stocks, nor to give another example can any of us regard the isolated occurrence of genius as any bar to our acceptance of the view that ability is markedly inherited.

Again, before the analysis of the material as a whole can be considered the age of onset in each pedigree will need to be examined, and in cases for which the 'normal' members were below the age at which the disease tends to occur the whole sibship should be rejected until it is known from an examination of the entire population in what proportion these undetermined cases should be divided amongst the affected and unaffected; sibships in which members died young or in infancy should be similarly treated. May we assume that pedigrees in which the disease is always congenital are truly homogeneous with those in which the disease always developed at say about the age of 17 years?

We must further point out that there appears to be some very fundamental difference between such pedigrees as for example Figs. 1B, 3 and 5 in which the defect is very prevalent and is invariably transmitted by affected individuals the normal members of these stocks bearing normal offspring only in every case, and pedigrees such as Figs. 50, 57, 156, 212 and 225 in which the disease may miss one generation or more and is transmitted through normal members of affected sibships. We cannot in the present state of our knowledge feel assured that a material containing pedigrees of a defect showing this variety in its mode of transmission is homogeneous. If we attempt to keep these two groups separate in which group are we to place the many single sibships given to us in which one parent was known to be affected?

Thus when we come to consider the possibility of an exact analysis we realise painfully our weak points and the depths of ignorance yet to be overcome before we can expect the statistician to use his tools and give us facts that we can insist upon; nevertheless we are satisfied that the collection as it stands is of value as illustrating the varied manifestations and complex nature of retinitis pigmentosa and the danger of pronouncing upon the condition in the individual met with in the out-patient department from a knowledge of a few pedigrees only and without fully investigating the family history of the individual.

With this caution and repeating that we cannot, in the present state of our knowledge, insist upon the significance of the figures given, we offer some suggestions based on the material as a whole, with a few doubtful or anomalous cases omitted, relating to (i) the influence of consanguinity in the parents on the production of retinitis pigmentosa in the offspring; (ii) the proportion in which the sexes are affected and transmit the disease; (iii) the proportions in which the offspring of affected and of non-affected parents tend to be affected; (iv) the average size of families of affected and unaffected parentage.

Considering first the affected individual apart from the sibship and examining into the sex and parentage we find a very significant preponderance of males; where the sex is given we have 454 males and 363 females affected, and 373 males and 362 females unaffected. Thus $55{\cdot}6 \pm 1{\cdot}2\,\%$ of the affected population are males, or we have an excess of 11 males in every hundred of such a population; this sexual incidence tends to support statements made repeatedly by other workers. In a large percentage of cases both parents of an affected individual are normal and it is not possible from the pedigree to say through which of them the disease has been transmitted but in 400 cases we have information on this point and it appears that:

75 affected mothers have handed on the disease to 183 children. 56 affected fathers have handed on the disease to 96 children. 36 normal mothers have transmitted the disease to 76 children. 25 normal fathers have transmitted the disease to 45 children. 30 affected mothers and 44 affected fathers have only normal offspring. These figures we think may be taken to suggest that though the male tends to become affected more readily than the female, he is less liable to transmit the disease to his offspring, for on the average the father only transmits the disease to 1·7 of his children whilst the mother transmits it to 2·3 of her children, and further a considerably higher percentage of affected fathers do not transmit the disease at all. This point will be referred to again later.

Consanguinity in the parentage has been urged again and again as one of the most important etiological factors in the production of retinitis pigmentosa and indeed when we come to examine our affected population with regard to this point we find that $27{\cdot}2\,\%$ of the individuals are the offspring of consanguineous marriages, or that $25{\cdot}8\,\%$ of the affected sibships are the result of consanguineous parentage; these figures agree closely with the values given for albinism by Professor Pearson who found that $29\,\%$ of albinos of all classes were the result of consanguineous marriage. If we limit our affected population to cases of retinitis pigmentosa from sibships in which at least one case of deafness occurs we find that $40{\cdot}2\,\%$ of such selected individuals have a consanguineous parentage, or if we limit our population to cases from sibships in which at least one case of mental defect, idiocy or defect of the central nervous system occurs we find that $37{\cdot}7\,\%$ of such affected individuals have a consanguineous parentage. Thus with an increase in the percentage of consanguinity there appears to be an increase in the defect resulting.

On considering the amount of consanguinity in marriage in the general population Miss Elderton[1] concluded from her analysis of all available material that "it seems

[1] '*On the marriage of first cousins*,' pp. 20—24. *Eugenics Laboratory Lecture Series.* London 1911.

unlikely that the percentage of first cousin marriages can be greater than 3 among all classes in England." The factor, as demonstrated on material collected in the Galton laboratory and elsewhere, varies from class to class being greater for the professional and upper classes than for the working class population. Clearly then the numbers given above are of great significance; we will now examine what proportion of the offspring are affected when there is and when there is not a history of consanguineous marriage.

Omitting all isolated cases and taking only those sibships for which complete information of the number of affected and normal individuals is given, dividing also the numbers who died young or were at the time of observation below the age at which the disease usually appeared in that family in the proportion of the affected and normal individuals found for completed sibships in which such cases do not occur, we get the following table:

Percentage of Offspring Affected

	No. of Sibships	Average size of Family	Percentage
No Consanguinity			
Mother Normal, Father Normal ...	98	6·3	15·6 ± 1·4
Mother Normal, Father Affected ...	45	4·5	25·6 ± 2·1
Mother Affected, Father Normal ...	67	4·8	17·5 ± 1·9
Consanguinity			
Mother Normal, Father Normal ...	54	6·8	44·7 ± 1·8
Mother Normal, Father Affected ...	13	3·2	38·1 ± 5·1
Mother Affected, Father Normal ...	9	4·2	[31·6 ± 5·1]

Now the numbers given for cases in which both parents were normal are not comparable with those for which one parent was affected, for the latter cases include sibships in which there were no affected offspring and when both parents were normal it was not possible to detect those cases in which one or both of them had the disease latent but produced only normal offspring, but the table appears to support our suggestion that the female more readily transmits the disease to her offspring than does the male and further although consanguinity in parentage undoubtedly produces an increase in the number of affected sibships in the population, only in the one series of cases for which the mother is normal and the father is affected do we possibly find evidence of an increased proportion of affected members within the sibship as we pass from the non-consanguineous to the consanguineous groups; we may perhaps explain this case on the assumption that the affected father does not readily transmit the disease but his wife, if chosen from the same stock, tends to increase the proportion of his affected offspring. We regret that the number of sibships for the consanguineous group is here so small that we are not able to insist upon the percentage given for it.

If we now for comparative purposes consider only sibships in which affected members

occur and take the two groups in which neither parent or one parent is affected we find:

Percentage of Offspring Affected

	No Consanguinity		Consanguinity	
	No. of Sibships	Percentage	No. of Sibships	Percentage
Both parents normal ...	98	45·6 ± 1·4	54	44·7 ± 1·8
One parent affected ...	74	53·6 ± 1·7	16	50·0 ± 4·5

This condition of things has not been found for other diseases which have been investigated. Thus Fay[1] in discussing deaf-mutism in America states that when one or both parents are affected and consanguineous 30 °/₀ of their offspring are affected, but when there is no consanguinity only 8 °/₀ of their children are deaf-mutes. Professor Pearson has found for albinism that when one parent is albinotic and there is consanguinity 32 °/₀ of the offspring are albinotic whilst only 14 °/₀ are affected when there is no consanguinity; when neither parent is albinotic but consanguinity is present 40 °/₀ of the offspring are affected, when there is no consanguinity the number is reduced to 34 °/₀.

(η) *Diseases allied to Retinitis Pigmentosa.*

Chorio-retinitis. We have included in our series only two pedigrees[2] described by the authors under this title, which are of some interest and appear to be undoubtedly allied to retinitis pigmentosa, but in which choroidal changes are a marked feature of the ophthalmoscopic picture. We have found some difficulty in deciding what should and what should not be included here for the group is ill-defined and a graduated series of cases might be arranged in which changes are present in both tunics, at one end of the scale choroidal changes predominating but becoming less marked and the retinal changes relatively more marked as we go down the scale until we find the typical picture of retinitis pigmentosa.

Retinitis punctata albescens. This condition, named by Mooren[3] in 1882, is of great rarity and the number of cases on record are too few to be of any interest from the point of view of its heredity, but it is unmistakably allied to retinitis pigmentosa and when an anatomical examination of the condition has been made may help to throw some light on the etiology of that disease. The defect is found in several members of a sibship, which is the more significant in the light of its extreme rarity, and affects both sexes; it has never been observed in more than one generation in any family but is noted relatively frequently in pedigrees in which retinitis pigmentosa has occurred. The chief characteristic of retinitis punctata albescens is the presence of white dots in the fundus, but there are other conditions in which light spots are seen in the fundus such as those due to colloid bodies, due to honeycomb choroiditis or even due to Gunn's

[1] Fay, E. A. *An Inquiry into the Marriages of the Deaf in America*, p. 108. Washington 1898.

[2] See Fig. 256, Dor's Case, and Fig. 257, Pöllot's Case.

[3] Bibl. No. 114, p. 217.

crick dots, so that care is necessary in making the diagnosis, though Nettleship says the condition is quite characteristic and once seen is unmistakable; the dots are deep to the retinal vessels which invariably pass in front of them. To quote from Nettleship[1] "several conditions have received this title; the name should be restricted to the cases, apparently quite rare, in which the fundus is sown pretty evenly with innumerable discrete white dots entirely free from pigment, dull or dead like white paint, affecting the central region as well as or even more than the periphery, apparently dating from birth or early life and remaining so far as is at present known stationary; the dots are always small and may be invisible by the indirect method." Nettleship kept certain of his cases under observation over a long period of years, in some cases he notes no change in the fundus but in one case[2] he observed the entire disappearance of the white dots with the development of several pigmentary deposits typical of retinitis pigmentosa; in the sister to this case who was similarly affected, he observed a diminution in the number of the white dots. One other such observation has been reported by Gradle[3] who noted *retinitis punctata albescens* in a woman aged 29 associated with pigmentation of the retinal periphery; eight years later the white spots had disappeared.

Other characteristics of the condition are night-blindness which is almost invariably present from an early age; the retinal arteries may be slightly narrowed but are never markedly so; the discs may be a little pale, or may be normal; the fields are usually contracted in a dim light and may be so in a good light; and finally the visual acuity in a good light may be full or may be markedly diminished.

Sixteen small pedigrees in which *retinitis punctata albescens* occurs are given in Figs. 269—284 of our series and of these, the cases described by Spengler[4] and Diem[5] are atypical in the absence of night-blindness, the case described by Nettleship and Collins[6] is atypical in the late onset of night-blindness. Other references to the condition are given in the Bibliography[7]. The case described by Cohen[8] is of interest as it is the only case reported of *retinitis punctata albescens* in more than one sibling in a coloured race, but the condition described is not entirely consistent with Nettleship's definition given above. The disease certainly occurs in India for Kirkpatrick has noted one and possibly two cases amongst the 327 cases of disease of the choroid or retina seen at Madras during the years 1914—1918. We believe that several cases have recently been reported in a Japanese ophthalmological journal but we have been unsuccessful in our attempts to procure it.

Choroideremia. This may almost certainly be described as a developmental defect in the complete form of which the choroid is entirely absent; the defect in such cases appears to have taken place at a very early date before the first signs of the development of the chorio-capillaris at the macula region has taken place, but in most of the cases seen there is described a white or greyish-white fundus with a small plexus of capillary vessels at the macula region giving a more or less normal red reflex at this

[1] Bibl. No. 251, pp. 377—8. [2] See Fig. 274, *Description of Pedigree Plates*, also Bibl. 299.
[3] Bibl. No. 242. [4] Fig. 272. [5] Fig. 280. [6] Fig. 275.
[7] Bibl. Nos. 121, 187, 210, 234, 316, 325. [8] Fig. 282.

Fig. i

Fig. ii

point, in some cases also patches of normal red fundus at the outermost periphery have been noted. Such cases possibly indicate an arrest in development at a slightly later date. The beautiful coloured plate[1] which we owe to Usher admirably illustrates all the features of the condition.

Choroideremia is very rare and no anatomical examination of the condition has been made, but the occurrence of the anomaly in Smith and Usher's pedigree[2] in a boy whose mother and sister had retinitis pigmentosa and whose father had congenital stationary night-blindness, also its occurrence with atypical retinitis pigmentosa and with possibly gyrate atrophy of the choroid and retina in Zorn's pedigree[3] suggest that there is some common factor in the etiology of these conditions. Zorn's case is of special interest as the patient was married and had seven children of whom six were normal and one had possibly *retinitis pigmentosa sine pigmento.*

The defect has been noted in two brothers by Koenig[4], Alexander[5] and Mauthner[6]; Oguchi[7] and others have described cases whose siblings or other relatives were reported to be night-blind but had not been examined. It is perhaps worth drawing attention to the fact that all undoubted cases so far described have been in males. Other characteristics of the condition are night-blindness which the patient usually reports to have been present since his earliest recollections; the visual fields are contracted; the central vision in a good light may be full or may be defective; the discs and retinal vessels may be normal but are not invariably so; the condition appears to be either stationary or to progress very slowly. Eleven small pedigrees showing this condition in one or more of the members are given below in Figs. 119, 253, 255, 258—263, 286 and 287[8].

Gyrate atrophy of the choroid and retina. This condition which is of extreme rarity was named by Fuchs in [illegible] distinguishing characteristic consists in the appearance of the fundus which in its typical form gave rise to the name of the defect and which shows an irregular zone of choroidal atrophy surrounding the disc, followed by a zone of normal choroid which is again surrounded by a zone of atrophy, the peripheral choroid being normal; the margins of the atrophic zones may be pigmented and are lobulated to form bays which encroach upon the areas of normal choroid. The condition varies much from case to case, and of the three sisters, patients of Fuchs and described by Cutler[10], one of them showed such marked divergence from the type that had the condition not been seen in her sisters she would assuredly not have been placed in this group. Other characteristics of the defect are night-blindness, defective vision, contraction of visual fields and discs and retinal vessels which may be normal or may be as found in retinitis pigmentosa.

The condition has been noted in siblings of either sex, and in one small pedigree[11] a father and son have a defect placed by Nettleship in this group though it is in some respects atypical.

[1] See Plate B. [2] Fig. 119. [3] Fig. 262. [4] Fig. 260.
[5] Fig. 255. [6] Fig. 287. [7] Figs. 258, 259, 261.
[8] See also Bibl. Nos. 134, 170, 237, 296, 319 for descriptions of further isolated cases.
[9] Bibl. No. 187. [10] Fig. 268. [11] Fig. 268.

Fig. i. Choroiditis in a male aged 24 years. Ophthalmoscopic appearance of the right *fundus oculi*, whole *fundus* × *circa* 5.

Right Fundus

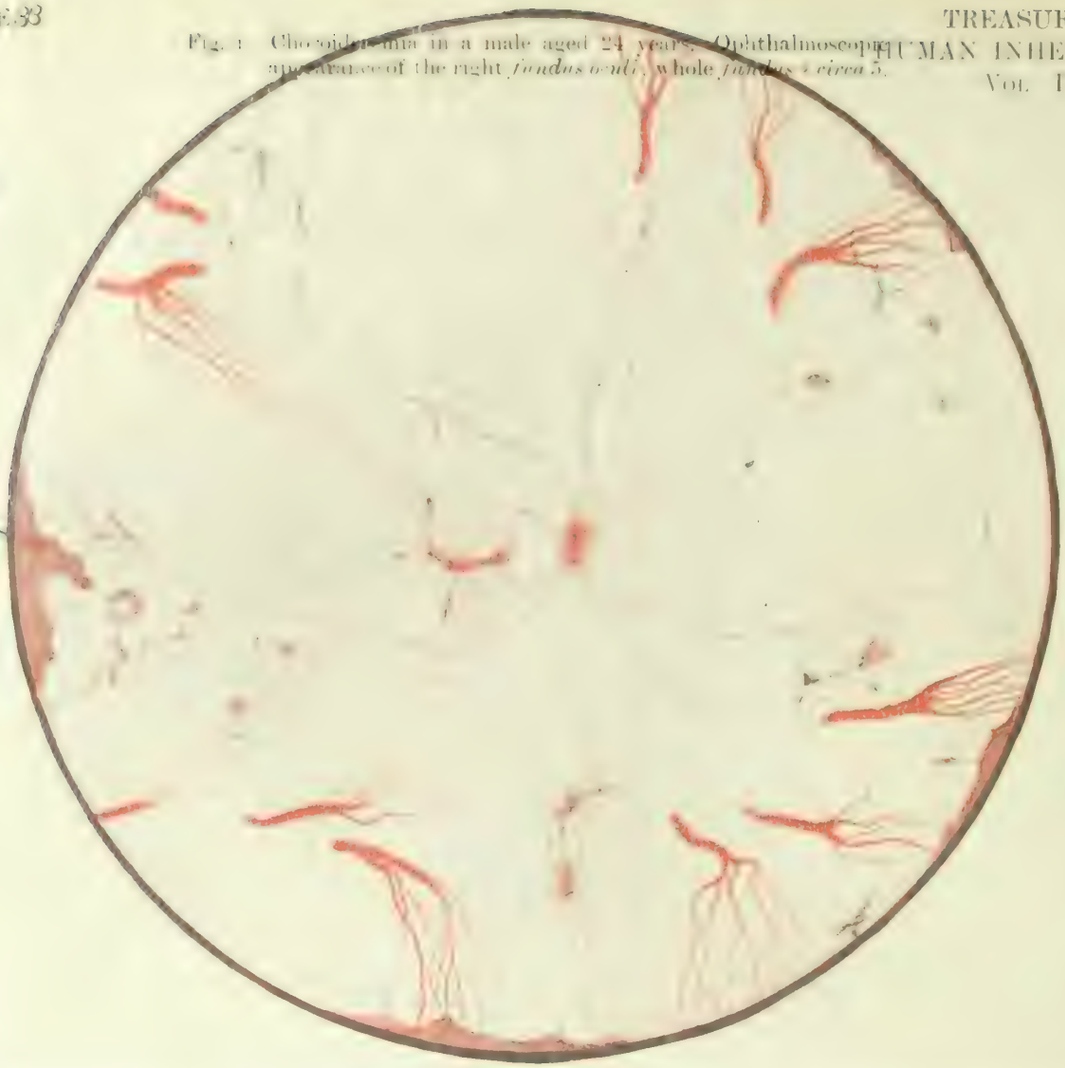

Nasal

Fig. ii

Fig. ii. Ophthalmoscopic appearance of the left *fundus oculi* of same case; part of *fundus* only × *circa* 8.

Left Fundus

Temporal

point, in some cases also patches of normal red fundus at the outermost periphery have been noted. Such cases possibly indicate an arrest in development at a slightly later date. The beautiful coloured plate[1] which we owe to Usher admirably illustrates all the features of the condition.

Choroideremia is very rare and no anatomical examination of the condition has been made, but the occurrence of the anomaly in Smith and Usher's pedigree[2] in a boy whose mother and sister had retinitis pigmentosa and whose father had congenital stationary night-blindness, also its occurrence with atypical retinitis pigmentosa and with possibly gyrate atrophy of the choroid and retina in Zorn's pedigree[3] suggest that there is some common factor in the etiology of these conditions. Zorn's case is of special interest as the patient was married and had seven children of whom six were normal and one had possibly *retinitis pigmentosa sine pigmento.*

The defect has been noted in two brothers by Koenig[4], Alexander[5] and Mauthner[6]; Oguchi[7] and others have described cases whose siblings or other relatives were reported to be night-blind but had not been examined. It is perhaps worth drawing attention to the fact that all undoubted cases so far described have been in males. Other characteristics of the condition are night-blindness which the patient usually reports to have been present since his earliest recollections; the visual fields are contracted; the central vision in a good light may be full or may be defective; the discs and retinal vessels may be normal but are not invariably so; the condition appears to be either stationary or to progress very slowly. Eleven small pedigrees showing this condition in one or more of the members are given below in Figs. 119, 253, 255, 258—263, 286 and 287[8].

Gyrate atrophy of the choroid and retina. This condition which is of extreme rarity was named by Fuchs in 1895[9]; its distinguishing characteristic consists in the appearance of the fundus which in its typical form gave rise to the name of the defect and which shows an irregular zone of choroidal atrophy surrounding the disc, followed by a zone of normal choroid which is again surrounded by a zone of atrophy, the peripheral choroid being normal; the margins of the atrophic zones may be pigmented and are lobulated to form bays which encroach upon the areas of normal choroid. The condition varies much from case to case, and of the three sisters, patients of Fuchs and described by Cutler[10], one of them showed such marked divergence from the type that had the condition not been seen in her sisters she would assuredly not have been placed in this group. Other characteristics of the defect are night-blindness, defective vision, contraction of visual fields and discs and retinal vessels which may be normal or may be as found in retinitis pigmentosa.

The condition has been noted in siblings of either sex, and in one small pedigree[11] a father and son have a defect placed by Nettleship in this group though it is in some respects atypical.

[1] See Plate B. [2] Fig. 119. [3] Fig. 262. [4] Fig. 260.
[5] Fig. 255. [6] Fig. 287. [7] Figs. 258, 259, 261.
[8] See also Bibl. Nos. 134, 170, 237, 290, 319 for descriptions of further isolated cases.
[9] Bibl. No. 187. [10] Fig. 266. [11] Fig. 268.

The condition has not been found in association with retinitis pigmentosa unless we may include the doubtful case described in Zorn's pedigree[1], and although we should like to be able to describe it as due to an arrest in development of the choroid taking place at a later stage than the interruption which occurs in the case of choroideremia we are not able to do so at present. We hope shortly in cooperation with the embryologist to set going some developmental experiments which may throw some light on this question.

Pedigrees which are of interest in this connection may be seen in Figs. 262, 264—268, and 285[2].

[1] See Fig. 262.

[2] See also Bibl. Nos. 187, 188, 209, 297, 317 for references to single cases.

SECTION II

CONGENITAL STATIONARY NIGHT-BLINDNESS

This section is included here for convenience of issue and not out of consideration for any supposed association with retinitis pigmentosa; the two conditions differ fundamentally and the only factors common to both of them are a hereditary disposition and the presence of night-blindness, which is in this case always congenital and stationary, is associated with no visible changes in the fundus and with no other defect of vision except that due to myopia in the sub-group in which it occurs.

The first definite description of the defect as a clinical entity and distinct from the other hereditary diseases in which night-blindness is a marked feature, we owe to Leber who gave a very brief account of the condition in 1877, though several pedigrees of the condition had been published before that date. The earliest recorded hereditary case was, with the possible exception of the single sibship described by Richter[1] in 1830, the famous Cunier pedigree of the Nougaret family published in 1838; it was not however until Nettleship renewed interest in this family and the nature of the case was investigated with the aid of the ophthalmoscope that the Cunier pedigree greatly extended and brought up to date could in 1907 be definitely placed in this group[2]. The condition is of great rarity and only gradually the fact became recognised that the cases classed in this group were not homogeneous but that two definite sub-groups must be formed in one of which should be placed pedigrees in which both sexes are affected and the defect is transmitted by affected members of either sex only, or in some stocks by normal members also, in the second sub-group should be placed pedigrees in which the condition affects males only[3] and is transmitted characteristically by the unaffected female but in a few stocks is also transmitted by the affected male. This second sub-group is further differentiated by the very frequent association of myopia in the night-blind members and occasionally in their 'normal' siblings.

We have then an example of the type of inheritance which follows what is sometimes described as Nasse's[4] law and is seen to hold for such a variety of conditions as haemophilia, pseudo-hypertrophic muscular paralysis, nystagmus, Leber's disease, megalocornea, colour blindness, etc., we can find no common factor in these conditions

[1] See Fig. 297. [2] See Fig. 317.

[3] We obviously cannot be assured in all cases that a small pedigree in which males only are affected should be placed in this sub-group, as more complete information might reveal the defect in females also.

[4] Nasse described this type of inheritance for the case of haemophilia in 1820; he held the view that the male bleeder was in all cases ultimately responsible for the transmission of the disease in a latent form to his unaffected female descendants who were rendered in this way liable to transmit the defect; Lossen however in 1877 as the result of his analysis of the Mampel family (a historic bleeder family) concluded on the contrary that haemophilia was never transmitted through the male bleeder, that his children were only affected if he himself married a conductor and that in all cases it was through the unaffected female that the defect was inherited.

which might offer any clue to the explanation of their common mode of descent; it is significant that sex-limited inheritance should invariably confine the defect to the male and that there is no single hereditary disease known to us in which the female alone is affected.

There has been no advance in our knowledge of congenital stationary night-blindness since Nettleship gave a very complete account of all the available material in 1908. Doubtless owing to the rarity of the defect only two additional good, fully worked out pedigrees have been published since and the more extensive of these we owe to Nettleship. We are still in complete ignorance of the pathology of both types of the defect and cannot even be sure that the seat of the defect is in the eye at all; it has not yet been found possible to make a microscopic examination of the condition.

The defect is not a very serious handicap to the victims, but they are liable to difficulties and accidents which are so well expressed in a letter to Nettleship by one of his patients whom he describes as "a gentleman of scientific tastes and an acute and very trustworthy observer" that we are tempted to quote him fully. He writes: "I have a hand moving in front when in any doubt as to surroundings, and when out alone at night I invariably look up to catch the outline of trees, etc. against the sky unless the latter to me is absolutely black. In what is to me complete darkness I can, without a stick, get along fairly well by feeling the contour of the road or the junction of the roadway and grass. Naturally I have often come to grief when out alone at night, e.g. I three times walked into the canal near my father's house, twice in consequence of thinking a certain light was from one lamp when it was from another, and the third time because I had gone a little further than I thought. Again, I have walked over a wall and fallen six feet into a sunk road; once when walking fast through a village at twilight I cut my face open against a lamp-post, and as a boy I have run into many wheelbarrows and iron railings, and even a horse and cart standing still. At the same time I have never run into a wall or a tree of any size; I always detect the proximity of such a large solid object, sometimes by heat radiating from it, sometimes by a change in the air currents, but much more often by sound—the echo of my own footsteps. I can see very few of the stars, I think only the first magnitude, and though I can manage to get about in gas-lit streets I do not like doing so unless the ground is wet, and I can then see the reflections of the people and vehicles I meet..... I remember once, when I was a boy, being out with friends near the sea, in the daytime, when a thick fog came on, and as we hurried along through a grass field I suddenly stopped and called out; we all listened, and heard the sea breaking below us, the edge of a cliff which we thought a quarter of a mile off being a yard in front of us; I think it was an air current I felt as the sea was very calm[1]."

The disability in this case was evidently of an average intensity, but it is quite clear from other accounts that the defect is a graduated one and that possibly the rarity of published cases should not be taken as an indication of the rarity of the condition but rather as suggesting that the less severe cases are not detected. A correspondent of academic culture wrote to Professor Pearson as follows: "My mother is

[1] Bibl. No. 251, pp. 395—6.

rather myopic and suffers to a certain extent from night-blindness; but neither affection is very strongly marked. Of my eight brothers and sisters the five eldest (girls) give this result: A. (now dead) had normal sight, neither myopic nor night-blind; B. has also normal sight; C. is markedly myopic and is rather night-blind; D. has normal sight; E. is rather myopic, but not night-blind. The next child is myself; I am extremely myopic and perfectly night-blind. My next brother has normal sight; my youngest sister is extremely myopic and is perfectly night-blind; my youngest brother is very slightly myopic, but not at all night-blind." This example clearly indicates the variability of the defect within the sibship and suggests the need for an estimation of the light sense in all the affected and in a large sample of the general population. There are difficulties in the collection of such observations as require 10—20 minutes in a dark room before the test can be made but we hope shortly to find a sufficient number of people willing to come and sacrifice that amount of time and so enable us to get some accurate knowledge of the average light sense and its variability in the general population. We have in our series 33 pedigrees of congenital stationary night-blindness and of these 19 belong to the sub-group in which males and females are affected, 14 to the sub-group in which males only are affected; these numbers are very small but some of the pedigrees are so extensive that the material is not so meagre as might appear. Nowhere do we realise our debt to Nettleship more keenly than here; if we omitted the pedigrees which he worked out or which were investigated owing to his enquiry we should indeed find ourselves with scanty information.

Considering first the sub-group in which both sexes are affected, we find that the sexes are very nearly equally liable to the defect and there is no significant difference in the frequency with which either sex transmits the condition. When we come to examine the proportions of affected and unaffected in the sibships we have at once to admit that the material is entirely overruled by the very extensive Cunier pedigree and Nettleship had some doubts about the accuracy of the numbers given in it; he points out that there was no note of those who died in infancy and that there was a well recognised desire on the part of the family to hide the defect, the mothers fearing that a knowledge of the condition might hamper their children in life and the women fearing lest such knowledge should be a bar to their marriage. There is probably some underestimation of the numbers affected, from these causes, but the mothers were able at a very early infancy to discover whether their children were affected or not, and considering the years of labour devoted to the elaboration of this pedigree in 1838 as well as at the later period by the most indefatigable and careful workers we think that the figures given may be taken as a fairly close approximation to what has occurred; we know well how a whisper of an attempt to hide knowledge of this kind on the part of those giving the information rouses the alarm of the careful worker and tends perhaps too readily to plunge him into doubt and mistrust of the whole family history. Nevertheless the warning must be remembered in any consideration of the figures to be given.

Taking first the affected population only we find that 16·7 % of the individuals have a history of consanguinity in their parents or grandparents; this percentage is considerably lower than that found for retinitis pigmentosa but it is high and indicates

again that consanguinity is a factor of some importance in the etiology of this condition; but as we shall see later we find ourselves again confronted with the position that though we have this high percentage of consanguinity in the stocks in which the defect occurs we do not find a higher percentage of affected members in the offspring of consanguineous parents than in the offspring of unrelated parentage.

Analysing our material and dividing those who were stillborn or died in infancy in the proportion of the affected and normal for the population obtained by omitting sibships in which such cases occur, we get the following table:

	No. of Sibships	No. of Individuals	Percentage affected
Both parents normal ...	11*	71	$43{\cdot}7 \pm 4{\cdot}0$
No Consanguinity			
One parent affected ...	96	357	$41{\cdot}5 \pm 1{\cdot}8$
Mother affected	52	189	$43{\cdot}4 \pm 2{\cdot}4$
Father affected	44	168	$38{\cdot}7 \pm 2{\cdot}5$

* Two sibships were the offspring of first cousins.

Further we find 18 sibships, with one parent affected and a history of consanguinity, consisting of 89 individuals of whom $32{\cdot}6 \pm 3{\cdot}2$ % are affected. Now taking note of the probable errors there is no significant difference in any of the percentages given and indeed all we feel able to insist upon is that a history of consanguinity does not at any rate increase the percentage of affected offspring and that the percentage of affected offspring is probably no greater when one parent is affected than it is for the case of both parents normal[1].

We may add that there is one sibship only in our series for which both parents were affected, they were also distant cousins; this marriage resulted in two children who were both night-blind.

For the sub-group in which males only are affected and the condition is associated with myopia and is transmitted characteristically through the unaffected female but also in certain stocks may be handed on by the affected male, our material is scanty but we notice at once that consanguinity in parentage is no more frequent in this group than it is found to be in the general population and that indeed only 5 % of our affected population have a consanguineous parentage, we may therefore feel assured that consanguinity is of no significance as a factor in the etiology of this type of congenital stationary night-blindness.

Omitting all sibships containing individuals of unknown sex and making the usual allowance for those who died in early infancy we find ourselves with 60 sibships containing 112 affected males, 48 unaffected males and 119 unaffected females. Two interesting facts can be deduced from these figures: (i) The percentage of males affected

[1] When one parent is affected sibships occur in which all are normal, the figures given are therefore not really comparable with those for the case in which both parents are normal.

is very high, no fewer than 70 °/₀ of them showing the defect. (ii) There is an excess of males in the affected sibships, as if nature were trying to compensate for their defect by increasing their number, for 57·3 °/₀ of the members of affected sibships are males giving an excess of 15 males in every hundred of the population; Bulloch points to a similar excess of males in the affected sibships of the pedigrees of haemophilia. We must point out however that the population of such sibships is not a random sample of the general population with regard to sex but is highly selected in as far as no sibships can be included in which females only occur, affected males have a greater chance of occurring in sibships containing a large number of males than in sibships consisting chiefly of females, sibships with several affected males have a greater chance of record than those with few, and sibships in which all the males are normal are also excluded. With regard to the number of females who transmit the condition the only fact we can really insist upon is the inadequacy of our material; for a large number of unaffected females no statement as to whether they had or had not offspring is made, in other cases they had daughters only and we cannot say whether their sons if they had been born would have been affected or not; such figures as we have indicate that an exceedingly high percentage of the daughters of affected males transmit the defect and that a lower percentage of the daughters of unaffected females (who are nearly always siblings to affected males) hand on the defect to their sons. Thus we find for the daughters of affected males 24 who transmit the defect and only 4 who have unaffected male offspring; this gives a percentage of 86·2 who transmit the defect but we feel convinced that if we had complete information about the large number of cases in which we have no knowledge this percentage would be reduced, perhaps markedly. Again, for the daughters of unaffected females we find 26 who transmit the defect and 13 whose male offspring is unaffected giving a percentage of 66·7 who transmit the defect, a percentage which would again be probably markedly reduced with complete information.

We hope in a future number of this publication to give comparative values for the percentage of affected males in other sex-limited inheritable diseases.

SECTION III

BIBLIOGRAPHY

This Bibliography does not claim to be a complete record of all the literature which has been published on the subject of retinitis pigmentosa and allied diseases; it contains a few references to the early accounts of night-blindness in the chronological order of the authors, and as far as possible all papers of interest from the point of view of heredity. Accounts of isolated cases which give no information of the family history have only been included if they present some special point of interest or have been referred to in the text.

* indicates that the original publication has not been seen.

1 EBERS, G. Papyrus Ebers. Die Maasse und das Kapitel über die Augenkrankheiten. *Abhandlungen der philologisch-historischen Classe der königlich-sächsischen Gesellschaft der Wissenschaften.* Bd. XXV., S. 135—336. Leipzig, 1890. [This book of medicine of the ancient Egyptians is believed to date as far back as 1500 B.C. In it the classical prescription for night-blindness—the roasted liver of an ox—is recommended for some vaguely described defect of the eyes, and this has been held to suggest the recognition of night-blindness in Egypt at that early date.]

2 PLINIUS, C. S. Historiae Naturalis Libri XXXVII. Edited by Gabriel Brotier. Paris, 1779. [T. v., Lib. XXVIII., Cap. XLVII. "Et quoniam noctu aeque quoque cernant, sanguine hircino sanari lusciosos putant, nyctalopas a Graecis dictos...."]

3 CELSUS, A. C. Of Medicine in eight Books. Translated by J. Greive, M.D. London, 1756. [P. 345 "...there is a kind of weakness of the eyes, in which patients see well enough in the day-time, but not at all in the night: which never happens to a woman when her menstrual discharge is regular. But persons labouring under this disorder ought to be anointed with the blood of a liver (particularly the liver of a he goat, if that can't be had of a she goat) that drops from it while roasting; and they ought to eat the liver itself."]

4 AETIUS, A. Tetrabiblos II., Sermo III. Basil, 1542. [Cap. XLVI., p. 353 "De Nyctalope" describes night-blindness and its cure.]

5 TRALLIANUS, A. Medici libri duodecim. Basil, 1556. [Lib. II., Cap. VI., p. 147 "De Nyctalope."]

6 PAULUS AEGINETA, The seven Books of. Translated by F. Adams. London, 1844—47. [In Vol. I. of the translation, p. 420 we find "In the disease called nyctalopia the patient sees during the day, but at sunset his vision becomes dimmer, and when night comes on he does not see at all. We must effect the cure by bleeding from the arm and the angle of the eye, then purging or evacuating by a clyster, and afterwards ordering masticatories or sternutatories. Before food, we give hyssop to drink or rue, but if the disease do not yield we must again administer the purgative medicine formed from scammony and castor....Having roasted the liver of a goat, collect the ichor during the roasting and anoint, but give the liver itself to eat; or boil, and direct the vapours to be received with open eyes."]

7 ALSAHARAVIUS (Khalaf-ben-Abbas, Abu-al-Kasim). Liber Theoriae necnon practicae Alsaharavii in prisco Arabum medicorum conventu facile principis: qui vulgo Acararius dicitur; jam summa diligentia & cura depromptus in lucem. Augustae Vindelicorum, 1519. [In fol. XLVII., Cap. XII. of this translation by Ricius we find *De egritudine dicit alhasa.* "Haec egritudo est ut non videt quis in nocte & videt in die & appellat etia almazid...." The author prescribes a cure by venesection, blisters, gargles, and the liver of a goat to be used as described above.]

8 ACTUARIUS, J. Methodi medendi libri sex, quibus omnia quae ad medicinam factitandam pertinent, fere complectitur. Venetiis, 1554. [Lib. II., Cap. VII., p. 73 and Lib. IV., Cap. XI., p. 162 refer to night-blindness and its treatment.]

9 FOREST, P. VAN.] Observationum et curationum medicinalium ac chirurgicarum Opera omnia. Francofurt, 1634. [Lib. XI., Obs. XXXVIII., p. 46 gives a description of night-blindness under the heading of "De Nictalopia seu nocturna caecitudine."]

10 SCHENCK, J. Observationum medicarum rararum...Tomus unus. Continens Librum I. De capite, etc. Francofurti, 1600. [Describes a cure for night-blindness under the heading "Nyctalopis curatio expedita," p. 241, Obs. CCCXI.]

11 RIOLAN, J. A sure Guide; or the best and nearest Way to Physick and Chyrurgery. Written in Latin. Englished by N. Culpeper. London, 1671. ["Sight abolished is called Caecitas Blindness; when it is diminished only 'tis termed Amblyopia, thick sightedness; and it is accounted twofold *Myopsis* and *Nyctalops.* In the former the Patient is Pore-blind, and is fain to look close to what he would discern and to hold his eye-lids almost shut together. In the latter, the patient can see only by day, but very little or nothing at all by night, or very obscurely." Book IV., p. 142.]

12 GUILLEMEAU, J. Traité des maladies de l'œil. Paris, 1585. ["De ceux que ne voyent rien de nuict, que l'on peut nommer aveuglement de nuict, dict en grec Νυχταλωπιασις, en latin Nocturna ou respertina [? Vespertina] caecitudo." Chap. X., p. 27.]

13 BONTIUS, J. De medicina Indorum. Lugduni Batav., 1642. [It has been suggested that the Chapter entitled "De Coecitate, ac debilitate visus, quae navigantibus Amboynam, ac Moluccas versus, ac in circumiacentibus fretis accidit" (Cap. XVI., p. 173) describes a condition of night-blindness which often degenerated into a total deprivation of sight.]

14 Plemp, V. F. Ophthalmographia sive Tractatio de Oculo. Lovanii, 1648. [Lib. v., Cap. xxvi., pp. 219—221 "De Nyctalopiasi."]

15 Hoefer, W. Hercules medicus. Norimbergae, 1675. [A discussion of night-blindness is given Lib. i., Cap. viii., p. 72.]

16 Etmuller, M. Opera omnia in compendium redacta. London, 1701. ["Nyctalopia, si interdiu recte, vesperi parum aut nihil videtur, raro curatur." Lib. ii., p. 33.]

17 Maitrejean, A. Traité des maladies de l'œil. Troyes, 1707. [The author refers to the night-blindness which can be cured and the night-blindness which cannot be cured, and infers that you can only determine which case you are dealing with by watching the effects of treatment. Pp. 270—272.]

18 La Serre, J. Coecitas certa anni tempestate invadens. *Miscellanea Curiosa sive Ephemeridum medico-physicarum Germanicarum Academiae Imperialis Leopoldinae Naturae Curiosorum.* Dec. ii., Ann. vi., p. 169, Obs. lxxix. Norimbergae, 1688. See Fig. 291.

19 Ovelgün. Nyctalopia haereditaria. *Acta Physico-Medica.* Vol. vii., Obs. xxviii., pp. 76, 77. Norimbergae, 1744. See Fig. 292.

20 Bergen, C. A. A. and Weise, J. C. Disputatio de nyctalopia seu caecitate nocturna. Francof., 1754. *Haller's Disputationes ad morborum historiam et curationem facientes.* T. i., pp. 361—374. Lausannae, 1757.

21 Pye, S. Of a periodical blindness. *Medical Observations and Inquiries.* Vol. i., pp. 111—125. London, 1757.

22 Guthrie, M. Observations on the Kuritsha Slepota, or Hen blindness of Russia. *Medical Commentaries.* Dec. ii., Vol. ix., pp. 284—291. Edinburgh, 1794. [Gives an interesting early account of temporary night-blindness in Russia with its cure by an infusion of *Centaurea Cyanus* (Corn Flower). No recognition of a night-blindness which does not readily respond to treatment.]

23 Bampfield, R. W. A practical essay on hemeralopia or night-blindness, commonly called nyctalopia. *Medico-Chirurgical Trans.* Vol. v., pp. 32—66. London, 1814. [Concerns itself chiefly with the temporary night-blindness, sometimes associated with scurvy. The author states that night-blindness sometimes progresses to complete blindness, but considers this to be due to lack of proper treatment.]

24 Richter, H. C. E. Commentatio decima quarta enarrans tres hemeralopiae congenitae casus. *Scriptores ophthalmologici minores.* Vol. iii., pp. 173—206. Lipsiae, 1830. See Fig. 297.

25 Langenbeck, B. C. R. De retina. Observationes anatomico-pathologicae. Pp. 1—188. Gottingae, 1836. [Describes "melanosis retinae," pp. 155—160.]

26 Ammon, F. A. von. Klinische Darstellungen der Krankheiten und Bildungsfehler des menschlichen Auges. Berlin, 1841. [Plate xix. of the first part of this publication (dated 1838) shows in figures ix. and x. coloured illustrations of pigmentation of the retina.]

*27 Cunier, F. Histoire d'une Héméralopie Héréditaire depuis deux siècles dans une famille de la commune de Vendémian, près Montpellier. *Annales de la Société de Médecine de Gand*, 1838, pp. 383—395. Gand, 1838. See Fig. 317.

28 Cunier, F. Describes the Nougaret pedigree of congenital stationary night-blindness in a footnote to a paper by J. E. Petrequin, *Annales d'Oculistique et de Gynécologie.* T. i., pp. 31—33. Charleroi, 1838.

29 Boyer, P. Traité des maladies chirurgicales. T. iv., pp. 602, 616. Paris, 1847.

30 Stiévenart. Note sur une héméralopie héréditaire. *Annales d'Oculistique.* T. xviii., pp. 163, 164. Paris &c., 1847. See Fig. 305.

31 Van Trigt, A. C. De oogspiegel. *Nederlandsch Lancet.* 3e Ser., 2e J., B. 417—509. 's Gravenhage, 1852—1853. [On pp. 492, 493 the author gives what is probably the first description of the fundus of a case of retinitis pigmentosa as seen through the ophthalmoscope. Plate xii., Fig. 4 gives a good coloured illustration of the condition.]

32 Ruete, C. G. T. Bildliche Darstellung der Krankheiten des menschlichen Auges, Plate vii., Fig. 3, S. 52. Leipzig, 1854.

33 Donders, F. C. Torpeur de la rétine, congénitale héréditaire. *Annales d'Oculistique.* T. xxxiv., pp. 270—273. Paris &c., 1855. See Fig. 330.

34 Dumont, G. Recherches statistiques sur les causes et les effets de la Cécité. Pp. 1—117. Paris, 1856. [The author states that on investigation of the cause of blindness in 1168 individuals, hereditary transmission could be traced in 114 cases.]

35 Von Graefe, A. Ueber die Untersuchung des Gesichtsfeldes bei amblyopischen Affectionen. *Archiv f. Ophthalmologie.* Bd. ii., Abth. 2, S. 258—298. Berlin, 1856.

36 Donders, F. C. Beiträge zur pathologischen Anatomie des Auges. Pigmentbildung in der Netzhaut. *Archiv f. Ophthalmologie.* Bd. iii., S. 139—150. Berlin, 1857.

37 Förster, R. Ueber Hemeralopie und die Anwendung eines Photometers. Breslau, 1857. See Fig. 329.

38 Von Graefe, A. Exceptionelles Verhalten des Gesichtsfeldes bei Pigmententartung der Netzhaut. *Archiv f. Ophthalmologie.* Bd. iv., Abth. ii., S. 250—253. Berlin, 1858.

39 Junge. Beiträge zur pathologischen Anatomie der getigerten Netzhaut. *Archiv f. Ophthalmologie.* Bd. v., S. 49—95. Berlin, 1859.

40 Mooren, A. De la rétinite pigmenteuse. *Annales d'Oculistique.* T. xli., pp. 21—31. Bruxelles, 1859. See Fig. 210.

41 Schweigger, C. Untersuchungen über pigmentirte Netzhaut. *Archiv f. Ophthalmologie.* Bd. v., Abth. i., S. 96—111. Berlin, 1859.

42 Liebreich, R. Abkunft aus Ehen unter Blutsverwandten als Grund von Retinitis pigmentosa. *Deutsche Klinik.* Bd. xiii., No. 6, S. 53–55. Berlin, 1861. *Archives Générales de Médecine.* Sér. v., T. xix., pp. 145—151. Paris, 1862. See Figs. 80, 91.

43 Maes, H. G. Akademisch Proefschrift handelende over Torpor retinae. Pp. 1–134. Utrecht, 1861. [We owe the sight of this to the courtesy of the librarian of Utrecht University. See Figs. 11, 55, 68, 71, 88, 330, 331.]

44 Pagenstecher, H. A. Klinische Beobachtungen aus der Augenheilanstalt zu Wiesbaden. Bd. i., S. 26—42, 53. Wiesbaden, 1861. See Fig. 252.

45 Brochard. Danger des alliances consanguines. *Gazette médicale de Paris.* Sér. iii., T. xvii., p. 452. Paris, 1862. [Describes a case in which the marriage of healthy first cousins resulted in two children, one of whom was a deaf mute, the other had congenital hemeralopia (probably retinitis pigmentosa).]

46 Pope, Bolling. Ueber Retinitis pigmentosa insbesondere den Mechanismus der Entstehung von Pigment in der Retina. *Würzburger medicinische Zeitschrift.* Bd. iii., S. 244–251. Würzburg, 1862.

47 Mooren, A. Ueber Retinitis pigmentosa. *Klinische Monatsblätter f. Augenheilkunde.* Jahrg. i., S. 93—106. Erlangen, 1863. [Refers to von Graefe's early description of the disease in the Spanish Marquis Ariani.]

48 Van Biervliet u. von Rooy. Ueber Retinitis pigmentosa beim Pferde. *Archiv f. Ophthalmologie.* Bd. x., Abth. i., S. 81—86. Berlin, 1864. [Describes retinitis pigmentosa with hemeralopia in the horse.]

49 Höring, jun. Retinitis pigmentosa. *Klinische Monatsblätter f. Augenheilkunde.* Bd. ii., S. 233—235. Erlangen, 1864. See Fig. 114.

50 Schweigger, C. Vorlesungen über den Gebrauch des Augenspiegels. Berlin, 1864. [Retinitis pigmentosa is described pp. 112—118. No family histories given.]

51 Pedraglia. Retinitis pigmentosa. *Klinische Monatsblätter f. Augenheilkunde.* Bd. iii. S. 114—117. Erlangen, 1865. [Gives a detailed description of a case of unilateral retinitis pigmentosa.]

52 Stör. Retinitis pigmentosa. *Klinische Monatsblätter f. Augenheilkunde.* Bd. iii., S. 23, 24. Erlangen, 1865. [Describes a case of retinitis pigmentosa in a woman who had six fingers on each hand and six toes on each foot.]

53 Wilson, H. Retinitis pigmentosa. *Dublin Quarterly Journal of Medical Science.* Vol. xl., pp. 72—78. Dublin, 1865. [Discusses the pathology and clinical features of the condition.]

54 Hutchinson, J. Slowly progressive blindness from the age of 9 years. Retinitis pigmentosa with the accumulations most abundant near the disc. Extreme shrinking of retinal vessels. *Royal London Ophthalmic Hospital Reports.* Vol. v., pp. 325, 326. London, 1866.

55 Lawrence, J. Z. and Moon, R. C. Four cases of retinitis pigmentosa occurring in the same family and accompanied by general imperfections of development. *Ophthalmic Review.* Old Series, Vol. ii., pp. 32—41. London, 1866. See Fig. 267.

56 Laycock, T. Nyctalopia, with partial deafness, in five children of the same family. *Medical Times and Gazette.* Vol. i. for 1866, p. 412. London, 1866. See Fig. 238.

57 Schultze, M. Zur Anatomie und Physiologie der Retina. *Archiv f. mikroskopische Anatomie.* Bd. ii., S. 165—286. Bonn, 1866.

58 De Wecker, L. Traité Théorique et Pratique des maladies des Yeux. T. ii., pp. 344—52. 1866. Paris.

59 Mooren, A. Ophthalmiatrische Beobachtungen. Berlin, 1867. [The significance of consanguinity in parentage as a factor in the production of retinitis pigmentosa is suggested p. 261; the familial character of the disease is referred to and several incomplete histories are given.]

60 Simi, A. Retinitis pigmentosa occurring in three brothers. *Ophthalmic Review.* Vol. iii., p. 278. London, 1867. See Fig. 38.

61 Jeffries, B. Joy. Three cases of retinitis pigmentosa, together with a ready method of recording the field of vision, and a register for the same. *The Boston Medical and Surgical Journal.* Vol. i. (new series), pp. 193—195. Boston, 1868. See Figs. 192, 197.

62 Mannhardt, J. Klinische Mittheilungen aus Constantinopel. *Archiv f. Ophthalmologie.* Bd. xiv., Abth. iii., S. 26–50. Berlin, 1868. [Reports that retinitis pigmentosa is very common in Constantinople and consanguinity in parentage is rare.]

63 Mouchot, E. Essai sur la rétinite pigmentaire. Pp. 1—69. Paris, 1868. See Figs. 288, 293, 294.

64 Picard, A. Note sur un cas de rétinite pigmentaire s'accompagnant de choroïdite atrophique et de cataracte polaire; effets vicieux d'une alliance consanguine. *Gazette médicale de Paris.* Sér. iii., T. xxiii., pp. 332, 333. Paris, 1868. See Fig. 77.

65 Hutchinson, J. Cases of retinitis pigmentosa with remarks. *Royal London Ophthalmic Hospital Reports.* Vol. vi., pp. 39—42. London, 1869. See Fig. 191.

66 Hutchinson, J. Retinitis pigmentosa in an advanced stage. Gradual failure during 20 years or more. Nyctalopia not present. Reported failure of sight in a daughter of the patient. *Royal London Ophthalmic Hospital Reports.* Vol. vi., pp. 222, 223. London, 1869.

67 Hutchinson, J. Retinitis pigmentosa supposed to be congenital: marriage of consanguinity. Nyctalopia an ill-marked symptom. Ophthalmoscopic appearances. *Royal London Ophthalmic Hospital Reports.* Vol. vi., pp. 272, 273. London, 1869.

68 Leber, T. Ueber Retinitis pigmentosa und angeborene Amaurose. *Archiv f. Ophthalmologie.* Bd. xv., Abth. iii., S. 1—25. Berlin, 1869. [Describes the post-mortem examination of the eye of a patient who had suffered from retinitis pigmentosa.]

69 KNAPP, H. Demonstration of ophthalmoscopic drawings. *Trans. of American Ophthalmological Society.* Vol. I., pp. 120—122. Boston, 1870.

70 WINDSOR, T. Retinitis pigmentosa: its seat and nature. *Manchester Medical and Surgical Reports.* Vol. I., pp. 161—167. Manchester, 1870. [The author concludes that—(1) in some, probably in many, cases the disease commences and is chiefly located in the outer layers of the retina; (2) the disease is probably inflammatory in its nature, and that the inflammatory processes in the adjacent portion of the choroid, the inner layers of the retina, the optic nerve, the vitreous and the lens are secondary.]

71 BERLIN, R. Ueber Sehnervendurchschneidung. *Klinische Monatsblätter f. Augenheilkunde.* Bd. IX., S. 278—305. Erlangen, 1871.

72 LEBER, T. Ueber anomale Formen der Retinitis pigmentosa. *Archiv f. Ophthalmologie.* Bd. XVII., Abth. I., S. 314—341. Berlin, 1871. See Figs. 49, 124, 129.

73 SCHULTZE, M. Neue Beiträge zur Anatomie und Physiologie der Retina des Menschen. *Archiv f. mikroskopische Anatomie.* Bd. VII., S. 244—257. Bonn, 1871.

74 SWANZY, H. R. A peculiar form of retinitis pigmentosa in connection with inherited syphilis. *Dublin Quarterly Journal of Medical Science.* Vol. LI., pp. 290—294. Dublin, 1871. [Description of a case with coloured plate of fundus.]

75 BAYER, F. W. B. Ueber Retinitis pigmentosa. Pp. 5—28. Inaugural Dissertation. Bonn, 1872. See Figs. 33, 183.

76 HARLAN, G. C. Case of congenital retinitis pigmentosa. *American Journal of the Medical Sciences.* Vol. LXIV., pp. 130, 131. Philadelphia, 1872.

77 LANDOLT, E. Anatomische Untersuchungen über typische Retinitis pigmentosa. *Archiv f. Ophthalmologie.* Bd. XVIII., Abth. I., S. 325—348. Berlin, 1872. [Describes microscopic examinations of two cases of retinitis pigmentosa.]

*78 MAUTHNER, L. Ein Fall von Chorioideremie. *Naturwissenschaftlich-medizinischer Verein.* Innsbruck, 1872. [Describes a case of choroideremia in a man aged 32 who was night-blind and had defective central vision; the choroid was believed to be entirely absent in the left eye and to be represented by a few remains only in the right. A brother was believed to be similarly affected; a paternal uncle saw badly. (Taken from Nettleship and Usher.) See Fig. 287.]

79 BAUMEISTER, E. Retinitis pigmentosa unilateralis mit gleichseitiger Taubheit. *Archiv f. Ophthalmologie.* Bd. XIX., Abth. II., S. 261—264. Berlin, 1873.

80 FITZGERALD, C. E. Case of congenital nyctalopia commonly termed hemeralopia. *Irish Hospital Gazette.* Vol. I., pp. 216—218. Dublin, 1873. See Fig. 310.

*81 FRICKENHAUS, G. Beitrag z. Aetiologie u. Ther. d. typ. Pigment-Entartung der Retina. Inaugural Dissertation. Marburg, 1873. See Fig. 219.

82 HARLAN, G. C. Report of an examination of the eyes of 167 inmates of the Pennsylvania Institution for the Instruction of the Blind. *American Journal of the Medical Sciences.* Vol. LXV., pp. 410—419. Philadelphia, 1873. See Figs. 29, 62, 117.

83 SWANZY, H. R. Cases of congenital hemeralopia. *Irish Hospital Gazette.* Vol. I., pp. 84—86. Dublin, 1873. See Fig. 316.

84 SOELBERG WELLS, J. A treatise on the diseases of the eye. London, 1873 (3rd edition). [Retinitis pigmentosa is described pp. 388—393 and a coloured plate of the fundus in this disease is given.]

85 MOOREN, A. Ophthalmologische Mittheilungen aus dem Jahre 1873. Berlin, 1874. See Fig. 58.

*86 KOENIG, H. Zwei Beobachtungen von mangelhafter Entwickelung der Choriodea verbunden mit Hemeralopie. Inaugural Dissertation. Greifswald, 1874. See Fig. 260.

87 SCHELSKE, R. Lehrbuch der Augenheilkunde. Berlin, 1874. [Describes retinitis pigmentosa and *retinitis pigmentosa sine pigmento* and refers to the inheritable nature of the disease. Pp. 182—5. No family histories given.]

88 SCHMIDT, H. Zur Heredität der Retinitis pigmentosa. *Klinische Monatsblätter f. Augenheilkunde.* Bd. XII., S. 29—32. Erlangen, 1874. See Fig. 200.

89 HOCQUARD, E. De la rétinite pigmentaire. Paris, 1875. See Fig. 7.

90 HOSCH. Ungewöhnliche Form von Retinitis pigmentosa. *Klinische Monatsblätter f. Augenheilkunde.* Bd. XIII., S. 58—64. Stuttgart, 1875. [Describes microscopic examination of an eye affected with retinitis pigmentosa.]

91 PONCET. Examen histologique d'un cas de rétinite pigmentaire. *Annales d'Oculistique.* T. LXXIV., pp. 234—239. Bruxelles, 1875. [Describes the post-mortem examination of the eye of the case whose history is given by Hocquard. The patient died of malignant scarlet fever.]

92 SCHWEIGGER, C. Handbuch der speciellen Augenheilkunde. Berlin, 1875. [Retinitis pigmentosa is described pp. 452—461, its hereditary nature is referred to, also the frequent association of other defects, but no family histories are given.]

93 BADER, C. Retinitis pigmentosa. *Guy's Hospital Reports.* Vol. XXI., pp. 229—232. London, 1876.

94 NOLDEN, P. Ueber Retinitis pigmentosa. Pp. 5—21. Inaugural Dissertation. Bonn, 1876. See Figs. 33, 208.

95 PUFAHL. Ueber hereditäre Amblyopie. *Berliner klinische Wochenschrift.* Bd. XIII., S. 128—130. Berlin, 1876. See Fig. 234.

96 WARLOMONT and DUVEZ. De la rétinite pigmentaire. *Annales d'Oculistique.* T. LXXVI., pp. 113—143. Bruxelles, 1876. [An interesting historical sketch of the disease referring to its hereditary nature but giving no family histories.]

97 Hutdiez. Rétinite pigmentaire sans pigment visible à l'ophthalmoscope. *Annales d'Oculistique.* T. LXXVIII., pp. 211—214. Bruxelles, 1877. See Fig. 8.

98 Leber, T. Die Krankheiten der Netzhaut und des Sehnerven. Graefe-Saemisch: *Handbuch der gesammt. Augenheilkunde.* Bd. v., S. 521—1048. Leipzig, 1877. See Fig. 116.

99 Nettleship, E. N. Clinical Notes and Cases. Retinitis pigmentosa, Cases 1—4. *Royal London Ophthalmic Hospital Reports.* Vol. IX., pp. 168—175. London, 1877. See Figs. 17, 21.

100 Pier d' Houy, A. Contribuzione allo studio della retinite pimmentosa. *Annali di Ottalmologia.* Anno VI., pp. 10—15. Milano, 1877. [Describes two cases of retinitis pigmentosa in each of which the condition appears to have been inherited. Coloured plates of the fundi of one of the cases are not very typical.]

101 Alt, A. Ein Fall von vor der Enucleation diagnosticirter Retinitis pigmentosa. *Archiv f. Augen- u. Ohrenheilkunde.* Bd. VII., S. 376—379. Wiesbaden, 1878. [Macroscopic and microscopic appearances of the eye are described.]

102 Pagenstecher. Erblichkeit der Hemeralopie. *Beilage zum Centralblatt f. praktische Augenheilkunde.* Bd. II., S. XL. Leipzig, 1878. See Fig. 318.

103 Panas, F. Leçons sur les rétinites. Paris, 1878. [Retinitis pigmentosa is considered in chapters X. and XI., pp. 127—162.]

104 Vieusse. Une nouvelle forme d'héméralopie, dite "héméralopie temporaire congénitale." *Gazette Hebdomadaire de Médecine et de Chirurgie.* Sér. II., T. XV., pp. 667—669. Paris, 1878. See Fig. 315.

105 Webster, D. The aetiology of retinitis pigmentosa with cases. *Trans. of American Ophthalmological Society.* Vol. II., pp. 495—505. Boston, 1878. [Describes family in Kentucky which has suffered from retinitis pigmentosa for more than two hundred years; about half the members are affected. There has been one intermarriage and the children of this union form the only sibship entirely free from disease. No details of this pedigree are given. See Figs. 2, 12, 26, 74, 76, 90, 99.]

106 Hirschberg, J. Beiträge zur Anatomie und Pathologie des Auges. *Archiv f. Augenheilkunde.* Bd. VIII., S. 49—64. Wiesbaden, 1879. [An anatomical examination of retinitis pigmentosa is described pp. 53—55.]

107 Oeller, J. N. Beiträge zur Lehre der Chorio-Retinitis pigmentosa. *Archiv f. Augenheilkunde.* Bd. VIII., S. 435—482. Wiesbaden, 1879.

108 Badal. Examen des yeux des deux cents sourdes-muettes de l'institution nationale de Bordeaux. *Annales des Maladies de l'Oreille, du Larynx.* T. VII., pp. 198—209. Paris, 1881. [Six cases of retinitis pigmentosa found associated with deaf mutism, three of the cases being in the offspring of first cousins. No family histories are given.]

109 Greenhill, W. A. On the meaning of the words "Nyctalopia" and "Hemeralopia": with a critical examination of the use of these words in the ancient Greek and Latin authors. *Royal London Ophthalmic Hospital Reports.* Vol. X., pp. 284—292. London, 1881.

*110 Machek. On zwyrodineniu barwikowem siatkowki (chorioretinitis). *Przeglad lekarski.* XX., S. 201, 219, 235. Krakow, ?1881. Abstract in *Jahresbericht der Ophthalmologie* for 1881, p. 395. Tübingen, 1883. See Fig. 175.

111 Cowell, G. Retinitis pigmentosa with remarkably little pigment. *Trans. of Ophthalmological Society of United Kingdom.* Vol. II., p. 58. London, 1882. See Fig. 10.

112 Derigs, G. Ueber Retinitis pigmentosa. Pp. 7—22. Inaugural Dissertation. Bonn, 1882. See Figs. 180, 183, 196, 235, 236, 242.

113 Hutchinson, J. On retinitis pigmentosa and allied affections, as illustrating the laws of heredity. *Ophthalmic Review.* Vol. I., pp. 2—7, 26—30. London, 1882.

114 Mooren, A. Fünf Lustren ophthalmologischer Wirksamkeit. Wiesbaden, 1882. See Figs. 15, 56, 57, 101.

115 Priestly Smith. Retinitis pigmentosa connected with a history of maternal shock. *Ophthalmic Review.* Vol. I., pp. 30—32. London, 1882. See Fig. 79.

116 Tweedy, J. On the meaning of the words "Nyctalopia" and "Hemeralopia" as disclosed by an examination of the diseases described under these terms by the ancient and modern medical authors. *Royal London Ophthalmic Hospital Reports.* Vol. X., pp. 413—436. London, 1882.

117 Ulrich, R. 3 Fälle von typischer Retinitis pigmentosa mit rudimentärer Arteria hyaloidea perseverans. *Klinische Monatsblätter f. Augenheilkunde.* Bd. XX., S. 240, 241. Stuttgart, 1882. [No family histories given; one of the cases was of consanguineous parentage.]

118 Burnett, S. M. A case of retinitis albescens punctata. *Archives of Ophthalmology.* Vol. XII., pp. 22—25. New York, 1883. [Describes an isolated case of rather doubtful nature.]

119 Dor, H. Héméralopie dépendant d'une forme atypique de rétinite. *Archives d'Ophtalmologie.* T. III., pp. 481—485. Paris, 1883.

120 Gayet, A. D'une lésion congénitale de la rétine est-ce une rétinite pigmentaire? *Archives d'Ophtalmologie.* T. III., pp. 385—393. Paris, 1883. See Fig. 271.

121 Landesberg, M. Zur Retinitis punctata albescens. *Centralblatt f. praktische Augenheilkunde.* Bd. VII., S. 261—267. Leipzig, 1883. [Three cases described, no family histories given.]

122 Lee, C. G. Notes on the ophthalmic conditions of deaf-mutes. *British Medical Journal.* Vol. II. for 1883, p. 1184. London, 1883. [The author emphasises the peculiar liability of deaf-mutes to retinitis pigmentosa.]

123 Magnus, H. Die Blindheit, ihre Entstehung und ihre Verhütung. Breslau, 1883. See Fig. 232.

124 Pflüger. Stammbaum einer Familie, in welcher Hemeralopie neben hochgradiger Myopie sich forterbt. *Universitäts-Augenklinik in Bern. Bericht über das Jahr* 1881. Pp. 54—59. Bern, 1883. See Fig. 326.

125 Rampoldi, R. Retinite pigmentosa in quattro fratelli pellagrosi. *Annali di Ottalmologia.* Anno xii., pp. 268, 269. Pavia, 1883. [A scanty history given with no reference to normal members of the family. See Fig. 290.]

126 Ulrich, R. Typische Retinitis pigmentosa mit congenitalen Glaskörper-Anomalien. *Klinische Monatsblätter f. Augenheilkunde.* Bd. xxi., S. 140—142. Stuttgart, 1883. See Fig. 277.

127 Zimmermann, C. A review of the theories of hemeralopia, with a case of night-blindness from miasmatic influences affecting four children of the same family. *Archives of Ophthalmology.* Vol. xii., pp. 190—200. New York, 1883.

128 Chibret. Un cas extraordinaire d'héméralopie congénitale. *Archives d'Ophtalmologie.* T. iv., pp. 79—83. Paris, 1884. [No family history given.]

129 Guaita. Anatomie et physiologie pathologique de la rétinite pigmentaire. *Recueil d'Ophthalmologie.* Sér. iii., T. vi., pp. 319—386. Paris, 1884.

130 Parinaud, H. Sur la sensibilité visuelle. *Comptes Rendus de l'Académie des Sciences.* T. xcix., pp. 241, 242. Paris, 1884.

131 Tobin, W. Pigmentary degeneration of the retina in deaf-mutes. *Canada Medical and Surgical Journal.* Vol. xii., pp. 193—201. Montreal, 1884. See Fig. 73.

132 Ancke, R. Beiträge zur Kenntniss von der Retinitis pigmentosa. *Centralblatt f. praktische Augenheilkunde.* Bd. ix., S. 167—175. Leipzig, 1885. See Fig. 65.

133 Magnus, H. Die Blinden der Stadt Breslau im Jahre 1884. *Archiv f. Augenheilkunde.* Bd. xiv., S. 391—436. Wiesbaden, 1885. See Fig. 295.

134 Morton, S. A. Atrophy of choroid. *Trans. of Ophthalmological Society of United Kingdom.* Vol. v., pp. 142—144. London, 1885. [Coloured plate of fundus is given showing red reflex present only at the macular region; family history negative.]

135 Schleich, G. Die Augen der Idioten der Heil- und Pflege-Anstalt Schloss Stetten in Württemberg. *Klinische Monatsblätter f. Augenheilkunde.* Bd. xxiii., S. 446—456. Stuttgart, 1885. [The author examined 156 cases and found not a single example of typical retinitis pigmentosa.]

136 Sedan. Une famille d'héméralopes. *Recueil d'Ophthalmologie.* Sér. iii., T. vii., pp. 675—678. Paris, 1885. See Fig. 301.

137 Wider, A. Ueber die Aetiologie der Retinitis pigmentosa. Pp. 3—33. Inaugural Dissertation. Tübingen, 1885. See Figs. 34, 96, 248.

138 Ayres, S. C. Retinitis pigmentosa. *American Journal of Ophthalmology.* Vol. iii., pp. 81—90. St Louis, Mo., 1886. See Figs. 46, 72, 130, 231, 244, 250.

139 Cant, W. J. A family of four children affected with retinitis pigmentosa, the father being an epileptic. *Ophthalmic Review.* Vol. v., pp. 245, 246. London, 1886. See Fig. 97.

140 Davidson, D. Congenital blindness from optic atrophy and pigmentary retinitis. *British Medical Journal.* Vol. i. for 1886, p. 72. London, 1886. [Four scanty family histories are given, two of which are said to be associated with syphilis. No description of individual cases.]

141 Kerschbaumer, F. Die Blinden des Herzogthums Salzburg. Wiesbaden, 1886. [Cases of retinitis pigmentosa are described on p. 23. See Fig. 233.]

142 Magnus, H. Die Jugend-Blindheit. Wiesbaden, 1886. See Fig. 181.

143 Magnus, H. Fall von einseitiger idiopathischen Hemeralopie. *Klinische Monatsblätter f. Augenheilkunde.* Bd. xxiv., S. 269—271. Stuttgart, 1886.

144 Picqué, L. Anomalies de développement et maladies congénitales du globe de l'œil. Thèse, pp. 1—476. Paris, 1886.

145 Schleich, G. Die Augen der Epileptiker der Heilanstalt Schloss Stetten in Württemberg. *Klinische Monatsblätter f. Augenheilkunde.* Bd. xxiv., S. 469—474. Stuttgart, 1886. [The author examined 127 individuals and described no typical case of retinitis pigmentosa.]

146 Siegheim, M. Beiträge zur Kenntniss der Retinitis Pigmentosa. Pp. 9—68. Inaugural Dissertation. Breslau, 1886. See Figs. 41, 95, 122.

147 Snell, S. Nyctalopia (Retinitis Pigmentosa) occurring in several members of one family. *Ophthalmic Review.* Vol. v., pp. 72—74. London, 1886. See Fig. 42.

148 Darier, A. Quelques observations de rétinite pigmentaire avec anomalies intéressantes. *Archives d'Ophtalmologie.* T. vii., pp. 170—176. Paris, 1887. See Figs. 190, 194, 195, 205, 214.

149 Derby, H. On the possible retardation of retinitis pigmentosa. *Trans. of American Ophthalmological Society.* Vol. iv., pp. 217—227. Boston, 1887. See Figs. 81, 113.

150 Featherstonhaugh, T. Hemeralopia without appreciable lesion. *American Journal of Ophthalmology.* Vol. iv., pp. 241—244. St Louis, 1887. [Describes a case of congenital stationary night-blindness without fundus changes associated with congenital deafness in a man aged 21 years who had been a somnambulist in his earlier youth. Family history negative.]

151 Nettleship, E. On some of the forms of congenital and infantile amblyopia. *Royal London Ophthalmic Hospital Reports.* Vol. xi., pp. 353—399. London, 1887. See Fig. 323.

152 Nettleship, E. Cases of permanent partial night-blindness with unusual ophthalmoscopic changes. *Trans. of Ophthalmological Society of United Kingdom.* Vol. vii., pp. 301—305. London, 1887.

153 Perlia. Beitrag zur Vererbungslehre der Augenleiden. *Klinische Monatsblätter f. Augenheilkunde.* Bd. xxv., S. 197—203. Stuttgart, 1887.

154 Standish, M. A case of retinitis pigmentosa treated electrically. *Trans. of American Ophthalmological Society.* Vol. iv., pp. 553—558. Boston, 1887. [Describes very material improvement in a case under treatment.]

155 Jacobsohn, E. Ein Fall von Retinitis pigmentosa atypica. *Klinische Monatsblätter f. Augenheilkunde.* Bd. xxv., S. 202—206. Stuttgart, 1888. See Fig. 268.

156 Mellinger, C. Drei Fälle von Retinitis pigmentosa. Besserung der centralen Sehschärfe und des Gesichtsfeldes. *Klinische Monatsblätter f. Augenheilkunde.* Bd. xxvi., S. 356—366. Stuttgart, 1888. See Fig. 78.

157 Nettleship, E. A case of stationary night-blindness with minute white spots at the fundus. *Trans. of Ophthalmological Society of United Kingdom.* Vol. viii., pp. 163—171. London, 1888.

158 Peltesohn, N. Zur Frage der *Retinitis pigmentosa sine pigmento. Centralblatt f. praktische Augenheilkunde.* Bd. xii., S. 206—211. Leipzig, 1888. See Fig. 9.

159 Oakley, J. Consanguineous marriages and retinitis pigmentosa in children. *The Provincial Medical Journal.* Vol. viii., pp. 329, 330. Leicester, 1889. See Figs. 86, 107, 128.

160 Wecker, L. de and Landolt, E. Traité complet d'Ophthalmologie. Paris, 1878—1889. [Vol. iv., pp. 121—140 gives an interesting description of retinitis pigmentosa.]

161 Günsburg, F. Ueber einen Fall von typischer Retinitis pigmentosa unilateralis. *Archiv f. Augenheilkunde.* Bd. xxi., S. 184—191. Wiesbaden, 1890. [Family history negative.]

162 Kaupp, M. Ueber Retinitis pigmentosa. Pp. 5—42. Inaugural Dissertation. Freiburg, 1890. See Figs. 83, 226.

163 Schmidt, E. Ueber Retinitis pigmentosa. Pp. 3—48. Inaugural Dissertation. Bonn, 1890. See Figs. 14, 132, 220, 235.

164 Wagenmann, A. Experimentelle Untersuchungen über den Einfluss der Circulation in den Netzhaut- und Aderhautgefässen auf die Ernährung des Auges, insbesondere der Retina, und über die Folgen der Sehnervendurchschneidung. *Archiv f. Ophthalmologie.* Bd. xxxvi., Abth. iv., S. 1—120. Leipzig, 1890.

*165 Deutschmann, R. Einseitige typische Retinitis pigmentosa mit pathologischem Befund. *Beiträge z. Augenheilkunde.* Bd. iii., S. 69—. Hamburg, 1891.

166 Macnamara, N. C. Diseases and refraction of the eye. London, 1891. [Refers to the frequency of retinitis pigmentosa among the natives of India. P. 291.]

167 Ransohoff, M. Zur Kenntniss der Retinitis pigmentosa. *Klinische Monatsblätter f. Augenheilkunde.* Bd. xxix., S. 271—273. Stuttgart, 1891. See Fig. 69.

168 Wagenmann, A. Beitrag zur Kenntniss der pathologischen Anatomie der Retinitis pigmentosa. *Archiv f. Ophthalmologie.* Bd. xxxvii., Abth. i., S. 230—242. Leipzig, 1891. [Describes a post-mortem examination of the eye of a man who had suffered from typical retinitis pigmentosa; the man's sister had retinitis pigmentosa associated with deafness and dementia, also his niece aged 12 was under treatment for retinitis pigmentosa.]

169 Ayres, S. C. Retinitis pigmentosa in the coloured race. *American Journal of Ophthalmology.* Vol. ix., pp. 65, 66. St Louis, Mo., 1892. See Fig. 131.

170 Cowgill, W. M. Report of a case in which there is binocular absence of the choroid showing a rich plexus of cilio-retinal vessels supplying the region of the yellow spot in both eyes. *Archives of Ophthalmology.* Vol. xxi., pp. 105—106. New York, 1892. [Drawings of the fundi are given; no family history.]

171 Trousseau, A. La consanguinité en pathologie oculaire. *Annales d'Oculistique.* T. cvii., pp. 5—12. Paris, 1892. See Figs. 39, 230.

172 Bellarminoff, L. Ein seltener Fall von Retinitis pigmentosa complicirt durch Glaucom. *Archiv f. Augenheilkunde.* Bd. xxvii., S. 53—61. Wiesbaden, 1893. See Fig. 245.

173 Capauner. Das Zustandekommen der Netzhautpigmentirung. *Bericht der xxiii Versammlung der Ophthalmologischen Gesellschaft zu Heidelberg.* S. 45—75. Published with the *Klin. Monatsbl. f. Augenheilk.* Bd. xxxi. Stuttgart, 1893.

174 Germaix. Pseudo-rétinite pigmentaire. *Annales d'Oculistique.* T. cx., pp. 276—281. Paris, 1893.

175 Morton, A. Stanford. Two cases of hereditary congenital night-blindness without visible fundus change. *Trans. of Ophthalmological Society of United Kingdom.* Vol. xiii., pp. 147—150. London, 1893.

*176 Neuffer, F. Ueber den Einfluss der Heredität und der Consanguinität der Eltern in der Aetiologie der Retinitis pigmentosa. Inaugural Dissertation. Strassburg, 1893. See Figs. 187, 218.

177 Cutler, Colman W. Drei ungewöhnliche Fälle von Retino-choriodeal Degeneration. *Archiv f. Augenheilkunde.* Bd. xxx., S. 117—122. Wiesbaden, 1894. See Fig. 266.

178 Marlow, F. W. A case of retinitis pigmentosa with extreme contraction of the visual fields and without night-blindness. *American Journal of Ophthalmology.* Vol. xi., pp. 191, 192. St Louis, Mo., 1894. [Describes typical ophthalmoscopic appearances of retinitis pigmentosa in case; no family history of eye-trouble; no consanguinity.]

179 Reinecke, G. Ein Beitrag zur Kenntniss der Retinitis pigmentosa. Pp. 5—17. Inaugural Dissertation. Kiel, 1894. See Figs. 201, 206, 216.

180 Atwool, W. T. Two cases of hereditary congenital night-blindness. *Royal London Ophthalmic Hospital Reports.* Vol. xiv., pp. 260—263. London, 1895. See Fig. 308.

181 Bürstenbinder, O. Anatomische Untersuchung eines Falles von Retinitis pigmentosa. *Archiv f. Ophthalmologie.* Bd. xli., Abth. iv., S. 175—186. Leipzig, 1895.

182 Cutler, C. W. Congenital night-blindness and pigmentary degeneration. *Archives of Ophthalmology.* Vol. xxiv., pp. 313—333. New York, 1895. See Figs. 302, 306, 325.

183 Liebrecht, R. Retinitis punctata albescens. *Klinische Monatsblätter f. Augenheilkunde.* Bd. xxxiii., S. 169—176. Stuttgart, 1895. [The author describes an interesting family history of a condition which Nettleship suggested should be classed clinically as family choroiditis.]

184 Roy, A. B. Retinitis pigmentosa. Report of a case. *Annals of Ophthalmology and Otology.* Vol. iv., pp. 24—28. St Louis, 1895. See Fig. 188.

185 Bruns, H. D. Two years in a southern eye clinic; with especial reference to diseases of the eye in the Negro; four thousand one hundred and sixty cases arranged in statistical tables. *American Journal of Ophthalmology.* Vol. xiii., pp. 193—207, 228—235, 278—288. St Louis, Mo., 1896. [Of the 4160 cases in the tables 1113 only were of African descent; three cases of retinitis pigmentosa in the negro were recorded.]

186 Frost, W. Adams. The fundus oculi. London, 1896. [Gives four coloured illustrations of the fundus in varying types of retinitis pigmentosa.]

187 Fuchs, E. Ueber zwei der Retinitis pigmentosa verwandte Krankheiten (Retinitis punctata albescens und *Atrophia gyrata chorioideae et retinae*). *Archiv f. Augenheilkunde.* Bd. xxxii., S. 111—116. Wiesbaden, 1896. [Describes in considerable detail an isolated case of retinitis punctata albescens in the offspring of a nephew and aunt, also an isolated case of gyrate atrophy of choroid and retina, with some discussion of the characteristics of these conditions.]

188 Jennings, J. E. A rare form of retino-choroidal degeneration. *American Journal of Ophthalmology.* Vol. xiii., pp. 74—76. St Louis, 1896. [An interesting case of gyrate atrophy of choroid and retina is described in a male; posterior cortical cataracts were present in both eyes. The parents, a brother and one sister had good sight; a sister who was dead had had bad sight, which the patient believed to have been much the same as his.]

189 McCassy, J. H. Some cases of retinitis. *Annals of Ophthalmology and Otology.* Vol. v., pp. 1300—1304. St Louis, 1896. See Fig. 209.

190 McCreight, S. L. Retinitis pigmentosa without night-blindness—recurrence of that symptom after optical iridectomy. *Annals of Ophthalmology and Otology.* Vol. v., p. 60. St Louis, Mo., 1896. See Fig. 193.

191 Nolte, F. Beitrag zu der Lehre von der Erblichkeit von Augenerkrankungen. Pp. 1—37. Inaugural Dissertation. Marburg, 1896. See Fig. 217.

192 Schneider, H. Ueber die Erblichkeit der Retinitis pigmentosa nebst Mitteilung eines Falles von Retinitis pigmentosa hereditaria in fünf Generationen einer Familie. Pp. 5—39. Inaugural Dissertation. Berlin 1896. See Fig. 4.

193 Goldzieher, W. Ein Fall von Retinitis pigmentosa mit Glaucoma. *Centralblatt f. praktische Augenheilkunde.* Bd. xxi., S. 116—118. Leipzig, 1897. See Fig. 251.

194 Gould, G. M. Retinitis pigmentosa without the characteristic pigmentation. A report of two cases. *Annals of Ophthalmology.* Vol. vi., pp. 695—710. St Louis, 1897. See Fig. 59.

195 Griffith, J. A case of so-called "retinitis punctata albescens." *Trans. of Ophthalmological Society of United Kingdom.* Vol. xvii., pp. 51—53. London, 1897. See Fig. 273.

196 Heinersdorff. Ein Fall von doppelseitigem, nicht entzündlichem Glaucom in jugendlichem Lebensalter bei gleichzeitiger Retinitis pigmentosa und Myopie. *Archiv f. Augenheilkunde.* Bd. xxxiv., S. 230—241. Wiesbaden, 1897. See Fig. 249.

197 Ammann, E. Das Vererbungsgesetz der Hämophile bei der Nachtblindheit. *Correspondenz-Blatt f. Schweizer Aerzte.* Bd. xxviii., S. 623—626. Basel, 1898. See Fig. 332.

198 Bruner, W. E. Ring scotoma with night-blindness. *Ophthalmic Record.* Vol. vii., pp. 556—560. Chicago, 1898. [Very detailed account of an individual case is given; family history negative.]

199 Bullar, J. F. Deficiency of the choroid. *Trans. of Ophthalmological Society of United Kingdom.* Vol. xviii., pp. 183, 184. London, 1898. See Fig. 253.

200 Haas, J. Ueber das Zusammenvorkommen von Veränderungen der Retina und Chorioidea. *Archiv f. Augenheilkunde.* Bd. xxxvii., S. 343—348. Wiesbaden, 1898.

201 Schön. Die Ursache der Retinitis pigmentosa. *Centralblatt f. praktische Augenheilkunde.* Bd. xxii., S. 15—18. Leipzig, 1898. See Fig. 13.

202 Hansell, H. F. A case of atypical retinitis pigmentosa. *American Journal of Ophthalmology.* Vol. xvi., pp. 153—155. St Louis, Mo., 1899. [Discusses briefly a classification of retinitis pigmentosa and allied diseases; describes case of retinitis pigmentosa in child of ten.]

203 Herrlinger, C. L. Über die Ätiologie der Retinitis pigmentosa. Pp. 7—29. Inaugural Dissertation. Tübingen, 1899. See Figs. 24, 25, 28, 51, 61, 94, 98, 102—104, 112.

204 Krückmann, E. Die pathologischen Veränderungen der retinalen Pigmentepithelzellen. *Archiv f. Ophthalmologie.* Bd. xlviii., Abth. ii., S. 237—282. Leipzig, 1899.

205 Levinsohn, G. Ueber Sclerose der Aderhaut mit secundärer Netzhautdegeneration. *Archiv f. Augenheilkunde.* Bd. xxxviii., S. 268—273. Wiesbaden, 1899.

*206 Rodsewitsch. Ein Fall von Pigmentdegeneration der Netzhaut ohne Pigment. *Voyenno-Meditsinskiy Jurnal.* x., p. 468. Reference and abstract in *Jahresbericht d. Ophthalmologie f.* 1899. Bd. xxx., S. 665, 666. Tübingen, 1901. See Fig. 241.

207 Scimemi, E. Di una speciale pigmentazione del fondo oculare. *Annali di Ottalmologia.* Anno xxviii., pp. 649–674. Pavia, 1899. See Fig. 31.

208 Thompson, J. T. Congenital deficiency of choroid. *Trans. of Ophthalmological Society of United Kingdom.* Vol. xix., pp. 140, 141. London, 1899. See Fig. 263.

209 Bednarski, A. Ueber einen Fall von *Atrophia gyrata chorioideae et retinae* mit Sclerose der Aderhaut. *Archiv f. Augenheilkunde.* Bd. xl., S. 420—426. Wiesbaden, 1900.

210 Byers, W. G. M. An atypical case of retinitis pigmentosa. *American Journal of Ophthalmology.* Vol xvii., pp. 11—15. St Louis, Mo., 1900.

211 Dean, L. W. The prenatal degeneracy of the eye. *Ophthalmic Record.* Vol. ix., pp. 433—447. Chicago, 1900. See Figs. 36, 70, 93.

212 Hutchinson, J. Slowly progressive Paraplegia and disease of the choroids, with defective intellect and arrested sexual development in several brothers and a sister—the disease beginning in childhood. Several other brothers quite healthy. Father the subject of obscure disease of the nervous system, ending with ?cerebral haemorrhage. *Archives of Surgery.* Vol. xi., pp. 118—122. London, 1900. See Fig. 267.

213 Rosenbaum, O. Ueber Retinitis pigmentosa. Pp. 5—22. Inaugural Dissertation. Kiel, 1900. See Figs. 37, 45, 54, 82, 106, 109, 126, 127.

214 Blessig, E. Alternirendes Auftreten von Glaukoma simplex und Retinitis pigmentosa an einer Reihe von Geschwistern. *St Petersburger medizinische Wochenschrift.* Bd. xxvi., S. 105, 106. St Petersburg, 1901. See Fig. 246.

215 Gonin, J. Le scotome annulaire dans la dégénérescence pigmentaire de la rétine. *Annales d'Oculistique.* T. cxxv., pp. 101—130. Paris, 1901. See Figs. 89, 108.

216 Spengler, E. Eine ungewöhnliche Aderhautnetzhautveränderung auf congenitaler Basis. *Zeitschrift f. Augenheilkunde.* Bd. vi., S. 285—292. Berlin, 1901. See Fig. 272.

216 a Thompson, A. H. Superficial choroidal atrophy, without subjective symptoms in a member of a family subject to night-blindness. *Trans. of Ophthalmological Society of United Kingdom.* Vol. xxi., pp. 66—68. London, 1901. See Fig. 203.

217 Wuestefeld, F. Zur Casuistik der Retinitis punctata albescens. *Zeitschrift f. Augenheilkunde.* Bd. v., S. 110—115. Berlin, 1901. See Fig. 283.

218 Gonin, J. Nouvelles observations de scotome annulaire dans la dégénérescence pigmentaire de la rétine. *Annales d'Oculistique.* T. cxxviii., pp. 90—107. Paris, 1902. See Figs. 43, 53, 92, 182.

219 Aubineau. Rétinite pigmentaire congénitale familiale. *Annales d'Oculistique.* T. cxxix., pp. 432—439. Paris, 1903. See Fig. 176.

220 Cuperus, N. J. Ueber primäre Atrophie der Aderhaut mit Sclerose der Gefässe: "*Atrophia alba chorioideae.*" *Archiv f. Augenheilkunde.* Bd. xlviii., S. 235—242. Wiesbaden, 1903. See Fig. 285.

221 Ginsberg, S. Grundriss der pathologischen Histologie des Auges. Berlin, 1903. [The pathology of retinitis pigmentosa is considered pp. 341—343.]

222 Gonin, J. Examen anatomique d'un œil atteint de rétinite pigmentaire avec scotome zonulaire. *Annales d'Oculistique.* T. cxxix., pp. 24—48. Paris, 1903.

223 Greeff, R. Retinitis pigmentosa. Orth's *Lehrbuch der speciellen pathologischen Anatomie.* Bd. x., S. 376—380. Berlin, 1903.

224 Hudson, A. Notes of a case of congenital night-blindness. *The Ophthalmoscope.* Vol. i., pp. 89, 90. London, 1903. See Fig. 304.

225 Lister, W. T. A case of retinitis pigmentosa with pathological report. *Royal London Ophthalmic Hospital Reports.* Vol. xv., Part iii., pp. 254—259. London, 1903.

226 Pyle, W. L. An interesting case of pigmentary degeneration of the retina. *Trans. of American Ophthalmological Society.* Vol. x., pp. 172—175. Washington, 1903. [Describes a typical case of retinitis pigmentosa which is said to be the only case of sericus ocular disease in a careful family history extending over a century. No consanguinity.]

227 Snell, S. Numerous instances of night-blindness (retinitis pigmentosa) occurring in five generations with genealogical chart. *Trans. of Ophthalmological Society of United Kingdom.* Vol. xxiii., pp. 68—70. London, 1903. See Fig. 3.

228 Stein, L. Zur pathologischen Anatomie und Differentialdiagnose der Chorioretinitis syphilitica und der Retinitis pigmentosa. *Archiv f. Ophthalmologie,* Bd. lvi., S. 463—486. Leipzig, 1903.

229 Abelsdorff, G. Diseases of the eye in relation to marriage with especial regard to heredity. In "Health and Disease in relation to marriage and the married state," edited by Senator and Kaminer. Vol. ii., pp. 677—696. Translated, New York, 1904. See Fig. 222.

*230 Bessonnet. Héméralopie héréditaire sans lésions rétiniennes. *Annales medico-chirurgicales du Centre.* Mai 1904. Abstract in *Recueil d'Ophthalmologie.* Sér. 3, Vol. xxiv., pp. 505, 506. Paris, 1904. See Fig. 314.

231 Galezowski, J. Rétinite ponctuée albescente congénitale. *Recueil d'Ophthalmologie.* Sér. 3, Vol. xxiv., pp. 714—723. Paris, 1904. See Fig. 284.

232 Schmidhäuser, F. Retinitis pigmentosa und Glaucom. Pp. 5—24. Inaugural Dissertation. Tübingen, 1904.

233 Jackson, E. A type of degeneration involving the central zone of the choroid and retina. *Trans. of American Ophthalmological Society.* Vol. x., pp. 150—153. Hartford, 1905. See Fig. 264.

234 Pascheff, C. Retinitis punctata albescens. *Ophthalmic Review.* Vol. xxiv., pp. 65—69. London, 1905.

235 Sinclair, W. W. Hereditary congenital night-blindness without visible ophthalmoscopic changes. *Ophthalmic Review.* Vol. xxiv., pp. 255—258. London, 1905. See Fig. 300.

236 Studer, T. F. Ueber Netzhautpigmentierung nach Resectio opticociliaris beim Menschen. *Archiv f. Augenheilkunde.* Bd. liii., S. 206—238. Wiesbaden, 1905.

237 Landman, O. Ein Fall von symmetrischem angeborenem Mangel der Chorioidea und der Retina ausserhalb der Maculargegend. *Archiv f. Augenheilkunde.* Bd. liv., S. 63—68. Wiesbaden, 1906. [An isolated case is described, no family history is given.]

238 Nettleship, E. Some hereditary diseases of the eye. *The Ophthalmoscope.* Vol. iv., pp. 493—506, 550—556. London, 1906.

239 Takayasu, M. Zur Kasuistik der Retinitis punctata albescens. *Archiv f. Ophthalmologie.* Bd. lxiii., S. 281—286. Leipzig, 1906. See Fig. 279.

240 Cabannes. Des relations de la rétinite pigmentaire fruste avec la névrite optique rétro-bulbaire héréditaire. *Archives d'Ophthalmologie.* T. xxvii., pp. 642—650. Paris, 1907. See Fig. 228.

241 Van Duyse. Trois cas de rétinite ponctuée albescente typique et familiale. *Archives d'Ophthalmologie.* T. xxvii., pp. 497—510. Paris, 1907. Fig. 269.

242 Gradle, H. Further observations on retinitis punctata. *Journal of American Medical Association.* Vol. xlix., pp. 301—303. Chicago, 1907. [Describes a case of retinitis punctata albescens seen, in a woman aged 29, associated with pigmentation of the retinal periphery and with night-blindness; eight years later the night-blindness had progressed to some extent, the retinal pigmentation was unchanged, but the white spots had disappeared.]

243 Nettleship, E. A history of congenital stationary night-blindness in nine consecutive generations. *Trans. of Ophthalmological Society of United Kingdom.* Vol. xxvii., pp. 269—293. 1907. See Fig. 317.

244 Snell, S. Retinitis pigmentosa occurring in several members of a family. *Trans. of Ophthalmological Society of United Kingdom.* Vol. xxvii., pp. 217—219. London, 1907. See Fig. 50.

245 Bordley, J. A family of hemeralopes. *Johns Hopkins Hospital Bulletin.* Vol. xix., pp. 278—281. Baltimore, 1908. See Fig. 6.

246 Gebb, H. Ueber punktförmige Aderhautatrophie und Pigmentirung. *Archiv f. Augenheilkunde.* Bd. lix., S. 383—388. Wiesbaden, 1908. [Isolated case described with coloured plate of fundus.]

247 Ginsberg, S. Ueber Retinitis pigmentosa. *Klinische Monatsblätter f. Augenheilkunde.* Bd. xlvi., pp. 1—10. Stuttgart, 1908.

248 Grossmann, E. Kongenitaler Herzfehler, familiäre Polydaktylie und Retinitis pigmentosa. *Wiener medizinische Wochenschrift.* Bd. lviii., S. 741—746. Wien, 1908. See Fig. 237.

249 Hepburn, M. L. The visual fields in pigmentary degeneration of the retina. *Trans. of Ophthalmological Society of United Kingdom.* Vol. xxviii., pp. 255—286. London, 1908.

250 Knape, E. V. Pigmentation of the retina from the vitreous chamber. Typical retinitis pigmentosa. *Archives of Ophthalmology.* Vol. xxxvii., pp. 574—587. New York, 1908.

251 Nettleship, E. On retinitis pigmentosa and allied diseases. *Royal London Ophthalmic Hospital Reports.* Vol. xvii. Part i., pp. 1—56. Part ii., pp. 151—166. Part iii., pp. 333—426. London, 1908. See Figs. 1 b, 5, 18, 19, 20, 22, 23, 27, 30, 32, 35, 40, 44, 47, 52, 63, 66, 67, 75, 84, 85, 87, 100, 120, 121, 123, 125, 186, 211, 215, 218, 219, 224, 225, 227, 240, 274—276, 278, 312, 313, 319, 323, 324, 327, 328.

252 Parsons, J. H. The pathology of the eye. London, 1904—1908. See Vol. ii., pp. 602—607, Vol. iv., pp. 1399—1402.

253 Parsons, J. H. Night-blindness. *The Lancet.* Vol. i. for 1908, pp. 555, 556. London, 1908.

254 Reuter, H. Beitrag zur Kenntniss der einseitigen Retinitis pigmentosa. *Archiv f. Augenheilkunde.* Bd. lx., S. 59—62. Wiesbaden, 1908.

255 Stock, W. Ueber eine bis jetzt noch nicht beschriebene Form der familiär auftretenden Netzhautdegeneration bei gleichzeitiger Verblödung und über typische Pigmentdegeneration der Netzhaut. *Klinische Monatsblätter f. Augenheilkunde.* Bd. xlvi., S. 225—244. Stuttgart, 1908.

256 Wernicke, O. *Atrophia gyrata chorioideae et retinae. Archiv f. Augenheilkunde.* Bd. lxii., S. 239—245. Wiesbaden, 1908. See Fig. 265.

257 Axenfeld, T. Bemerkungen über Retinitis pigmentosa, besonders solche ohne Hemeralopie. *Klinische Monatsblätter f. Augenheilkunde.* Beilageheft. Bd. xlvii., ii., S. 53—66. Stuttgart, 1909. [A beautiful coloured plate of the fundus is given and an interesting case is described with no information concerning family history.]

258 Gebb, H. Zur Casuistik der *Retinitis pigmentosa sine pigmento. Archiv f. Augenheilkunde.* Bd. lxiv., S. 204—208. Wiesbaden, 1909. See Fig. 16.

259 Krauss, W. Zur Kasuistik des Ringskotoms bei der Retinitis pigmentosa. *Zeitschrift f. Augenheilkunde.* Bd. xxi., S. 48—50. Berlin, 1909. [Family history negative.]

260 Lauber, H. Die sogenannte Retinitis punctata albescens. *Klinische Monatsblätter f. Augenheilkunde.* Bd. xlviii., S. 133—148. Stuttgart, 1910. See Fig. 270.

261 Loeb, C. Hereditary blindness and its prevention. *Annals of Ophthalmology.* Vol. xviii., pp. 1—47, 489—547, 755—789. St Louis, Mo., 1909. See Figs. 174, 198, 223, 289.

262 Merzbacher, L. Gesetzmässigkeiten in der Vererbung und Verbreitung verschiedener hereditär-familiärer Erkrankungen. *Archiv f. Rassen- u. Gesellschafts-Biologie.* Bd. VI., S. 172–198. Leipzig, 1909.

263 Nettleship, E. The Bowman lecture on some hereditary diseases of the eye. *Trans. of Ophthalmological Society of United Kingdom.* Vol. XXIX., pp. LVII–CXCVIII. London, 1909. See Figs. 156, 213, 311, 322.

264 Wilbrand, H. and Saenger, A. Die Neurologie des Auges. Bd. IV., pp. 71—117. Wiesbaden, 1909. See Figs. 105, 110, 111, 115, 189, 202, 229, 239.

265 Alexander, E. W. Congenital absence of the choroid with retinitis pigmentosa, and report of a case. *Ophthalmology.* Vol. VI., pp. 343—350. Seattle, Wash., 1910. See Fig. 255. [We are greatly indebted to the Secretary of the Washington Medical School at Seattle and to Miss E. Dawson for a manuscript copy of this paper.]

266 Chaillous, F. La rétinite pigmentaire chez les sourds-muets. *Annales d'Oculistique.* T. CXLIV., pp. 97—103. Paris, 1910. See Figs. 177, 179.

267 Dor, L. Chorio-rétinite pigmentaire familiale. *La Clinique Ophtalmologique.* T. XVI., pp. 60—63. Paris, 1910. See Fig. 256.

268 Doyne, R. W. Retinitis pigmentosa. *The Ophthalmoscope.* Vol. VIII., pp. 505, 506. London, 1910.

269 Hess, C. Studies concerning hemeralopia. *Archives of Ophthalmology.* Vol. XXXIX., pp. 482—495. New York, 1910.

270 Magitot, A. Étude sur le développement de la rétine humaine. *Annales d'Oculistique.* T. CXLIII., pp. 241—282. Paris, 1910.

271 Ormond, A. W. Retinitis pigmentosa and night-blindness. *Guy's Hospital Gazette.* Vol. XXIV., pp. 445—447, 479, 480. London, 1910.

272 Holloway, T. B. Retinitis pigmentosa associated with albuminuric neuroretinitis. *Trans. of American Ophthalmological Society.* Vol. XII., pp. 972–977. Philadelphia, 1911. See Fig. 184.

273 Jennings, J. E. Unilateral retinitis pigmentosa. *Annals of Ophthalmology.* Vol. XX., pp. 707—709. St Louis, Mo., 1911. [In a woman aged 35 the field of the right eye was contracted to within 8° of the fixation point, the field of the left eye was full; the fundus of the right eye showed a pale disc, diminished vessels and a few small specks of pigment at the extreme periphery; the fundus of the left eye was normal. Family history negative.]

274 Von Kries, J. Ueber die Funktionsteilung im Sehorgan und die Theorie der Nachtblindheit. *Klinische Monatsblätter f. Augenheilkunde.* Bd. XLIX., i., S. 241—269. Stuttgart, 1911.

275 Lutz, A. Ueber eine Familie mit hereditärer-familiärer Chorio-Retinitis. *Klinische Monatsblätter f. Augenheilkunde.* Bd. XLIX., S. 699—703. Stuttgart, 1911.

276 Magnusson, H. Ueber Retinitis pigmentosa und Konsanguinität beim Hunde. *Archiv f. vergleich. Ophthalmologie.* Bd. II., S. 147—163. Leipzig, 1911. See Fig. 185.

277 Pöllot, W. Atypische Chorioretinitis pigmentosa hereditaria. *Archiv f. Ophthalmologie.* Bd. LXXX., S. 379—394. Leipzig, 1911. See Fig. 257.

278 Tobias, G. Ein Beitrag zur Vererbungsmöglichkeit erworbener Augendefekte. *Klinische Monatsblätter f. Augenheilkunde.* Bd. XLIX., S. 212—216. Stuttgart, 1911.

279 Wittmer, H. Ein Beitrag zur Kenntniss der anomalen Formen der Retinitis pigmentosa. *Archiv f. Augenheilkunde.* Bd. LXVIII., S. 82—86. Wiesbaden, 1911. [The anomaly consists in the bilateral development of a clearly defined ring of dense pigmentation, typical of retinitis pigmentosa with the remaining parts of the fundi wholly normal. Family history negative.]

280 Greeves, R. A. Report of a case of retinitis pigmentosa with pathological investigation. *Royal London Ophthalmic Hospital Reports.* Vol. XVIII., Part III., pp. 301—309. London, 1912.

281 Lenz, F. Über die krankhaften Erbanlagen des Mannes und die Bestimmung des Geschlechts beim Menschen. Untersuchungen über somatische und idioplasmatische Korrelation zwischen Geschlecht und pathologischer Anlage mit besonderer Berücksichtigung der Hämophilie. Pp. 1—170. Jena, 1912.

282 Nettleship, E. A pedigree of congenital night-blindness with myopia. *Trans. of Ophthalmological Society of United Kingdom.* Vol. XXXII., pp. 21—45. London, 1912. See Fig. 320.

283 Oguchi, C. Über die eigenartige Hemeralopie mit diffuser weissgraulicher Verfärbung des Augenhintergrundes. *Archiv f. Ophthalmologie.* Bd. LXXXI., S. 109—117. Leipzig, 1912. See Figs. 258, 259, 261.

*284 Pons, Marqués L. Ectasia corneal, retinitis pigmentaria y atrofia óptica congénitas en tres hermanas. *Arch. de Oftal. Hispano-Am.* Vol. XII., pp. 581—586. Barcelona, 1912. See Fig. 296.

285 Shoemaker, J. F. *Retinitis pigmentosa sine pigmento. American Journal of Ophthalmology.* Vol. XXIX., pp. 36—40. St Louis, Mo., 1912. [Family history negative; case is described in which fields are contracted to within 5° of fixation point with no development of visible pigment in the retina.]

286 Suganuma, S. Ein Beitrag zur Kenntnis der Pathologie der Pigmentdegeneration der Netzhaut. *Klinische Monatsblätter f. Augenheilkunde.* Bd. L., S. 175—184. Stuttgart, 1912. [Describes the microscopic appearance of an eye with retinitis pigmentosa which had been enucleated for some other condition. No family history.]

*287 Carpenter, M. W. Three cases of retinitis pigmentosa in same family. *Cleveland Medical Journal.* Vol. XII., p. 762. Cleveland, 1913. Abstract seen in *The Ophthalmic Year Book.* Vol. X., p. 228. Denver, 1914. See Fig. 199.

288 Fergus, A. Freeland. Subjective colour sensations in retinitis pigmentosa. *Ophthalmic Review.* Vol. XXXII., pp. 1—3. London, 1913. See Fig. 118.

289 Frenkel, H. and Dide, M. Rétinite pigmentaire avec atrophie papillaire et ataxie cerebelleuse familiales. *Revue Neurologique.* T. xxv., pp. 729—734. Paris, 1913. See Fig. 48.

290 Goldberg, H. G. Choroideremia. *Trans. of College of Physicians of Philadelphia.* 3rd Ser., Vol. xxxv., pp. 414—416. Philadelphia, 1913. See Fig. 254.

291 Van der Hoeve, J. Oogafwijkingen bij doofstomheid. *Nederlandsch Tijdschrift voor Geneeskunde.* J. lvii., S. 664—671. Amsterdam, 1913. See Fig. 178.

292 Lohmann, W. Disturbances of the visual functions. Translated by Angus Macnab. pp. 62—64. London, 1913.

293 McKee, H. Retinitis pigmentosa: a pathological report. *The Ophthalmoscope.* Vol. xi., pp. 408—411. London, 1913.

294 Oliver, G. H. Thirteen cases of hereditary transmission of retinitis pigmentosa in two generations. *The Ophthalmoscope.* Vol. xi., pp. 407, 408. London, 1913. See Fig. 60.

295 Oliver, G. H. Hyaline bodies at the optic disc in a case of retinitis pigmentosa. *The Ophthalmoscope.* Vol. xi., pp. 716—718. London, 1913. [Gives a beautiful coloured plate of the fundi in a case associated with epilepsy, deafness, mental weakness and stammering; the patient was the child of first cousins; family history negative.]

296 Diem, M. Retinitis punctata albescens et pigmentosa. *Klinische Monatsblätter f. Augenheilkunde.* Bd. liii., S. 371—379. Stuttgart, 1914. See Fig. 280.

297 Komoto, J. Ueber die sog. *Atrophia gyrata chorioideae et retinae. Klinische Monatsblätter f. Augenheilkunde.* Bd. lii., S. 416—421. Stuttgart, 1914. [Describes a case in one of six children the offspring of normal consanguineous parents; no eye disease was known in the family.]

298 Lindner, K. Über einen Fall von Hemeralopie mit weissgrau-verfärbtem Fundus. *Archiv f. Ophthalmologie.* Bd. lxxxviii., S. 251—258. Leipzig, 1914. See Fig. 286.

299 Nettleship, E. A note on the progress of some cases of *retinitis pigmentosa sine pigmento* and of retinitis punctata albescens. *Royal London Ophthalmic Hospital Reports.* Vol. xix., Part ii., pp. 123—129. London, 1914. See Figs. 274, 276.

300 Newman, H. H. Five generations of congenital stationary night-blindness in an American family. *Journal of Genetics.* Vol. iii., pp. 25—38. Cambridge, 1914. See Fig. 321.

301 Usher, C. H. On the inheritance of retinitis pigmentosa with notes of cases. *Royal London Ophthalmic Hospital Reports.* Vol. xix., Part ii., pp. 130—236. London, 1914. See Figs. 133—155, 157—173.

302 Augstein, C. Kriegserfahrungen über Hemeralopie und Augenhintergrund. *Klinische Monatsblätter f. Augenheilkunde.* Bd. lv., S. 474—488. Stuttgart, 1915.

303 Bane, W. C. Retinitis Pigmentosa. *Annals of Ophthalmology.* Vol. xxiv., p. 587. St Louis, Mo., 1915. See Fig. 204.

304 Langdon, H. M. Hereditary deficiency of the light sense in otherwise healthy eyes, with report of a case. *Annals of Ophthalmology.* Vol. xxiv., pp. 469—473. St Louis, Mo., 1915. See Fig. 309.

305 Mayou, M. S. A case of retinitis pigmentosa treated by trephining. *Trans. of Ophthalmological Society of United Kingdom.* Vol. xxxv., pp. 357—363. London, 1915. See Fig. 64.

306 Birch-Hirschfeld, A. Nyctalopia. *Journal of American Medical Association.* Vol. lxvii., pp. 1952, 1953. Chicago, 1916.

307 Bradburne, A. A. Retinitis pigmentosa in five sisters with glaucoma in three of them. *Ophthalmic Review.* Vol. xxxv., pp. 65—70. London, 1916. See Fig. 247.

308 Carruthers, J. F. Case of retinitis pigmentosa (atypical) with oedema of the macula. *Proc. Roy. Soc. of Med.* Vol. ix., Sect. of Ophthalmology, pp. 103—105. London, 1916. See Fig. 243.

308 a Cohen, M. Two cases of retinitis punctata albescens. Reported in *Archives of Ophthalmology.* Vol. xlv., pp. 373, 374. New York, 1916. See Fig. 282.

309 Mayou, M. S. A case of retinitis pigmentosa treated by trephining. *Trans. of Ophthalmological Society of United Kingdom.* Vol. xxxvi., pp. 350—352. London, 1916. See Fig. 64.

310 Smith, H. E. and Usher, C. H. Choroideremia and two other varieties of night-blindness in the same pedigree. *Royal London Ophthalmic Hospital Reports.* Vol. xx., pp. 157—174. London, 1916. See Fig. 119.

311 Weekers, L. Night-blindness (Hemeralopia). *Medical Press and Circular.* Vol. ii. for 1916, pp. 386, 387. London, 1916.

312 Weekers, L. L'héméralopie chez les soldats. *Archives d'Ophtalmologie.* T. xxxv., pp. 73—88. Paris, 1917.

313 Hansen, S. Om Retinitis pigmentosa og dens hereditaere aekvivalenter. *Hospitalstidende.* Nr. xli., pp. 1377—1384. København, 1918.

314 Jones, E. L. Relation of retinitis pigmentosa and allied conditions to the ductless glands. *American Journal of Ophthalmology.* Ser. 3, Vol. i., pp. 107—114. Chicago, 1918. [Several incomplete family histories are given; the author describes a case of retinitis pigmentosa in a mulatto girl aged 15, the only case he had ever seen in the coloured race.]

315 Voorhoeve, N. Blue sclerotics in connection with other hereditary or congenital abnormalities. *The Lancet.* Vol. ii. for 1918, pp. 740, 741. London, 1918.

316 Agatston, S. A. Retinitis punctata albescens. *Archives of Ophthalmology.* Vol. xlviii., pp. 294, 295. New York, 1919. [Case described in a girl aged 19; family history negative; Wassermann negative.]

317 Böhm, F. M. Ueber einen eigentümlichen Fall von Retinitis pigmentosa mit Atrophie der Aderhaut (*Atrophia gyrata choroideae et retinae*). *Klinische Monatsblätter f. Augenheilkunde.* Bd. LXIII., S. 381—386. Stuttgart, 1919. See Fig. 221.

318 Collins, E. Treacher. Abiotrophy of the retinal neuro-epithelium or "retinitis pigmentosa." *Trans. of Ophthalmological Society of United Kingdom.* Vol. XXXIX., pp. 165—195. London, 1919.

319 Connor, A. B. Congenital choroideremia. *American Journal of Ophthalmology.* Ser. 3, Vol. II., pp. 553—555. Chicago, 1919.

320 Roy, J. N. The eyesight of the Negroes of Africa. *Archives of Ophthalmology.* Vol. XLVIII., pp. 72—83. New York, 1919.

321 Vogt, A. Vererbung in der Augenheilkunde. *Münchener Medizinische Wochenschrift.* Bd. LXVI., S. 1—5. Munich, 1919.

322 Elliot, R. H. Tropical Ophthalmology, p. 390. London, 1920.

323 Zorn, B. Über familiäre atypische Pigmentdegeneration der Netzhaut (totale Aderhautatrophie). *Archiv f. Ophthalmologie.* Bd. CI., S. 1—13. Berlin, 1920. See Fig. 262.

324 Healy, J. J. Retinitis punctata albescens. *British Journal of Ophthalmology.* Vol. V., pp. 18, 19. London, 1921. See Fig. 281.

325 Lievens, E. Chorio-rétinite albescente ponctuée et pigmentaire. *Annales d'Oculistique.* T. CLVIII., pp. 829—838. Paris, 1921. [Typical retinitis punctata albescens in one, possibly in two males in a sibship of sixteen; the parents were normal and unrelated.]

326 Mohr, T. Einseitige Retinitis pigmentosa. Vereinigung der Augenärzte Schlesiens und Posens. Report in *Klinische Monatsblätter f. Augenheilkunde.* Bd. LXVI. S. 927. Stuttgart, 1921.

327 Mücke, R. Ein Beitrag zur Vererbung der Retinitis pigmentosa. *Klinische Monatsblätter f. Augenheilkunde.* Bd. LXVI., S. 562—568. Stuttgart, 1921. See Fig. 212.

328 Stockard, C. R. Developmental rate and structural expression: an experimental study of twins, "double monsters" and single deformities, and the interaction among embryonic organs during their origin and development. *The American Journal of Anatomy.* Vol. XXVIII., pp. 115—277. Philadelphia, 1921.

NAME INDEX TO CHRONOLOGICAL BIBLIOGRAPHY AND TO AUTHORS OF PEDIGREES

Abelsdorff (229, Fig. 222), Actuarius (8), Aetius (4), Agatston (316), Alexander (265, Fig. 255), Alsaharavius (7), Alt (101), Ammann (197, Fig. 332), Ammon (26), Ancke (132, Fig. 65), Atwool (180, Fig. 308), Aubineau (219, Fig. 176), Augstein (302), Axenfeld (257), Ayres (138, 169, Figs. 46, 72, 130, 131, 231, 244, 250).

Badal (108), Bader (93), Bampfield (23), Bane (303, Fig. 204), Baumeister (79), Bayer (75, Figs. 33, 183), Bednarski (209), Bellarminoff (172, Fig. 245), Bergen (20), Berlin (71), Bessonnet (230, Fig. 314), Biervliet (48), Birch-Hirschfeld (306), Blessig (214, Fig. 246), Böhm (317, Fig. 221), Bontius (13), Bordley (245, Fig. 6), Boyer (29), Bradburne (307, Fig. 247), Brochard (45), Bruner (198), Bruns (185), Bürstenbinder (181), Bullar (199, Fig. 253), Burnett (118), Byers (210).

Cabannes (240, Fig. 228), Cant (139, Fig. 97), Capauner (173), Carpenter (287, Fig. 199), Carruthers (308, Fig. 243), Celsus (3), Chaillous (266, Figs. 177, 179), Chibret (128), Cohen (308 A, Fig. 282), Treacher Collins (318), Connor (319), Cowell (111, Fig. 10), Cowgill (170), Cunier (27, 28, Fig. 317), Cuperus (220, Fig. 285), Cutler (177, 182, Figs. 266, 302, 306, 325).

Darier (148, Figs. 190, 194, 195, 205, 214), Davidson (140), Dean (211, Figs. 36, 70, 93), Derby (149, Figs. 81, 113), Derigs (112, Figs. 180, 183, 196, 235, 236, 242), Deutschmann (165), Dide (289, Fig. 48), Diem (296, Fig. 280), Donders (33, 36, Fig. 330), Dor (119, 267, Fig. 256), Doyne (268), Dumont (34), Duvez (96), Duyse (241, Fig. 269).

Ebers (1), Elliot (322), Etmuller (16).

Featherstonhaugh (150), Fergus (288, Fig. 118), Fitzgerald (80, Fig. 310), Förster (37, Fig. 329), Forest (9), Frenkel (289, Fig. 48), Frickenhaus (81, Fig. 219), Frost (186), Fuchs (187).

Galezowski (231, Fig. 284), Gayet (120, Fig. 271), Gebb (246, 258, Fig. 16), Germaix (174), Ginsberg (221, 247), Goldberg (290, Fig. 254), Goldzieher (193, Fig. 251), Gonin (215, 218, 222, Figs. 43, 53, 89, 92, 108, 182), Gould (194, Fig. 59), Gradle (242), Graefe (35, 38), Greeff (223), Greenhill (109), Greeves (280), Griffith (195, Fig. 273), Grossmann (248, Fig. 237), Guillemeau (12), Guthrie (22).

Haas (200), Hansell (202), Hansen (313), Harlan (76, 82, Figs. 29, 62, 117), Healy (324, Fig. 281), Heinersdorff (196, Fig. 249), Hepburn (249), Herrlinger (203, Figs. 24, 25, 28, 51, 61, 94, 98, 102—104, 112), Hess (269), Hirschberg (106), Hocquard (89, Fig. 7), Hoefer (15), Höring (49, Fig. 114), Holloway (272, Fig. 184), Hoeve (291, Fig. 178), Hosch (90), Hudson (224, Fig. 304), Huidiez (97, Fig. 8), Hutchinson (54, 65—67, 113, 212, Fig. 267).

Jackson (233, Fig. 264), Jacobsohn (155, Fig. 268), Jeffries (61, Figs. 192, 197), Jennings (188, 273), Jones (314), Junge (39).

Kaupp (162, Figs. 83, 226), Kerschbaumer (141, Fig. 233), Knape (250), Knapp (69), Koenig (86, Fig. 260), Komoto (297), Krauss (259), Kries (274), Krückmann (204).

Landesberg (121), Landman (237), Landolt (77, 160), Langdon (304, Fig. 309), Langenbeck (25), La Serre (18, Fig. 291), Lauber (260, Fig. 270), Lawrence (55, Fig. 267), Laycock (56, Fig. 238), Leber (68, 72, 98, Figs. 49, 116, 124, 129), Lee (122), Lenz (281), Levinsohn (205), Liebrecht (183), Liebreich (42, Figs. 80, 91), Lievens (325), Lindner (298, Fig. 286), Lister (225), Loeb (261, Figs. 174, 198, 223, 289), Lohmann (292), Lutz (275).

McCassey (189, Fig. 209), McCreight (190, Fig. 193), Machek (110, Fig. 175), McKee (293), Macnamara (166), Maes (43, Figs. 11, 55, 68, 71, 88, 330, 331), Magitot (270), Magnus (123, 133, 142, 143, Figs. 181, 232, 295), Magnusson (276, Fig. 185), Maitrejean (17), Mannhardt (62), Marlow (178), Mauthner (78, Fig. 287), Mayou (305, 309, Fig. 64), Mellinger (156, Fig. 78), Merzbacher (262), Mohr (326), Mooren (40, 47, 85, 114, Figs. 15, 56—58, 101), Morton (134, 175), Mouchot (63, Figs. 288, 293, 294), Mücke (327, Fig. 212).

Nettleship (99, 151, 152, 157, 238, 243, 251, 263, 282, 299, Figs. 1B, 5, 17—23, 27, 30, 32, 35, 40, 44, 47, 52, 63, 66, 67, 75, 84, 85, 87, 100, 120, 121, 123, 125, 156, 186, 211, 213, 215, 218, 219, 224, 225, 227, 240, 274—276, 278, 311—313, 317, 319, 320, 322—324, 327, 328), Neuffer (176, Figs. 187, 218), Newman (300, Fig. 321), Nolden (94, Figs. 33, 208), Nolte (191, Fig. 217).

Oakley (159, Figs. 86, 107, 128), Oeller (107), Oguchi (283, Figs. 258, 259, 261), Oliver (294, 295, Fig. 60), Ormond (271), Ovelgün (19, Fig. 292).

Pagenstecher (44, 102, Figs. 252, 318), Panas (103), Parinaud (130), Parsons (252, 253), Pascheff (234), Paulus Aegineta (6), Pedraglia (51), Peltesohn (158, Fig. 9), Perlia (153), Pflüger (124, Fig. 326), Picard (64, Fig. 77), Picqué (144), Pier d' Houy (100), Plemp (14), Pliny (2), Pöllot (277, Fig. 257), Poncet (91), Pons (284), Pope (46), Priestly Smith (115, Fig. 79), Pufahl (95, Fig. 234), Pye (21), Pyle (226).

Rampoldi (125, Fig. 290), Ransohoff (167, Fig. 69), Reinecke (179, Figs. 201, 206, 216), Reuter (254), Richter (24, Fig. 297), Riolan (11), Rodsewitsch (206, Fig. 241), Rooy (48), Rosenbaum (213, Figs. 37, 45, 54, 82, 106, 109, 126, 127), Roy (184, 320, Fig. 188), Ruete (32).

Schelske (87), Schenck (10), Schleich (135, 145), Schmidhäuser (232), Schmidt, E. (163, Figs. 14, 132, 220, 235), Schmidt, H. (88, Fig. 200), Schneider (192, Fig. 4), Schön (201, Fig. 13), Schultze (57, 73), Schweigger (41, 50, 92), Scimemi (207, Fig. 31), Sedan (136, Fig. 301), Shoemaker (285), Siegheim (146, Figs. 41, 95, 122), Simi (60, Fig. 38), Sinclair (235, Fig. 300), Smith, H. E. (310, Fig. 119), Snell (147, 227, 244, Figs. 3, 42, 50), Spengler (216, Fig. 272), Standish (154), Stein (228), Stiévenart (30, Fig. 305), Stock (255), Stockard (328), Stör (52), Studer (236), Suganuma (286), Swanzy (74, 83, Fig. 316).

Takayasu (239, Fig. 279), Thompson (208, 216A, Figs. 203, 263), Tobias (278), Tobin (131, Fig. 73), Trallianus (5), Trigt (31), Trousseau (171, Figs. 39, 230), Tweedy (116).

Ulrich (117, 126, Fig. 277), Usher (301, 310, Figs. 119, 133—173).

Vieusse (104, Fig. 315), Vogt (321), Voorhoeve (315).

Warlomont (96), Webster (105, Figs. 2, 12, 26, 74, 76, 90, 99), Wecker (58, 160), Weekers (311, 312), Wells (84), Wernicke (256, Fig. 265), Wider (137, Figs. 34, 96, 248), Wilbrand (264, Figs. 105, 110, 111, 115, 189, 202, 229, 239), Wilson (53), Windsor (70), Wittmer (279), Wuestefeld (217, Fig. 283).

Zimmermann (127), Zorn (323, Fig. 262).

SECTION IV

DESCRIPTIONS OF PEDIGREE PLATES

Pedigree 1 a. *Nettleship's Case.* An extensive family history showing lamellar cataract, "Coppock" or discoid cataract and retinitis pigmentosa in different members of the same pedigree of six generations. See[1] *Treasury of Human Inheritance*, Vol. I., pp. 147—151, Plate xxxii., Fig. 342.

Plate I, Fig. 1 b. *Nettleship's Case.* Thirty-nine individuals affected with retinitis pigmentosa in seven generations. This family was under observation by Nettleship over a period of 24 years, 1883—1907, during which time he examined, in some cases repeatedly, seventeen members. He describes the history as follows: "Descent of the disease in this family was invariably continuous, no healthy pair ever having an affected child. The disease was transmitted by the father six times, by the mother eleven times.

"Not a single case of deaf-mutism, mental defect, or other degeneracy has occurred in this genealogy. The members have been occupied in various small trades or as artisans, and the ones I have seen were above the average of their class in intelligence. They are decidedly long lived.

"The now living head of the family, George Young, IV. 35 aged 66 (1905), has been blind from retinitis pigmentosa for many years....I saw him first in 1883 and 1884 when he was aged 44; the R. eye had then been blind for three years and presented a complete over-ripe cataract, the L. fundus was visible in spite of posterior cortical cataract, and showed extreme retinitis pigmentosa, there was still a little sight in this eye. He said he could not remember ever having seen well at night and believed his day vision had never been so good as that of other people, but he could see to go about easily by daylight till he was aged about 36 years. He was the fourth born of seven children, only one other, IV. 38, lived to grow up, he had good sight and died aged 36 of typhoid fever. IV. 34 and IV. 37 all died in infancy...IV. 35 had five children, V. 49—53 of whom two are normal, one died aged 16 months, and two boys have the family disease...V. 50 aged 11 (1883) had in each eye my. 6 D. and corrected V. $= \frac{2}{7}\frac{0}{0}$ and J. 1; he had a fair complexion, hair straw-coloured; no retinal pigmentation visible by indirect examination but by direct method at periphery a few grains of pigment in the retina and along one or two retinal veins; haze of retina at periphery, choroid at same part was dappled with palish spots; there was a slight loss of upper part of each field. In 1905 I saw him again with hair nearly black, irides brown, very abundant retinitis pigmentosa and posterior polar cataracts.

"V. 52 aged 5 (1884) had V. $= \frac{2}{1}\frac{0}{0}\frac{0}{0}$, improved to $\frac{2}{7}\frac{0}{0}$ by -1 D.; media and optic discs normal; choroid at equator showed round pale dots; some dots and lines of pigment in retina at inner periphery; a patch of complete atrophy of choroid at outer periphery in R. eye. In 1905 he had typical and abundant retinitis pigmentosa, he could still read and write but not easily. V. 49 aged 34 (1905) was examined and found to be normal....Their mother, IV. 36 aged about 65, told me that she used to know which of her children were affected almost when they were in arms, and that by the time they were about four years old the defect was evident enough; she considered that V. 53, who died aged 16 months, was unaffected.

"The others of this genealogy that I have examined are V. 26 and four of her five living children, VI. 30—36, all characteristically affected in different degrees; VI. 35 has been night-blind all her life; VI. 36 aged 22 has severe changes and has been night-blind as long as he can remember; VI. 30 aged $17\frac{1}{2}$ shows decided shrinking of retinal arteries and waxy haze of discs, he is distinctly night-blind according to the testimony of his friends, though he himself is reluctant to admit it. Note that this lad, VI. 30, slightly affected, is the issue of his mother's second marriage, the husband not being her cousin, whilst VI. 35 and 36 by her first husband, who was her cousin and of the affected stock, are both badly affected and have been night-blind as long as they can remember. VI. 22 aged 14 has dappling of choroid at periphery, slight typical pigmentation of retina and shrunken arteries, he cannot remember ever having seen well at night. V. 18 aged 35 had advanced typical changes. VI. 38 was examined, and the three children of V. 45 of whom the eldest, VI. 45 aged 20, has advanced changes, but can still read and sew well; she has about 9 D. of myopia.

"IV. 2 was seen by Mr Hutchinson at the age of 49 in 1869; he had been failing from boyhood but could then still read large letters and see to do his work; he died aged 86 in 1903.

"IV. 35 knows that his mother III. 12, who died aged 70 in 1876 having been blind for twenty years, two of her sisters III. 7 and 9 and her brother III. 1 were all night-blind and became quite blind. From these sources and from IV. 2 he learnt further that his mother's mother II. 2 and her mother I. 1 had the same complaint. III. 1, a local preacher in the Isle of Wight, lived to be 90 and died about the year 1876.

[1] No pedigree published in Vol. I. of the *Treasury of Human Inheritance* will be repeated in Vol. II.

"I have been able to examine III. 20, now aged 90 (1906), hale and active and with perfect eyes; his father, II. 5, had good sight so far as is known, he was a pilot and was drowned, aged 50 years, about 1817. II. 3, died aged 70, was blind for some years before her death but had good sight until she was well advanced in years.

"III. 14, who had only one child, died aged 40 (1855); IV. 25—33 all grew up and married; IV. 8—18 all grew up and their history is well known, none are affected; V. 19—21 consisted of nine children of whom the six eldest grew up and had good sight, the three youngest died in infancy, it is known that none of their children were affected." Consanguinity. Bibl. No. 251, pp. 7—10.

Fig. 2. *Webster's Case.* A girl aged 16 complaining of night-blindness was found to have retinitis pigmentosa with partial atrophy of the optic nerves; she had slight posterior polar cataract in the right lens; her defect had been noticed about the age of 10 years. Her parents were first cousins; her mother, I. 2, had had "weak eyes always." Consanguinity. Bibl. No. 105.

Fig. 3. *Snell's Case.* Twenty-nine cases of retinitis pigmentosa in five generations; night-blindness in all cases appears to have been present in early childhood or infancy; at about the age of 40 those affected became practically blind. IV. 10, aged 46 (1902), had never been able to see well at night, but in the day his eyesight had been fairly good until the last six years when it had rapidly become worse; for two years or more he had been altogether unable to do his work; R.V. $= \frac{2}{60}$, L.V. $= \frac{1}{60}$; the pigmentation of the retina was marked at the periphery, but did not extend towards the papilla so far as is often seen in such an advanced stage of the disease; the discs were white and waxy; in each eye there was a posterior polar opacity of the lens; the fields of vision were contracted to fixation point.

IV. 10 was remarkably well acquainted with all branches of the family. IV. 23 and one of his affected daughters were also examined; in each the condition was typical. No consanguinity. Bibl. No. 227.

Fig. 4. *Schneider's Case.* Retinitis pigmentosa in five generations. The members are described as being healthy and well developed with no sign of hereditary syphilis and no other defect. The ophthalmoscopic appearances of those examined was typical of the disease. I. 1, female, was "born blind" and died in 1852, aged 72. Of her three children, II. 2, a daughter, was night-blind from youth, totally blind at the age of 40 and died aged 65; II. 3, a son, was "born blind" and died aged 2 years; and II. 4, a son, became blind "from cold" at the age of 5 and died aged 7 years. III. 1, night-blind from childhood, had typical retinitis pigmentosa and also anterior and posterior polar cataracts; she had eleven children of whom IV. 2, 3 and 6 were normal and living; IV. 8 died aged 8 years with normal sight and five others, IV. 9, died in infancy. IV. 4 and IV. 7 were affected with retinitis pigmentosa. IV. 2 married and had two normal children, V. 1, 2. IV. 4 married and had three children of whom one, V. 4, aged 3 years had retinitis pigmentosa. The author describes the cases living in considerable detail. No consanguinity. Bibl. No. 192.

PLATE II. Fig. 5. *Nettleship's Case.* This pedigree is of interest as showing severe retinitis pigmentosa associated with no serious degree of night-blindness; a large part of the history was worked out by Major Kilkelly, but the author examined a very considerable number of the members. IV. 8, aged 44, was an intelligent man of outdoor habits; he had very good central acuity separated from a broad belt of peripheral vision by an incomplete ring scotoma which became much larger in a subdued light; he said that he never had difficulty at night, but a relation reported that she had thought for many years that he had some degree of the family blindness; his disease was severe as regards pigmentation of the retina. III. 14, aged 78, mother of IV. 8, had advanced retinitis pigmentosa with some haze of her lenses, but she could see to read until two or three years ago; she had never had difficulty in going about at night; she had lost several fingers of both hands from senile gangrene.

The disease was characterised in this family by its very slow progress and late maturity. No consanguinity. Bibl. No. 251, p. 360.

Fig. 6. *Bordley's Case.* Progressive night-blindness without retinal pigmentation, with symmetrical scotoma in temporal part of field, in five generations. This is a pedigree of great interest and, if it may be classed amongst the cases here being dealt with, is unique in several respects.

The condition is unusually dominant, for thirty-five of the forty-two descendants of I. 1 were known to be affected. The condition in the affected members is characterised by night-blindness, they all had to cease work when the sun set and artificial light only aided them if they were in its direct glare; their vision in good daylight was practically normal in their youth, though one man was myopic (2 D.). The fields of vision were examined for seven members of different branches of the family at different ages, in every case there was a complete loss of the outer lower quadrant of both fields, these scotomata were absolute and did not encroach upon the central portion of the fields; as the light was diminished the fields rapidly contracted until they were reduced to a small central area, for form only; as age increased the fields progressively contracted until the patient became totally blind, and shortly after this death occurred, not one case had lived longer than 16 months after becoming blind. After blindness had developed, the corneae ulcerated and the eyes became infected and were lost; in a case seen by the author, III. 6, there was found to be a loss of epithelium of the left cornea associated with complete anaesthesia of the cornea and the portion of that side of the face supplied by Trigeminus; later the right side became similarly affected and death from apoplexy occurred less than six months after the onset of blindness.

No strabismus or nystagmus were present.

Ophthalmoscopic examination revealed nothing abnormal in the very young children, but showed a very pronounced arterio-sclerosis in older members of the family; except for these rather early vascular changes, the fundi of all examined were perfectly normal, the papillae were normal, and the retinae were free from pigmentary disturbances.

The temporal arteries of even the children were very marked, and the radials were said to be quite stiff. The blood and urine were normal in all cases examined, the blood-pressure was not taken.

This was a negro family; all members were below the normal height, very muscular, intensely ignorant but prodigious workers. It was a misfortune that the author was able to get no record of any member of the family with normal sight having had children. No consanguinity recorded. Bibl. No. 245.

Fig. 7. *Hocquard's Case.* IV. 1, a soldier in an artillery regiment, aged 21 years, was intelligent and robust in general health but he suffered from congenital night-blindness, and was completely blind at night; his colour-sense was normal; his fields of vision were markedly contracted; ophthalmoscopic examination revealed little departure from the normal; there was some infiltration of the retina surrounding the papilla; choroidal vessels could be seen; retinal vessels were almost normal in size, and on the right side there was one oval spot of pigment only, along the trajectory of a vein, on the left side there were two or three grains of pigment of characteristic form present. The father, III. 2 aged 50, an uncle, III. 3 aged 47 years, also a great-uncle, II. 2 aged 79, were all sufferers from congenital retinitis pigmentosa; all other members of the family had excellent sight. No consanguinity. Bibl. Nos. 89, 91.

Fig. 8. *Huidiez' Case.* Retinitis pigmentosa *sine pigmento* in a child aged 8 years who had been under the observation of the author for five years. IV. 1 had very marked night-blindness which had apparently been congenital; visual fields were considerably contracted, central vision was good; some infiltration of the retina was described at the periphery and also surrounding the papilla, but no trace of pigment was visible ophthalmoscopically. Her maternal grandparents were first cousins, and further, a first cousin of the grandmother, aged 55, whose parents also were first cousins, had congenital night-blindness. Consanguinity. Bibl. No. 97.

Fig. 9. *Peltesohn's Case.* II. 2 seen, aged 21, reported that his sight had diminished during the last two years and that it was specially bad at night; he was found to have visual fields which were normal in a good light but were reduced to 10° round the fixation point in a dim light; the retinal vessels were a little narrowed but there was no trace of pigmentation to be seen. He was seen from time to time and the progress of the disease seemed to be rapid, for about three years later his fields were reduced to 5° and he had developed deposits typical of retinitis pigmentosa. He was deaf but was healthy in other respects. The parents were unrelated. His siblings were free from any eye trouble at the time of the first examination of II. 2 but two of them had since then developed night-blindness at about the same age as it appeared in the brother's case. A cousin, aged 30 years, suffered from the same affection. This is interesting as being an undoubted case in which *retinitis pigmentosa sine pigmento* was seen to develop into typical retinitis pigmentosa. No consanguinity. Bibl. No. 158.

Fig. 10. *Cowell's Case.* II. 5 could see well until about the age of 14 years when her sight appeared to fail and she could not see to read at night; soon after this she had scarlet fever, and a year later was unable to read in daylight; she complained of occasional flashes of light and frequent headaches, and when examined her vision was reduced to perception of light and large objects; she had slight nystagmus; the choroid was pale and patchy; the discs were yellowish white with blurred margins; the retinal vessels were small; retinitis pigmentosa was present with a slight amount of pigment only. Her four brothers and her parents were healthy and had good sight. No signs of syphilis were present. No consanguinity. Bibl. No. 111.

Fig. 11. *Maes' Case.* I. 1 and 2 were first cousins with normal eyes; they had six children, five sons and one daughter, of whom two sons, the second and fourth born, had retinitis pigmentosa. II. 2, G. B., was not examined, but it was reported that he suffered from night-blindness, that he had good sight by day, and that his condition was almost stationary; he was unmarried. II. 4, J. B., aged 43 years, suffered from night-blindness, and said that his sight had become worse year by year since the age of 18; he had subjective colour sensations when he was tired; his visual fields were contracted in a dim light; on ophthalmoscopic examination there was found pigmentation of the retina, a slightly atrophic disc, and a semi-transparent film with a few small flecks are described in the vitreous; there were posterior polar cataracts in both eyes. J. B. married and had three sons of whom the two eldest suffered from congenital retinitis pigmentosa. III. 1, E. B., a fair boy, aged 17, had good vision by daylight and had emmetropic eyes but he suffered from night-blindness and his fields were contracted in a dull light; in the retina there was no pigment to be seen but little white specks are described in the equatorial region. The second son, W. B., III. 2, was not examined, but according to the statement of his father he suffered from the same condition to a less severe degree. III. 3 was examined and found to be normal. Consanguinity. Bibl. No. 43.

Fig. 12. *Webster's Case.* Typical retinitis pigmentosa in III. 1. His mother, II. 1, had always seen

badly at night or in a darkened room but had no visible pigment deposits in her retina, she was probably a case of retinitis pigmentosa *sine pigmento*. Parents of III. 1 were first cousins once removed. Consanguinity. Bibl. No. 105.

Fig. 13. *Schön's Case.* Retinitis pigmentosa in a brother and two sisters, also in a daughter of one of the sisters. No information is given of normal members of the family. No consanguinity recorded. Bibl. No. 201.

Fig. 14. *E. Schmidt's Case.* In a sibship of eleven, the offspring of uncle and niece, three members had retinitis pigmentosa, one had kerectasia and the others were said to be myopic. III. 1, aged 21, a female, was said to have typical retinitis pigmentosa. III. 2, a male aged 19, had retinitis pigmentosa with concentric contraction of fields, V. = $\frac{1}{2}\frac{2}{0}$ in each, and also had *ectopia pupillae*. No further information is given. Consanguinity. Bibl. No. 163.

Fig. 15. *Mooren's Case.* II. 1 seen by the author when aged 3 years, had night-blindness and retinitis pigmentosa; he was seen again three years later when the amount of pigment did not appear to have increased but the night-blindness was worse; his mother's sister had five children who were not seen by the author but who were all reported to have either retinitis pigmentosa or congenital night-blindness. No consanguinity. Bibl. No. 114.

Fig. 16. *Gebb's Case.* Two first cousins, who were healthy and whose siblings and ancestors were as far as was known free from any history of inheritable eye disease or disease of the central nervous system, married and had three children II. 1—3. II. 1, a boy aged 6, was healthy but had seen very badly since birth, especially in the twilight; on examination of his eyes it was found that the media were clear; there was a medium degree of myopic astigmatism; the fundus was extremely pale, and the choroidal vessels could be clearly seen as in the case of albinism; the papilla was yellowish red in colour; the retinal vessels were markedly narrowed, especially the arteries which were thread-like; in the macula region were four small delicate pigment deposits, and there were also spots of pigment, not of the 'bone corpuscle' type, in the periphery, the rest of the fundus was absolutely free from pigment. II. 2, aged 4, had seen very badly since birth and was night-blind; he was a healthy boy, and was found to have a medium degree of myopic astigmatism; V. = $\frac{1}{36}$ not improved by glasses; the papilla was pale, the retinal vessels diminished, and there was no trace of pigmentation of the retina to be seen; colour sense was normal. II. 3, a sister aged 2, had the same condition as II. 2; the retinal vessels were very fine, and there was no trace of pigment to be seen in the retina; her vision was better than that of her brothers. The central nervous system appeared to be normal for all. Consanguinity. Bibl. No. 258.

PLATE III. Fig. 17. *Nettleship's Case.* A single case of retinitis pigmentosa in a pedigree which shows the presence of other degeneracies in the stock. IV. 4, Mary Simcox, aged 36, had typical retinitis pigmentosa; she believed her sight was perfect till after her confinement twelve years before when she was very ill and her vision began to fail; she had posterior polar cataracts and some myopic astigmatism; R. V. = 12 J., L. V. = 18 J.; she had seen muscae and "coloured rings and serpents" for some time; pupils acted well; she was night-blind. She was further very subject to nervous occipital headaches, and for three years had had a constant roaring in her R. ear; she was not deaf, and had never had otorrhoea.

III. 3 died, aged 45, of fits following delirium tremens. IV. 1 had infantile convulsions, "her legs never grew below the knees, and she has never walked." IV. 5 and 7 died in infancy. IV. 9 had frequent fits. IV. 11 died, aged $2\frac{3}{4}$ years, "from insanity after a fright." IV. 12, subject to fits after infancy, died aged 12 years "of inflammation." IV. 14 died aged 25, insane. No consanguinity. Bibl. No. 99.

Fig. 18. *Lawford's Case.* (Taken from Nettleship.) Five cases of retinitis pigmentosa in a large sibship, the offspring of "cousins," and with a history of three first cousin marriages in the maternal ancestry in the direct line. VI. 1 had retinitis pigmentosa. VI. 2 had retinitis pigmentosa and was deaf. VI. 3 had retinitis pigmentosa, was deaf and was also an idiot. VI. 7 had retinitis pigmentosa and was deaf. VI. 8 had retinitis pigmentosa. VI. 9 represents two miscarriages. VI. 10 died, aged 3 years, and was believed to have seen well. There was no known case of blindness or deafness or nerve degeneracy in the ancestors of this sibship. No information was available concerning IV. 3, II. 1, or III. 1 and 2. Consanguinity. Bibl. No. 251, p. 39.

Fig. 19. *Nettleship's Case.* IV. 3 married twice; by his first wife he had one child, V. 5, with retinitis pigmentosa, who married and had two normal children, VI. 1; IV. 3 by his second wife, who was his first cousin, had four children, of whom V. 1 died, aged 6 years, mentally deficient, V. 2 was a miscarriage, V. 3, aged 13, had retinitis pigmentosa and was mentally deficient, V. 4, aged 6, was normal. IV. 1, maternal aunt to this sibship, was mentally defective, and her great aunt and great uncle, II. 1 and 2, were insane. Consanguinity. Bibl. No. 251, pp. 26—7.

Fig. 20. *Nettleship's Case.* Three cases of retinitis pigmentosa in a sibship of nineteen, of whom eleven died young. IV. 2 and 17 died in childbed; IV. 3, 4 and 5 died in infancy; IV. 6, an idiot, died aged 7; IV. 7, aged 40, had retinitis pigmentosa, she was also deaf and was half idiotic; IV. 9 was normal and had normal children; IV. 14, aged 30, was mentally feeble and had retinitis pigmentosa; IV. 15 had retinitis

pigmentosa; IV. 16 died, aged 18, of an accident. The father, III. 4, aged 74, had excellent sight, but nothing was known of his ancestors. The mother, III. 3, aged 70, had six siblings, of whom three were still living; her mother, II. 2, was one of a sibship of twenty-two of whom six died young, one of the survivors, II. 3, had fits. No consanguinity. Bibl. No. 251, pp. 23—4.

Fig. 21. *Nettleship's Case.* Retinitis pigmentosa in two members of a sibship of eleven. III. 1, aged 26, had a slight defect in her sight but was not seen. III. 3, aged 24, had never been able to see well at night, and was getting slowly worse; he had typical retinitis pigmentosa with scanty pigmentation; changes in the discs and vessels were relatively advanced, choroids were extremely pigmented; refraction normal; he had black hair, brown irides, was well grown and intelligent and was not deaf; he had been married 7 months. III. 6, aged 17, was well grown and intelligent but excitable; she only noticed that she was night-blind about six months ago when she began dress-making; she had typical retinitis pigmentosa with pale slightly hazy discs and much diminished vessels; no opacities in vitreous or lens. III. 7 died, aged 6 years, from "water on the brain," he "had no bones and could not walk unless splintered up to the waist," was intelligent, and head was not very large. III. 8 died, aged 6 months, of "inflammation on the chest." III. 11, aged 8, was described as "very peculiar and excitable, brain too active and head rather large," any little excitement was liable to make him delirious and disturbed at night.

I. 2 was insane in old age. I. 3, half-sister to I. 2, became blind and died paralysed and insane at the age of about 30. II. 2, not examined, was said to be very "short-sighted." II. 7 was said to be half imbecile. II. 8 married her first cousin and had children, of whom some were said to be defective in intellect. There were normal offspring from some members of II. 3—6. Consanguinity. Bibl. No. 99.

Fig. 22. *Nettleship's Case.* Four cases of retinitis pigmentosa in three generations. John Mills, III. 3, aged 57, and his sister, III. 2, aged 70, had the disease, also his mother, II. 1, and his maternal grandmother, I. 1. He probably had more than one sibling. Of his ten children four died in infancy, one son, an idiot, died aged 18, and five were living and normal. No consanguinity. Bibl. No. 251, p. 13.

Fig. 23. *Lawford's Case.* (Taken from Nettleship.) One case of retinitis pigmentosa, IV. 1, and one congenital idiot, IV. 4, in a sibship of four. The parents, III. 1 and 2, were half first cousins; the maternal grandfather, II. 2, and paternal grandmother, II. 3, were half siblings by the same father, I. 2, and different mothers. Consanguinity. Bibl. No. 251, pp. 46, 336.

Fig. 24. *Herrlinger's Cases* 22 *and* 23. Four cases of retinitis pigmentosa associated with deaf-mutism, idiocy and polydactylism. IV. 1, aged 14, had seen badly since childhood, and his vision was now reduced to finger counting; he had retinitis pigmentosa, was an idiot, was deaf, and had six toes on each foot and six fingers on his left hand. IV. 2, aged 12, had retinitis pigmentosa and was an idiot; her vision was reduced to finger counting. IV. 3 was an idiot, had bad sight and had polydactyly; she was not examined. IV. 4 represents four siblings who died young. IV. 5 represents four healthy and normal siblings. IV. 6, son of a paternal uncle to the sibship IV. 1—5, was blind and a deaf-mute.

The parents, III. 1 and 2, were healthy and unrelated. I. 2 was a deaf-mute, I. 3 an idiot. No consanguinity. Bibl. No. 203.

Fig. 25. *Herrlinger's Cases* 3 *and* 91. Retinitis pigmentosa in two brothers whose parents were first cousins on their father's side and second cousins on their mother's side. IV. 1 and 2 died in infancy. IV. 3 was stillborn. IV. 4 and 5 were healthy. IV. 6, aged 7, had seen badly since birth and his vision was now reduced to finger counting, he had retinitis pigmentosa and was mentally defective. IV. 7, aged 4, had retinitis pigmentosa *sine pigmento*, his vision was reduced to perception of light. The parents and other relatives had normal vision. Consanguinity. Bibl. No. 203.

Fig. 26. *Webster's Case.* A healthy man and woman, I. 1 and 2, had two healthy sons, II. 2 and 3. II. 2 married and had five living children of whom two had retinitis pigmentosa and three daughters saw well. III. 1, aged 42, was examined and was found to have the right retina loaded with pigment deposits, the left retina showing the same condition in a less severe stage; there was partial atrophy of the discs; the fields were irregularly contracted with numerous scotomata; her vision had always been poor, but was getting worse.

II. 3 married his first cousin and had nine children of whom three became blind and afterwards idiotic, five were presumably healthy, III. 8 had good sight but died of a "chronic disease of the nervous system." Consanguinity. Bibl. No. 105.

Fig. 27. *Nettleship's Case.* Retinitis pigmentosa in two brothers, III. 1 and 3; they had two normal brothers, III. 2 and 4. The father, II. 2, had had eleven siblings of whom four died of phthisis, one died in infancy and six were living. His father, I. 3, committed suicide; his mother, I. 2, and her sister, I. 1, died of phthisis. No consanguinity. Bibl. No. 251, p. 23.

Fig. 28. *Herrlinger's Case* 90. Retinitis pigmentosa in III. 1, aged 7 years. His sister, III. 2, aged 5, was blind, two brothers, aged 3 and 2 years respectively, saw well. The father and grandfather were drinkers. The maternal grandfather, I. 4, had a congenital defect in his foot. The sister of the maternal grandmother had a daughter who was blind and an idiot. No consanguinity. Bibl. No. 203.

Fig. 29. *Harlan's Case.* Four siblings born blind, or with slight perception of sight only, in a sibship of six. The eldest and youngest were normal. One blind child had died, one was an idiot, and the others were rather deficient in intellect. One case only was examined, he, II. 2, aged 21, had contracted and immovable pupils, and nystagmus; pigmentation of the retina was well-marked in the periphery but not abundant. There was no known hereditary predisposition to retinitis pigmentosa. No consanguinity. Bibl. No. 82.

PLATE IV. Fig. 30. *Nettleship's Case.* One case of retinitis pigmentosa in a pedigree which shows freedom from disease in the direct line for three previous generations on the maternal and two on the paternal side; no information was obtained of the collaterals. The patient, a woman aged 40, had ten normal siblings; she was married and had four normal children. She showed no signs of hereditary syphilis, and there was nothing to suggest acquired syphilis; the eye changes were typical of ordinary retinitis pigmentosa. No consanguinity. Bibl. No. 251, p. 21.

Fig. 31. *Scimemi's Case.* Two normal first cousins, III. 1 and 2, married and had five sons of whom three were normal and two, IV. 2 and 3, had retinitis pigmentosa; IV. 3 married his second cousin, IV. 4, and after a miscarriage they had a daughter, V. 3, who at the age of 26 was seen to have retinitis pigmentosa. After the death of IV. 3, his brother, IV. 2, married the widow, IV. 4, his second cousin; they had a daughter, V. 1, who had a progressive diminution in vision, and was believed to have retinitis pigmentosa, although the characteristic changes in the fundus had not yet appeared at the time of examination. Consanguinity. Bibl. No. 207.

Fig. 32. *Nettleship's Case.* Retinitis pigmentosa with atypical symptoms but typical changes in two sisters, V. 2 and 3, who had two normal sisters; they were the offspring of second cousins. No known history of bad sight in generations I.—IV., but details of generation I. could not be obtained. Consanguinity. Bibl. No. 251, pp. 47, 336.

Fig. 33. *Bayer and Nolden's Case.* I. 1 was described by Bayer when she was aged 42; she had suffered from retinitis pigmentosa for thirty years; she could read Jäg. No. 14, her fields showed concentric contraction, the retinal vessels were not much narrowed, and she had a slight deposit of pigment in the periphery of the retina. She had five children, four or five of whom suffered from night-blindness. Nolden described one of these, a boy, II. 1, Wilhelm Fassbender, aged 10 years, whose vision $= \frac{10}{20}$, his fields were contracted, and the pigmentation of the retina was typical though scanty. No consanguinity. Bibl. Nos. 75, 94.

Fig. 34. *Wider's Case.* Retinitis pigmentosa in three sisters aged 63, 53 and 51 respectively when examined; in each case vision was reduced to hand movements only, all were myopic and had only very small fields of vision; the fundi were typical of the disease. They had one brother who was said to see very badly. The parents were normal and related in the "3rd Grade." There had been much intermarriage in the families, and numerous relatives were said to be blind or to be night-blind. Consanguinity. Bibl. No. 137.

Fig. 35. *Nettleship's Case.* Retinitis pigmentosa with day-blindness and colour-blindness in three members of a sibship of nine, the offspring of first cousins once removed. The affected members were V. 2, aged 34, a woman who was married and had two normal children; V. 7, a male aged 24; V. 8, a male aged 21; V. 6 died, aged 11 years, of "fever." The father, III. 3, died, aged 50, of heart disease; the mother, IV. 1, aged about 57, was melancholic. No information about the maternal grandmother, III. 1. Consanguinity. Bibl. No. 251, p. 45.

Fig. 36. *Dean's Case.* Two sisters marry two brothers, their first cousins; five cases of retinitis pigmentosa occur with two normal members in the resulting sibships. III. 1, aged 17 years, had typical retinitis pigmentosa, his vision was reduced to finger counting only at 1 m. III. 2, aged 15 years, was partially blind. She could not see to count fingers, and her fundus showed typical retinitis pigmentosa. III. 3, aged 9 years, had good vision. III. 4, aged 4 years, was blind. By the second sibship, III. 5, aged 16 years, was almost blind and could not see to count fingers, the fundus again showed typical retinitis pigmentosa. III. 6, aged 13 years, had normal vision. III. 7, aged 10 years, could not see to count fingers, had typical retinitis pigmentosa and further had degenerate changes in his teeth; thus the two upper central incisors were absent and the two lower ones were about one-third the normal size, the two upper lateral incisors were small and conical, the two lower ones were only about a quarter the normal size. Consanguinity. Bibl. No. 211.

Fig. 37. *Rosenbaum's Case.* Retinitis pigmentosa in II. 1, aged 41; V. $= \frac{8}{60}$. An uncle, I. 3, and two brothers, II. 2 and 3, suffered from night-blindness. No consanguinity recorded. Bibl. No. 213.

Fig. 38. *Simi's Case.* Three cases of retinitis pigmentosa in a sibship of five, no other cases being known in the family. Sebastiano Giannini, aged 7, had both eyes affected with retinitis pigmentosa, the deposits being more profuse in the right eye; vision was completely lost; his two brothers were said to be as blind as the patient. Two sisters had excellent sight. No consanguinity. Bibl. No. 60.

Fig. 39. *Trousseau's Case.* Retinitis pigmentosa in IV. 1, aged 12, the illegitimate child of an uncle and

niece. The parents and very aged grandparents were examined and found to have normal eyes; a maternal aunt, III. 2, was examined and was found to be nearly blind with retinitis pigmentosa. Consanguinity. Bibl. No. 171.

Fig. 40. *Nettleship's Case.* I. 1 was blind at the age of 40, probably from retinitis pigmentosa; his son, II. 1, had normal vision, he was married and had several children, of whom one, a daughter, had typical retinitis pigmentosa. No consanguinity. Bibl. No. 251, p. 19.

Fig. 41. *Siegheim's Case.* Retinitis pigmentosa in two siblings and their paternal great-uncle. No information of normal members of the family. No consanguinity recorded. Bibl. No. 146.

Fig. 42. *Snell's Case.* Six cases of retinitis pigmentosa in a sibship of eight. The father, I. 1, aged 56, had normal fundi, hypermetropia 4 D. and V. $= \frac{2}{30}$ in each eye. The mother, I. 2, was myopic, but otherwise her eyes were normal. II. 1, aged 27, was myopic, - 5 D., V. $= \frac{2}{50}$, her fundi were normal. II. 2, aged 25, had always seen badly at night, the disability increasing with his age; the retinal periphery was studded with pigment, the margins of the discs were a little blurred; he was myopic and V. $= \frac{2}{30}$. II. 3, aged 24, was night-blind and had well-marked pigmentary deposits in the retina; R.V. $= \frac{2}{50}$, L.V. $= \frac{2}{70}$, slightly improved by + glasses. II. 4, not examined, was reported to suffer in the same way as his brothers. II. 5, aged 18, was night-blind, and had deposits of pigment scattered round the periphery of the retina; the discs were paler than normal; he had myopia - 4 D., and V. $= \frac{2}{50}$; his fields showed concentric contraction. II. 6, aged 17, had seen badly at night for four years; small pigment dots were seen at the periphery of the retina; he had a high degree of myopia and astigmatism. II. 7, aged 14, had always seen badly at night; pigment dots were seen at the periphery of the retina; V. $= \frac{2}{50}$. II. 8, aged 13, was not night-blind, the retina was a little mottled at the periphery, but no deposits of pigment were present; he was hypermetropic, V. $= \frac{2}{20}$.

Careful inquiry could discover no evidence on either parent's side of night-blindness in their progenitors. In all the brothers the complexion was florid and hair was fair; they were all healthy looking market gardeners. No consanguinity. Bibl. No. 147.

Fig. 43. *Gonin's Case.* Th. B., II. 2, aged 30, was the third of twelve siblings; he had had night-blindness since infancy and had typical retinitis pigmentosa; central visual acuity $= \frac{3}{10}$; he had myopia of 2 D.; visual fields were contracted in a lowered light and showed an annular scotoma. A sister aged 20 years had night-blindness; seven living siblings were normal, and three siblings were dead, of whom there was no information. The parents were healthy "cousins of the 8th degree." No ocular affections were known in the antecedents. Consanguinity. Bibl. No. 218.

Fig. 44. *Smyth's Case.* (Taken from Nettleship.) Two cases of retinitis pigmentosa in a sibship of seven. The affected members were a male, the fifth born and a female, the youngest of the sibship. Three brothers were normal, one brother died in infancy, and one female, IV. 6, was normal. The parents, believed to be normal, were uncle and niece. Consanguinity. Bibl. No. 251, p. 34.

Fig. 45. *Rosenbaum's Case* 13. III. 1, aged 19, had retinitis pigmentosa; V. $= \frac{6}{9}$. Her maternal grandfather, I. 1, her mother, II. 2, all her mother's siblings (number not given) and two of her three siblings were night-blind. No consanguinity recorded. Bibl. No. 213.

Fig. 46. *Ayres' Case.* In a sibship of seven, four boys have such defective sight that they are unable to plough a field or drive a reaper, and one girl also has defective sight; the first and fifth born, two girls, have good sight. Only one case was examined; he, aged 25 years, had typical retinitis pigmentosa with greatly contracted fields and with vision so imperfect that he was unfit for ordinary work. The parents were cousins and the mother delicate. Consanguinity. Bibl. No. 138.

Fig. 47. *Nettleship's Case.* Nine cases of retinitis pigmentosa in three generations. Two affected sisters, II. 1 and 3, had a normal brother, II. 2. II. 3 married and had seven children of whom three sons and one daughter had retinitis pigmentosa, one son and two daughters were normal. The two normal daughters, III. 2 and 4, had each a normal child. One affected son, III. 7, was believed to have five normal children. III. 9, an affected son, was known to have an affected daughter, IV. 8. III. 11, the affected daughter was known to have two affected sons, IV. 10 and 13, and four normal children of whom three were daughters. No consanguinity. Bibl. No. 251, pp. 13—14.

Fig. 48. *Frenkel and Dide's Case.* Retinitis pigmentosa associated with severe defects of the central nervous system in three siblings. II. 1 was normal to the age of 7, she talked, walked and was learning to read; in her seventh year her sight diminished, and a year later she was believed to be blind, but she evidently saw still in the day; a little later she became ataxic and later still mental troubles developed; towards the age of 13 convulsive attacks commenced with loss of consciousness, salivation, tonic convulsions and stertor; she died aged 20. II. 7, aged 18, was normal to the age of 8 when her sight diminished; at puberty she became ataxic and later had epileptiform attacks; she had slight convergent strabismus, no nystagmus, pupils reacted, media were transparent; R. fundus showed atrophy of temporal side of disc which was also pale on the nasal side, arteries narrowed, margins of disc clear, and there was typical retinitis pigmentosa; similar conditions were present in the L. fundus, though here the pigmentary deposits

approached nearer to the papilla; visual acuity and fields could not be examined. The authors give a detailed description of the conditions found in the central nervous system. II. 8, aged 13, was normal to the age of 7½ since when her vision had progressively diminished; she had slight convergent strabismus, pupils reacted sluggishly, nystagmus was present, media were transparent, fundi were typical of retinitis pigmentosa.

The parents were both living, there was no history of nervous or degenerative disease or troubles with vision in them or any of their relations, there was no syphilis and no consanguinity. The family was Catholic and of Spanish origin. The first patient was born two years after marriage; II. 2 and 3 were twin boys born three years later who both died aged 6 or 7 days; II. 4, born one year later, was living and well, aged 28, and had a healthy daughter; II. 6, a boy, born two years later, died, aged 2, of meningitis. No consanguinity. Bibl. No. 289.

Fig. 49. *Leber's Case.* Retinitis pigmentosa in two brothers and a sister with three normal siblings; parents and grandparents were normal. III. 1, aged 34 years, had suffered since his twelfth year when he first noticed night-blindness and a rapidly increasing amblyopia; a year later he could only read with difficulty; ophthalmoscopic appearances were typical of the disease, the pigment reaching to the neighbourhood of the papilla. No consanguinity. Bibl. No. 72.

PLATE V. Fig. 50. *Snell's Case.* Twelve cases of retinitis pigmentosa in a pedigree of five generations, generation II. being free from the defect. III. 8, aged 45 (1906), complained of his sight being very defective especially at night; he was found to have severe retinitis pigmentosa with waxy looking discs; R.V. = $\frac{1}{60}$, L.V. = $\frac{4}{60}$; the fields of vision were reduced to a very small area, little more than fixation point. The author also examined IV. 6, aged 12, who was normal, and V. 3 who was affected. No consanguinity. Bibl. No. 244.

Fig. 51. *Herrlinger's Case* 71. Retinitis pigmentosa in a girl, aged 19 years, whose grandmothers were half-sisters by their mother, II. 2, and whose great-grandfathers, II. 1 and 3, were brothers; she also had convergent strabismus. The parents were normal. Consanguinity. Bibl. No. 203.

Fig. 52. *Nettleship's Case.* Nine cases of retinitis pigmentosa in two sibships of the same generation; one grandfather, I. 2, was believed to have had the disease, his wife and their five children were certainly normal. II. 2 had ten children of whom III. 1 aged 28, III. 4 aged 24, and III. 7 aged 10 had retinitis pigmentosa; III. 8 was stillborn, III. 9 died of "croup" in childhood. II. 3 had thirteen children of whom six males had retinitis pigmentosa and their seven siblings had good sight; none of this sibship were examined. II. 5 had several children, one of whom was "near-sighted but not like the night-blind ones," the others were normal. No consanguinity. Bibl. No. 251, p. 20.

Fig. 53. *Gonin's Case.* Victor B., III. 3, aged 18, suffered from retinitis pigmentosa with typical appearance of fundus; V.R. = V.L. = $\frac{1}{10}$; he had myopia of 6 D. in R. and 8 D. in L.; visual fields were contracted. His elder brother, aged 20, suffered from night-blindness; his younger brother was only aged 4 and no information was given of his eyes; his seven sisters had good sight. I. 2, the maternal grandfather, lost his sight gradually about the age of 40 without knowing the cause. II. 3, a maternal aunt, had several children with "weak sight." II. 5, the father, had atrophy of the optic nerve following a retrobulbar abscess four years previously No consanguinity. Bibl. No. 218.

Fig. 54. *Rosenbaum's Case.* Retinitis pigmentosa in III. 3, aged 25 years; R.V. = $\frac{8}{18}$, L.V. = $\frac{8}{12}$; fundus examined. Consanguineous marriages had occurred in the mother's family. A brother, aged 36 years, and a sister, aged 38, also suffered from retinitis pigmentosa. The mother, the maternal grandfather, a maternal uncle and his child all suffered from night-blindness. The author does not refer to any normal members of the family. Consanguinity. Bibl. No. 213.

Fig. 55. *Maes' Case.* Retinitis pigmentosa in two brothers and a sister with six normal siblings; the parents and grandparents were normal. One case only was examined, he, aged 51, had suffered from night-blindness as a child; his vision had become greatly diminished during the last two years; he had normal lenses and discs; the arteries of the retina were somewhat narrowed; the fields were contracted and the retina was pigmented. No consanguinity recorded. Bibl. No. 43.

Fig. 56. *Mooren's Case.* Retinitis pigmentosa in a boy, III. 1, his father and two uncles, and also in his paternal grandmother; the latter was not examined by the author. No consanguinity recorded. Bibl. No. 114.

Fig. 57. *Mooren's Case.* Two first cousins married and had six children of whom two sons had retinitis pigmentosa; one of the normal sons of this sibship married and had four sons of whom one had retinitis pigmentosa, one had congenital night-blindness, and two had normal sight. One of the affected sons of the sibship, II. 3, married his cousin and had four children who all suffered from retinitis pigmentosa. Consanguinity. Bibl. No. 114.

Fig. 58. *Mooren's Case.* Retinitis pigmentosa in a nine year old girl, III. 1, in her father, II. 2, and his three brothers, II. 3, 4 and 5, and in her paternal grandmother, I. 1. Most of these cases were examined

by the author who however makes no reference to any unaffected members of the family. No consanguinity recorded. Bibl. No. 85.

Fig. 59. *Gould's Case.* III. 2, aged 26 years, a typist, complained of headache with obscure ocular and cerebral symptoms apparently due to eye strain. R.V. with - Sph. 0·37 Cyl. 0·24 ax. 180° $\frac{20}{20}$, L.V. with – Cyl. 0·37 ax. 180° $\frac{20}{30}$. Preliminary ophthalmoscopic examination was negative. For 3 years she had had difficulty in walking alone at night, and on examining her fields it was found that for white the fields were contracted to about half the normal, and for colours they were very small and irregular in outline; colour sense was normal; with extreme care the author could now detect numberless obscure tiny dots, brownish or blackish, strewn over the retinal periphery. III. 1, brother to III. 2, aged 29, was also examined and the condition was just as in his sister's case; the retinal vessels and discs were normal in both cases. Two other siblings, a sister and brother, had normal eyes. The parents were normal, but the paternal grandfather was night-blind all his life, and was quite blind at the age of 70. No consanguinity recorded. Bibl. No. 194.

Fig. 60. *Oliver's Case.* Fourteen cases of retinitis pigmentosa in three generations. II. 2 had for many years been unable to see at night, and now had become unable to read by daylight. The ophthalmoscope showed a typical retinitis pigmentosa with almost entire absence of retinal vessels and advanced optic atrophy. All cases were examined except I. 1, II. 7, III. 8 and 9 but no further details were given. There was no knowledge of other cases in the ancestry. No consanguinity recorded. Bibl. No. 294.

Fig. 61. *Herrlinger's Cases* 42, 43. Three cases of retinitis pigmentosa in a sibship of fifteen, of whom ten were dead. The parents were normal and unrelated, the paternal grandparents were first cousins. III. 1, aged 27, had suffered from night-blindness since his school days; V. = finger counting at $\frac{1}{2}$ m.; refraction, myopia of – 3 D.; retinitis pigmentosa was found. III. 2, aged 15, was similarly affected; for her R.V. = $\frac{2}{60}$, L.V. = $\frac{4}{60}$; refraction, myopia of – 4 D. in R., – 3 D. in L. III. 3, aged 13 years, was said to be affected to a less degree than III. 1 and 2. III. 4 and 5 were normal and saw well. Consanguinity. Bibl. No. 203.

Fig. 62. *Harlan's Case.* Retinitis pigmentosa in three siblings, their mother and their maternal grandfather. III. 1, aged 20, had always been night-blind, and was at the time of observation just able to see to go about alone and could recognise persons in bright daylight; blindness was absolute except in the region of the macula. III. 3, aged 16, never had good sight, but could recognise persons up to the age of 10, since when she has had quantitative vision only; she had external strabismus and nystagmus. III. 2, said to be similarly affected, was not examined. Three brothers and three sisters were reported to have had normal vision, two of them however died young. No consanguinity recorded. Bibl. No. 82.

Fig. 63. *Nettleship's Case.* Retinitis pigmentosa in five members of a sibship of eight. The patient, III. 5, aged 26, said that all her sisters, one of her four brothers, her mother and "all" relatives on her mother's side had the disease; three of her brothers had normal vision. The author was unable to get more information concerning the cases in this family. No consanguinity recorded. Bibl. No. 251, p. 16.

Fig. 64. *Mayou's Case.* III. 1, aged 17 years, had suffered from night-blindness for two years; Wassermann test negative. Her fundus showed typical but not very marked retinitis pigmentosa, the discs were slightly grey, retinal vessels almost normal in size, lenses were clear, fields of vision contracted to the ten degree circle, pigmentary deposits in the periphery of the retina. There was some improvement in the fields on paracentesis, and the author therefore trephined; a week later the patient reported that she had lost her night-blindness, and her fields were markedly improved. Her aunt, II. 3, showed far more extensive changes and was practically blind; she also showed marked improvement in her fields after trephining. The author was of the opinion that the improvement was possibly temporary, and this proved to be the case. The patient's father, her grandfather and her brother were also affected. No consanguinity recorded. Bibl. Nos. 305, 309.

Fig. 65. *Ancke's Case.* III. 1, aged 18 years, complained of night-blindness which she had noticed since the age of 7; she had good central vision but her fields were contracted in daylight and much more so in a dull light; fields for colour were much more markedly contracted; her fundus showed a typical retinitis pigmentosa. III. 2, aged 17, had normal vision. III. 3, aged 16, did not suffer from night-blindness, her central vision was good, but the fields were markedly contracted in a dull light; the periphery of the fundus was seen to be stippled with numerous small white spots which were not confluent and further there was seen a typical fine distribution of pigment of the 'bone corpuscle' shape; the arteries were narrowed. III. 4, aged 14, did not complain of his sight but he suffered from night-blindness and was found to have fields full in daylight but contracted in a dull light; retinitis pigmentosa was found on ophthalmoscopic examination. III. 5, aged 12, had normal vision. The parents of this sibship were first cousins. Consanguinity. Bibl. No. 132.

Fig. 66. *Nettleship's Case.* Retinitis pigmentosa in two brothers in a sibship of six. III. 1, 3 and 5 were examined and found to be normal; III. 2, died, aged 1½ years, of measles; III. 4 and III. 6, aged 9, were affected. The maternal grandparents, who both saw well, were "half-cousins." Consanguinity. Bibl. No. 251, p. 43.

Fig. 67. *Nettleship's Case.* Retinitis pigmentosa in a brother and sister who had one normal brother, III. 1, aged 46; the mother, II. 1, and maternal grandmother, I. 1, were also affected. The parents were "distant cousins," the maternal grandparents were "cousins." Consanguinity. Bibl. No. 251, p. 25.

PLATE VI. Fig. 68. *Maes' Case.* Retinitis pigmentosa in three siblings, eight other siblings died young; parents and grandparents were normal and unrelated. III. 1 was seen, aged 56, he reported that he had seen quite well even in the evening up to his eleventh year, but since then his sight had steadily got worse until now in bright daylight his fields of vision were contracted; he had posterior polar cataracts but the pigment of the retina could be seen between them; he was also deaf. III. 1 reported that his two living sisters had the same disease and had become almost blind at about the age of 50; one of the sisters was also deaf. No consanguinity. Bibl. No. 43.

Fig. 69. *Ransohoff's Case.* II. 2, aged 55 years, came up for treatment for hypopyon keratitis of the left eye, she had always been short-sighted and seen badly, but was able to do her own housework. On examining the right eye it was found that the papilla was pale, the vessels narrowed and there was a considerable development of pigment in the periphery of the retina. She had four siblings of whom three could see well, but the youngest sister was short-sighted and night-blind. This sister had five children none of whom had retinal disease, but two of whom had myopia of 6 D. and 9 D. respectively. II. 2 married a healthy man with normal eyes and no history of eye disease in his family; of their seven children four had retinitis pigmentosa and myopia. III. 1, Wilhelmine, had retinitis pigmentosa and myopia of 9 D. III. 2 was normal. III. 3, Gustav, had retinitis pigmentosa, a R. posterior polar cataract and myopia of 5 D. III. 4, Emil, had normal eyes. III. 5, Carl, with retinitis pigmentosa, had myopia of 5 D. III. 6, Wilhelm, had retinitis pigmentosa with myopia of 10 D., and III. 7, Franz, had normal eyes. No consanguinity. Bibl. No. 167.

Fig. 70. *Dean's Case.* Retinitis pigmentosa in a boy, III. 1, aged 13 years, whose fundus showed the typical changes, V. $= \frac{6}{12}$; he had one younger brother whose eyes were apparently normal. The mother seen, aged 35 years, had retinitis pigmentosa and also cataract. The maternal grandfather, I. 2, had been blind since the age of 35, and had complained of night-blindness before he became totally blind. No consanguinity recorded. Bibl. No. 211.

Fig. 71. *Maes' Case.* Retinitis pigmentosa in two brothers whose parents and grandparents were normal and unrelated. One only of the brothers was examined, he, III. 2, had had good sight with no difficulty in the evening light up to his 17th year, but since then his vision had slowly diminished; when examined at the age of 40 he had night-blindness, contracted fields in a dim light; posterior polar cataracts and a pigmented retina. The greyish appearance of the retina is noted, and also the presence here and there of white spots in the retina. No consanguinity. Bibl. No. 43.

Fig. 72. *Ayres' Case.* II. 2, aged 37 years, a widow, had been unable to see well at night since childhood but was able to earn her living by doing plain sewing. On examination it was found that L.V. = R.V. $= \frac{1}{2}\frac{5}{5}$; there was a small posterior polar cataract in each lens; the vessels of the retina were considerably diminished in size, and pigment was sparsely scattered over the retina, the greater portion of it being on the inner side; she was the third child in a sibship of five. III. 1, daughter to II. 2, aged 15 years, had the same defect; R.V. = L.V. $= \frac{1}{2}\frac{5}{0}$; the retinal vessels were slightly diminished and she had less pigment in the retina than her mother. III. 2, aged 12 years, had some difficulty in seeing at night; for her R.V. = L.V. $= \frac{1}{5}\frac{5}{0}$; she was found to have more pigment in her retina than her sister or mother. II. 3, husband to II. 2, had good eyes. No consanguinity. Bibl. No. 138.

Fig. 73. *Tobin's Case.* II. 2 and 3, two healthy and energetic "near relations," married and had twelve children, five girls and seven boys, of whom III. 1, a son, aged 47, is healthy. III. 2, Nancy, aged 42, was born deaf and with bad sight, she is unable now to follow the finger alphabet, and has been unable to read for ten years. III. 3, 4, 5, 7 and 8 are normal. III. 10, Jane, aged 32, with dark hair and brown irides, is an intelligent deaf-mute, and has retinitis pigmentosa with very defective vision and night-blindness; her fields are reduced to a circle of 10° round the fixation point and are even smaller for colours; the retinal vessels are diminished in size and their walls thickened, there is no atrophy of the disc; pigment is abundant at the periphery and scattered masses extend to the neighbourhood of the disc; she has a posterior polar cataract. III. 11 and 12 are two healthy sons. III. 13, a son, aged 25, is a deaf-mute with retinitis pigmentosa, masses of black pigment in a lace-like pattern form a complete circle round the retinal periphery; he is night-blind and can only read in a bright light, his sight has been gradually failing for some time. III. 14, a son, aged 22, is a deaf-mute with retinitis pigmentosa; he is night-blind, his sight began to fail in childhood and now he can scarcely see to read or write; pigment is abundant; the retinal vessels are reduced to threads and his fields are markedly contracted.

The mother came of healthy parents and died, aged 50, of heart disease. The father also came of healthy parents and had ten healthy siblings. Two normal daughters of the sibship married and had healthy families. One other normal daughter was examined and found to have slight astigmatism. Consanguinity. Bibl. No. 131.

Fig. 74. *Webster's Case.* Four cases of retinitis pigmentosa in a sibship of four, the mother and three cousins being also affected. II. 6, aged 44, had always been troubled with night-blindness and for several years had found difficulty with his sight in the day also; R.V. = $\frac{20}{200}$, L.V. = $\frac{20}{30}$; visual fields were nearly circular and very small; retinitis pigmentosa was very marked in both eyes; he had also floating bodies in the vitreous and a R. posterior polar cataract. No consanguinity. Bibl. No. 105.

Fig. 75. *La Gleyze's Case.* (Taken from Nettleship.) Retinitis pigmentosa in two brothers. II. 6 and 7, aged 12 and 10 years respectively (1903). II. 4 and 5 were miscarriages; II. 8 represents six other children of whom details are given. II. 1—3 are three siblings, maternal first cousins to II. 6, 7, who were all affected by congenital cataract, one was operated on and the fundus was then seen to be normal. The parents of each sibship were first cousins. Consanguinity. Bibl. No. 251, p. 344.

Fig. 76. *Webster's Case.* Three cases of retinitis pigmentosa in a sibship of seven. III. 1, 4 and 5 had no eye trouble. III. 6, aged 33, had worn glasses for ten years for reading only. III. 2, aged 49, had always had bad sight and became blind at the age of 25, he had characteristic pigmentary deposits over the whole fundus, atrophy of the optic nerves and posterior polar cataracts in both eyes. III. 3, aged 46, had no cataract, no marked atrophy of the discs, was still able to do her own housework, but had marked retinitis pigmentosa; she married and had three children who died in infancy. III. 7, aged 30, could see to work on a farm up to the age of 15; he had retinitis pigmentosa with atrophy of the discs and posterior polar cataract, bilaterally. The paternal grandfather, I. 2, had "inflammation in his eyes from a cold" and was blind for several years before his death at the age of 76. A paternal great-aunt, I. 3, was blind from her youth. No consanguinity. Bibl. No. 105.

Fig. 77. *Picard's Case.* Two healthy first cousins have three children, of whom II. 1, a robust youth aged 21, who had had trouble with his sight since early infancy, was found to have retinitis pigmentosa with narrowed retinal vessels, atrophy of disc and typical deposits of pigment in the retina; he had contracted fields, diminished visual acuity and night-blindness, also a posterior polar cataract on the left side. II. 2 was delicate and had suffered from night-blindness since infancy. II. 3 was deaf and had severe attacks of neuralgia. Consanguinity. Bibl. No. 64.

Fig. 78. *Mellinger's Case.* II. 1, aged 38, had suffered from his eyes during his school days and had always seen badly at night; R.V. = L.V. = $\frac{2}{7}$; media clear except for a bilateral posterior polar cataract; the papillae were very pale; the vessels very narrow; the characteristic bone corpuscle type of pigment commenced near the papillary margin, the deposits sometimes being thickly massed and sometimes more dispersed; towards the equator the retina was free from pigment; the fields had almost normal boundaries but on each side was found a zone in which the sight was bad. He had a sister who suffered from night-blindness. The parents and grandparents were unrelated but a sibling of one of the grandmothers was said to have suffered from weak eyes. No consanguinity. Bibl. No. 156.

Fig. 79. *Priestly Smith's Case.* Four cases of retinitis pigmentosa in a sibship of seven, associated with deafness and with posterior polar cataract. Generations I. and II. were known to be healthy, and to have good sight and hearing. III. 1 was strong, hearing perfect, vision normal. III. 2, died, aged 25, from injury, had good sight and hearing. III. 3, aged 48, nearly deaf and dumb, was irritable and passionate; she was night-blind and her sight failed gradually until she had only perception of light; the fundus in each eye was partly hidden from view by posterior cortical cataracts; she had advanced retinitis pigmentosa. Her mother, II. 1, had a severe nervous shock in the early months of her pregnancy with III. 3. III. 4, died, aged 18 months, of croup. III. 5, aged 41, had advanced retinitis pigmentosa, was nearly deaf and had posterior polar opacities in each lens. III. 6, aged 38, not examined, was reported to be nearly deaf and partly blind. III. 7, aged 33, had advanced retinitis pigmentosa, was very deaf and had posterior polar cataracts; he married and had four children, aged 12 to $2\frac{1}{2}$, all with perfect sight and hearing. No consanguinity. Bibl. No. 115.

Fig. 80. *Liebreich's Case.* I. 2, a healthy soldier, who was however addicted to drink, married twice; by his first wife he had two normal children; by his second wife he had five children of whom three, two females and one male, were deaf-mutes with retinitis pigmentosa, one female and one male were normal I. 2 further, had an illegitimate son by the younger sister of his second wife, born between the second and third legitimate children, who was also a deaf-mute with retinitis pigmentosa. No consanguinity recorded. Bibl. No. 42.

Fig. 81. *Derby's Case.* III. 1, aged 14, had retinitis pigmentosa; pigment was profuse, nerves "muddy," vessels small, V. = 0·3 in each eye, fields greatly contracted; at the age of 19 he was found to be getting rapidly worse and vision was reduced to 0·1 in each eye. His father, II. 2, had bilateral posterior polar cataract, he, and also III. 2, 3 and 4, had divergent strabismus. The paternal grandparents were first cousins. Bibl. No 149.

Fig. 82. *Rosenbaum's Case.* Retinitis pigmentosa and incipient cataract in I. 1, aged 56 years. V. = $\frac{8}{60}$. All his children had the same disease. No consanguinity recorded. Bibl. No. 213.

Fig. 83. *Kaupp's Case.* I. 1 and 2 were unrelated and had normal sight. Of their ten children, II. 1

was a deaf-mute with retinitis pigmentosa, II. 2 represents four children who died young. II. 3 and 4 were normal sons, II. 5 a normal daughter, and II. 6 and 7, both daughters, were deaf-mutes with normal vision. II. 1 was examined at the age of 28 years, and reported that for ten years he had suffered from night-blindness; V. = $\frac{3}{6}$; fields were greatly contracted, and the fundi showed changes typical of the disease. No consanguinity. Bibl. No. 162.

Fig. 84. *Nettleship's Case.* Retinitis pigmentosa and deafness in a girl, IV. 4, who had two normal brothers and one normal sister. A sister of her paternal grandfather, II. 1, was a deaf-mute. I. 1 and 2 were first cousins. The parents, III. 1 and 2, were normal and unrelated. Consanguinity. Bibl. No. 251, p. 29.

Fig. 85. *Lawford's Case.* (Taken from Nettleship.) A single case of retinitis pigmentosa associated with deaf-mutism in a girl, III. 2, who had one normal brother. The parents were first cousins; the grandmothers were sisters, each of whom had many children and grandchildren, all of whom were known to be free from defects of sight, deaf-mutism and mental degeneracy. Consanguinity. Bibl. No. 251, p. 39.

Fig. 86. *Oakley's Case.* III. 2, a stupid heavy looking girl, aged 16, had retinitis pigmentosa and myopia of 4 D., V. = $\frac{12}{70}$. A younger sister and an elder brother, aged 22, were highly myopic but had no retinitis pigmentosa. The parents were first cousins, and were dead, but the grandmother, I. 1, reported that they were both deaf and had very bad sight. I. 1, with good sight, married her second cousin who had bad sight; one of her daughters was the mother of III. 2, and another daughter, who was seen and had myopia, married a near relative and had five children of whom one was deaf and another had disease of the hip joint. It is unfortunate that there is no ophthalmological report of II. 1 and 2. Consanguinity. Bibl. No. 159.

Fig. 87. *Nettleship's Case.* II. 2, died of phthisis, aged 30; his wife, II. 3, an only child, committed suicide from grief at her husband's death; both had good eyes. Of their three children, III. 1 died, aged 3 years, III. 2 was normal and healthy, III. 3 was partially deaf and had, when seen, aged 71, advanced retinitis pigmentosa and cataract. III. 3 had two children, of whom one, IV. 2, had retinitis pigmentosa. IV. 2 had one child, aged 17, with posterior cortical cataract, but no retinitis pigmentosa. The family history was well known for two generations before generation III. No consanguinity. Bibl. No. 251, p. 17.

Fig. 88. *Maes' Case.* Retinitis pigmentosa associated with deafness in three sisters, the first, second and tenth born in a sibship of ten. Seven siblings were normal; the parents were normal and unrelated. One sister only was examined, she had seen quite well as a child, but since her twentieth year her vision had slowly deteriorated; at the age of 44 years her fields were greatly contracted even in bright daylight, but she was still able to read fairly well; media were normal and the retina was pigmented. No consanguinity. Bibl. No. 43.

Fig. 89. *Gonin's Case.* Retinitis pigmentosa in an only child, a deaf-mute aged 17 years, the condition had been diagnosed by Professor Dufour six years previously; visual acuity was $\frac{1}{3}$ for the R. eye and $\frac{1}{2}$ for the L.; she had slight hypermetropic astigmatism; her visual fields were contracted in a reduced light and even in full daylight she had an incomplete annular scotoma in the R. eye; night-blindness was not very pronounced; yellowish spots are described in the equatorial region as well as the typical pigmentation. Her parents were normal, but her maternal aunt was night-blind. No consanguinity recorded. Bibl. No. 215.

Fig. 90. *Webster's Case* 2. Retinitis pigmentosa and deaf-mutism in a boy, aged 16, the offspring of first cousins. Consanguinity. Bibl. No. 105.

PLATE VII. Fig. 91. *Liebreich's Case.* This pedigree is of special interest as being, according to Nettleship (Bibl. No. 251) the first family history of retinitis pigmentosa to be drawn up in support of consanguinity as a cause. The family was that of a noble, and intermarriage had been frequent within it for several generations. I. 1 and 2 were healthy and unrelated; they had one normal son, II. 2, whose descendants in the third and fourth generations were healthy, and two normal daughters who became first and second wives to their normal cousin II. 4. II. 3 died at the birth of her first still-born child. II. 5 had thirteen children, of whom three died in infancy; one, III. 5, died, aged 16, completely paralysed; three had retinitis pigmentosa, and further one of these was an idiot; one, III. 10, married a first cousin once removed, and had seven children, of whom one was an idiot; and one, III. 11, married a cousin and had one feeble-minded child, IV. 3; four normal members either did not marry or had no children. Consanguinity. Bibl. No. 42.

Fig. 92. *Gonin's Case.* Retinitis pigmentosa with typical ophthalmoscopic appearances in two brothers whose six sisters were normal, and whose parents were normal and unrelated. II. 2, aged 28, had greatly contracted fields, and his vision was reduced to finger counting at 2 metres with the R. eye and at 5 metres with the L.; media were transparent; pigmentation of the retina reached nearly to the disc. II. 4, aged 20, had visual acuity of $\frac{1}{6}$ in 1898, and also on a second examination in 1901, he had slight hypermetropia and contraction of fields; other conditions were typical of the disease. The maternal uncle, I. 2, was mentally defective and suffered from night-blindness. There was no syphilis in the family. No consanguinity. Bibl. No. 218.

Fig. 93. *Dean's Case.* Retinitis pigmentosa in three siblings, the mother was healthy and had normal vision, the father was an idiot. II. 1, aged 11 years, could see large objects during the day, but became blind in a dull light; V. $= \frac{6}{9}$; fundus showed changes typical of retinitis pigmentosa; he was exceedingly dull and had defective teeth, only three wedge-shaped incisors being present in the lower jaw. II. 2, aged 9, a very bright boy with normal teeth, had fundi like his brothers; V. $= \frac{6}{9}$. II. 3, aged 6 years, a very stupid little girl, suffered from night-blindness; V. $= \frac{6}{10}$; her fundus showed retinitis pigmentosa; she had been without any upper incisors for 18 months. No consanguinity recorded. Bibl. No. 211.

Fig. 94. *Herrlinger's Case* 86. II. 2, aged 26, had retinitis pigmentosa; he had divergent strabismus and myopia of $-4{\cdot}5$ D. for the R. eye, -8 D. for the left, corrected V. $= \frac{5}{30}$ for each. His brother was dead, but was reported to have had bad sight. The parents were first cousins, and the mother, I. 3, had bad sight, but was apparently not examined. The mother's brother, I. 2, was reported to be nearly blind; his children were almost idiotic, and had weak sight. Consanguinity. Bibl. No. 203.

Fig. 95. *Siegheim's Case* 16. Retinitis pigmentosa associated with deaf-mutism in II. 2, all the five siblings, II. 3, were deaf-mutes. The mother, I. 2, had good sight; the father, I. 3, was mentally defective, the state of his vision was unknown. The mother had normal children by her first husband. No consanguinity recorded. Bibl. No. 146.

Fig. 96. *Wider's Case.* Retinitis pigmentosa associated with mental defect and polydactyly in a brother and sister, the only children of normal parents, II. 1, aged 20, when examined had suffered from the disease since early youth; she was hypermetropic, had defective colour sense, greatly contracted fields, V. $= \frac{5}{24} - \frac{5}{18}$, and her fundus showed typical changes; she had six fingers on each hand, and six toes on each foot, and was mentally defective. II. 2, aged 14, when examined had also suffered from the disease for some years; he was myopic, had defective colour sense, concentric contraction of fields, V. $= \frac{5}{36}$, and his fundus also showed typical changes; he had the same associated defects as his sister, and also stammered. No consanguinity recorded. Bibl. No. 137.

Fig. 97. *Cant's Case.* Four cases of retinitis pigmentosa in a sibship of four; the father was epileptic. The disease increased in severity from the youngest, aged 5, whose fundus was dotted with minute pigmentary deposits at the periphery, to the eldest, aged 15, in which case the pigment was much more profuse and extended nearly to the centre of the retina; the retinal vessels were narrowed in the elder children, and the discs were pale. All were hypermetropic, and the two eldest boys had R. internal strabismus; fields of vision were greatly diminished in all; for the eldest V. $= \frac{5}{50}$ and J. 6, in the younger ones V. $= \frac{5}{18}$ and J. 4. All had difficulty in finding their way about in the evening, and saw very badly by artificial light; colour sense was normal. No consanguinity. Bibl. No. 139.

Fig. 98. *Herrlinger's Case* 18. III. 1, aged 39 years, had noticed that he had a marked diminution of vision for four years; he had retinitis pigmentosa, with contraction of his fields of vision; refraction was myopic (-2 D.), R. V. $= \frac{5}{12} - \frac{5}{9}$, L.V. $= \frac{5}{24}$; colour sense was normal. Two of his four siblings and a sister of his grandmother suffered from night-blindness. His parents had good vision. No consanguinity. Bibl. No. 203.

Fig. 99. *Webster's Case.* Retinitis pigmentosa in II. 2 appeared to follow a severe nervous shock due to the death of a daughter. II. 1 had imperfect vision, especially at night; no other members of the family were affected. No consanguinity. Bibl. No. 105.

Fig. 100. *Nettleship's Case.* IV. 1, aged 13 years, had retinitis pigmentosa; her two sisters were normal, her parents were normal and unrelated. III. 3, a first cousin of the father, III. 2, became blind at the age of 16, almost certainly from the same malady; his maternal grandparents, I. 1 and 2, were first cousins. Consanguinity. Bibl. No. 251, p. 28.

Fig. 101. *Mooren's Case.* Retinitis pigmentosa in a boy who was the offspring of uncle and niece, the parents and grandparents having normal vision. Consanguinity. Bibl. No. 114.

Fig. 102. *Herrlinger's Case* 66. IV. 1, aged 8 years, had very weak sight, but was able to go about alone; refraction was emmetropic; he had retinitis pigmentosa with very marked concentric contraction of his visual fields; he had nystagmus. One sister was born blind. The parents were healthy, and were first cousins once removed. No other case of retinitis pigmentosa was known in the family. Consanguinity. Bibl. No. 203.

Fig. 103. *Herrlinger's Case* 39. Retinitis pigmentosa in a brother and sister whose great-grandparents were first cousins. IV. 1, aged 9 years, had seen badly since early childhood; R.V. $=$ L.V. $= \frac{5}{9}$, refraction was myopic; he had defective colour vision and retinitis pigmentosa with some contraction of fields of vision. His only sister was similarly affected. The parents and other relatives were normal. Consanguinity. Bibl. No. 203.

Fig. 104. *Herrlinger's Case* 36. II. 2, aged 66, had had weak sight since her youth; she had retinitis pigmentosa, and her vision was now reduced to finger counting. Her brother who was dead had suffered from night-blindness. Their parents were normal. II. 2 had six children who all saw well, but one of

them married a cousin, and had two boys who suffered from an atypical retinitis pigmentosa. Consanguinity. Bibl. No. 203.

Fig. 105. *Wilbrand and Saenger's Case.* Retinitis pigmentosa in a brother and sister, the offspring of first cousins. Consanguinity. Bibl. No. 264.

Fig. 106. *Rosenbaum's Case.* Retinitis pigmentosa in II. 1, aged 18, he had been night-blind since childhood; fundi were typical of the disease; R.V. $= \frac{8}{12}$, L.V. = 1. His father was night-blind. No consanguinity recorded. Bibl. No. 213.

Fig. 107. *Oakley's Case.* I. 1 with retinitis pigmentosa married a near relative; they had seven children, of whom the only survivor, a son aged 27, reported that he had had bad sight since childhood, and had been told at the age of 9 years that he had retinitis pigmentosa. Consanguinity. Bibl. No. 159.

Fig. 108. *Gonin's Case.* In a sibship of seven brothers the first, third and fifth born suffered from night-blindness, which developed about the age of 25 years; the seventh born was at the time of the report only aged 24, but had not so far complained of his sight. The parents were normal and unrelated. One case only was examined, he, II. 3, aged 36, had a visual acuity of $\frac{1}{2}$ for the right eye and $\frac{5}{6}$ for the left; his fields were much contracted in a reduced light, and there was found to be a typical, though not very extensive, pigmentation of the retina, the pigment for the most part was to be seen on the nasal side in the equatorial region. No consanguinity. Bibl. No. 215.

Fig. 109. *Rosenbaum's Case* 20. Retinitis pigmentosa in six members of a sibship of eleven. No consanguinity recorded. Bibl. No. 213.

Fig. 110. *Wilbrand and Saenger's Case.* Retinitis pigmentosa in two siblings who had two deaf siblings, the parents were blood relations. Consanguinity. Bibl. No. 264.

Fig. 111. *Wilbrand and Saenger's Case.* Unilateral retinitis pigmentosa in a man aged 46. II. 2, aged 46, had V. $= \frac{6}{9}$ for the left eye which was ophthalmoscopically normal; for the right eye V. = fingers at 2·5 m., he had a posterior cortical cataract and retinitis pigmentosa. At the age of 14 the patient had noticed by chance that he saw badly with his right eye, and he believed that the vision had remained much the same since that time, he was night-blind in that eye, and the field of vision was contracted almost to the fixation point; with Förster's photometer after 10 minutes adaptation he could see through an opening of 2 mm. with the left eye, but with the right eye he required an opening of 22 mm. after 32 minutes adaptation. A sister, aged 51, was almost blind, and was deaf. Syphilis was apparently not present. No consanguinity. Bibl. No. 264.

Fig. 112. *Herrlinger's Case* 92. Retinitis pigmentosa in a girl aged 16 whose parents were second cousins, her two grandmothers were first cousins; her father saw badly by day and by night, but was apparently not examined; her three siblings were healthy. II. 1 had suffered from night-blindness from an early age; she had slight myopia, R.V. $= \frac{5}{9} - \frac{5}{6}$, L.V. $= \frac{5}{7 \cdot 5}$; colour vision was normal, and there was concentric contraction of her fields of vision. Consanguinity. Bibl. No. 203.

Fig. 113. *Derby's Case.* II. 1 was seen, aged 3, his parents having noticed imperfect vision at night for 15 months; the child was restless and difficult to examine, and the ophthalmoscope revealed nothing. Five years later the child with his sister, II. 2, aged 7, were seen; each was night-blind, and showed changes typical of retinitis pigmentosa; their visual fields were contracted, V. = 0·2 for II. 1 and 0·4 for II. 2. Both patients showed improvement under treatment with constant current. No further cases of retinitis pigmentosa were known in the family. No consanguinity. Bibl. No. 149.

Fig. 114. *Höring's Case.* I. 1 and 2, a healthy and normal brewer and his wife living in comfortable circumstances in a healthy district, had five children. The three eldest, aged 15, 12 and 11 years respectively, were normal, the two youngest, a girl aged 9 and a boy aged 5, were extremely stubborn and difficult in temperament, the girl had six toes on each foot, and six fingers on her left hand, the boy had twelve toes and twelve fingers, and they both suffered from night-blindness, with fundal changes typical of retinitis pigmentosa. No consanguinity recorded. Bibl. No. 49.

Fig. 115. *Wilbrand and Saenger's Case.* II. 2, aged 23, had retinitis pigmentosa, he had seen and heard badly since birth; R.V. = L.V. $= \frac{6}{18}$; the fields of vision were greatly contracted. His eldest sister, aged 34, also had bad sight and hearing; his eight other siblings had normal vision, but two of his younger sisters were epileptic. The father was a great drinker. No consanguinity. Bibl. No. 264.

Fig. 116. *Leber's Case.* Retinitis pigmentosa following an extremely rapid course in three consecutive siblings, a girl and two boys. The disease appeared when they were aged 6 or 7 years, and after from 9 to 18 months each was completely blind; there was no associated night-blindness in these cases. No consanguinity recorded. Bibl. No. 98.

Fig. 117. *Harlan's Case.* Seven cases of retinitis pigmentosa in a sibship of twelve. II. 1, aged 38, could distinguish large letters till the age of 18, but was now absolutely blind; pupils dilated and fixed, external strabismus. II. 2, aged 28, could read large letters till the age of 20, she can now just distinguish day from night; pupils dilated and fixed, strabismus. The ophthalmoscopic appearances were very beauti-

fully marked in both cases. Seven out of the twelve children of this sibship were born partially blind, the condition increasing with age. II. 3—7 are not so blind as the two described above. Parents were healthy and lived to old age. No cases of retinitis pigmentosa were known in previous generations. No consanguinity. Bibl. No. 82.

Fig. 118. *Fergus's Case.* II. 1 had retinitis pigmentosa diagnosed twenty years ago; she had been unable to read or write for twelve years, and her vision was now reduced to a very faint perception of light and shade. The author describes various subjective colour phenomena experienced by the patient, and is of the opinion that they indicate the last stages in the destruction of the retinal function. One brother and two maternal relations were also affected. Four living siblings had normal vision, five siblings were dead. The parents were first cousins. Consanguinity. Bibl. No. 288.

Plate VIII. Fig. 119. *Usher and Smith's Case.* This pedigree is of very special interest, for it is the only example found in the literature of the subject showing the result of intermarriage between two individuals, one of whom was suffering from retinitis pigmentosa and the other from congenital stationary night-blindness without fundus changes; of the four children born of these parents two had normal fundi, one had choroideremia, and one had typical retinitis pigmentosa. We are greatly indebted to Usher for allowing us to publish the beautiful colour sketch which he had prepared showing the appearance of the fundus in the case of choroideremia: we believe it to be the first coloured plate of the condition to be published in this country. See Plate B.

IV. 7, Alexander E., aged 24 (1914), was a butchers' messenger boy; he had no history of serious illness, but had been delicate as a child, was irritable, slept badly at night, and required much attention; he was subject to chilblains on ears and fingers; he had been night-blind as long as he could remember, but reported that his vision was no worse than it had always been. There was nothing abnormal about the eyes externally, though when dilated the pupils were of a pale reddish apple jelly colour; refraction: R. myopia 4 D. in horizontal meridian, 6·5 D. in vertical meridian, V. with correction $= \frac{6}{18}$; L. myopia 3·5 D. in horizontal, 5 D. in vertical meridian, V. with correction $= \frac{6}{24}$. Night-blindness was marked; fields of vision, tested with a 10 mm. white square in good daylight, were contracted to within 10°, though in the left field there was a narrow seeing area down-out extending to 50°; result of tests for colour vision were unsatisfactory and not uniform. Ophthalmoscopic examination showed small opacities in both lenses and a single small translucent floating opacity in each vitreous. The appearances in each fundus were similar; the light reflected into the pupils at one or two feet distance produced a white reflex which became pink when he fixed the mirror; on direct or indirect examination most of the fundus of each eye appeared to be white; at some parts, especially near the discs, there was very faint mottling, just an indication that the white was not quite uniform. The optic disc had a good red colour; there was no physiological cup, and the edge of the disc was not clearly defined. The retinal vessels were little, if at all, narrowed, no white lines were seen along their edges, they had a normal distribution. The vorticose veins were conspicuous, most of them received branches from peripheral parts of the fundus only, but vessels from the macular region communicated with branches of some of them; some of the vorticose veins disappeared suddenly, others appeared to gradually pass more deeply into semi-translucent white tissue. Close to the outer edge of the left optic disc was a large congeries of very small tortuous blood-vessels closely packed together, which converged towards a few large vessels at the edge of the plexus believed to be veins draining the macular plexus formed presumably by posterior ciliary arteries; some retinal vessels passed in front of the vessels in the plexus, but none were found to anastomose with them. At the macula of the right eye was a much smaller congeries of similar vessels partly covered and largely hidden by a fairly homogeneous red layer with scanty pigment; no vessel passed from the edge of the optic disc to either plexus; no vessels were seen which correspond to the long ciliary arteries. Some pieces of branched pigment were scattered sparsely over the fundus. At the extreme periphery of each fundus were a few narrow areas of dark red fundus visible with widely dilated pupils, they were in marked contrast with the rest of the fundus, their margins, usually well defined, were irregular and formed bays, and at some parts choroidal vessels passed from beneath them to the venae vorticosae. There were a few small islands of what seemed to be pigmented retinal epithelium to judge by their colour and relation to retinal vessels. A detailed account of the physical condition of the patient and of former examinations of his eyes are given by the author. Of the siblings of IV. 7, a sister, aged 26, IV. 5, and a brother, aged 24, IV. 6, had normal fundi and good vision. A younger sister, IV. 8, aged 22 (1912), suffered from night-blindness; refraction: R. myopia 1 D. in vertical and hypermetropia 2 D. in horizontal meridian, V. with correction $= \frac{6}{18}$; L. myopia 5 D. in vertical and hypermetropia, 2 D. in horizontal meridian, V. with correction $= \frac{6}{12}$; media were clear; optic discs possibly rather too pale, arteries narrowed; the periphery of each fundus was studded with dark moss-like pigment; no patches of choroidal atrophy were present; fields showed incomplete relative ring scotoma, and were contracted; Wassermann test negative. She and her brother, IV. 7, were fat, heavy and expressionless, their two normal siblings were more fresh and alert.

The father of this sibship, III. 7, aged 54, had congenital night-blindness without fundus changes, and was myopic. For him fields of vision were full, colour sense normal, media clear, discs and retinal

vessels were normal, and there was no retinal pigmentation; he had myopia in each eye of 7·5 D., R.V. with correction = $\frac{6}{18}$, L.V. with correction = $\frac{6}{12}$ partly; night-blindness was marked. He was twice married, but had no children by his second wife.

The mother, III. 41, died in 1910 of heart disease; she was the illegitimate child of II. 17 and probably II. 18; her fundi had been examined and retinitis pigmentosa diagnosed in 1905; her husband reported that she saw well at night. No cases of night-blindness were known in the ancestors of III. 41, but her mother, II. 17, appears to have been dissolute, and seldom sober after the death of her husband. A maternal uncle of the father, II. 1, was reported to have been night-blind from his earliest days, and to have been myopic; information concerning him was obtained from his son, III. 5, who was a medical man, and who did not know of any other case of the defect amongst his ancestry.

A considerable number of the normal members of the pedigree were examined by the author, and information concerning them is given in the original history. No consanguinity. Bibl. No. 310.

Fig. 120. *Nettleship's Case.* Retinitis pigmentosa in at least four children in a sibship of eight, the offspring of first cousins. IV. 1 and 2 were affected girls, IV. 3 and 5 were affected boys; IV. 6 and 7 were too young to test, IV. 8 died aged 10 months. The parents were normal, their fathers, II. 2 and 3, were brothers; their mothers, II. 1 and 4, were remotely connected also. Consanguinity. Bibl. No. 251, p. 37.

Fig. 121. *La Gleyze's Case.* (Taken from Nettleship.) Two cases of retinitis pigmentosa in the offspring of uncle and niece. Parents and grandparents were normal, but two of the father's first cousins, II. 4 and 5, had retinitis pigmentosa. Consanguinity. Bibl. No. 251, p. 28.

Fig. 122. *Siegheim's Case.* Retinitis pigmentosa in IV. 1, sex not given. One brother had weak sight and was night-blind, two brothers and one sister were normal. The father had normal vision, the mother had "weak" sight, one maternal uncle was blind, two aunts and one uncle, siblings of the mother, had normal vision. The maternal grandfather and great-grandfather were blind. It is to be regretted that only one case was apparently examined, and so little information is given of the other affected members of the family. No consanguinity recorded. Bibl. No. 146.

Fig. 123. *Nettleship's Case.* Seven cases of retinitis pigmentosa in a sibship of eight, III. 1—8. Of the affected members four were males, three were females; the unaffected member of the sibship was a male. The parents were normal and unrelated, but a maternal great-uncle had retinitis pigmentosa. No consanguinity. Bibl. No. 251, p. 18.

No. 124. *Leber's Case.* Retinitis pigmentosa in a boy whose grandfathers were brothers, and whose grandmothers were sisters; his three siblings were normal. The boy, aged 12 years, was blind; fine spots of pigment were scattered over the whole fundus, and occasionally pigment flecks of the bone corpuscle type were to be seen along the retinal vessels; the vessels, especially the arteries, were greatly narrowed; the boy also had some defect in his speech. Consanguinity. Bibl. No. 72.

Fig. 125. *Smyth's Case.* (Taken from Nettleship.) Two cases of retinitis pigmentosa in a sibship of six. III. 1, 3 and 4 were living, and had perfect sight; III. 2, twin to III. 1, died soon after birth. III. 5, a boy aged 10 years, had been noticed to be night-blind at the age of 2, he now had typical retinitis pigmentosa. III. 6, a boy aged 4, was night-blind at the age of 3 years, and now had a few patches of pigment at the periphery of each fundus, with somewhat shrunken retinal arteries. The parents were normal and unrelated. There was a history of phthisis in the mother's maternal aunt, I. 4, in her paternal uncle, I. 1, and in three of her paternal cousins, II. 1, 2, 3. No consanguinity. Bibl. No. 251, p. 354.

Fig. 126. *Rosenbaum's Case.* Retinitis pigmentosa in two brothers whose paternal grandparents were first cousins. III. 1 was seen, aged 9, when he was suffering from phlyctenular conjunctivitis, the fundi were then normal; three years later he was night-blind, and had typical retinitis pigmentosa with visual acuity reduced to $\frac{8}{36}$; the disease progressed rapidly in his case. III. 2, aged 8, was seen with typical retinitis pigmentosa; for him V. = $\frac{1}{2}$. Consanguinity. Bibl. No. 213.

Fig. 127. *Rosenbaum's Case.* Retinitis pigmentosa in III. 1, aged 20 years; V. = $\frac{8}{24}$; fields greatly contracted; the pigmentation of the retina reached almost to the macula region. The father, grandfather and a paternal uncle suffered from night-blindness. No consanguinity recorded. Bibl. No. 213.

Fig. 128. *Oakley's Case.* Retinitis pigmentosa in three, probably in four generations. III. 3 seen, aged 46, was anaemic, but had always had fairly good health, he was wearing spectacles of −5 D. for myopia, and had been told twenty years previously that he had retinitis pigmentosa; the disease made very little progress until a year ago, when his sight became rapidly worse. His parents, II. 2 and 3, were first cousins, and his father, who died aged 56, had bad sight, and was nearly blind at the time of his death. He believed that his grandfather's sight was also very bad. His mother and her three daughters by a second marriage were all examined and found normal. The younger brother of III. 3 by the first marriage also had retinitis pigmentosa. The paternal aunt, II. 4, had retinitis pigmentosa, married her first cousin, and transmitted the disease to one of her six children. III. 3 married his first cousin with normal eyes, and had two children, a son aged 14 years with retinitis pigmentosa and myopia, and a daughter with normal eyes. Consanguinity. Bibl. No. 159.

Fig. 129. *Leber's Case.* Retinitis pigmentosa in four generations. IV. 2, aged 26 years, had seen badly and been under treatment since boyhood; he suffered from night-blindness, which had apparently not progressed recently; the discs were whitish in colour, and oval in shape, and were surrounded by a ring of choroidal atrophy; the vessels were narrowed, and there were pigment flecks lying along the retinal vessels; choroidal vessels showed very distinctly. The elder brother of IV. 2 was said to be similarly affected, also his mother with her brother and sister; his grandmother and his great-grandmother were said to have suffered from the disease, his younger sister had normal vision. No consanguinity recorded. Bibl. No. 72.

Fig. 130. *Ayres' Case.* IV. 1, seen, aged 44 years, had marked retinitis pigmentosa, the pigment extending to the disc, and the field of vision being reduced to the point of fixation; his only sister had normal eyes. III. 5, mother of IV. 1, died, aged 66 years, and was blind for several years before her death from the same disease; two of her sisters had normal eyes, one sister and one brother were nearly blind. II. 2, maternal grandmother to IV. 1, aged 89 years, had been blind for many years. I. 2, maternal great-grandmother to IV. 1, and one or two of her brothers were blind. It is unfortunate that only one case apparently, in this interesting pedigree, was examined. No consanguinity. Bibl. No. 138.

Fig. 131. *Ayres' Case.* II. 1, a negro, aged 45, had been night-blind for more than twenty years; he had myopia of 2·5 D. for R. eye, 3 D. for L. eye; fields of vision were contracted, and the fundus showed typical retinitis pigmentosa at a rather advanced stage. He had several normal siblings. This was the only case of retinitis pigmentosa seen by the author in a coloured race. No consanguinity. Bibl. No. 169.

Fig. 132. *E. Schmidt's Case.* II. 4, aged 9, and II. 5, aged 5, were said to have retinitis pigmentosa and nystagmus, and to have one sibling who also had bad eyes. Two children of some distant relation of the father were blind, and also the brother of this relation had a blind child. The mother's brother had two blind children. It is unfortunate that no further information was given concerning the nature of the blindness in these cases. No consanguinity in parents or grandparents of II. 4—6. No consanguinity recorded. Bibl. No. 163.

The Usher Series of Pedigrees of Retinitis Pigmentosa.

The following forty-one pedigrees, all worked out by Usher, are of the greatest value both as a collection and also for the wealth of detail which has been given for the individual cases and histories. An extensive family history was taken for forty-one consecutive cases of retinitis pigmentosa seen by the author, (who only omitted a few cases for which no information could be obtained or in which the diagnosis was doubtful), in order to demonstrate whether or no the marked tendency to inheritance of this disease indicated by published histories was to some extent due to selection of cases, authors generally tending only to publish pedigrees in which several members were known to be affected. Nettleship had noted many apparently isolated cases, but he suspected that if sufficient were known of the antecedents of such cases, a hereditary origin could often be demonstrated for them. Usher has clearly shown that such isolated cases do undoubtedly exist, and that in them the defect is not an inherited one; such cases, however, in no sense weaken the significance of the marked hereditary nature of the disease in certain stocks.

We have reproduced many of the pedigrees of this series in full, some of those for isolated cases have only been included in our collection in an abridged form, not indeed from any lack of interest and appreciation for such pedigrees but partly on account of space and cost of reproduction, and also because we hope this will encourage the student of heredity to study the author's original work which contains a great wealth of information the significance of which can be grasped from the author's description far better than from any reproduction.

Usher examined and described a great number of normal as well as affected members in all the families concerned; Wassermann tests were made on many individuals and the most careful enquiry was made throughout for associated defects in affected or unaffected branches of the stocks.

PLATE IX. Fig. 133. *Usher's Case* 14. One case of retinitis pigmentosa and two cases of coloboma of the optic nerve in a sibship of thirteen, also a case of retinitis pigmentosa in a sibship of seven in the same generation. IV. 49, aged 25 (1910), was less robust than his siblings though he had no history of serious illness or bleedings and was not subject to cold fingers and toes; he was night-blind, and defect was first noticed in his vision after he went to school; media clear, discs pale, retinal arteries very narrow and moss-like pigmentation of retina most abundant towards the periphery was in relation to veins and not arteries; no spots or patches of choroidal atrophy; close to inner edge of R. disc were three small grey slightly raised bodies; refraction was hypermetropic, with correction R.V. $-\frac{6}{12}$, L.V. $-\frac{6}{12}$; fields of vision were not contracted but a complete absolute ring scotoma was present in each; Wassermann test negative. His sister, IV. 45, aged 30 (1910), had been married for six years but had no child, she was examined by

Dr Souter; the L. eyeball was smaller than R.; there was defective outward movement of each eye and lateral nystagmus on lateral movement of eyes; in the central part of each fundus there was a circular white area several times the size of a normal disc, it had a well-defined margin, retinal vessels converged to a part near its upper edge; two small white patches of choroidal atrophy were present below this area in R. eye and some choroidal atrophy was present at same position in L.; coloboma of optic nerve was diagnosed; the rest of the fundus, the lenses and irides were normal; the refraction was hypermetropic, corrected vision for R. $= \frac{6}{36}$, for L. $= \frac{6}{60}$. R. field of vision had a large defect above extending from the periphery nearly to fixation point. IV. 46, male, aged 31 (1912), had constant lateral nystagmus; the R. eye was microphthalmic and its disc was replaced by a large crater-like depression two or three times the size of the normal disc, with some choroidal atrophy adjoining its lower part; there were opacities at outer and posterior parts of lens; refraction was hypermetropic; V. with correction = finger counting; the left O. D. was larger than normal, refraction myopic, 6 D.; corrected vision $= \frac{6}{36}$; large sector absent at upper part of field of vision; no night-blindness. Of the other siblings seven of whom were examined all had normal fundi and good vision. IV. 43 was myopic, R. 1·5 D. in oblique meridian, 2·25 D. in opposite meridian, L. 2 D., corrected V. $= \frac{6}{6}$ in each. The children of all the siblings had normal fundi except V. 30, a boy, aged 12 (1908), who had hydrocephalus and double optic atrophy. The mother, III. 43, her parents, II. 22 and 29, and one of her grandparents, I. 3, had good sight, little was known of I. 4. The father, III. 24, his parents, II. 9 and 17, and his grandparents, I. 1 and 2, saw well, but a grandchild of II. 9 by another wife, II. 4, had retinitis pigmentosa. Thus IV. 24, female, aged 32 when seen, had always been night-blind, she had no history of illness or bleeding; retinal vessels showed some narrowing, O. D.'s no marked pallor, choroidal vessels exposed only at periphery; in each eye a small area below showed retinal moss-like pigmentation; some vitreous opacity; the fields were contracted at upper part, at some parts below they were full, but there was a commencing ring scotoma below in each; refraction hypermetropic, corrected V. $= \frac{6}{12}$ in each; Wassermann test positive, she lived in a remote country place and had no appearance of syphilis. Siblings of IV. 24 all saw well. II. 4 suckled III. 24 at the same time that she was suckling her own son, III. 11, and the night-blindness in the offspring of these two was attributed to the mental shock of II. 4 when she learned that III. 24 was her husband's illegitimate child. III. 11 had a normal fundus and good vision, Wassermann test negative, his wife also had good sight.

The only further defects known in this extensive pedigree are deaf-mutism in IV. 66, a second cousin of IV. 49, he was a shoemaker and was not night-blind; myopia in IV. 10, first cousin to IV. 24, and in V. 43. No consanguinity. Bibl. No. 301.

Fig. 134. *Usher's Case* 19. A very extensive pedigree showing two cases of retinitis pigmentosa in a sibship of six, a third case in another sibship of the same generation, and a fourth case in a sibship of the previous generation. V. 13, a fisherman, aged 31 (1908), had noticed that he had defective vision especially at night for three years; he had marked retinal pigmentation especially at inner part of fundus, narrowed retinal arteries and contracted fields; with correction of + 1D. for R. and + 2D. cyl. for L., R.V. = L.V. $= \frac{6}{24}$; seen again in 1912 when he had just returned from a lunatic asylum the condition had progressed; he had had no illnesses or severe bleedings; Wassermann test negative; he was married and had three young children who had normal vision. V. 15, aged about 33 (1912), was very weak mentally and physically, and marked night-blindness had been noticed when he went to school; he read print about the size of 1 J.; fields of vision were much contracted; retinal vessels narrowed; discs pale; extensive typical retinal pigmentation; Wassermann test negative. Of the siblings of V. 13 and 15 one died, V. 20, three had good vision, and V. 19, who was examined had a normal fundus; the children of V. 17 saw well. The parents, IV. 4 and IV. 22, were normal, and the father, IV. 22, had three unaffected children by his second wife. The mother's parents, her grandparents and one great-grandparent had good vision; II. 2, her grandfather, was noted for his bad temper; there were three cases of mental defect in this branch of the family, V. 1, and two cases of myopia, V. 1 and 3. The father's parents, his grandparents, and one of his great-grandparents, I. 12, had good vision, his father, III. 22, became mentally affected at the age of 45, but recovered; the father of III. 23 is doubtful. Of the father's eight siblings seven were normal, one had congenital ptosis, III. 32; one of his great-nephews, VI. 13, had spina bifida.

V. 42, female, aged 16 (1912), had always had difficulty in seeing in a dim light, appearances of both fundi were quite typical of retinitis pigmentosa (case described by the author); Wassermann test positive. Of her siblings V. 39 died aged 3 months; V. 40 was mentally defective and showed evidence of hereditary syphilis, retinal vessels were narrow, discs pale, moss-like pigmentation was present at the periphery in R., in L., a myopic eye, there was dense black pigment, not moss-like, at lower and outer part of fundus only; R.V. = finger counting, L.V. = 1J.; no night-blindness. V. 41 had choroido-retinitis at the age of 3 (1894), when seen in 1913 there was choroido-retinitis affecting the whole fundus, the macula being least affected; R.V. $= \frac{6}{18}$, L.V. = no perception of light. V. 43 had a normal fundus. The mother of this sibship, IV. 58, had no miscarriages but had been treated for syphilis, she had a normal fundus and good vision. The father, IV. 46, was reported to have had venereal disease, he was alcoholic; one of his brothers, IV. 45, was in a lunatic asylum, his other siblings and the children of two of them had normal vision. The maternal grandparents of V. 42 were first cousins, they and their parents had normal vision; the ancestry on the

father's side in the direct line was normal, but several cases of mental defect occurred in the collateral branches.

IV. 14, fisherman, aged 30 (1897), complained of "gradual weakness in both eyes" for 20 years; he had typical retinitis pigmentosa (case described by author); refraction my. R. 7 D. in oblique, 9 D. in opposite meridian, corrected V. $\frac{6}{18}$, for L. 5 D. in horizontal, 6 D. in vertical meridian corrected V. $\frac{6}{18}$; he was seen again in 1904 and 1906, in 1912 he was dead; Wassermann test not taken. Three of his siblings, IV. 9, died young from croup, IV. 13 was peculiar, seldom did any work and wandered about with a gun aimlessly. The parents of this sibship were first cousins, they, their parents and grandparents were reported to have normal vision.

For further cases of mental defect in the more distant relatives of the affected sibships, see the pedigree or the author's original account of the family. I. 6 was related to the sibship I. 12—19, they were probably first cousins; there were no fewer than 19 cousin marriages which were not indicated in the pedigree as the figure became too complicated. Consanguinity. Bibl. No. 301.

Fig. 135. *Usher's Case* 3. Possibly three cases of retinitis pigmentosa and one case of congenital ptosis in a sibship of twelve. IV. 36, female, aged 30 (1897), had always had bad sight, her vision had got gradually worse, she was night-blind, and retinitis pigmentosa was diagnosed at this date. In 1912 R.V. $= \frac{1}{60}$, L.V. $= \frac{2}{60}$, no myopia; fields of vision very much contracted; posterior cortical lens opacities were present and the appearance of each fundus was typical of retinitis pigmentosa; Wassermann test negative; she was a gloomy individual with no history of illness or bleedings. Of her siblings, IV. 26, a male, had a stillborn child; IV. 28 had some nose trouble, she and her six children saw well; IV. 29, a male, who died aged 30, was reported to have had defective sight similar to that of his sister; IV. 30 died, aged 37, of appendicitis, she and her six living children had good vision; IV. 32 was not strong, she was married but had no child, her sight was good; IV. 33 was healthy but had some nasal trouble, she had an illegitimate daughter who had a child; IV. 35 had weak sight though not so pronounced as in IV. 29 and IV. 36, he was of strong build and died, aged 24, in a lunatic asylum, nothing had been noticed to be the matter with him until one warm day in August when working in the hayfield he suddenly complained of pain in his head, and all at once became insane, he died a few days afterwards; IV. 38 was not very strong, but he and his ten children saw well; IV. 40 died in infancy; IV. 41 had had ozaena and depressed bridge of nose as long as she could remember, her nine children were healthy and saw well; IV. 44 had congenital (partial) ptosis on the right side, he and his three children saw well.

Of the ten children of IV. 36 five had normal vision, V. 41, 44, 46, 47, 48; V. 49 was a miscarriage; V. 50 had a normal R. fundus, the left optic disc was twice as large as the right, its outer part pale and cupped (coloboma of optic disc); V. 42, aged 22 (1913), had fields nearly full with a complete ring scotoma in each, in R. field the scotoma is absolute up in and down out and relative up out and down in, in L. field the scotoma is absolute except at inner part at 90°; refraction, as in 1906, my. R. 10 D. in horizontal meridian, 13 D. in vertical, L. 13 D. in horizontal, 16 D. in vertical meridian; corrected V. for each $\frac{6}{12}$; night-blindness appeared to be present, but was not marked; slow adaptation to dark after coming out of light; the discs were a good colour; retinal arteries of full size; a posterior staphyloma with complete choroidal atrophy was present in each; one spot of pigment at outer part of R. retina was present; had cold hands; Wassermann test positive. V. 43 had myopia R. 3 D., L. 4·5 D.; V. 45 had myopia of not more than 1·5 D. in each.

The parents of IV. 36 were first cousins, they and their parents were healthy and lived to old age with good vision; the father had a deaf-mute first cousin, III. 1, and a first cousin who died of phthisis in middle age, III. 2; the mother had six siblings of whom four died of phthisis, one of these being also mentally defective. I. 1 and 2 lived to old age, but nothing was known of their vision. Further information concerning more distant relatives may be obtained from the original history. Consanguinity. Bibl. No. 301.

PLATE X. Fig. 136. *Usher's Case* 30. Two, possibly four cases of retinitis pigmentosa in a sibship of eleven, three other supposed cases in other generations. III. 6, female, aged 66 (1898), had no difficulty in seeing until the age of 25; she had extensive retinal pigmentation at the periphery, though the extreme periphery was free; retinal vessels were much narrowed, the discs a yellowish white colour, and she had posterior lens opacities; refraction myopic, 9 D. in R., 4 D. in L., with correction R.V. $= \frac{6}{18}$, L.V. $= \frac{6}{36}$; fields of vision concentrically contracted to 10°. III. 13, female, in her dotage (1910), fundi were seen with difficulty, she had small pupils and probable lens changes, but retinal pigmentation could be seen at the periphery; vision had failed gradually, and she was nearly if not quite blind; she had a history of night-blindness. III. 19, was night-blind, he died aged 58, was "always short-sighted; got glasses, but did not benefit by them." III. 3, male, was said to have been affected in the same way as III. 6 and 13. III. 4, female, was bedridden, she had senile cataract, and neither fundus was visible. III. 8 was drowned, aged 32. III. 9, aged 74, was myopic, fundus normal except for crescent in L. III. 12, died in infancy. III. 15 had good sight. III. 17, aged 63, had normal fundi. Parents and grandparents of this sibship had good vision.

IV. 28, the eldest son of III. 13 was "silly," and died in a lunatic asylum; his vision was said to be

"just the same as his mother's." The other three children of III. 13, with their children and grandchildren, had normal vision. IV. 4, the second child of III. 3, aged 62, was myopic, had lens opacities, and was deaf, he had a posterior staphyloma; he was not night-blind, and had no retinal pigmentation; one of his five children, V. 6, was myopic, but had no retinitis pigmentosa or night-blindness. IV. 27, youngest of the ten sons of III. 9, was myopic, but had normal fundi and no night-blindness.

In generation II two members, II. 7, maternal uncle to the affected sibship of generation III, and II. 13, first cousin to II. 7, were both reported to have been night-blind. For further information concerning normal members see the original pedigree and author's account. No consanguinity. Bibl. No. 301.

Fig. 137. *Usher's Case* 34. Probably two cases of retinitis pigmentosa in a sibship of four, the offspring of first cousins, in a pedigree where there has been much intermarriage. V. 15, a sullen and morose fisherman, aged 31 (1899), never had good sight, and it had gradually become worse; he did not see well in a bright light, and his sight was best at sunset and sunrise, sight was bad for some considerable time when he went from a light to a dark place and vice versâ; no serious illness; the retinal arteries were very narrow; there was scanty retinal pigmentation at the periphery of the fundus; the discs were of a uniform red colour; choroidal vessels readily seen; he had low hypermetropia and V. $= \frac{6}{36}$ for each; fields of vision were contracted. In 1909 vision was reduced to finger counting at 7 feet, he had marked posterior cortical cataracts in each, and there was retinal pigmentation over the whole periphery of the fundus; the discs were a good colour, retinal arteries extremely narrow. V. 16 died aged 30, of "consumption"; her vision was defective like her brother's; she was night-blind, and fears were entertained that she would fall over the pier. The two sisters, V. 13 and 14, had normal fundi; V. 13 had four normal children, V. 14 married her first cousin, and had no offspring. The parents, grandparents, and great-grandparents had no known defect of vision, one great-grandparent, II. 9, was mentally affected for eight years before his death. II. 13 had the same name as II. 7—10, but was not known to be related. III. 34, a maternal great-uncle, was latterly mentally affected. No defects of vision were known in generations II. and III. In generation IV. one paternal uncle, IV. 11, and one more distant relation, IV. 15, had myopia; IV. 11 had for years taken large quantities of laudanum, he had eleven children, V. 11, of whom two were myopic, and one was mentally defective. One maternal first cousin, V. 30, was a mentally defective deaf-mute; his parents were first cousins, and he had six normal siblings. One further case of deaf-mutism occurs in the pedigree, V. 36. The husband of V. 14, namely V. 34, her first cousin, had uniocular simple optic atrophy, the rest of the fundus being normal, he had no central scotoma, and tension was normal, but his vision had never been good.

IV. 34 was a cripple; VI. 17, an imbecile, died aged 9; VI. 16, died aged 2; VI. 19, aged 31, had a slight stammer and typical symmetrical lamellar cataract; he had four children with normal vision. Additional cousin marriages, not shown in the pedigree, took place between IV. 39 and 42, V. 32 and VI. 25, V. 3 and V. 17. Consanguinity. Bibl. No. 301.

PLATE XI. Fig. 138. *Usher's Case* 9. Two cases of retinitis pigmentosa in a sibship of four, and one case in their half-uncle. IV. 47, male, aged 32 (1909), an exceptionally strong man, was very deaf, and had defective vision which was noticed by his father before he was aged 6; he had marked night-blindness; fields of vision were contracted to 10°; the R. eye could read 1 J. at 11 inches with correction for mixed astigmatism, the L. eye read the same with correction for low myopia; discs were pale, retinal arteries contracted and moss-like retinal pigmentation was all around the periphery; choroidal vessels were much exposed; Wassermann test negative. IV. 49, aged 23 (1905), was very able, and had been first of his year at college; defect in his vision was noticed before the age of 6; he was also very deaf; he was night-blind, and fields of vision were contracted to 10°; refraction R. emm. in horizontal, my. of 1·25 D. in vertical meridian, corrected V. $= \frac{6}{12}$; L. hm. 1 D. in horizontal, my. of 1·75 D. in vertical meridian, corrected V. $= \frac{6}{18}$; opacity at posterior part of lenses; some vitreous opacity; much typical retinal pigmentation; choroidal vessels exposed; pupils reacted sluggishly to light; nystagmus was present; Wassermann test negative. IV. 48 had a normal fundus. IV. 50, aged 19 (1905), had no night-blindness, V. $= \frac{6}{6}$ in each, and fields were full, but there was some narrowing of the retinal arteries, the choroidal vessels were conspicuous at the periphery, and there were some fine granules of pigment in places in the R. periphery of the retina; he had excellent hearing. The mother, III. 55, died, aged 46, of an abdominal tumour, she was not night-blind. The father, III. 29, had a normal fundus, and there was no recorded case of defect in sight or hearing in any of his ancestry. The father of III. 55 had married three times; by his first wife he had three children, of whom one, a male, III. 48, was abroad, but was well known to his cousin, III. 29, he was night-blind, and was reported to be deaf, to lisp, and to have a defective sense of smell. The siblings of III. 48 had good vision. III. 55 was the only child of the second marriage of her father. By his third marriage, II. 39, had three children with normal vision. No other defects were known in this extensive pedigree. Consanguinity. Bibl. No. 301.

Fig. 139. *Usher's Case* 21. Three males and one female, with deaf-mutism and retinitis pigmentosa in the offspring of first cousins, and four further cases, in their cousins, of deaf-mutism and probably retinitis pigmentosa in a sibship, also the offspring of first cousins. IV. 35, male, aged 33 (1906), a deaf-mute, was

in a blind asylum; the discs were pale, the retinal vessels extremely narrow, the choroidal vessels much exposed; extensive retinal pigmentation extended to the O. D.; the fields of vision were very much contracted, and he was night-blind; he had slight hypermetropia; V. for R. = finger counting at 6 feet, for L. = reading 16 J.; Wassermann test negative; his wife was normal, but they had no children. IV. 36, a farmer, was a deaf-mute; he had posterior cortical cataracts; marked retinal pigmentation, discs pale, retinal vessels very narrow, and was night-blind; he could read the newspaper with a high magnifying glass; he had a R. divergent strabismus. IV. 37, twin brother to IV. 36, died, aged 4 months, of teething fever; it was not known whether he was deaf. IV. 38, a deaf-mute, had commencing posterior cortical cataracts, very extensive retinal pigmentation, discs were pale, retinal vessels narrow, and he was night-blind; he had low hypermetropia, and was able to see enough to get about by himself. IV. 39 was still-born. IV. 40, aged 30 (1911), a very intelligent female, was a deaf-mute; she was night-blind, and had retinal pigmentation confined to the periphery of the fundus; she had some hypermetropia, and enough vision to read the newspaper through a strong glass. None of these cases had a history of severe illness or bleeding; in all the night-blindness was first noticed on going to school; no evidence of syphilis. Of the other siblings, all were believed to have normal sight and hearing, and the fundus was normal in two cases examined, and in two children of the next generation who were examined. IV. 28, died, aged 16, of typhoid fever. IV. 32 was stillborn. The parents, who were first cousins, had good sight and hearing; they died in middle age. The maternal grandmother, II. 11, married three times; by II. 10 she had one child, a son, who died of phthisis, aged 19; by II. 12 she had a daughter, III. 10, the mother of the sibship IV. 25—40; by II. 13 she had three children, III. 20, who died of phthisis, aged 33, III. 22, who was weakly in mind and body, did odd jobs, and was "nearly silly," and III. 23, who died, aged 50, leaving four normal children. The paternal grandmother, II. 18, with good sight and hearing, also married twice; by her first husband, II. 4, who saw and heard well, she had nine children, with no known defects of sight or hearing, though III. 27, who married his first cousin, was father of the sibship IV. 25—40 and III. 30, who married her first cousin, was mother of the other defective sibship IV. 14—23; by her second husband, II. 18, had two sons, of whom one was normal and had two normal children, the other, III. 44, was "silly." I. 1—4 were not known to have any defect of sight or hearing.

IV. 14 was reported to be "soft"; IV. 15—18 were all deaf-mutes and had defective vision, they were abroad; IV. 15, a farmer; IV. 16, died aged 15; IV. 17, died aged 5; IV. 18 was an inmate of an asylum abroad, the medical superintendent reported that she was a deaf-mute, and the sight almost gone, "she no doubt has retinitis pigmentosa." IV. 19—24 and their children had good sight and hearing. The father of this sibship married his first cousin, they both had good sight and hearing, as also had the paternal grandparents II. 5 and 6. Consanguinity. Bibl. No. 301.

Fig. 140. *Usher's Case* 5. Two cases of retinitis pigmentosa in a sibship of seven. III. 1, female, aged 18 (1911), had typical retinitis pigmentosa in each eye; Wassermann test negative; hearing excellent; never had any serious illness; night-blindness was noticed as soon as she could move about; refraction, slight hm., with correction R. V. = $\frac{6}{18}$, L. V. = $\frac{6}{18}$; small posterior cataracts were present; discs were pale and waxy, retinal arteries very narrow, choroidal vessels much exposed; much moss-like retinal pigmentation extended from periphery towards macula and disc; fields of vision much contracted. Her affected sister, III. 3, aged 14 (1911), was first noticed to have defective vision after an attack of bronchitis and inflammation of the lungs at the age of 3; she had marked night-blindness; retinal arteries very narrow; choroidal vessels much exposed; in 1906 retinal pigmentation was present in the left periphery only, in 1911 there was a considerable amount present in the right eye also, though less than in the left eye at the same date; fields of vision were much contracted, the left more than the right; refraction my. 1·5 D. in oblique meridian 4 D. in opposite meridian for each eye, corrected V. for each eye = $\frac{6}{36}$. Of the siblings of III. 1 and 3 two brothers were examined and seen to have normal fundi, two brothers died in infancy, and one brother, III. 7, was seen, aged 1 day, when fundus examination was unsatisfactory.

The parents, grandparents, great-grandparents, and five great-great-grandparents were believed to have normal vision, the fundus was seen to be normal in the parents and maternal grandparents. Nine paternal aunts and uncles had normal vision, and twelve maternal aunts and uncles were free from defect. Two paternal first cousins and three maternal first cousins suffered from some defect in hearing. Further information can be obtained from the greatly extended pedigree of the original account. No consanguinity. Bibl. No. 301.

Fig. 141. *Usher's Case* 28. One, possibly two, cases of retinitis pigmentosa in a sibship of six. III. 2, a male, basket-maker, aged 52 (1897), had gradual failure of vision since the age of 24; in each eye there was extensive retinal pigmentation and choroidal vessels much exposed; posterior lens opacities and vitreous opacities were present in the left eye; R. V. = L. V. = perception of light; refraction was myopic. Patient had been subject to headaches and vomiting since the age of 24, he had lateral nystagmus, and venereal trouble. His sister, III. 4, was reported to have the "same sight" as his own; two sisters and two brothers had normal vision. Parents and grandparents had normal vision. No consanguinity. Bibl. No. 301.

Fig. 142. *Usher's Case* 32. A single case of retinitis pigmentosa in an only child born before the

marriage of his parents. III. 1, aged 24 (1911), a healthy farm labourer, with no history of illness except measles and whooping cough, had noticed that he was night-blind for fifteen years, he was also deaf, but not completely so. He was seen first in 1901, when *retinitis pigmentosa sine pigmento* was diagnosed, night-blindness was then demonstrated, both fields of vision were slightly contracted, and the fundus was normal, excepting a possibly too uniform colour of disc; refraction in both was myopic, 2 D. in oblique meridian, 2·5 D. in opposite meridian, corrected vision = $\frac{6}{12}$ in both. Ten years later both fundi presented the usual appearance of well-marked retinitis pigmentosa, night-blindness was troublesome, but he could read almost the smallest print in day-time. His parents were robust and had normal fundi, each had low hypermetropia. Twelve aunts and uncles, the grandparents and great-grandparents, sixty first cousins, and many more distant relatives shown in the original pedigree had normal vision. Four maternal second cousins had myopia, one paternal second cousin was mentally defective, and died aged 20. One maternal aunt, II. 9, had a normal right fundus, near the periphery of left fundus on temporal side was an area three times the size of O. D. with well-defined margin, roughly circular, in which choroidal vessels were well seen, the rest of the fundus was dark, and choroidal vessels were hardly visible. No consanguinity. Bibl. No. 301.

PLATE XII. Fig. 143. *Usher's Case* 16. A single case of retinitis pigmentosa in a sibship of six. III. 10, a farmer, aged 54 (1912), had never seen well in the dark, had "inflammation of lungs" when a boy, some bleeding of nose when young but not severe, was not subject to cold hands or feet, radial arteries normal; refraction hm. 1 D. in both eyes; R. V. with correction = $\frac{6}{36}$, L. V. with correction = $\frac{6}{60}$; light sense much diminished; both fields nearly full with symmetrical absolute ring scotoma; O. D.'s too pale; retinal arteries much narrowed; choroidal vessels exposed, though not at the periphery; retinal pigmentation fairly typical but limited to inner part of each fundus; no atrophic choroidal patches. Wassermann test negative. Parents and grandparents had good vision.

The patient's siblings were all abroad, and saw well; his seven children were all examined by the author, and had normal fundi.

Two maternal first cousins of the patient had goitre, III. 31 and 36, the former was seen, and had no exophthalmos, tremors, or rapid pulse; she had thirteen children, many of whom were examined and had normal fundi, one of them, IV. 27, was subject to epileptic fits.

Four second cousins, III. 37, 38, 49, 50, were mentally defective, also two first cousins, once removed, II. 15 and 17. Information concerning this branch of the family was given by a medical man, III. 45, who was subject to cold hands and feet and signs of early arterial degeneration; one of his sisters, III. 43, and her mother, II. 18, had cataract; one of his daughters, IV. 39, also was subject to cold hands and feet. All other members of this extensive pedigree were reported to be normal. No consanguinity. Bibl. No. 301.

Fig. 144. *Usher's Case* 36. A single case of retinitis pigmentosa in a sibship of twelve and a doubtful case in a grandchild. II. 21, female, aged 54 (1896), the youngest in a large family, had never had good sight, it had been getting worse for some years, and she was bothered by bright light; at the age of 8 she had been badly fed and was taken to an orphanage; she was found to have extensive peripheral retinal pigmentation, retinal vessels narrow, discs pale, opacities at posterior part of lens, vitreous opacity; R. V. = L. V. = $\frac{6}{60}$; fields of vision contracted to 12°, 10° at some parts. At the age of 70 (1912) she had complete cataract in both eyes with no perception of light; she was healthy and active. Her parents, I. 3 and 4, were believed to have died comparatively young. No visual defect was known in her uncle, I. 2, or his descendants, but one of his seven children and one of his grandchildren had hare-lip. Of the siblings of II. 21 four died young, II. 16 was stillborn, II. 18 had delusions and was in a lunatic asylum, his fundi were normal; II. 12, with normal vision, married a woman, II. 13, who was normal herself, but had four deaf-mute cousins; one of their eight children, III. 15, had ten children, of whom three were deaf-mutes and two twins died in infancy; six of these children were examined, and found to have normal fundi. II. 21 had three miscarriages and six children, of whom III. 36 died aged 1 day, and III. 48, aged 18 (1896), had myopia of 8 D. in both eyes, her fundi were normal except for myopic crescents; other members of the sibship and their children were free from visual defect with one exception, a daughter of III. 44. She, IV. 40, a bright girl, aged 12, made no complaint of vision; R. and L. fundi showed a few particles of pigment at periphery of retina at one point, questionable whether retinal arteries were narrowed and O. D. too pale. A few months later (1912) R. V. = $\frac{6}{24}$, with + 1 D. cyl. = $\frac{6}{9}$ partly, L. V. = $\frac{6}{18}$, with + 1 D. cyl. = $\frac{6}{12}$ partly, she had no demonstrable night-blindness, fields of vision were definitely contracted except down and in; no ring scotoma; discs just appreciably too pale, retinal arteries narrowed to a small extent, choroidal vessels exposed towards the periphery where fundus had a mottled appearance, and there was here and there a small deposit of pigment in the retina. No evidence of syphilis in the parents or any of their children.

III. 7, whose wife was in a lunatic asylum, believed that his son, IV. 4, was mentally affected, for he was morose, and had sometimes assaulted him.

No other defects were known in this pedigree. No consanguinity. Bibl. No. 301.

Fig. 145. *Usher's Case* 26. A single case of retinitis pigmentosa in a sibship of eleven. III. 16, male,

aged 14 (1911), had had gradually failing vision for four or five years, he was unable to see at dusk; had always been very healthy; four years ago he lost about a teacupful of blood after cutting his right forefinger with an axe, the wound healed readily, but he said that after this his sight began to fail; he was fairly intelligent though somewhat slow mentally, memory good; hair very dark and stubbly, some dark hair on upper lip, forehead narrow, no deformities or bony thickenings, high palate, teeth good but irregular, no enlarged glands in neck, axillae or groins; pulse 75, regular, systolic pressure 120 mm. Hg.; hearing, smell, and speech normal; Wassermann test positive, and when repeated was again positive. His light sense was markedly defective, read $\frac{6}{60}$ in a light which gave normal eyes $\frac{6}{6}$ partly; refraction low hypermetropia, with correction R. V. = L. V. = $\frac{6}{12}$; media clear, retinal arteries much narrowed, choroidal vessels much exposed, no white atrophic spots; discs pale, with well defined edge; retinal pigmentation was present only at nasal part of R. fundus, and at nasal part and outer periphery in L. fundus; in these parts pigment was very scanty, had a moss-like arrangement, and was not very dark, in addition there was in the left eye a not very dark pepper-like mottling in some places behind the retinal vessels; the fields of vision were contracted, especially the upper halves. This boy had probably been vaccinated from arm to arm, but his mother reports that the pustule healed without trouble, and was followed by no illness.

Of the siblings of III. 16, one, III. 15, died aged 19, of pneumonia, he was reported to have had good vision and no night-blindness; III. 17—25, all had good vision and normal fundi, III. 19 had low myopia, the others low hypermetropia.

The mother, II. 18, had had no miscarriages or stillborn babies, she had good vision and normal fundi, and there was no known visual defect in her siblings or their children; one of her siblings, II. 26, was in a lunatic asylum; her parents and grandparents were reported to have had normal vision, one of her grandparents died of phthisis.

The father of III. 16 had normal fundi, he was in a lunatic asylum at the age of 18 for depression, there was no visual defect in his siblings or their children, but II. 4 died of phthisis, aged 23, and her two illegitimate children both died young, II. 6 was weak-minded and very quiet, II. 8 had a leg amputated at the knee for white swelling, II. 12, himself normal, had five normal children, and one, III. 10, who died aged 11 years, mentally weak, with large head and small body. II. 16 was in a lunatic asylum, and all his six children died young. The parents, grandparents, and great-grandparents of II. 11 were believed to have had normal vision, but his father, I. 1, had his leg amputated above the knee for white swelling. For further information concerning other normal members of the family see the author's original history and his considerably enlarged pedigree. No consanguinity. Bibl. No. 301.

Fig. 146. *Usher's Case* 20. A single case of retinitis pigmentosa associated with lamellar cataracts in a boy, III. 13, aged 17 (1908). He was well nourished, never had fits, was fidgety, teeth and palate normal, had mumps and measles when at school; at the age of 4 years he fell against a broken pail and cut bridge of nose, he was said to have lost much blood, but the evidence was not convincing; defective vision was noticed at the age of six or seven years, and had been getting worse. Typical symmetrical lamellar cataracts were removed by curette extraction in 1908 and 1909; after operation in each the course was uneventful; retinitis pigmentosa was first detected after removal of lenses. In each eye there was marked retinal pigmentation, with moss-like character, all over periphery of fundus; retinal arteries not markedly contracted; O. D. a good colour; night-blindness; fields of vision markedly contracted; refraction before operation R. my. 2·5 D., V. with correction = $\frac{6}{6}$, L. emm. V. = $\frac{6}{6}$; after operation R. hm. 11 D., V. with correction = $\frac{6}{36}$, L. hm. 10 D., V. with correction = $\frac{6}{6}$. In 1912 central vision and refraction were unaltered, in dim light allowing a normal eye to read $\frac{6}{12}$, he could only read $\frac{4}{6}$; right field of vision was reduced to 10°, left field was rather less; retinal pigment had increased. Wassermann test negative.

II. 6, aged 54, mother of III. 13, had media clear and fundus normal in each eye; one of her two brothers, II. 7, had R. my. approximately 5 D., L. traumatic cataract; one of her five sisters held things close to her, but was not night-blind. The maternal grandparents, I. 3 and 4, had good vision, as also had the parents of I. 4 (not given in pedigree). II. 5, aged 64, father of III. 13, had media clear and fundi normal; one of his five brothers, II. 3, had a R. senile cataract, his other four brothers and four sisters, with their descendants, had normal vision; the paternal grandparents had normal vision.

Of the siblings of III. 13, III. 17 was stillborn; III. 18 died, aged 2 months, and the living eleven had normal vision. Twelve nieces and nephews of the patient also had good vision.

The original pedigree gives information of 51 first cousins and other more distant relatives. The author examined 37 individuals. No consanguinity. Bibl. No. 301.

PLATE XIII. Fig. 147. *Usher's Case* 33. A single case of retinitis pigmentosa in a sibship of twelve, with a doubtful case in the next generation, in which changes were limited to the macular area, in a large pedigree otherwise remarkably free from defect. IV. 29, female, aged 39 (1908), had had difficulty in seeing at a distance for two years, and slight frontal headaches; the retinal arteries were narrowed, discs a little pale; well marked retinal pigmentation was present at inner part of fundus between the periphery and the disc; media clear; fields of vision full; absolute symmetrical ring scotoma; refraction, R. hm. 0·5 D.

in oblique meridian, my. 1·5 D. in opposite meridian, corrected V. = $\frac{6}{9}$, L. emm. in oblique meridian, my. 2 D. in opposite meridian, corrected V. = $\frac{6}{9}$; no complaint of night-blindness. The patient was liable to indigestion, and had a history of typhus fever at the age of 12, also of inflammation of the bladder and congestion of kidneys; urine was free from albumen and sugar. She had three unaffected daughters, the eldest of whom was aged 19. Five of her siblings died in infancy, IV. 25 died aged 37, of "apoplexy," IV. 26 died aged 21, of typhus, IV. 28 died aged 15, of "abscess," IV. 35 was at sea, IV. 36 was a nurse.

III. 11, father to IV. 29, had normal fundi; one of his four siblings, III. 16, had senile cataract; his mother, II. 10, was blind for six years before her death at the age of 66; one of his first cousins once removed, IV. 1, male, had a large patch of choroido-retinitis at periphery of nasal half of fundus with dense black pigment, some in front of retinal vessels, and almost complete choroidal atrophy, discs were normal and retinal arteries of normal size. All other ancestry or descendants of III. 11 were believed to have normal vision with the exception of his great niece, V. 12, aged 31 (1908), who had had defective vision as long as she could remember; discs were a little pale, retinal vessels perhaps a little narrowed; there was retinal pigmentation limited to the macular region and in branched forms coarser than is usual in retinitis pigmentosa; choroidal vessels seen indistinctly in pigmented area; light sense was markedly defective; fields of vision full, paracentral absolute scotoma below fixation point; refraction my. R. and L. 1 D., V. = finger counting at 3 feet in each; Wassermann test positive; in 1908 was in hospital with pelvic cellulitis, "no history of syphilis"; her first child died aged 4 months, the next three children had normal fundi, VI. 5 represents two miscarriages. The only sibling of V. 12 had normal fundi, her mother, IV. 13, died, aged 27, of "decline," her father, IV. 12, died of kidney disease.

III. 35, the mother of IV. 29, had good vision, she was the daughter of first cousins; there was no known visual defect in her relatives. Further information of normal members may be obtained from the author's account of the family. Consanguinity. Bibl. No. 301.

Fig. 148. *Usher's Case* 11. Two cases of retinitis pigmentosa associated with deafness, and two cases of congenital nystagmus in a sibship of nine. III. 12, an unmarried female, aged 44 (1906), had had gradual failure of vision since night-blindness was first noticed at the age of 20 or later; she had no defect at school age when she had sometimes to walk home in the dark along a country road; her eyes were painful and watered; she had no history of illness or severe bleeding, but had a fright at the age of 20; she was very deaf. R. V. = $\frac{6}{24}$, L. V. = $\frac{6}{36}$; posterior cortical lens opacities were present; discs were pale, retinal vessels markedly contracted, choroidal vessels much exposed; there was much retinal pigmentation at the periphery of each fundus; fields of vision contracted to from 10° to 20°. Seen six years later the condition of fundus was unchanged; Wassermann test negative. Her brother, III. 8, an unmarried farmer, aged 57 (1912), was very deaf, and had had chronic blepharitis since measles; at the age of 16 he had a discharge from the clavicle, and fragments of bone came away; no bleedings; he had marked night-blindness which had been noticed at an age much earlier than in his sister's case; he reported that he heard and saw well before he had measles. Refraction was myopic, R. V. = L. V. = 1 J.; nystagmus was present; posterior cortical lens opacities; discs were pale, and retinal arteries narrow; much retinal pigmentation was present at the periphery of the retina. III. 11, a twin, aged 53 (1912), was not night-blind, could read ordinary print easily, and had normal fundi, but he had a constant lateral nystagmus in both eyes, which had been "present from birth"; his irides were green, yellow in parts, and his hair was yellow. His twin brother, III. 10, died aged 14 months. III. 5, with good vision and no night-blindness, had constant nystagmus present since birth. Two sisters, III. 7 and III. 13, had normal fundi, no deafness and no nystagmus. III. 3 died in infancy; III. 9 died unmarried. Two of this sibship had children, all of whom saw well. An illegitimate half-brother, III. 2, was normal, his nine children and two grandchildren saw well.

Both parents, II. 8 and 9, had good vision; the father's siblings nearly all lived to be over 70; a sister, II. 3, had cataract, the others with their twenty children and about twenty grandchildren had no known defects of vision, but two of the children, nephews to II. 8, died of phthisis. The mother's six siblings had normal vision; one of them had four children with normal vision, of whom one died in a lunatic asylum.

The maternal grandparents had normal vision, and were unrelated, the paternal grandparents, I. 1 and 2, had good vision, and were first cousins. A brother of I. 1 had two children, whose vision became defective, one of them had an operation on his eyes, and the other became blind late in life; a child of the first of these "screws his eyes up." A paternal second cousin of the sibship III. 3—13 was in a lunatic asylum for a few months at the age of 22.

Three of the great-grandparents were reported to have normal vision. For further information about normal members see the author's original history and enlarged pedigree. Consanguinity. Bibl. No. 301.

Fig. 149. *Usher's Case* 4. Four cases of retinitis pigmentosa in one sibship, the offspring of first cousins. III. 5, aged 57 (1912), saw sufficiently well for schooling, but since then his vision had gradually failed until he became quite blind, he had been night-blind; R. V. = L. V. = no perception of light; retinal pigmentation could be seen in the right eye, the left fundus was not visible owing to complete cataract;

he had congenital coloboma of iris in the left eye only; Wassermann test negative; he and all his siblings, except III. 7, had scarlet fever in childhood. III. 6, aged 41 (1898), had never been strong, she was night-blind, and her vision gradually failed, she saw well enough for schooling, but was blind at the time of examination; slow vertical nystagmus, myopia, R. V. = L. V. = no perception of light; retinal vessels, especially the arteries, were extremely narrow; there was much pigmentation at the periphery of retina of a moss-like pattern; the discs were of a pale yellow-red colour, with the edge not sharply defined. III. 7, aged 37 (1897), had "gastric fever" at the age of 13, but her vision began to fail before then, and she was almost blind at the time of examination; R. V. = L. V. = perception of light; she had slow lateral nystagmus, posterior cortical lens opacities; choroidal vessels much exposed, and retinal vessels very narrow; very extensive retinal pigmentation, reaching nearly to the discs. Seen again in 1912, she had no perception of light, and much lens opacity. III. 8 had R. V. = L. V. = no perception of light when seen in 1912, her vision had gradually failed; she had much lens opacity and details of discs, and retinal vessels could not be seen, but typical retinal pigmentation was visible; Wassermann test negative. Of the unaffected members of the sibship, III. 2, a healthy farmer, with normal fundi, had nine normal children, the first of whom was illegitimate, and five normal grandchildren; one of his nine children, however, IV. 7, aged 18, said on being questioned that for two years she had found some difficulty in seeing at dusk, she had never told this to her family, and they had never noticed any difficulty; she was peculiar, and possibly neurotic; the author examined her on two occasions, and found no diminution of light sense, no contraction of fields (perimeter not available) or ring scotoma, discs and retinal vessels were normal, but there was a yellowish dappled appearance at parts of the periphery of the retina, and at least one piece of retinal pigment visible. III. 4, died, aged 8 years, she saw and heard well. III. 9, also her children and grandchildren, had normal vision. III. 11 represents four miscarriages, the position of which in the sibship was unknown.

The parents of this sibship lived to old age and had good vision, as also had their parents and grandparents.

The mother's four siblings, with the descendants of the only one of them who had children, had normal vision; one of her sisters, II. 11, had normal illegitimate twins by her first cousin, II. 6, the brother of II. 3.

The father's seven siblings, with their descendants, had normal vision, but one of his nephews had a violent temper which was attributed to insanity, and later he became alcoholic.

A great-uncle, I. 5, was a "character," went about in old-fashioned costume, and was regarded as eccentric. The original pedigree shows a large number of his descendants, none of whom had defective vision, but one granddaughter had exophthalmic goitre, and she had a hysterical daughter, one great-grandson was mentally defective, and one was epileptic.

The original pedigree is greatly extended, and is described in great detail by the author; the only further cases of eye defect in the history were in a branch of distant connection where there were fundus changes not associated with night-blindness, and believed by the author to be due to high myopia. Consanguinity. Bibl. No. 301.

Fig. 150. *Usher's Case* 13. Four cases of retinitis pigmentosa, associated with deaf-mutism, in a sibship of seven. III. 2, aged about 17 (1911), was a deaf-mute with marked night-blindness, his defect of vision was not noticed until the age of 7 or 8 years; R. V. = L. V. = 1 J. in a good light; the discs were pale, the retinal vessels contracted, and there was a typical appearance of retinitis pigmentosa in each fundus; fields of vision were contracted. III. 4, male, aged about 15 (1911), was a deaf-mute, with night-blindness, which was first noticed at the age of 7 years; fundus changes were similar to those of III. 2. III. 6, aged 9 (1911), a mentally weak deaf-mute, was considered to be night-blind by those in charge at an institution for the deaf and dumb because in a dim light she knocked against objects which other children would avoid, but her mental condition was such that it was not possible to demonstrate that she was night-blind; the retinal vessels were narrow, the discs pale, choroidal vessels exposed; there was some yellowish mottling towards the periphery of the fundus, but no moss-like pigmentation; refraction hm. 2 D. in vertical meridian, 6 D. in horizontal meridian for each eye; Wassermann test negative. III. 7, aged 7 (1911), was a deaf-mute, and was believed to have not marked night-blindness; there was much yellowish mottling towards the periphery of the fundus behind the retinal vessels, and much pepper-like pigmentation of the fundus with two or three moss-like deposits at the periphery in front of the retinal vessels; refraction hm. R. 2 D. in vertical, 3·5 D. in horizontal meridian, L. 2 D. in vertical 5 D., in horizontal meridian; Wassermann test negative. None of these four children had a history of illness or bleeding; of their normal siblings III. 1, aged 18, had no deafness or myopia, her right fundus showed a dense white band extending from the inner edge of the disc to beyond its centre, otherwise both fundi were normal. III. 3 had a normal fundus. III. 5 died in infancy.

The mother of this sibship was always delicate, she died aged 44, of phthisis; she was third born in a sibship of thirteen, two of whom died in infancy, also one of her sisters and one brother died of phthisis; there were no defects of vision in her parents, I. 3 and 4, her grandparents, or their descendants other than those recorded above. The father, II. 3, was an intelligent robust farmer, with a normal fundus, his

three siblings, his parents and his grandparents with their descendants all had normal vision except the sibship III. 1—7.

Thirty-one first cousins and other more distant relations to the sibship III. 1—7 are shown on the original pedigree with no defects of vision. No consanguinity. Bibl. No. 301.

Fig. 151. *Usher's Case* 15. A single case of retinitis pigmentosa in a sibship of four. III. 2, male, aged 14 (1896), a farm servant, did not see well at night; at the age of $2\frac{1}{2}$ years he had been ill for six weeks with "inflammation of brain," and his father believed that his sight had been defective since; his nose bled daily when at school; he did not suffer from cold hands and feet; he was intelligent and healthy, with no evidence of syphilis. R. and L. well-marked retinal pigmentation with moss-like character, an unpigmented part of retina was present peripherally to the pigmented area at temporal and nasal sides, but not above or below; choroidal vessels exposed. O. D., of uniform reddish colour, with blurred edges; retinal vessels narrowed; posterior cortical lens opacities; refraction hm. R. 2 D. in oblique meridian, 4·5 D. in opposite meridian, corrected V. $=\frac{6}{12}$, L. 1·5 D. in horizontal meridian, emm. in vertical meridian, corrected V. $=\frac{6}{9}$; fields of vision were contracted. In 1912, R. V. $=\frac{6}{24}$, L. V. $=\frac{6}{18}$, not improved by glasses; O. D. waxy, moss-like retinal pigmentation not extending to central region; retinal vessels very narrow; no white patches in choroid; Wassermann negative. His father, II. 6, was illegitimate, and had normal fundi; the paternal grandfather went abroad and was not known, but the paternal grandmother and the six half siblings of the father had normal vision. His mother, II. 10, and her parents had normal vision; of her siblings, II. 11 died young of diphtheria, five had good vision, and II. 8, female aged 61, had difficulty in seeing at dusk, but fields of vision were full, and she had no ring scotoma; she had my. 0·75 D. R. and L. V. R. = V. L. $=\frac{6}{12}$ with correction, in dim light, giving $\frac{6}{18}$ to normal eyes, she did not read $\frac{6}{60}$; R. and L. O. D., a good colour, retinal arteries not contracted; at macula there was an area 2 O. D. in size, mottled with small yellowish spots which were interspersed and covered by small black pigment spots; in R. white crescent of choroidal atrophy next outer and lower edge of O. D., and at lower part of fundus two large oval yellowish spots with well-defined and pigmented margins (probably syphilitic); she had had two miscarriages, two children who died in infancy and two who lived; Wassermann positive.

The original more extensive pedigree shows six great-grandparents of III. 2, with normal vision, also thirteen maternal cousins and many more distant relations. The mother, II. 10, had an uncle and two first cousins who showed some degree of mental defect.

Of the siblings of III. 2, a sister, III. 1, had high hm. astigmatism with normal fundi, two brothers had normal vision. No consanguinity. Bibl. No. 301.

Fig. 152. *Usher's Case* 12. A single case of atypical retinitis pigmentosa in a sibship of five. III. 2, aged 6 years (1911), had uniform pallor of discs, physiological cup not filled in, retinal vessels very narrow and all over the periphery of the fundus were numerous small black pigment specks and much delicate branched pigment in the retina; there was little, if any, coarse moss-like pigment, and no circular patches of choroidal atrophy; in some large areas at the periphery the choroidal vessels showed more than elsewhere; no lens opacity; refraction hm., R. 3·5 D. in oblique, 6·5 D. in opposite meridian, L. 3 D. in oblique, 6·5 D. in opposite meridian; when she dropped small things her mother said she did not see them, yet in a badly lit room she seemed to have little difficulty in finding things on the floor. At the age of 17 months she did not see well, and there was constant lateral nystagmus with no gross fundus lesion, a year or so later ill-defined changes were present at the macula with pepper-like pigmentation and choroid paler at one spot; Wassermann test negative. Her four siblings had normal fundi, though the examination was unsatisfactory in the case of the youngest.

The mother, II. 8, had myopic astigmatism, no retinitis pigmentosa; her siblings and their seventeen children had no defects of vision; her parents, also their siblings, her grandparents and one great-grandparent had normal vision.

The father, II. 2, had a normal fundus, he had no siblings, his parents and grandparents had good vision; his half-aunt, I. 2, became blind after the age of 50; the cause was unknown, but the history was not suggestive of retinitis pigmentosa; she had one son, II. 1, who at the age of 45 had absolute glaucoma in each eye.

For further information concerning more distant relatives see the author's account of the case and his extended pedigree. No consanguinity. Bibl. No. 301.

PLATE XIV. Fig. 153. *Usher's Case* 24. An isolated case of retinitis pigmentosa in a female who had a positive Wassermann reaction; IV. 5, aged 24 (1898), had suffered from night-blindness and difficulty in reading and sewing for 12 years. Examination showed R. and L. marked retinal pigmentation at periphery of fundus except at outer part, no white patches; the discs were a dirty reddish colour, paler than normal; retinal vessels, especially arteries, very narrow; at nasal part of left fundus, between the disc and the pigmented area, was a speckled, pepper-like distribution of pigment; refraction my. R. 2 D., V. with correction $=\frac{6}{12}$, L. 1·75 D., V. with correction $=\frac{6}{12}$; fields of vision peripherally contracted, left to within 20°, right at temporal part to 30°, at other parts to within 20°. Seen again in 1907 with R. and L. small posterior cortical cataracts; discs waxy; retinal pigment approaching central region of fundus, but not

involving macula, R. V. with correction = $\frac{6}{12}$, L. V. with correction = $\frac{6}{12}$; R. field more contracted, L. field as before; she was mentally slow, and had no issue from her three marriages; she was delicate and an only child; when six weeks old her mother had "spotted (black) typhus fever." Her mother, III. 3, aged 65 (1911), was quite blind from primary glaucoma, she was an only child, and married her cousin, III. 6, the father of IV. 5; she had no children by her second husband, but had three illegitimate children by III. 2 and III. 4, all of whom had normal vision.

The father of IV. 5 was also the offspring of first cousins; his sister, III. 7, had retinal haemorrhages, but no retinitis pigmentosa, she also married her first cousin, and had five children with normal vision; another sister, III. 8, had a son with hydrocephalus and bilateral optic atrophy, and three children with normal vision; a brother, III. 10, had three children with normal vision. Other members of Gen. IV. had normal vision, but IV. 37 was in a lunatic asylum.

In Gen. V. one individual, V. 14, aged 4, daughter of one of the illegitimate children of III. 3, was an imbecile, did not speak, and had to be fed; she had nystagmus and gross choroido-retinitis in each eye. V. 18 had corneal opacities; V. 20 had a congenital crescent in left fundus, right eye myopic; V. 21 was mentally defective.

The author examined fifty-four members of this pedigree, and gives further information in his description of it. Consanguinity. Bibl. No. 301.

Fig. 154. *Usher's Case* 2. One case of retinitis pigmentosa in a sibship of three, the offspring of first cousins. III. 4, aged 37 (1910), was badly nourished and had never been strong, but there was no history of definite illness, and her face and teeth were not suggestive of inherited syphilis; she was very deaf, and though married, had no children; Wassermann test negative. Her vision was defective at the age of 16, and she had great difficulty in getting about in a dim light; in both eyes there was much retinal pigmentation; the discs were pale, retinal arteries narrow; posterior lens opacities were present; night-blindness was marked; fields of vision were contracted to about 10°; refraction R. simple myopic astigmatism of 3 D., corrected V. = $\frac{6}{24}$, L. myopia of 2 D. in horizontal, 4 D. in vertical meridian, corrected V. = $\frac{6}{18}$.

The mother of III. 4 died, aged 54, of cancer, she had eight siblings, of whom three died young; one, II. 6, had gross symmetrical choroido-retinitis and night-blindness, probably syphilitic, the remaining four, with their children and grandchildren, had good vision; the parents and grandparents were not known to have had any defect of vision.

The father of III. 4 and all his three siblings died of phthisis, neither they nor their parents were known to have had any defect of vision.

The two siblings of III. 4, and the five children of one of them, saw well.

The author's pedigree shows twenty-seven first cousins to III. 4, and other more distant relatives, who were believed to see well. Consanguinity. Bibl. No. 301.

Fig. 155. *Usher's Case* 40. An isolated case of retinitis pigmentosa in a male in a childship of seven. III. 13 was a gamekeeper, aged 43 (1894), his vision had been failing rapidly in both eyes for three months, he could see best in dim light, R. V. = $\frac{6}{18}$, L. V. = $\frac{6}{24}$, not improved by glasses; fields of vision were full with absolute ring scotoma complete in both though very narrow at upper nasal part in R.; optic discs waxy; retinal vessels diminished; moss arrangement of pigment in retina between disc and periphery, but there was no pigment immediately around the disc or at extreme periphery; patient unable to shoot ground game, but could shoot birds. Seventeen years later (1912) he was working in a mill as timekeeper, and could still read 1 J. with each eye readily; no history of syphilis; had "gastric fever" at age of 14; was badly shot in 1876, had 78 pellets in him; up to the age of 20 was subject to severe nose bleeding; did not bruise readily; no night-blindness; fields of vision taken with 10 mm. square of white paper on end of a stick had an absolute ring scotoma below and at nasal part, but not above or in temporal parts, where fields were contracted to perhaps 10° or 15°; retinal arteries were narrow; discs pale; choroidal vessels exposed; retinal pigment extended nearly to discs. The patient reported that his parents, grandparents, two brothers, four sisters, and his twelve children had all had good vision. The author examined the fundus of six children of the patient, and found all normal. The pedigree shows a large number of nieces and nephews, also aunts, uncles, and cousins apparently free from all eye trouble, and showing no other inheritable disease except in the case of two nephews, IV. 7 and 10, who died of phthisis. No consanguinity. Bibl. No. 301.

Fig. 156. *Usher's Case.* Six males affected with retinitis pigmentosa in four generations. I. 3 was invalided from the army as a young man for "moon-blindness," and was told it would get worse; he could see well in the day at this time, but not in the evening; he got steadily worse, was quite blind at the age of 50, and died aged 70. I. 1, 2 and 4 had good sight. II. 1 and 5 had good sight. Of their eight children III. 3 died in infancy; III. 4 died aged 14; III. 5, aged 40, had good sight, and his three children also had normal vision. III. 7, aged 38, had typical advanced retinitis pigmentosa, his four sons and his daughter, who had died recently, had normal vision. III. 9, aged 36, had typical advanced retinitis pigmentosa, his only son had normal vision. III. 11, aged 34, with typical retinitis pigmentosa, was married but had no children. III. 13 and 14 had normal vision, but the child of one of them, III. 14, seen by the author at a later date (Bibl. No. 301), then aged 8, had typical retinitis pigmentosa.

III. 17, first cousin to the previous three cases, aged 50, was nearly blind from retinitis pigmentosa; he was a drinker; by his first wife there were no children; by his second wife he had five or six children, of whom one or two had bad sight by day as well as by night. No consanguinity recorded. Bibl. No. 263, p. CLIII.

Fig. 157. *Usher's Case* 1. A single case of retinitis pigmentosa in a sibship of two. III. 3, aged 30 (1911), a widow, had never seen so well as others in a dim light; she was never strong, but had no history of illness or bleedings; her discs were pale and waxy, her retinal arteries narrow; there was moss-like retinal pigmentation visible chiefly at the (not extreme) periphery; choroidal vessels were conspicuous; posterior cortical opacities of the lenses; refraction was low hypermetropia, corrected V. $= \frac{6}{12}$ partly; she was night-blind; fields of vision much contracted; Wassermann test negative. She had been examined by the author thirteen years previously, the visual fields had contracted considerably in the interval, the defect in light sense was unchanged. IV. 3, the only child of III. 3, had a normal fundus. III. 2, the only sibling of III. 3, saw well, and her only child IV. 1 had a normal fundus.

II. 9, mother of III. 3, had a normal fundus; the father, II. 5, had good vision and no night-blindness. The grandparents and five great-grandparents, with all their descendants except III. 3, were free from any defect of vision so far as was known.

Two maternal first cousins to III. 3, and one paternal first cousin, died of phthisis; one maternal first cousin once removed "went wrong in his mind," and was in an asylum.

The original greatly extended pedigree shows twenty-seven first cousins and a large number of more distant relatives of the patient III. 3, all of whom were believed to be free from defect of sight or hearing or other inheritable defect, except the cases mentioned above. No consanguinity. Bibl. No. 301.

Fig. 158. *Usher's Case* 17. Two cases of retinitis pigmentosa in a sibship of nine. III. 1, male, unmarried, aged 24 (1911), the illegitimate son of II. 8 and 10 before their marriage, was a healthy-looking farm servant; night-blindness noticed when he left school, aged 14; had no illnesses, and had incomplete deafness. He was examined in 1902, and again in 1911, when the condition had progressed; at the latter date he had very extensive moss-like pigmentation at the periphery of the fundus: retinal arteries much narrowed; O. D. pale, with edge not well defined; posterior lens opacities; R. V. = L. V. $= \frac{6}{12}$; hm. 0·5 D. in each; in dim light that gave $\frac{6}{9}$ to a normal person he could only read $\frac{6}{60}$; fields of vision contracted to 18°, except at a point on horizontal line in outer part of fields where it reached 22°; no ring scotoma; hearing, right ear does not hear a watch on contact, left ear hears watch only on contact; smell normal; Wassermann test negative; no history of illness or bleedings.

III. 5, female, unmarried, aged 18 (1911), had always been deaf like her brother, she was night-blind, and had had no illnesses or bleedings; on examination some vitreous opacities were found; retinal vessels narrowed; discs showed no marked pallor, but edges were hazy; at periphery of fundus were yellow-white spots and some pepper-like dots; in R. only two spots of pigment were visible, one at outer, the other at inner periphery, in L. two similar black spots were down out at periphery; no white atrophic spots; choroidal vessels exposed; refraction R. my. 3·5 D. in oblique and emm. in opposite meridian V. with correction $= \frac{6}{12}$; L. my. 1 D. in oblique, 3·5 D. in opposite meridian, V. with correction $= \frac{6}{12}$; with correction in a dim light that gives a normal person $\frac{6}{12}$ she gets $\frac{6}{36}$; fields contracted most markedly above, in R. is an incomplete narrow ring scotoma; hearing as for III. 1; smell normal; Wassermann test negative. III. 3, 6, 8 and 9 had normal fundi; III. 2 and 4 had normal vision; III. 7 died aged 3, of "water in head."

The mother, II. 10, died of pneumonia, but had normal vision; her four siblings apparently also had normal vision.

The father, II. 8, had a normal fundus; his sister, II. 9, had "water in head," difficulty in walking, was deformed and probably silly; II. 7 died aged 2; II. 3 died aged 25 in a lunatic asylum, had fits; II. 1 died in infancy; II. 2 had a normal fundus; II. 4 and 6 had good sight. The paternal grandparents I. 1 and 2 were related, but not first cousins, they lived to old age and saw well; one sibling of I. 1 was deformed, and two siblings of I. 2 were probably myopic. The four parents of I. 1 and I. 2 were reported to have seen well. The maternal grandparents I. 3 and I. 4 saw well, and there was no reported defect in their siblings or in the parents of I. 4. For further information see the original greatly extended pedigree, which shows thirty-three first cousins to the sibship of III. 1 to 9, and a large number of more distant relatives, all believed to be free from hereditary defect. No consanguinity. Bibl. No. 301.

PLATE XV. Fig. 159. *Usher's Case* 27. Three cases of retinitis pigmentosa in a sibship of seven. III. 24, a farmer, aged 37 (1899), had scarlet fever in childhood, but no history of syphilis or other illness, and no severe bleedings; Wassermann test positive; the discs were pale, the retinal vessels much narrowed; retinal pigmentation was visible mostly at the periphery and in the form of fine granules; choroidal vessels much exposed; a few circular grey spots, one-sixth diameter of O. D., were seen in lower part of fundus, with choroidal vessels crossing them; refraction emm.; R. V. = L. V. $= \frac{6}{24}$; fields of vision contracted to 10°. Thirteen years later his vision was reduced to perception of light in each; posterior cortical lens opacities were present with moss-like retinal pigmentation except at the macula. He had records of hospital notes given him at the age of 27, when R. V. = L. V. $= \frac{6}{9}$, and no pigment was seen in either eye.

III. 16, a farmer aged 67 (1912), was mentally keen, but not robust in appearance; no history of illness, unless possibly scarlet fever, and no bleedings; he had posterior cortical cataracts; discs were waxy, retinal vessels very narrow, choroidal vessels much exposed; moss-like retinal pigmentation was visible except at the macula; R. V. = L. V. = no perception of light, he had been quite blind for 30 years; refraction low hypermetropia; he thought the onset of his visual defect was between the ages of 20 and 30. III. 14 was abroad, he was quite blind, and was believed to be affected in the same way as his brothers; his failure of vision was first noticed about the age of 30 and from that time gradually progressed.

The parents were first cousins, they and their parents had good vision.

Of the normal siblings of the affected brothers, III. 17 died of typhoid, she had three normal children; III. 19 died aged 23 of "gastric fever"; III. 20 died of "haemorrhage," her first six children died in infancy, and the remaining four reached adult life to die of typhoid; III. 22 died aged 23 of "brain fever."

All the affected members had children, six of whom were examined and showed no signs of retinitis pigmentosa, one daughter of III. 24 and one son of III. 16 were myopic.

A sister of the father II. 8 married her first cousin, a brother of the mother II. 9, and had three children, III. 9—11, of whom III. 9 was mental and shy and refused examination, all had good vision and hearing.

IV. 31, first cousin once removed to the affected sibship, had always been bed-ridden, and had defective hearing; there was no information concerning his vision. Nineteen first cousins and many more distant relatives seen in the pedigree were free from any known defect. Consanguinity. Bibl. No. 301.

Fig. 160. *Usher's Case* 31. A single case of retinitis pigmentosa in a sibship of thirteen. III. 8, aged 28 (1911), complained of defective vision especially in a dim light, her sight had been failing for 13 years, she had frontal headaches and felt tired; she had an abscess in her leg two years before, and diphtheria at the age of 26, had frequent anaemia since the age of 18; R. V. = finger counting at 10 inches, L. V. = hand movements at 2 metres; night-blindness not very marked; discs were a homogeneous dirty red colour, retinal vessels very narrow, choroidal vessels much exposed; retinal pigmentation was only visible at the extreme periphery, it was moss-like and in some places pepper-like; fields of vision were contracted to within 10°. III. 14 died in infancy, the other siblings of III. 8 and the twelve children of two of them were healthy and saw well.

The father, II. 3, died aged 67, he had a weak heart; he, his parents, one of his grandparents, and their descendants were free from any defect of vision. The mother, II. 8, had normal fundi and was healthy; her parents, two grandparents, and their descendants, were free from visual defect, but one of her nine siblings, a sister, II. 9, was a deaf-mute with normal fundi, and one of her nieces (see the original pedigree) was mentally defective and deformed.

Fifty-three normal first cousins and many more distant relatives are shown in the author's original pedigree. No consanguinity. Bibl. No. 301.

Fig. 161. *Usher's Case* 8. Three cases of retinitis pigmentosa in a sibship of eleven. III. 8, aged 19 (1902), complained of failing vision and of night-blindness which had been first noticed by his mother when he was aged 10; he had occasional aching in the temporal regions; refraction myopic, R. 2 D., corrected V. = $\frac{6}{18}$, L. 1·5 D., corrected V. = $\frac{6}{12}$; fields of vision were contracted to 12°; pupils were small, equal in size, and reacted sluggishly to light; the discs were a fairly good colour with well-defined edge, the retinal arteries were narrowed, and typical retinal pigmentation was present; a few vitreous opacities were present; his hearing was defective, the right ear heard nothing, the left ear heard a watch on contact only; there was some defect in his speech also, but in other respects he appeared to be normal, and was of a robust physique; Wassermann test negative, and no history of illness. Seen again seven years later, his vision was worse and the condition had progressed. III. 3, a stonecutter, aged 25 (1902), was strong and intelligent and had no history of illness, but he was rather deaf, had some difficulty with his speech, and was night-blind; he was in Canada and reported that his vision was getting worse; notes of his fundus and fields could not be found. He was married, but had no children. III. 10, aged 24 (1910), was somewhat deaf and night-blind, she also had some difficulty in speaking; her retinal arteries were narrowed, her discs were pale, but not markedly so; fields of vision were contracted; vitreous opacities were present in the right eye; retinal pigmentation was typical; she had an illegitimate boy, IV. 9, who apparently had normal vision as an infant. Of the normal siblings, III. 2 was an illegitimate daughter of II. 11 by a different father; she had four sons with normal fundi. III. 4, III. 6, III. 9, and III. 12 to 15 had normal fundi, and no night-blindness. III. 16 died aged 12 months of whooping cough and teething. The three children of III. 4, and three of the four children of III. 6, had normal fundi; IV. 5 died aged 14 months.

The mother, II. 11, aged 56 (1910), had no night-blindness or contraction of fields; her vision was perfect, but at the lower periphery of the left fundus there were two or three patches of superficial choroidal atrophy with well-defined edges; there was no known defect of vision in her eight siblings, her parents or grandparents, or their descendants. The father, II. 5, aged 53 (1910), had normal fundi, several of his eleven siblings died young, the seven survivors had normal fundi or good vision; his father, I. 1, died

aged 75 quite blind, his sight failed gradually in adult life, there was no history of night-blindness, but he had had two operations for cataract. The parents of I. 1 had normal vision; his maternal grandmother died aged 102 when she had been blind for two years. I. 6 was at one time in a lunatic asylum; I. 7 was in a lunatic asylum for a number of years.

A sister of II. 5 married a brother of II. 11, and had two daughters with normal fundi.

The author's greatly enlarged pedigree shows sixty-three first cousins to the affected sibship all believed to have normal vision, as well as a considerable number of more distant relatives. No consanguinity. Bibl. No. 301.

Fig. 162. *Usher's Case* 23. Three cases of retinitis pigmentosa and one case of vacillating ring scotomata in a sibship of four. IV. 1, aged 47 (1910), was deaf, had very defective vision, and was night-blind; in 1913 there was some lens opacity, the discs were pale and waxy, the retinal vessels thread-like, the choroidal vessels much exposed, and much retinal pigmentation was visible towards the periphery; his refraction was myopic, 3 D. in each, corrected V. = $\frac{6}{24}$ in each; night-blindness was very marked; Wassermann test negative. IV. 3, aged 39 (1910), was deaf, and had marked night-blindness; he had posterior cortical cataracts, fields of vision were much contracted, and his fundus showed changes typical of retinitis pigmentosa. IV. 4, aged 34 (1910), was deaf and had defective vision, which was gradually getting worse; R. V. = L. V. = hand movements at 5 metres; pupils were equal, and reacted sluggishly to light; he had posterior cortical cataracts and retinal pigmentation, which was most marked midway between the optic disc and the periphery, some of the pigment was arranged in circles or round patches like choroidal pigmentation; retinal arteries were very narrow, and fields of vision were reduced to less than 5°. The defect of vision in each of the three brothers had been noticed as soon as they could walk. IV. 2, aged 45 (1910), reported that "nothing was thought about his sight," although his parents knew that it was not right; he was examined because his brothers had retinitis pigmentosa, and was found to have some night-blindness, some contraction of visual fields, some defect of vision, V. with correction for low hypermetropia was $\frac{6}{9}$ for each, and he had an absolute complete ring scotoma in the left field; the case was examined repeatedly at varying intervals, and the scotoma was sometimes present, sometimes absent in one or both eyes, it was sometimes complete and sometimes partial; the fundus was normal in all respects. The patient had Raynaud's disease, and was subject to migraine-like attacks, and the author was of the opinion that the source of the transient scotomata was probably vascular; he describes the case with its repeated examinations in considerable detail.

The parents of this sibship were first cousins once removed; the mother, III. 5, died aged 62; at the age of 35 she was in bed for two years with "paralysis of voice, one side of body paralysed, headaches and vomiting," vision became affected at that time and gradually got worse; quite blind in one eye at the time of death, according to the report of her relatives. There were no defects of vision known in the eleven siblings of III. 5 nor in their children, grandchildren, or great-grandchildren, except in the case of one of the five children of III. 8, who had low myopia, and one of the children of III. 7, who never saw well, but was not night-blind. The parents of III. 5 saw well. The father, III. 2, had normal fundi; his six siblings and their children, grandchildren, and great-grandchildren, had normal vision, though one sibling, III. 1, had lens opacities at the age of 73. The father and paternal grandparents of III. 2 saw well; his mother, II. 3, had cataract.

The author shows more than eighty-three first cousins of the affected sibship with no symptoms of retinitis pigmentosa, as well as many more distant relatives not included in our abridged pedigree. Consanguinity. Bibl. No. 301.

Fig. 163. *Usher's Case* 39. A single case of retinitis pigmentosa in a sibship of six. III. 6, aged 27 (1907), had always had defective vision, but it had been worse the last twelve months; she reported that she had been night-blind as long as she could remember, but her aunt said it had not been noticed until she was aged 14; she had a history of anaemia two years previously, and of typhoid fever at the age of 6; she had well-marked retinitis pigmentosa, her discs were pale, retinal vessels small, fields of vision contracted to 10°; she had posterior cortical cataract; refraction was myopic, R. 1·5 D., corrected V. = $\frac{6}{36}$, L. 2·5 D., corrected V. = $\frac{6}{18}$. The parents saw well and were unrelated; when the mother, II. 10, was pregnant with III. 6, her youngest child, III. 5, was ailing, became totally blind, and died aged 2, "the doctor stating that had she lived it would have been as an imbecile"; the distress of the mother was supposed to have caused the defective vision in III. 6. Of the mother's eleven siblings one, II. 9, died aged 70, very deaf, and nine died of phthisis; her mother, I. 8, also died of phthisis aged 47.

The father, II. 6, and his parents saw well, all his siblings saw well, but one of them, II. 1, died in a lunatic asylum.

Of the siblings of III. 6, III. 7 was "short-sighted"; III. 4, 9 and 11, with their children IV. 1 to 4, all had good vision. No consanguinity. Bibl. No. 301.

Fig. 164. *Usher's Case* 25. Two cases of retinitis pigmentosa in half-brothers, each of whom had a positive Wassermann. IV. 16, aged 24 (1901), had been night-blind since early childhood; his refraction was R. myopia 4 D., corrected V. = $\frac{6}{36}$, L. V. = finger counting at 1 metre; he had a left central corneal nebula and an anterior polar cataract; marked divergent strabismus; field of vision much contracted,

R. field to 10°; the discs were a pale yellowish colour with soft looking margins, retinal vessels much contracted; retinal pigmentation as delicate branched lines forming at places a network; vitreous opacities were present; he had convulsions in childhood, bronchitis at the age of 18 months, and had an irritable temper; Wassermann test positive. IV. 16 had had four children, of whom three had normal vision, one, V. 13, had high myopia at the age of 6 years, R. 10 D. in horizontal, 12 D. in vertical meridian, L. 8 D. in horizontal, 11 D. in vertical meridian, she had small myopic crescents. The three siblings of IV. 16 and their children, V. 12 to 20, saw well.

IV. 10, half-brother to IV. 16, aged 40 (1905), reported that he was "always short-sighted," and that his vision had gradually got worse; in 1905 he had perception of light, but in 1912 he had no perception of light in either eye; in 1905 he was seen to have typical retinitis pigmentosa and posterior cortical cataract; his left lens was opaque, and was dislocated into the anterior chamber; in 1912 there was diffuse total opacity of right lens; he was in good health and spirits, was an abstainer from alcohol and tobacco, and had no history of syphilis, but his Wassermann test was positive. His two siblings and the children of one of them saw well.

The mother of these two sibships, III. 5, had always been healthy, and had, at the age of 75, normal fundi. Her first husband, III. 1, died aged 60, from the result of a chill; he was reported to have held things near, but was not night-blind, and his sight did not get worse. Her second husband, III. 11, saw well.

No further defect of vision was known in the six grandparents, II. 1 to 6; in the great-grandparents, I. 1 and 2, or in any of their descendants, twenty-six of whom were examined by the author. No deafness and no insanity had occurred in any member of this pedigree. No consanguinity. Bibl. No. 301.

PLATE XVI. Fig. 165. *Usher's Case* 7. Four deaf-mutes, with retinitis pigmentosa, in a sibship of five; a paternal second cousin, IV. 20, was a deaf-mute; a paternal first cousin once removed, III. 13, was an imbecile; and one child of the normal sibling, V. 1, had a congenital digital deformity. IV. 11, aged 32 (1911), was a deaf-mute postman, with typical retinitis pigmentosa, his discs were pale, with several translucent, probably hyaline, bodies on them, the retinal arteries were markedly narrowed; retinal pigmentation was of the usual moss-like character and also pepper-like in some places; he had constant lateral nystagmus, and was night-blind; refraction hypermetropic; in 1900 R. V. = L. V. = $\frac{6}{36}$ partly, not improved by glasses, in 1911 R. V. = L. V. = $\frac{4}{60}$; fields much contracted; no history of illness; Wassermann test negative. IV. 10, aged 34 (1911), was mentally slow and a deaf-mute; he read type of about J. 2 at a few inches; he had typical retinitis pigmentosa; one large raised translucent body on right disc; posterior cortical cataracts; refraction hypermetropic; had constant lateral nystagmus and was night-blind; he did odd jobs. IV. 9, aged 36 (1911), was a deaf-mute saddler, with typical retinitis pigmentosa; R. V. = $\frac{6}{36}$ partly, hm. 2 D., L. V. = $\frac{6}{60}$, hm. 2 D.; he was night-blind, and fields of vision were contracted to about 10° in all directions, he had no nystagmus. IV. 6 was drowned in the river at the age of 27, he had been subject to epileptic fits for seven years previous to his death; he was night-blind and a deaf-mute; "his sight was a great drawback." In all these cases defect of vision was only noticed after they went to school, but deafness was noticed at a very early age. Their only normal sibling was a sister, who had normal vision; she had three children, of whom the eldest, aged 7, had a deformed left hand, the thumb and forefinger being complete, the other fingers terminating at the middle joint, all three had normal vision.

The mother, III. 28, had normal fundi, her parents and grandparents, with all their descendants, except the sibship IV. 6—11, had normal vision, and were free from congenital defects. I. 6, by her second husband, had children, II. 12, who all died of phthisis.

The father, III. 16, his two siblings, his parents and his grandparents, had good vision; one of his first cousins, III. 13, was an imbecile; one of his first cousins once removed, IV. 20, was a deaf-mute, with good vision. For further information concerning normal members of this pedigree see the author's original account. No consanguinity. Bibl. No. 301.

Fig. 166. *Usher's Case* 37. A single case of retinitis pigmentosa in a sibship of seven. III. 7, sailor, aged 48 (1897), reported a gradual failure of vision for 12 years; could never see so well as most people; in 1884 he one evening walked off a plank into the sea; denied venereal disease; R. and L. retinal pigmentation at periphery with moss-like arrangement, pigment was scanty; choroidal vessels exposed; no white atrophic choroidal patches; O. D. a dirty white colour, lamina cribrosa visible; retinal vessels contracted to mere threads; vitreous opacities; R. V. = p.l., L. V. = $\frac{3}{36}$; left field of vision contracted peripherally, most at upper part, where it was reduced to 22°; he died, some years previous to 1912, mentally defective and paralysed. His parents, II. 4 and II. 5, died old, and had good sight, as also had his four grandparents, none of whose descendants were known to have had defective sight except III. 7.

III. 7 married his first cousin once removed and had a daughter, V. 9, and three other children who died in infancy; by a second wife he had five living children, there had also been five miscarriages.

The mental defect in V. 5 and 7 was believed to be derived from their mother, IV. 3, who had a sister in a lunatic asylum.

The original pedigree is much more extensive than this reproduction, showing fourteen maternal cousins of III. 7, and nineteen paternal cousins, none of whom were known to have defective vision, also a large

number of more distant relations are included; one paternal first cousin, son of II. 1, also one more distant relation in generation V. were mentally defective. There had been a considerable amount of cousin marriage in the other branches of the family. The author examined 31 members of the pedigree. Consanguinity. Bibl. No. 301.

Fig. 167. *Usher's Case* 35. Two, possibly four, cases of retinitis pigmentosa, in a sibship of eleven. III. 12, aged 21 (1911), a hairdresser, had been short-sighted as long as he could remember, and had great difficulty in seeing at night; he was mentally slow, had some deafness, and had chorea when at school; he lost much blood over an operation on his ear at the age of 13; refraction, my. 3 D. in oblique, 4 D. in opposite meridian for each eye, corrected V. $= \frac{6}{12}$ in each eye; fields of vision contracted to within 20° except at outer part of field which extends to nearly 30°; discs were waxy, retinal vessels very narrow, choroidal vessels exposed, there was extensive moss-like pigmentation of the retina. III. 13, aged 17 (1911), had marked night-blindness and deafness, which was complete in the right ear, the left ear heard a watch at one inch; he had no history of serious illness, but was not very strong; R. V. = L. V. $= \frac{6}{9}$, not improved by glasses; the discs were pale and waxy, the retinal vessels narrow, the choroidal vessels exposed, and much moss-like retinal pigmentation was present over the greater part of the fundus; his fields of vision were like those of his brother III. 12. III. 2 was reported by her mother to be affected in the same way as her brothers; she was obstinate and left home, and had not been seen for many years. III. 7 was reported to be deaf and night-blind; she had not been on speaking terms with her mother for sixteen years; she was married, but had no children. III. 3 died of croup, aged 2 years. III. 5 had chorea, and was very nervous; she was twice married, two of her three children by her first husband had died. III. 10 was seen and had normal fundi. III. 11 had rickets, and was not strong.

The mother of this sibship, III. 13, had normal fundi and was not deaf, but she was mentally peculiar and gloomy; her parents and her siblings, with their children, had good vision; one of her maternal aunts was paralysed at 15 and had fits.

The father, II. 6, had normal fundi; his parents and grandparents, with all their descendants, except the cases described above, had good vision and hearing.

Thirty-one normal first cousins, and other more distant relations, are described in the original extended pedigree. No consanguinity. Bibl. No. 301.

Fig. 168. *Usher's Case* 10. A single case of retinitis pigmentosa in a sibship of eight. III. 5, a female, aged 31 (1911), was unmarried; she had always been weak mentally and bodily, and had imperfect hearing; she had diarrhoea in infancy, "inflammation of lungs" at 16 months, never spoke until the age of 7; defective vision was first noticed at the age of 14 when she knocked against lamp-posts, it had gradually got worse; she had a violent temper, especially during menstruation, and once stabbed her mother in the arm, at other times she was morose. In 1903 she had posterior cortical cataracts, moss-like retinal pigmentation confined to a broad band at periphery of fundus, the extreme periphery was not pigmented; at the pigmented band the choroidal vessels were more exposed than elsewhere, and a few small bright white bodies were scattered here and there in the band region; O. D., a dirty white colour; retinal vessels very narrow; refraction, R. my. 1·25 D. in oblique meridian, 2·25 D. in opposite meridian; corrected V. $= \frac{6}{18}$ partly, L. my. as for R. with corrected V. $= \frac{6}{12}$ partly; fields of vision contracted. Eight years later (1911) pigmentation of retina was more marked, and night-blindness was severe, fields much contracted, speech defective, R. V. = L. V. $= \frac{6}{24}$ with correction; Wassermann negative. Her mother, II. 6, was healthy, with normal vision, but had a severe mental shock when $4\frac{1}{2}$ months pregnant with III. 5. Her father, II. 3, was excitable, but had a normal fundus; he had syphilis four years before his marriage. The grandparents had good vision.

Of the siblings of III. 5 the eldest, III. 2, had a normal fundus, and had one child, IV. 1, with normal fundus; III. 4, "quick tempered," had a normal fundus and one living child with normal fundus; III. 6—8 had good vision; III. 9 lived a few hours, said to have had club foot and a monster head; III. 10 had good vision.

A maternal uncle II. 4 died, aged 4, of "water in head."

The original and more extensive pedigree shows the eight great-grandparents of whom seven were reported to have normal vision, also nine first cousins and many more distant relatives are reported to have had normal vision. No consanguinity. Bibl. No. 301.

Fig. 169. *Usher's Case* 38. A single case of retinitis pigmentosa in a lazy, mentally feeble, illegitimate farm worker. IV. 17, aged 18 (1902), was night-blind, and had always been short-sighted; discs were a good colour, the retinal arteries distinctly contracted, choroidal vessels much exposed; there was much typical pigmentation at the periphery of the retina; fields of vision were contracted; no vitreous or lens opacities; nystagmus on lateral movement of eyes; refraction, myopia 3 D. in each, corrected V. $= \frac{6}{60}$ in each; with light reduced, so as to allow a normal eye $\frac{6}{12}$, he did not read $\frac{6}{60}$. Vision was reported by his doctor to be not markedly worse nine years later.

III. 5, believed to be the father of IV. 17, had normal fundi, his parents, grandparents, his siblings and their children, all had good vision; he was married, and had nine children, of whom IV. 6 died in

infancy, the others, who were all under 13 years of age, saw well. III. 12, the mother of IV. 17, died aged 44; two of her siblings died aged 16, and several brothers and sisters died in infancy; she was married and had four children, of whom one, IV. 18, died aged 15, of spinal disease, the others had normal fundi. Her parents, II. 6 and 7, and two paternal aunts, II. 4 and 5, had good vision. No consanguinity. Bibl. No. 301.

Fig. 170. *Usher's Case* 6. Retinitis pigmentosa in two members of a sibship of five, the offspring of first cousins. III. 3, aged 23 (1911), had marked night-blindness but saw well in the day time; his fields of vision were much contracted; retinal arteries were narrow, discs were pale and waxy, retinal pigmentation was very extensive, reaching to the papilla; refraction emmetropic. III. 5, a fisherman aged 19, had always had defective vision, he was night-blind and his vision was becoming worse; R. V. $= \frac{1}{60}$, L. V. $= \frac{4}{60}$; refraction low hypermetropia: discs were pale, retinal arteries much narrowed, choroidal vessels exposed, much moss-like retinal pigmentation was visible all over the periphery of the fundus; fields of vision were contracted, and each had a complete ring scotoma; Wassermann test negative. Of their siblings III. 1 died aged 13, III. 2 and 4 had good vision. Their mother, II. 7, was considered peculiar, she had a normal fundus, and had no miscarriages; of her siblings, II. 8 died aged 47, mentally defective, she did nothing for herself and never had good sight; II. 9 and the elder of II. 10 saw well; the younger of II. 10 had a bad temper and drank, his sight was defective and was getting worse, but he was found to have myopia and no retinitis pigmentosa. II. 11 was a fisherman with defective vision, which his doctor reports to be getting worse. The parents, grandparents and three great-grandparents of II. 7 were reported to see well; her mother, I. 3, was seen to have a normal fundus. The father of III. 1—5, first cousin of his wife, had a normal fundus but he had a cleft palate, his parents had normal vision; the parents of I. 1 saw well; II. 4 had eight siblings, of whom five died in infancy, the others and their children saw well. The original pedigree shows twenty-three first cousins and many more distant relatives free from any known defect. Consanguinity. Bibl. No. 301.

Fig. 171. *Usher's Case* 18. A single case of retinitis pigmentosa in a sibship of eight. III. 11, aged 53 (1911), a male factory worker, had difficulty in seeing in dim light and in seeing at either side of him; no defect was noticed until he was aged 45; the discs were pale; retinal vessels much contracted, profuse retinal pigmentation typical of retinitis pigmentosa, with two patches at outer part of left fundus suggestive of "choroiditis"; opacities at posterior part of lenses. R. V. $= \frac{6}{9}$, L. V. $= \frac{6}{18}$ partly; fields of vision concentrically contracted to 10°; Wassermann negative. Of the seven siblings of III. 11, three died young, and the others, with the children of two of them, saw well.

III. 11 had six children, of whom IV. 4 had high hm. astigmatism, fundi normal; IV. 6 had periodic internal strabismus, refraction R. and L. hm. 8 D. in vertical, 9 D. in horizontal meridian; fundus normal; IV. 7 died in infancy; the others had normal vision.

The father, II. 5, had good vision; the mother, II. 6, was short-sighted, screwed her eyes up, could see in old age, only had glasses for the last few years of her life, which ended at the age of 89. Three of the four grandparents were known to have seen well. No consanguinity. Bibl. No. 301.

PLATE XVII. Fig. 172. *Usher's Case* 22. An isolated case of retinitis pigmentosa commencing late in life. III. 18, female, seventh born in sibship of eight, aged 64 (1905); night-blindness first noticed about the age of 55; she was married and had 8 children, no miscarriages; severe bleeding at menopause confined her to bed. In a light allowing $\frac{6}{12}$ to normal eyes she could not see $\frac{6}{60}$; refraction R. and L. hm. 1 D., R. V. = L. V. $= \frac{6}{9}$ with correction; right field of vision nearly full; discs were pale, rather yellowish, lamina cribrosa much exposed; retinal arteries narrow; typical moss-like retinal pigment in each eye confined to an area extending from the disc downwards but not reaching the periphery of the fundus; choroidal vessels over the whole fundus were conspicuous; no vitreous opacities. Four years later there was very little change in the appearance of the fundus, but both fields were contracted and in the left was an absolute partial ring scotoma; four years later, again (1913), a complete absolute ring scotoma was present in both fields, and the retinal pigment had increased considerably; Wassermann test negative. Both parents lived to old age and had good sight. Two brothers of the patient had cataract, three brothers and two sisters had good sight. Of her children IV. 18 died aged 4; IV. 26 died aged 21; the other six, also their children, saw well. The patient's grandparents and aunts and uncles, also many more distant relatives, were reported to see well; no deformities, insanity, or consumption known in the stock. No consanguinity. Bibl. No. 301.

Fig. 173. *Usher's Case* 29. Retinitis pigmentosa in a brother and sister, the youngest members in a sibship of fourteen. III. 19, aged 45 (1898), was rather deaf, and had never seen well in a dim light; at this time R. V. = L. V. $= \frac{3}{36}$, extensive retinal pigmentation with pallor of discs and narrowed retinal vessels were noted. In 1910 her R. V. was reduced to hand-movements at 8 feet, L. V. to finger counting at 6 feet; there was a slight opacity of posterior part of lens in each; moss-like retinal pigmentation extended over practically the whole fundus. She had married twice, but had no children. III. 20, aged 40 (1895), was rather deaf, and had noticed night-blindness for three years only; for him R. V. $= \frac{6}{18}$, L. V. $= \frac{6}{24}$; extensive retinal pigmentation was present at the periphery of the fundi, the discs were pale,

the retinal vessels much contracted, vitreous clear, and his fields were contracted to about 15°. There appeared to be some difference of opinion as to whether the defects in III. 19 and 20 were the result of snowballing when they had measles or were due to slaps on the heads from their drunken father.

The mother, II. 6, was a "clever" woman, and had no night-blindness or deafness; she died aged 69. The father, II. 1, a postman, had good sight and hearing. Eleven aunts and uncles were free from defect in sight and hearing; also the four grandparents and four great-grandparents were believed to see and hear well.

III. 20 had five children, one of whom died in infancy, the others and the children of two of them saw and heard well.

Of the siblings of III. 19 and 20, III. 1 had phthisis, III. 11 died in infancy, the others were believed to be free from inherited defects; six of them had children, some of them grandchildren and great-grandchildren; one boy in generation V. had mental defect, one girl in generation IV. was epileptic. The original pedigree is much extended, and shows forty-eight or more first cousins and many more distant relatives, all believed to be free from defects of sight or hearing; one maternal first cousin was mentally defective. No consanguinity. Bibl. No. 301.

Fig. 174. *Alleman's Case.* (Taken from Loeb.) Retinitis pigmentosa in the descendants of a woman, I. 2, who was herself affected. Of the fifteen children of I. 2—II. 2, a male, had retinitis pigmentosa; II. 3, a female, was said to suffer from night-blindness; II. 5, a male, had retinitis pigmentosa; II. 7, a male, had night-blindness; four children had normal vision, and seven children died young, and nothing was known about the condition of their eyes. II. 2 had four children, one male and one female, with retinitis pigmentosa, one child with normal eyes, and one who was said to be blind. II. 3 had two children with retinitis pigmentosa and one with normal vision. II. 5 had one child with normal vision. II. 7 had one child with retinitis pigmentosa and one with normal vision. No further information is given. No consanguinity recorded. Bibl. No. 261.

Fig. 175. *Machek's Case.* Retinitis pigmentosa in five siblings, the offspring of consanguineous parents, two sisters were normal and had normal children. The five night-blind siblings first showed symptoms of the disease at the age of 10, the youngest, a boy, was completely blind at the age of 18, the others, all girls, were blind at the age of 20. They had nystagmus, and myopia of 5 to 9·5 D.; only in two cases were typical pigment deposits to be seen; some defect of colour vision had been demonstrated in three of the cases. Consanguinity. Bibl. No. 110.

Fig. 176. *Aubineau's Case.* Retinitis pigmentosa in three siblings, the offspring of parents who were first cousins and who themselves were the offspring of first cousins. The mother died aged 75, and the father aged 78; a paternal aunt could see still at the age of 81, and there were no ocular affections known amongst the relatives on either side.

In the sibship III. 1—4, III. 1 represents two sons, one of whom died of cholera aged 47, and the other died aged 53, both had perfect vision. III. 2, a son, had never been able to go about alone, and had been almost blind after sunset; he had nystagmus, convergent strabismus of the left eye, and at the time of examination his vision was reduced to perception of light; the discs were yellowish, only two or three thread-like retinal vessels could be seen; the retina was pale yellow, and typical pigmentary deposits were present over the whole fundus. He became tubercular and died; a *post-mortem* examination was made of the eye. III. 3, Rosalie C., aged 44, had been paralysed for 4 years and had had ocular difficulties since her birth, she was however able to go about alone in daylight up to the age of 20; she now had nystagmus, strabismus, vision reduced to perception of light, and fundi similar to those of III. 2. III. 4, Marie C., aged 42, a very intelligent woman, had always had bad sight, she had nystagmus and myopia of 3 D.; in good daylight she was able to recognise a hand; her fundi were similar to those of her brother and sister. Consanguinity. Bibl. No. 219.

Fig. 177. *Chaillous' Case.* Retinitis pigmentosa associated with deaf-mutism in an only child of unrelated parents. III. 1, a deaf-mute boy, was always debilitated, and was unable to walk until he was three years of age; his parents noticed trouble with his vision from his earliest youth, but the condition appeared to remain stationary; he was emmetropic; R. V. = L. V. = $\frac{5}{15}$; fields were contracted; media normal; and there was pigmentation of the retina which was more marked on the inner and outer sides than above or below. This distribution of the pigment was noted also in the other deaf-mute cases of this author. Of the parents the mother was normal, the father died aged 27, he suffered from articular rheumatism and complained of severe headaches; he was said to be very short-sighted and suffered from night-blindness. Of the grandparents, I. 1 died of paralysis in old age; I. 2 died of cerebral congestion; I. 3 died, aged 43, of pneumonia, and was alcoholic; I. 4 was living, and normal. No consanguinity. Bibl. No. 266.

Fig. 178. *van der Hoeve's Case.* Retinitis pigmentosa, deaf-mutism and albinism in a sibship of six. III. 1 suffered from night-blindness, fundus not described. III. 2 had a completely albinotic fundus. III. 3, a deaf-mute boy, examined at age of 10, had R. V. = L. V. = $\frac{1}{2}$; fields of vision concentrically contracted; the papilla was grayish yellow and atrophic; the retinal vessels were narrowed, and there was

scanty pigmentation of the retina typical of retinitis pigmentosa; there were also yellowish white round spots posterior to the retinal vessels which the author considered to be retinitis punctata albescens. III. 4, a girl, seen aged 4, was deaf-mute and night blind; she had contraction of fields of vision, atrophic papilla, narrowed retinal vessels and retinal or retino-choroidal changes; the author describes her as a case of atypical retinitis pigmentosa. III. 5 had normal sight and hearing. III. 6, a deaf-mute girl, was seen in her first year to have a completely albinotic fundus; the papilla was of a grayish colour, and the retinal vessels were narrower than normal; several months after her first birthday a single grayish white patch was seen in her fundus. The parents of this sibship were healthy and normal, there was no syphilis and no history of eye or ear disease in the ancestry; the grandmothers were cousins. The father's twelve siblings were healthy though one sister, II. 4, was a dwarf and a brother had a boy, III. 7, who was deaf and an idiot, had a right internal strabismus, and who had some abnormal pigment flecks in the periphery of his retina. Consanguinity. Bibl. No. 291.

Fig. 179. *Chaillous' Case.* Retinitis pigmentosa associated with deaf-mutism in several members of a sibship, the offspring of first cousins. III. 1, aged 24, was deaf-mute and blind; in her early childhood she had had some vision but became completely blind at 10 to 12 years of age; she was extremely intelligent. III. 2, a male, was born prematurely, and died aged 29 days. III. 3, a female, died aged 3, she was not deaf but had very little vision, and was only able to see to go about alone. III. 4 was a normal female, aged 18. III. 5, a normal female, aged 16. III. 6, a deaf-mute, aged 13, had never seen clearly, but the condition of his eyes appeared to be stationary; R. V. $= \frac{5}{10}$, L. V. $= \frac{5}{15}$; visual fields were contracted; media normal; there was some pigmentation of the retina. III. 7, a female, died aged 3, of tuberculosis; she was neither deaf nor blind. III. 8, aged 8, was a deaf-mute and blind; she had retinitis pigmentosa with very little pigment. III. 9, a female, died aged 14 months, of convulsions; she was a blind deaf-mute, and suffered from osteomalacia. Of the parents the mother was normal, and the father with normal vision had some affection of his vertebral column. Of the grandparents I. 1 and I. 4 were normal. I. 2 died of heart disease, and I. 3 was alcoholic. Consanguinity. Bibl. No. 266.

Fig. 180. *Derigs' Case.* Retinitis pigmentosa and deafness in two cousins, whose fathers were brothers and whose mothers were aunt and niece. II. 1, Eduard Huland, aged 43, had R. V. $= \frac{20}{100}$, L. V. $= \frac{20}{50}$; fields of vision were contracted; a very diffuse pigmentation reached to the papilla, the retinal vessels were narrowed, and there was choroidal atrophy; he also had posterior polar cataracts; his eight siblings all saw well. The patient had noticed a diminution of vision since childhood, he was also deaf. II. 3, Otto Huland, aged 17, had normal central vision, and read J. 1; there was some contraction of his fields of vision, and there was a diffuse epithelial atrophy reaching to the papilla, in the periphery of the retina were streaks of pigment; the papilla was not discoloured; the retinal vessels were narrow; the patient was also deaf. Consanguinity. Bibl. No. 112.

Fig. 181. *Magnus's Case.* A mentally defective man had six children, of whom five were deaf-mutes and one had retinitis pigmentosa; the mother of this sibship from another marriage with a healthy man had healthy children. No consanguinity recorded. Bibl. No. 142.

Fig. 182. *Gonin's Case.* II. 4, the sixth born in a sibship of nine, aged 24, had suffered from night-blindness since the age of 7 or 8 years, his vision was reduced to finger counting at 3 or 4 metres, and the ophthalmoscopic appearances were typical of retinitis pigmentosa. One of his siblings, the fourth born, who died aged 35, had retinitis pigmentosa. No consanguinity. Bibl. No. 218.

Fig. 183. *Derigs and Bayer's Case.* Retinitis pigmentosa in the second and last born members of a sibship of eight. II. 2, Daniel Lindenberg, was first examined by Bayer at the age of 20 years when his vision was $\frac{1}{5}$, fields were concentrically contracted, typical pigmentation was confined to the equatorial region, and he showed diffuse atrophic changes in the choroid. Derigs examined him twelve years later, and found that his condition had progressed; the boundaries of his fields of vision now were L. horizontal, outer 5°, inner 30°, L. vertical above 7°, below 10° with similar defects in the R.; the pigmentary deposits were extending towards the papilla, and posterior polar cataracts had developed.

II. 6, Wilhelm Lindenberg, was examined by Derigs at the age of 20. R. V. = L. V. $= \frac{20}{100}$; boundaries of fields of vision were L. temporal 65°, nasal 45°, above 30, below 23°; R. temporal 50°, nasal 45°, above 27°, below 15°; typical pigmentation of the retina was present; he also had R. divergent strabismus. Both brothers were night-blind. Three other brothers and two sisters had normal vision, one sister was reported to be "short sighted." No consanguinity. Bibl. Nos. 75, 112.

Plate XVIII. Fig. 184. *Holloway's Case.* III. 4, aged 34, had retinitis pigmentosa, complicated by albuminuric retinitis. She had posterior polar cataract of the R. lens, opacities in the vitreous, an oval disc with blurred margins and greyish coloration; the retinal vessels were reduced in calibre; there was a slight greyish haze over the posterior pole of the eye with a typical stellate figure in the macula region; deposits typical of retinitis pigmentosa reached almost to the macula region; there was contraction of fields with small central scotomata; V. $= \frac{5}{40}$. The patient had been marasmic as a baby, and from $2\frac{1}{2}$ to 8 years had attacks of probably petit mal; she had scarlet fever at 6 and measles at 9 years, to which she

attributes the origin of her retinitis pigmentosa, for she was blind for three days at that time; later she had severe pneumonia.

The patient had one living brother, who suffered from retinitis pigmentosa; one brother died aged 21, of tape worm; one brother died aged 7, of pneumonia, and all her four sisters died in childhood of diphtheria, measles, pneumonia or scarlet fever. These six siblings were said to have had good vision. Of the patient's three children IV. 1, a boy, aged 14, and IV. 3, a girl, aged 6, had good vision; IV. 2, a girl, aged 12, wore glasses, and was said to have defective vision.

A maternal aunt was markedly near-sighted, and her son was said to have had very defective vision since childhood. A maternal great uncle also had very poor eyes from his childhood, and was supposed to be near-sighted; he had been in an asylum for 35 years as a result, it was said, of a blow on his head. The parents, II. 3 and 4, had good vision. No consanguinity. Bibl. No. 272.

Fig. 185. *Magnusson's Case.* Retinitis pigmentosa in dogs. This is the only pedigree found showing the inheritance of retinitis pigmentosa in animals; it is claimed to be the first well-authenticated case of retinitis pigmentosa in the dog. The cases occurred in a valuable breed of Gordon Setters, and was believed to have been introduced into the stock by an imported unaffected dog named Ranger I. 2. Mated with I. 1, Ranger had a son, II. 1; mated with I. 3, he had puppies, including II. 2 and 3. These three puppies were normal.

II. 1, mated with his half-sister II. 2, produced six puppies, of which three males had retinitis pigmentosa, one male and two females were normal. II. 2, mated with her brother II. 3, had a litter of puppies, of which only one was preserved. She, III. 7, named Lisa Odinsheim, had retinitis pigmentosa. Lisa was then mated with Ranger, her grandfather on both sides, and produced five puppies, of which one male and one female had retinitis pigmentosa, two males and one female were normal.

Night-blindness was first noticed in these dogs at the age of about six months; in one case the dog became completely blind in four years. Ophthalmoscopic examination showed thread-like opacities in the vitreous, discs grey, retinal vessels very small; pigment was present as a coarse network. *Post-mortem* examination showed a severe degree of retinitis pigmentosa affecting chiefly the outer layers of the retina, but in places there was complete atrophy of the whole retina; the choroid was atrophic, the chorio-capillaris was thin and the vessels scanty, the larger choroidal vessels were normal. The pigment epithelium showed irregularity and proliferation, but the amount of pigment deposited in the retina was slight relatively to the extensive atrophy. No evidences of inflammation were found, the whole picture was characteristic of a slowly progressive atrophy. Consanguinity. Bibl. No. 276.

Fig. 186. *Maude's Case.* (Sent to Nettleship.) Retinitis pigmentosa in three siblings, members of a stock showing other forms of degeneracy. I. 2 died in old age of epithelioma of the vulva, her mental condition was good, and she had five children who all appeared to have normal vision. No information is given of I. 1. II. 2 had a son, III. 2, aged about 47 (1908), who was half-witted, and who had six children, IV. 1—6. Of these children the eldest was a congenital imbecile; IV. 4 had fits in infancy.

II. 3 and her husband were both alcoholic and arthritic, II. 3 also had Graves' disease with at one time ophthalmoplegia; she had at least one son, III. 3, who also was alcoholic. III. 3 married his first cousin III. 4, who drank more than was good for her, and had ten children, three of whom had retinitis pigmentosa. III. 4 also had a miscarriage, IV. 8. IV. 7 was under observation from the age of 8 (1894) until the age of 22 (1908), he had retinitis pigmentosa with optic nerve atrophy and greatly contracted fields at the age of 10 but was able to earn his living up to the age of 20 years. IV. 9 was very rheumatic and hysterical. IV. 11, at the age of 11 (1908), had V. $= \frac{6}{24}$ in each eye, choroids markedly thin, discs pale, retinal arteries narrowed, some patches of pigment in the equatorial region. IV. 12, two years younger than IV. 11, had V. $= \frac{6}{36}$, and slight hypermetropia; the ophthalmoscopic changes were similar to those of her sister but rather less advanced. One of the brothers, IV. 10, was examined, and found to have a normal fundus. IV. 13 died aged 3 months, of general tuberculosis. IV. 14, aged 3 (1908), was not examined.

The mother of this sibship, III. 4, was the daughter of II. 7, and had three normal siblings. II. 8 had two normal children. II. 5 was married but had no children; she was extremely hysterical. Consanguinity. Bibl. No. 251, pp. 345—6.

Fig. 187. *Neuffer's Case.* (Taken from Nettleship.) Two healthy first cousins, have three deaf-mute sons who are blind from retinitis pigmentosa, and one normal daughter, who married and had a son, who had retinitis pigmentosa. Consanguinity. Bibl. Nos. 251, p. 29, 176.

Fig. 188. *Roy's Case.* Retinitis pigmentosa in three siblings, their father, and their paternal grandmother; only one case was examined. III. 1, aged 29, the editor of a paper, was reported to have had defective vision at the age of one year; he himself had noticed for a long time that his vision was dim, and he thought the condition was stationary; he was almost blind in the evening, and could only see straight in front at any time; he had no history of severe illness, and was not syphilitic; R. V. = L. V. $= \frac{20}{30}$; visual fields were contracted to the 10° circle for white and still more markedly for colours; the discs were hazy, and pigmentation of the retina was typical. Of his siblings five brothers and one sister

had normal vision, one brother who was dead, and his youngest sister aged 12, had retinitis pigmentosa. The parents were living, the mother, aged 56, was normal; the father, aged 70, suffered from severe headaches and was night blind, he had spectacles at the age of 16, but they did not help his defective vision. The paternal grandmother was blind at the age of 60, and had suffered in her early years in the same way as her son II. 2. No consanguinity recorded. Bibl. No. 184.

Fig. 189. *Wilbrand and Saenger's Case.* II. 3, aged 40 years, had changes due to choroiditis in the region of the papilla, she also had pigmentary disturbances, which are not described in detail by the author, and myopia of 4 to 5 D.; R. V. = finger counting at $\frac{1}{2}$ m., L. V. = finger counting at $1\frac{1}{2}$ m.; she had bilateral incipient cataract. A younger brother saw badly, and was night-blind. Two children of an aunt were similarly affected, as also were the children of a sister. The patient had no children; she complained of headaches. The author considers that the choroidal changes and character of the fields of vision were such as to suggest a diagnosis of disseminated chorio-retinitis, whilst the pigment flecks and the family history of night-blindness suggest that the case should belong rather to the retinitis pigmentosa group. No consanguinity. Bibl. No. 264.

Fig. 190. *Darier's Case.* Retinitis pigmentosa in two brothers, their three sisters had normal vision. III. 1, a butcher, aged 31, complained that he had myopia: R. V. = $\frac{1}{10}$, L. V. = $\frac{1}{50}$; visual fields were contracted to $\frac{1}{3}$ the normal area; the papillae were pale and blurred, the retinal vessels were narrowed; the fundus showed very little pigment, but some typical moss like deposits were present in the periphery; the papillae were surrounded by a narrow zone of choroidal atrophy; this patient was night-blind. III. 2, aged 18, also a butcher, had never had good sight and had been night blind since infancy; R. V. = $\frac{1}{3}$, L. V. = $\frac{1}{2}$; the fields were reduced to give central vision only; the papillae were rosy and blurred, the retinal vessels very narrow; no pigmentation was visible in the retina.

The father, II. 1, had very good eyes, the mother was said to be myopic; the maternal grandfather became blind at the age of 30. No consanguinity. Bibl. No. 148.

Fig. 191. *Hutchinson's Case.* II. 2, aged 57 when examined, reported that he could see well until he was aged 18, when his sight began to fail, especially at night; at about the age of 37 it had failed more rapidly but the condition had now appeared to be stationary for about five years; he had had no pain in his eyes but complained of muscae occasionally; night-blindness was marked, vision was reduced to counting fingers; the discs were greyish white with blurred margins, the retinal vessels very narrow; around each disc was a greyish white area; at the periphery were very extensive accumulations of coal-black pigment beneath which the choroid was seen to be yellow and speckled with white. II. 2 had twelve children, all of whom were healthy but one; a daughter, aged 19, reported that "her sight left her at night and had been failing for about a year"; the ophthalmoscope showed an early stage of retinitis pigmentosa. No consanguinity. Bibl. No. 65.

Fig. 192. *Jeffries' Case.* II. 3, aged 19 years, had been more or less amblyopic since childhood and suffered from night-blindness; the condition had progressed and he carried on his work as shoemaker with difficulty; he had typical retinitis pigmentosa. The patient had three brothers and three sisters, his eldest brother, II. 1, aged 36, had such bad vision that he was unable to work; also a sister, aged 25, had very bad sight but she could see better than II. 1. The mother, I. 2, had died about nine years before, she had good eyes. The father, aged 60, also had good eyes. The patient had good general health and intelligence. No consanguinity. Bibl. No. 61.

Fig. 193. *McCreight's Case.* Retinitis pigmentosa in two siblings the offspring of "cousins." II. 1, aged 25, had had bad vision since she could remember but it had become noticeably worse the last two years; she could not read but was able to attend to her house duties; V. = finger counting at 8 feet; she had lateral nystagmus and anterior polar cataract in each lens; her visual fields were contracted to within 10° of fixation point; the ophthalmoscope showed typical changes in the fundus. Her brother, II. 2, also had typical retinitis pigmentosa. Consanguinity. Bibl. No. 190.

Fig. 194. *Darier's Case.* Retinitis pigmentosa in II. 1, aged 32, who had been night-blind since infancy; the condition was at an advanced stage and the fundus showed typical changes; R.V. = L.V. = $\frac{1}{4}$. Two siblings, aged 30 and 28 respectively, were night-blind, three siblings had normal vision. The father, aged 64 and the mother aged 60, had good health and very good vision. No consanguinity recorded. Bibl. No. 148.

Fig. 195. *Darier's Case.* Retinitis pigmentosa in a father and two of his six children. I. 1, aged 64, was almost blind with retinitis pigmentosa; his wife was not related to him and had good vision. II. 1 was night-blind but still had fair vision, her defect was first noticed at the age of 15 years. II. 2, aged 19, was night-blind, her visual fields were greatly contracted, R.V. = $\frac{1}{2}$, L.V. = $\frac{1}{3}$, and her fundi were typical of retinitis pigmentosa. No consanguinity. Bibl. No. 148.

Fig. 196. *Derigs' Case.* Retinitis pigmentosa with atrophic changes in the choroid associated with ectopia lentis and corectopia in a brother and sister. II. 1, aged 27, had R.V. = finger counting at 5 feet or with + 4 D. = finger counting at 20 feet, L. V. = finger counting at 3 feet, with + 4 D. at 5 feet. II. 2, aged 21, had L. V. with + 4 D. = $\frac{5}{60}$, R. V. = perception of light only; ophthalmoscopic examination was made in each case. No further information is given. No consanguinity recorded. Bibl. No. 112.

Fig. 197. *Jeffries' Case.* II. 1, a farmer, aged 33, was well developed, healthy, and fairly intelligent, but he had never seen so well as other people; at the age of 21 he had "lung fever" and his vision was worse after this; he was now only able to see to count fingers, but could read up to three or four years ago; there was an abundant deposit of pigment reaching to the papilla; floating opacities were present in the vitreous and there was a delicate web-like deposit on the posterior capsule of both lenses. The patient had five sisters who all had good vision, his one brother, II. 2, aged 44, had gradually become nearly blind. A maternal uncle, I. 3, had also gradually lost his sight before the age of 45.

The mother, I. 2, aged 67, was reported to be "near-sighted." No consanguinity. Bibl. No. 61.

Fig. 198. *Ryerson's Case.* (Taken from Loeb.) Retinitis pigmentosa in four siblings, the offspring of first cousins. The parents were said to be without visual defects. No further information is given. Consanguinity. Bibl. No. 261.

Fig. 199. *Carpenter's Case.* Retinitis pigmentosa in three members of a sibship of five. II. 1 had noticed defective vision since she was aged 6; she was night-blind and had extensive pigmentation of the retina. Her brothers, aged 18 and 16, noticed impaired vision at the ages of 12 and 10 years respectively; they were not night-blind, the elder showed the usual pigment deposits in the retina, the younger had no pigmentation. The three siblings had ring scotomata and contracted visual fields. No history of syphilis. Two sons of the mother's brother were believed to be similarly affected but were not examined. No consanguinity. Bibl. No. 287.

Fig. 200. *H. Schmidt's Case.* I. 1, a peasant, aged 55, had seen badly with his right eye since childhood; it was found to be completely amaurotic except for a very small portion of the outer quadrant of the field of vision where he could still see fingers at a near distance; on ophthalmoscopic examination atrophy of the disc was found with some narrowing of the vessels; left eye was normal. I. 2 had normal eyes and there was no history of syphilis in either. Of their three children, II. 1, a girl, aged 27, had concomitant convergent strabismus, oscillatory nystagmus at times, was emmetropic, had good visual acuity and no night-blindness; the papillae were of a particularly dull grey colour flecked with small white spots on the outer side, the margins were blurred, the vessels unusually narrow; in other respects the fundi were normal. The second daughter, II. 2, aged 21 years, and also her brother, aged 17, had typical retinitis pigmentosa with pale discs, narrowed vessels, and scattered deposits of pigment in the retina; in both cases the condition was more advanced in the right eye than in the left; each had suffered from night-blindness and diminution of vision since childhood. II. 2 also had nystagmus and convergent strabismus. No consanguinity recorded. Bibl. No. 88.

Fig. 201. *Reinecke's Case.* II. 1, a patient suffering from retinitis pigmentosa, reported that two of his siblings suffered from night-blindness, and three siblings were hard of hearing. The parents were first cousins. No further information is given. Consanguinity. Bibl. No. 179.

Fig. 202. *Wilbrand and Saenger's Case.* Retinitis pigmentosa in three sisters. No further information given. No consanguinity. Bibl. No. 264.

Fig. 203. *Thompson's Case.* Superficial choroidal atrophy, without subjective symptoms in a woman, aged 57, whose father, and whose three nephews (brothers), probably suffered from atypical retinitis pigmentosa. II. 1, seen, aged 57 (1901), was found to have in each fundus an area of superficial choroidal atrophy with well-defined margin around the disc; beyond this area there was a good deal of pigmentary disturbance, the macula was comparatively normal; the changes were remarkably similar in each eye; R. V. $= \frac{6}{9}$ (3 letters), L. V. $= \frac{6}{6}$ (3 letters); fields of vision were very nearly full, no scotomata were present and the patient was not night-blind; her retinal vessels were not narrowed. She reported that her father who died 30 years before had always stumbled against things on account of his bad sight, and yet he could see to read a small print copy of the Bible; he did not go blind. Three of her nephews (brothers) suffered from night-blindness. III. 1 was seen to have minute visual fields with V. $= \frac{6}{9}$ in each. III. 2 had pigment changes at the macula; an irregular but well-defined area of normal choroid round the macula, with atrophy of the chorio-capillaris and pigmentary changes beyond this area; retinal vessels of a fairly good size; visual fields were full peripherally but ring scotomata were present; R. V. with $-2{\cdot}5$ D. $= \frac{6}{6}$, L. V. with $-3{\cdot}0$ D. $= \frac{6}{12}$. III. 3 was reported to be getting to see as badly as his grandfather, and to be afraid to go out after dark. The condition was progressing in the three brothers. The general health of the family was good. No consanguinity. Bibl. No. 216 *a*.

Fig. 204. *Bane's Case.* III. 1 was first examined in 1895 when she complained of having had poor vision with night-blindness since childhood; R. V. = L. V. $= \frac{6}{24}$, with correction $= \frac{6}{15}$; the discs were a dull muddy colour, the retinal vessels small, and typical retinitis pigmentosa was present; her fields were contracted to 15° from fixation point. In 1899 vision was reduced to $\frac{6}{30}$; in 1915 she complained of rapid failure of vision during the last six months, with pain and headaches, there was an increase of visible pigmentation and her vision was limited to the central part of the field. Her parents were unrelated and had nine children, of whom two daughters had retinitis pigmentosa. An aunt of her father, I. 3, and also a cousin on her father's side, were said to be similarly affected. No consanguinity. Bibl. No. 303.

Fig. 205. *Darier's Case.* Retinitis pigmentosa associated with polydactyly. III. 3, a boy, aged 12, had been noticed to be night-blind since the age of 5 or 6 years; he was very dark and his fundus was of a slaty grey colour, the macula almost black; his fields were reduced to central vision only; R. V. $= \frac{1}{3}$, L. V. $= \frac{1}{10}$; the retinal vessels were narrowed; there were no typical pigment deposits of the bone corpuscle type but black points of pigment could be seen here and there along the course of the vessels; he had six fingers on each hand and six toes on each foot. Two sisters older than the patient and one sister younger had good vision; two brothers had died, one aged 3 years, the other aged 7 months, each had twelve fingers and twelve toes. The parents were not night-blind, a maternal uncle had bad sight and coloboma iridis; the paternal grandfather had lost an eye (cause not given). No consanguinity. Bibl. No. 148.

Fig. 206. *Reinecke's Case.* Elsie M., aged 19, III. 1, her mother, II. 2, and all her siblings, also her maternal grandfather, I. 1, and two of her three siblings suffered from night-blindness. The author gives no further information, but since he quotes the case as an example of inherited retinitis pigmentosa we assume that the night-blindness was associated with this condition and was not of the congenital stationary type without fundus changes. No consanguinity recorded. Bibl. No. 179.

Fig. 207. *Drinkwater's Case.* Retinitis pigmentosa in the direct line of descent in three generations. I. 3, an affected female, had two brothers and four sisters, all of whom had normal vision; she married, and had two sons, II. 2 and 3, who both had retinitis pigmentosa. II. 2 married and had three children of whom two were sons with normal vision, one a daughter with retinitis pigmentosa. No further information given. No consanguinity recorded. (Unpublished, sent to K. Pearson.)

Fig. 208. *Nolden's Case.* II. 1, aged 19, had for both eyes V. $= \frac{18}{20}$; his fields of vision were concentrically contracted, the R. to the 15° circle and the L. to 18°; he had no opacities of the lens and no pigmentation of the retina, but there was a fine white stippling of the choroid present in the equatorial zone; no mention is made of night-blindness. This is possibly a case of retinitis pigmentosa *sine pigmento.* The mother and six of the patient's seven siblings were said to suffer from a diminution of vision. The case is rather doubtful; it is included here since it has been quoted in the literature as a case of inherited retinitis pigmentosa. No consanguinity. Bibl. No. 94.

Fig. 209. *McCassy's Case.* Retinitis pigmentosa in three sisters, aged 15, 18, and 22, respectively; the eldest had noticed gradual diminution of vision for six or seven years. All were night-blind, there was no choroidal atrophy, opacities of the vitreous or involvement of the optic nerve. Parents were first cousins. Consanguinity. Bibl. No. 189.

Fig. 210. *Mooren's Case.* Four cases of retinitis pigmentosa in a sibship of eight. No consanguinity recorded. Bibl. No. 40.

Fig. 211. *Sambuc's Case.* Retinitis pigmentosa in six siblings, the only members of a sibship of fourteen who survived the age of 3 years; thus six males, the first, second, eighth, ninth, tenth and twelfth born, died under the age of 3, two twins, the last born, died aged a few months, the surviving two males, and all the four females, had retinitis pigmentosa. This account is taken from Nettleship who reports from a thesis published by the author in Bordeaux in 1896. The title of the thesis is not given, and we have been unsuccessful in our efforts to see it. No consanguinity recorded. Bibl. No. 251, p. 343.

PLATE XIX. Fig. 212. *Mücke's Case.* This is a very interesting pedigree showing retinitis pigmentosa in two or more sibships with night-blindness, high myopia, congenital deafness and other inheritable defects in several branches of the family. I. 1 and 2 were believed to have normal eyes; they had three children, II. 4, 6 and 7, who all had apparently normal vision and who married apparently normal individuals. II. 4 had a son, III. 4, who had high myopia. II. 6 had a son, III. 5, with normal vision. II. 7 had a daughter, III. 6, who is reported to have suffered from night-blindness.

III. 4 married III. 3 who was night-blind and they had two apparently normal daughters, IV. 4 and 6. The parents of III. 3 were normal, and her brother, III. 2, was normal, but the descendants of III. 2 were not free from eye defect. III. 2 married a healthy woman, III. 1, and they had a normal daughter, IV. 2, who married a healthy man, IV. 1, and had two daughters, of whom V. 1 had high myopia, V. 3 became completely blind after scarlet fever; V. 1 had a short-sighted daughter.

IV. 4 married twice; by her first husband she had a daughter, V. 4, who had always suffered from a recurrent inflammatory eye affection of an unknown character; by her second husband, IV. 5, she had two daughters, of whom V. 6 had high myopia and perhaps also, according to the statement of the priest, suffered from night-blindness; V. 8 had some eye affection "after catching a cold."

III. 5 married his first cousin, the night-blind III. 6; they had three normal sons, IV. 7, 8 and 9 who all transmitted eye disease and other hereditary defects to their descendants.

IV. 7 married his second cousin, IV. 6, the second normal daughter of III. 3 and 4; they had nine children of whom three died young, V. 11, 12 and 15 had retinitis pigmentosa, V. 13 had high myopia, V. 16 and 17 were normal. V. 11, female, aged 63 (1884), had typical retinitis pigmentosa, her fields of vision were much contracted on all sides and her vision was reduced to hand movements only. V. 12, unmarried, female, aged 53 (1877), saw badly as a child, especially at night; she had marked concentric contraction of fields; vision was reduced to hand movements; she had posterior polar opacities of both

lenses; her fundus showed a large number of white flecks in the central regions and pigmentary deposits in the periphery; the discs were atrophic and the retinal vessels very narrow. V. 15, unmarried, female, aged 51 (1877), had the same affection as V. 12, and her fundus showed the same condition at a less advanced stage; he was able to count fingers at $\frac{3}{4}$ m. V. 13 was the only member of this sibship who had children, she had a normal daughter, VI. 5, and a son, VI. 3, who was myopic and who had bilateral corneal opacities as a result of fascicular keratitis in his youth; VI. 3 had five children all of whom had normal vision, but one of them, VII. 3, had suffered from deafness since his birth.

IV. 8 married IV. 11, who was also probably from a tainted stock, for though her parents, III. 7 and 8, and her brother, IV. 12, had normal vision, the two sons of IV. 12 were night-blind; they had three children, V. 18, 19, 20. V. 18 suffered in his youth from very marked short-sight and night-blindness; at about the age of 40 years he became blind, and was known in the district where he lived as "blind Joseph." V. 19 had the same disease and became also completely blind. V. 20 was born blind.

IV. 9 married a woman whose history was unknown, they had a normal son, V. 21, and a daughter, V. 23, who had nystagmus. V. 21 married a healthy woman and had seven children of whom five died young of phthisis, and one, VI. 7, married and had three children, of whom one, VII. 6, died of phthisis. V. 23 married a healthy man and had four children, VI. 13, 14, 16, 18, none of whom showed any hereditary anomalies; all four married, VI. 13 had three children, of whom two died young of phthisis, VI. 14 had nine children, of whom seven were normal, two had some congenital deformity of the foot. VI. 16 had three children, one of whom was stillborn. VI. 18 had four children, of whom two died young of an unknown cause, VII. 24 had meningitis and became blind in his first year of life, VII. 25 had typical retinitis pigmentosa *sine pigmento*. Consanguinity. Bibl. No. 327.

Fig. 213. *Fisher's Case.* A single case of retinitis pigmentosa associated with deafness. This is a section only of a family history of which records had been accurately kept for many generations; Nettleship published for the first time in 1909 that part of it which showed the occurrences of retinitis pigmentosa and deafness from which this record is taken.

V. 6, aged 45, had well-marked retinitis pigmentosa and was moderately deaf. Of her six siblings, V. 5 died young of phthisis, V. 11 was deaf but had good sight, V. 4, 7, 9 and 13 were normal.

There was a vague history of bad sight in IV. 13, first cousin once removed of V. 6, and in her aunt, III. 12.

The parents of V. 6 were second cousins and the father, IV. 9, had been deaf since early life; there was also a history of deafness from early life in II. 8, IV. 12, V. 11 and 14, the deafness being severe in II. 8 and IV. 12, moderate in the other cases.

VI. 2 had attacks of mania, VI. 6 died in infancy from "some defect in the larynx" and VI. 7, the two children of a deaf father, also died in infancy. Consanguinity. Bibl. No. 263, p. CLIV.

Fig. 214. *Darier's Case.* Retinitis pigmentosa in three brothers of a sibship of five; the two eldest siblings and the parents had normal vision. II. 2, aged 77, a blacksmith, had been night-blind since infancy; he had senile cataract but his fundus could be seen to show changes typical of retinitis pigmentosa; he ceased to work at his forge at the age of 67 on account of his cataract. He had three children who all had normal vision, and two of whom had children with normal vision. II. 4 and 5 were also blacksmiths; they continued to work up to their deaths at the age of 77 and 46 years respectively, they were said to be night-blind but no statement was made as to an examination of the fundus in either case. No consanguinity. Bibl. No. 148.

Fig. 215. *Nettleship's Case.* Retinitis pigmentosa the onset of which appeared to be determined by an attack of scarlet fever in five siblings, two other siblings died of the scarlet fever (one case of which was associated with diphtheria) and three siblings had neither scarlet fever nor retinitis pigmentosa. III. 1 had scarlet fever at the age of 3 years, her sight failed in childhood after the fever, but the exact time of onset was uncertain. When aged 33 (1882), V. was less than $\frac{6}{60}$, fields were full, colour vision normal, sight best in a bright light; there was epithelial disturbance all over the central area, the retina was rather hazy at the periphery but showed no pigmentation; the discs were rather pale and hazy, the arteries too small. Thus she had an atypical retinitis pigmentosa and further she was a sleep walker, eccentric, suffered at times from delusions and was reported to have had Graves' disease at one time. III. 2 had scarlet fever at the age of 8 years and gave the disease to his five younger siblings; his sight began to fail just after the illness and became gradually worse but he was able to take a degree at Cambridge at the age of 22 years; when aged 54 (1904) he could only spell out very large letters with a hand lens and for many years had been unable to read ordinary print; he disliked bright light and was not night-blind; changes found on ophthalmoscopic examination were similar to those found in III. 1 but there were some small collections of pigment on the diseased central area and sclerosis of some choroidal arteries; mental condition was good.

III. 3, aged 30 (1882), had had a progressive failure of vision since the scarlet fever; vision was eccentric and about 16 J.; colour sense good; she also disliked a bright light; the central area in each eye showed a large surface with loss of epithelium and slight pigment collections; the arteries were doubtfully shrunken, the discs pale and hazy. In 1904 she was reported to be almost the same and to have three grown up children with perfect sight.

III. 5 reported that her sight became bad very soon after the fever, at the age of 28 she could still see well enough to be a governess, and she was not blind at the age of 43 (1897), when she died of heart disease and dropsy; latterly her mind had failed; there was no record of an examination of her eyes.

The two next youngest were girls who died from scarlet fever, aged 4 and 3 years respectively, the younger of the two had also diphtheria.

III. 7, when aged 10 months, was ill at the same time as her siblings "either with scarlet fever or measles," and afterwards had "abscess in the ear"; as a child she could see to read fairly well, began + glasses at the age of 14; ten years later she had well-marked nystagmus, sight worse in a bright light, loss of nasal third of each field; she had very typical advanced retinitis pigmentosa and was reported to be nearly blind at the age of 36; she was emotional.

III. 8, 9 and 10 were born after the scarlet fever outbreak and never had the disease, the mental power of III. 8 and 10 was above the average, their sister, III. 9, was extremely hysterical and had more than once been out of her mind; her eyes were normal and all the three had perfect vision at the age of 40—44.

The parents were healthy and unrelated; the mother was the offspring of "distant" cousins. Consanguinity. Bibl. No. 251, pp. 159—61.

Fig. 216. *Reinecke's Case.* Mathilde H., aged 55, II. 2, had always been night-blind; her brother, her mother, and her son were similarly affected. No further information is given. The author quotes this as a case of inherited retinitis pigmentosa; we assume, therefore, that the night-blindness was associated with this condition, and was not of the congenital stationary type without fundus changes. No consanguinity recorded. Bibl. No. 179.

Fig. 217. *Nolte's Case.* This case was placed by Nettleship amongst his reported cases of retinitis pigmentosa *sine pigmento*; three members in a sibship of eight were affected, also their two first cousins in a sibship of four; two maternal great-uncles were reported to have been blind at school age. The condition was associated with epilepsy in three cases, and in one case only was night-blindness noted.

III. 6, aged 21, was of a robust build and well nourished; he looked stupid, stammered, and was mentally very feeble; he had typical epileptic seizures; on ophthalmoscopic examination there was found to be atrophy of the optic nerve, marked narrowing of the retinal arteries, the retina was of a greyish colour, and the pigment epithelium was atrophied, producing a fine granular appearance in the fundus; he had small bilateral anterior polar cataracts. His father reported that diminution of vision was first noticed after a severe illness with brain symptoms and diarrhoea, which kept him in bed for six or seven weeks at the age of three; the condition had progressed from that time. An examination of his eyes in 1886, when he was aged 12, was reported.

III. 7 was healthy until the age of 4, when she developed epilepsy, and a diminution of vision was noticed which progressed to almost complete blindness; no ophthalmoscopic examination was reported. At the age of 14 she was sent to a hospital for epilepsy, and died later in epileptic coma.

III. 10, aged 8 (1904), was healthy, but of rather slow, dull intelligence; he could read and write at the age of six, when first a gradually progressive diminution of vision was noticed; at the age of 14 he was able to count fingers only; the ophthalmoscopic appearances were similar to those of his brother III. 6.

These siblings had four normal sisters aged 27, 24, 15 and 13 respectively, and one normal brother, aged 18.

The father's sister, II. 2, had four children, of whom two sons, aged 19 and 12 years respectively, were normal, one daughter, who died aged 19, had become blind, and a daughter, aged 18, had seen badly since her ninth year and was night-blind, she also had epileptic seizures. No consanguinity. Bibl. No. 191.

Fig. 218. *Neuffer's Case.* (Taken from Nettleship.) Five cases of retinitis pigmentosa in three sibships in a pedigree showing freedom from the disease in the direct line of ancestry for four preceding generations in the case of two sibships, V. 1 and 2 and V. 3 and 4, and for three preceding generations in the third case IV. 1.

V. 1 and 2 were first cousins to V. 3 and 4. IV. 1 was second cousin once removed to the other affected members. Nothing was known of II. 1 and II. 4. No consanguinity recorded. Bibl. Nos. 251, p. 22, 176.

Fig. 219. *Frickenhaus' Case.* (Taken from Nettleship.) Retinitis pigmentosa in a brother and sister, the offspring of healthy first cousins; they have one healthy sister IV. 2, who is married, and has three normal children. Consanguinity. Bibl. Nos. 251, p. 41, 81.

Fig. 220. *E. Schmidt's Case.* II. 1, aged 38, with V. $= \frac{1}{40}$ in each and fields irregularly contracted was seen to have diffuse choroidal atrophy, atrophy of the papilla and narrowed vessels; her father, two siblings, and the child of a normal sister, were said to be night-blind. No further information is given. The author includes the above in his series of observed cases of retinitis pigmentosa. No consanguinity recorded. Bibl. No. 163.

Fig. 221. *Böhm's Case.* Two brothers married two sisters respectively, their cousins. One marriage resulted in two children, of whom the elder, a boy, was epileptic but had normal vision, his brother had retinitis pigmentosa. The other marriage resulted in four children, of whom the eldest, a boy, became blind at the age of 10 from retinitis pigmentosa; his younger brother and two sisters had normal vision. Consanguinity. Bibl. No. 317.

PLATE XX. Fig. 222. *Abelsdorff's Case.* Retinitis pigmentosa in probably four generations. The patient III. 2, aged 24, and her sister, aged 19, presented a typical picture of retinitis pigmentosa; a brother was reported to have good sight. The patient's mother and her grandmother were night-blind from early childhood, the grandmother became blind at the age of 56, the mother was blind at the age of 44. III. 2 had three children, a boy with normal vision, a daughter, aged 6 months, who could not be examined, and a daughter, aged 4 years, was already showing changes in the pigment epithelium in the form of numerous white spots in the periphery of her fundi. No consanguinity recorded. Bibl. No. 229.

Fig. 223. *Ewing's Case.* (Published by Loeb.) Retinitis pigmentosa in four successive generations. I. 1 suffered from night-blindness; her son, II. 2, had well-developed cataract in the right eye, the left eye was aphakic and retinitis pigmentosa was present. Of the children of II. 2, a son III. 2 had marked cupping and pallor of the right disc with retinitis pigmentosa in the peripheral portions of both eyes; a son, III. 3, was troubled a little with night-blindness and some small pigment spots were present in the fundus, vessels were of normal size; three years later the night-blindness had increased, vision was normal in both eyes and characteristic stellate pigmentation was present. III. 4, daughter of II. 2, had always suffered from night-blindness; ophthalmoscopic examination showed one fundus to be normal in every respect, in the other eye a small black spot was present in the upper peripheral portion of the fundus, in the lower portion there was a slight greyish retinal change.

IV. 1, daughter of III. 2, had been night-blind since early childhood; R. V. = L. V. = $\frac{20}{15}$; fields normal; no pigmentation of the retina; three years later there was typical pigmentation of both retinae with moderate contraction of fields. No consanguinity recorded. Bibl. No. 261.

Fig. 224. *Nettleship's Case.* A single case of retinitis pigmentosa in a girl, the offspring of first cousins; her only sibling died of measles aged 2 years. There was no information of the father's family; the mother's family was believed to be free from the disease. Consanguinity. Bibl. No. 251, p. 41.

Fig. 225. *Nettleship's Case.* Retinitis pigmentosa in a brother and sister, II. 2 and 4, who were the offspring of healthy first cousins. It was reported that they both went blind at about the age of 45 of "optic nerve decay"; they each lived to an advanced age. II. 2 married twice and had normal children by each wife; a daughter by the second marriage, III. 4, was examined by the author; a son by the first marriage, III. 2, married his first cousin and had four children, of whom the eldest, a girl, had contracted fields of vision and suffered from night-blindness. Consanguinity. Bibl. No. 251, p. 29.

Fig. 226. *Kaupp's Case.* Retinitis pigmentosa in two brothers; the mother, the maternal grandmother and other relatives were reported not to have seen well. III. 1, aged 50, had had near vision as a child and had never learned to read or write; he was addicted to drink; for 8 years he had noticed a gradual diminution in his sight, especially in the evening; he was examined and found to have typical retinitis pigmentosa with greatly contracted fields, narrowed retinal vessels, whitish papilla, and pigmentation at the periphery of the fundus; he was treated with strychnine with an improvement. The author describes the appearance of his fundi at three examinations covering a period of years. III. 3, aged 49, had suffered from night-blindness as a child but had seen well in the day until two years before the examination, since then there had been a rapid diminution of vision; his fundus was typical of retinitis pigmentosa but in addition there were some greyish white flecks described in the choroid. V. R. = $\frac{1}{6}$, V. L. = $\frac{1}{20}$; fields showed concentric contraction. The two sisters of III. 1 and 3, and the three children of III. 3 had good sight. No consanguinity. Bibl. No. 162.

Fig. 227. *Nettleship's Case.* Retinitis pigmentosa in a father and one of his six children. II. 5 had no noticeable night-blindness until the age of about 32 when his fields of vision were full and V. = $\frac{5}{5}$, but the retinal arteries were slightly narrowed and the discs were palish and blurred; no pigment changes could be found; two years later the arteries were smaller and V. = $\frac{5}{12}$, the pigment epithelium was stippled and the choroidal vessels sclerosed but there was still no visible pigmentation of the retina. His father, I. 1, died aged 57, of enteric fever, he had suffered from night-blindness for many years but could see fairly well by day up to the time of his death. His mother, I. 2, suffered badly from "dead fingers." One of the patient's sisters suffered from very severe chilblains. No defective vision or other degeneracies were known in other members of the family. No consanguinity. Bibl. No. 251, p. 347.

Fig. 228. *Cabannes' Case.* An atypical case of retinitis pigmentosa associated with other defects of vision. II. 1, Charles N., aged 28, had excellent vision up to the age of 12 when he first noticed a diminution in vision; this progressed, he was unable to read or write after the age of 16 and was unable to recognise people after the age of 25; he was unable to go about alone at night; he was found to have nystagmus, horizontal and rotary, and had central scotomata; his pupils reacted sluggishly; tension was normal; the retinal veins were a little increased in volume, the arteries were scarcely appreciable; the choroid appeared to be a little congested and there were multiple pigmentary deposits at the periphery; the macula region was normal; he complained of frontal headaches and had myopia of 3—4 D.

II. 2, aged 21, had myopia of 8 D.; he complained of headaches and a diminution of vision which began at the age of 13—15; V. = $\frac{1}{6}$ in 1903 and V. = $\frac{1}{10}$ in 1906; pupils reacted briskly; he was not night-blind; the retinal vessels were diminished, the veins perhaps a little tortuous; the papilla was pale and

showed some neuro-papillitis with slight atrophy; there was no peripheral pigmentation and no history of syphilis or alchoholism.

II. 3, aged 18, was emmetropic in the right eye with V. $\frac{1}{6}$, he was myopic, 3 - 4 D. in the left eye with V. = $\frac{1}{10}$; he had noticed a diminution of vision from the age of 5—6 years; no scotomata were present and no night-blindness; the papillae were pale and vessels rather narrower than normal. The author suggested that II. 1 was a case of retinitis pigmentosa, II. 2 and 3 approached nearer to hereditary optic neuritis. No consanguinity recorded. Bibl. No. 240.

Fig. 229. *Wilbrand and Saenger's Case.* Retinitis pigmentosa in four siblings. II. 1, a girl aged 13, had typical retinitis pigmentosa, she had further some defects of the central nervous system shown by exaggerated reflexes and a marked lowering of sensibility to pain. II. 2, a boy aged 12, had typical retinitis pigmentosa. II. 3, a boy aged 10, had typical retinitis pigmentosa. II. 4, a girl aged 7, had typical retinitis pigmentosa and further she had exaggerated reflexes and reduced sensibility to pain in parts of her body. No consanguinity recorded. Bibl. No. 264.

Fig. 230. *Trousseau's Case.* Retinitis pigmentosa in II. 1, the child of first cousins. The father, I. 3, had retinitis pigmentosa and his brother, I. 2, was completely blind. The mother, I. 4, had amblyopia and strabismus of the left eye. Consanguinity. Bibl. No. 171.

Fig. 231. *Ayres' Case.* Third, fourth and fifth children with defective sight in a sibship of eight; only one case examined. II. 2, female aged 26, had noticed a gradual impairment of vision for some years, she was now unable to see to get about and was found to have very contracted fields and marked retinitis pigmentosa, the pigment extending beyond the equator of the eye. The parents were cousins, the mother had good eyes but the father's sight was very defective. Consanguinity. Bibl. No. 138.

Fig. 232. *Magnus's Case.* The three eldest members in a sibship of four became completely blind from retinitis pigmentosa at about the age of 8 years; the youngest, a boy aged 16, suffered from very defective vision but was not completely blind. No information is given of the parents. No consanguinity recorded. Bibl. No. 142.

Fig. 233. *Kerschbaumer's Case.* Retinitis pigmentosa in a blind peasant, I. 3, his sister, I. 2, and his daughter, II. 1. I. 3 had numerous other siblings and children who had normal vision. No consanguinity recorded. Bibl. No. 141.

Fig. 234. *Pufahl's Case.* Retinitis pigmentosa in two members of a sibship of four, the offspring of parents who were uncle and niece. II. 2, seen, aged 30, was night-blind and suffered from retinitis pigmentosa and deafness; he had seen badly for several years. His sister, II. 1, had died at the age of 34, she also had been night-blind and was affected in the same way as her brother; the disease had appeared in both cases in the same year of life. Consanguinity. Bibl. No. 95.

Fig. 235. *Derigs and E. Schmidt's Case.* Atypical retinitis pigmentosa with very marked atrophic changes in the choroid in two brothers. II. 1 was examined by Derigs when aged 16; R. V. = L. V. = $\frac{2}{20}$ with − 0·3 D.; fields were much contracted and very marked atrophic changes were present in the choroid and in the epithelial layer of the retina, in the macular region were brownish red pigment flecks; there was only a trace of pigment in the periphery typical of retinitis pigmentosa; the patient was rather backward in his development but no defects were found in other organs; the diminution of vision was first noticed after scarlet fever at the age of 6. His brother, II. 2, was examined some years later by Schmidt at the age of 14 when R. V. = $\frac{20}{30}$, L. V. = $\frac{20}{20}$, and he was diagnosed as chorio-retinitis pigmentosa with scanty pigmentation of the periphery of the retina. Parents were healthy, and six siblings had normal eyes. No consanguinity. Bibl. Nos. 112, 163.

Fig. 236. *Derigs' Case.* Unilateral retinitis pigmentosa in a woman aged 46. II. 1, Frau Merz, had R. V. = $\frac{110}{100}$, field of vision for R. markedly contracted; she had a posterior polar cataract, a marked atrophy of the papilla and a profuse pigmentation of the equatorial zone; her diminution of vision had progressed since her youth. Her brother is described as having the same disease but it is not stated whether in his case the trouble is unilateral or bilateral. No consanguinity. Bibl. No. 112.

Fig. 237. *Grossmann's Case.* Retinitis pigmentosa in II. 2 who had seen badly since the age of 15, he was night-blind but was able to carry on his work in the day, V. = $\frac{6}{36}$; he also had six toes on each foot and six fingers on the right hand, left hand normal. A brother aged 20 had six fingers on each hand and six toes on each foot, he also had bad sight; the parents and other siblings were normal. No consanguinity. Bibl. No. 248.

Fig. 238. *Laycock's Case.* II. 1, a healthy girl aged 17, had had difficulty in distinguishing objects as soon as twilight came on since the age of 12; she could see perfectly well during the day; she had been somewhat deaf in childhood but this had gradually improved. II. 2, a boy aged 15, also suffered from night-blindness and rather defective hearing. II. 3, aged 13, a nervous and delicate looking boy, suffered from night-blindness and was much more seriously deaf than his elder siblings; throat was normal and beyond a free excretion of cerumen there was no discernible defect in the ears. II. 4, aged 10, was extremely deaf and had suffered from night-blindness for several years. II. 5, aged 7, was also extremely

deaf and had suffered from night-blindness for two or three years. The other five siblings had normal sight and hearing. It is unfortunate that no ophthalmoscopic examination was made in these cases. The history is only tentatively included in this section. No consanguinity recorded. Bibl. No. 56.

Fig. 239. *Wilbrand and Saenger's Case.* Of three children of blood-related parents II. 1, a son, had typical retinitis pigmentosa; II. 2, a daughter, had night-blindness with concentric contraction of fields, atrophy of the papilla, very narrow retinal vessels and white flecks in the periphery of the retina, no pigmentary deposits were to be seen. Another son, II. 3, was deaf. It is not stated whether there were any normal members of the family. Consanguinity. Bibl. No. 264.

Fig. 240. *La Gleyze's Case.* (Published by Nettleship.) Retinitis pigmentosa in the daughter of healthy first cousins and also in her first cousin. Consanguinity. Bibl. No. 251, p. 28.

Fig. 241. *Rodsewitsch's Case.* This case is of interest as being an illustration of retinitis pigmentosa *sine pigmento* seen at an advanced stage with no development of pigment having taken place. II. 1 had been night-blind since childhood; R. V. $= \frac{5}{200}$, L. V. $= \frac{2}{200}$; fields were contracted to fixation point; the papillae were pale, the vessels greatly narrowed, and nowhere were there any deposits of pigment to be seen. His mother was completely blind, and a brother and sister had weak sight. No consanguinity recorded. Bibl. No. 206.

Fig. 242. *Derigs' Case.* Retinitis pigmentosa in four siblings. II. 1, aged 36, Auguste Schmidt, had R. V. = L. V. $= \frac{2}{70}$, she had considerable contraction of her fields of vision, also posterior polar cataracts; the pigmentation was very marked and extended to the region of the papilla. II. 2, aged 32, had myopia of $\frac{1}{30}$ in the R. and hypermetropic astigmatism in the L. eye; his fields of vision were contracted but not very markedly, above and below to 30°, inner and outer to 40°; no ophthalmoscopic changes were present but he complained of night-blindness and was possibly a case of retinitis pigmentosa *sine pigmento*; he was reported to have a brother with the same difficulties. II. 3, Maria Schmidt, aged 24, had R. V. = L. V. $= \frac{2}{40}$; her fields were contracted R. above to 35°, below to 30°, temporal to 50°, nasal to 25° with similar changes in the L.; the pigmentation was less markedly developed than in her sister II. 1; she had posterior polar cataracts. Consanguinity. Bibl. No. 112.

Fig. 243. *Carruthers' Case.* III. 2, aged 19, reported that he had been night-blind since early childhood; his fields of vision were slightly contracted, R. V. = L. V. $= \frac{6}{12}$; no ring scotoma was present; the left fundus showed very little abnormality except retinal atrophy; in the right fundus the surface of the disc was raised about 1·5 D. above the adjacent retina, the macular region was oedematous and glistening striae could be seen especially marked between the macula and the disc; there was retinal atrophy and in one spot towards the nasal side of the fundus three or four faint but definite pigmented corpuscular figures were seen in proximity to the vessels. Urine was free from sugar and albumen; blood pressure 140; Wassermann test negative. The case was discussed and was decided to be retinitis pigmentosa with some acute process overlying the atrophic process; one observer noted fine floating opacities in the vitreous. The patient's sister, aged 24, and his brother, aged 17, also suffered from night-blindness and, from the description given by III. 2, appeared to suffer from ordinary retinitis pigmentosa. The parents and grandparents were normal. No consanguinity. Bibl. No. 308.

Fig. 244. *Ayres' Case.* III. 1, a carriage painter, aged 54 years, had suffered from night-blindness for 20 years; his fields were much contracted and pigmentation of the retina was well marked; he had an attack of acute glaucoma in the right eye and when seen the pupil was moderately dilated, T. = + 2 and R. V. = perception of light only; L. V. $= \frac{6}{64}$. III. 2, aged 47, also had retinitis pigmentosa, the pigment being sparsely scattered over the retina; she had no limitation of fields; R. V. $= \frac{15}{30}$, L. V. $= \frac{15}{25}$. III. 3 had defective eyes from an unknown cause. The maternal grandmother, I. 2, was night-blind. No consanguinity recorded. Bibl. No. 138.

Fig. 245. *Bellarminoff's Case.* Retinitis pigmentosa and glaucoma in a peasant, Iwan Nikiforoff, aged 40. III. 1 complained of pain in both eyes with marked diminution of vision; he began to see badly with the right eye a year previously and his left eye had been failing for about six months; earlier he had suffered from night-blindness and had seen coloured rings round the lamp; he had seen well and had not night-blindness in his youth. He was found to have R. T. = + 2, L. T. = + 1, marked dilatation of the anterior ciliary veins, anterior chambers small; pupils showed a medium dilatation, greater on the right side, with a sluggish reaction; the vision of the right eye was reduced to perception of light and for the left eye was greatly diminished, V. $= \frac{2}{40}$, and the field also was greatly contracted; media were clear except for a small opacity of the L. lens; the papilla showed a deep glaucomatous excavation, and towards the periphery of the fundus were seen typical deposits of retinitis pigmentosa.

The sister of the patient died aged 55 completely blind, also a maternal cousin was blind, no further details are given of these relatives. The father, II. 2, died aged 80 with his sight, and the mother could see at the time of her death when she was aged 70; she had suffered from night-blindness during pregnancy. The grandparents died with full vision. No consanguinity. Bibl. No. 172.

Fig. 246. *Blessig's Case.* Three cases of retinitis pigmentosa and two cases of glaucoma simplex in a

sibship of nine. III. 1, Sophie P., at the age of 62 had R. glaucoma simplex for which iridectomy was performed, at the age of 77 she had L. glaucoma simplex for which again iridectomy was performed. III. 2, Carl, was seen at the age of 48 to have retinitis pigmentosa with posterior cortical cataracts, papillae pale, R. V. $= \frac{2}{7} - \frac{2}{5}$, L. V. $= \frac{2}{10} - \frac{2}{7}$, fields contracted almost to fixation point; he had been night-blind since childhood and was deaf; he was seen at subsequent intervals and became almost blind; he was married and had normal children. III. 4, Emma, had normal vision and had normal children. III. 6, Julie, and her children had healthy eyes. III. 8, Emilie, was deaf, she had bilateral glaucoma simplex and was unmarried. III. 9, Robert, was night-blind from his youth and deaf; he was seen, aged 53, with typical retinitis pigmentosa, his fields were contracted to fixation point and anterior polar cataracts were noted; he married and had normal children. Fanny, III. 11, and Bernhart, III. 12, were unmarried and normal. Anna, III. 13, was night-blind and deaf; she was seen at the age of 46 to have advanced retinitis pigmentosa with her visual fields contracted to fixation point; she was unmarried. The parents, II. 2 and 3, were normal and unrelated. The paternal grandfather, I. 1, was blind in his old age. No consanguinity. Bibl. No. 214.

Fig. 247. *Bradburne's Case.* Five cases of retinitis pigmentosa in a sibship of nine, associated with glaucoma in three of the cases. I. 1 died aged 50; I. 2 died aged 80 with good sight. Of their eight children, seven saw well and one, II. 3, had been night-blind since her childhood, the condition following a severe attack of scarlet fever; she died aged 69, the mother of III. 1—9. III. 1 died aged 60 with good sight. III. 2 died aged 4 years from diphtheria. III. 3, aged 61, twin to III. 2, had well-marked retinitis pigmentosa, her sight had been very defective for the last twenty years; the cornea was quite clear and had a diameter of 11 mm.; anterior chamber was shallow; there was a small opacity in the centre of the lens; details of the fundus could not be seen owing to a slow nystagmus; T. was sub-normal; no vitreous opacities were seen; she had a history of severe attacks of pain in the left eye.

III. 4, aged 58, had well-marked retinitis pigmentosa; V. in each eye = finger counting at 3 m.; corneal diameter 12 mm.; anterior chamber shallow; T. sub-normal; there was marked degeneration of vitreous in which were large freely floating opacities; the R. lens showed a posterior capsular opacity; she had never had prodromata of glaucoma.

III. 5, aged 54, had no retinal changes and no prodromata of glaucoma; corneal diameter 12 mm.; anterior chamber shallow; pupils partially dilated; there was a considerable haze in the lens and some opacity at its centre; T. slightly sub-normal; no evidence of opacities in the vitreous; the R. disc had a deep physiological cupping equal to – 2 D. with steep sides, the L. disc had a deep funnel-shaped excavation equal to – 2·5 D.

III. 6 died aged 3. III. 7, aged 51, had had defective vision for a long time which was becoming worse; she had had attacks of pain five weeks previously in both eyes; corneal diameter 12 mm.; posterior polar opacities with general haze of lens obscured the details of the fundus; T. = + 1; pupils nearly fully dilated. Operation was performed for glaucoma.

III. 8, aged 50, had well-marked retinitis pigmentosa; she also had acute glaucoma in the L. eye and was entirely blind in the R_4 eye as a result of a similar attack some years earlier. III. 9 had well-marked retinitis pigmentosa; corneal diameter 11·5 mm.; anterior chamber shallow; media clear; R. V. $= \frac{3}{60}$, L. V. = hand movements; T. high. She had an attack of severe pain in the L. eye and operation for glaucoma was performed. No consanguinity was recorded. Bibl. No. 307.

Fig. 248. *Wider's Case.* Retinitis pigmentosa in six siblings with normal parents. II. 1 seen, aged 53, had suffered since his youth, his vision was reduced to hand movements and his fields were very small, he was hypermetropic and his fundi showed typical changes. II. 3, aged 48, had symptoms of retinitis pigmentosa since his youth and also had absolute glaucoma. There were four other siblings, all of whom were said to have retinitis pigmentosa, two of them being completely blind. II. 3 had five children with normal vision. No consanguinity recorded. Bibl. No. 137.

Fig. 249. *Heinersdorff's Case.* Retinitis pigmentosa associated with glaucoma. II. 1, aged 22, had suffered since his earliest youth from night-blindness and "short sight"; four or five months before examination he noticed cloudiness of his vision occasionally, and this condition had been constant for about a month; he also saw rainbows, and had pain in his eyes and headache. Three years previously he had been given spectacles—3·0 D. sph. He now had bilateral myopia of 6 D. and with correction R. V. = 0·45, L. V. = excentric hand movements only, not improved by glasses; his fields were greatly contracted; the papillae were greyish white, atrophic and excavated; the retinal vessels were extremely narrowed and scanty, and there was a glaucomatous halo surrounding the papillae. The author gives a beautiful coloured plate of the fundus, showing all the features of a severe retinitis pigmentosa combined with glaucoma. His parents were living and were unrelated; they had good vision. A sister, aged 16, had myopia of 12 D. and a not very advanced retinitis pigmentosa; she had not suffered from night-blindness. Three other living siblings were normal. The grandparents were unrelated. No consanguinity. Bibl. No. 196.

Fig. 250. *Ayres' Case.* II. 1, aged 37 years, had noticed a defect in his vision commencing at the age of 18; he was unable to go out alone at night, and also had some difficulty in daylight. On examination

it was found that R. V. = L. V. = $\frac{5}{30}$; fields were much contracted; retinal vessels were narrowed; papillae were rather pale and the retinae were moderately pigmented; he was under observation for several years, and the disease progressed slowly; he was also partially deaf. II. 2, aged 35 years, had eyes similarly affected, the onset in her case occurred at about the age of 18; the condition was more severe in her case than in that of her brother and was further complicated by glaucoma in both eyes; she was quite deaf. II. 3, aged 33, had had defective vision since "boyhood," but the condition had remained stationary for several years; he was unable to walk alone at night and had difficulty in daylight; his fields were contracted; R. V. = $\frac{5}{70}$, L. V. = shadows of hand downwards and inwards; he had attacks of acute glaucoma in both eyes for which a double iridectomy was performed with no improvement to the left eye. II. 4 died, aged 16 years, having developed so far no defect in her vision. II. 5, aged 26 years, had normal vision. The parents were living and in good health; the father had normal eyes and the mother with a correction for 6 D. of myopia could see well. No consanguinity. Bibl. No. 138.

PLATE XXI. Fig. 251. *Goldzieher's Case.* II. 1, seen at the age of 30, had always had weak eyes, but had been able up to a year before to earn her living as a sempstress, since then she had had headaches and her sight had become so dim that she was unable to go about alone. She was a strongly built person but was deaf; R. V. = 0, on the left side she was still able to count fingers in certain positions at a distance of a metre; field of vision was very small; the pupil was irregularly dilated almost to the maximum degree; there were cataracts in the posterior layers of both lenses and also bilateral very fine opacities in the vitreous; there was a deep glaucomatous excavation of the papilla; the retina showed in places atrophy of the pigment epithelium and wholly typical star shaped pigmentary deposits at the periphery; tension was raised in both eyes and the condition was diagnosed as bilateral glaucoma with typical pigmentary degeneration of the retina. Her sister, an intelligent midwife, stated that her parents were healthy and unrelated and that of their eight children six (four brothers and two sisters) suffered from night-blindness, and in some cases sight had become so bad as to interfere with their work. One of the brothers was examined and was found to be deaf and to have typical retinitis pigmentosa. No consanguinity. Bibl. No. 193.

Fig. 252. *Pagenstecher's Case.* II. 1, a girl aged 20, was deaf and night-blind in her right eye only; her right field of vision showed a marked concentric contraction, the papilla was white and there was diffuse pigmentary disturbance and atrophy of the choroid; pigmentary deposits in the retina were almost completely absent. The mother, I. 2, had three sisters who suffered also from deafness and night-blindness. The author believed that the condition in II. 1 was primarily a choroidal affection and the name of retinitis pigmentosa for it had been ill-chosen. We include it under the title of chorio-retinitis. No consanguinity recorded. Bibl. No. 44.

Fig. 253. *Bullar's Case.* "Deficiency of the choroid" in a boy aged 16 (1892). II. 1 had always had bad sight; refraction myopic, 5·5 D.; R. V. with correction = $\frac{6}{18}$, L. V. = $\frac{6}{12}$; seen again in 1898 when his myopia was 7 D.; fields consisted of a small central area of less than 10°, and of a peripheral part about 10° wide lying between the 50° and 60° circles; greater part of fundus was greyish-white with scattered pigment spots, red reflex being limited to a small patch at macula region and round the disc; some isolated choroidal vessels were seen at the periphery where there was a faint red tinge. Two sisters and two brothers had good sight, two brothers had bad sight. No mention of night-blindness in the patient or his brothers. No consanguinity. Bibl. Nos. 199, 251, p. 376.

Fig. 254. *Goldberg's Case.* The author describes this as a case of choroideremia in a brother and sister aged 20 and 12 years respectively; he describes a complete absence of choroid at the periphery, so that the membrane was represented by an irregular ring varying in breadth; in the boy there was also an absence of choroid surrounding the disc; he had a nuclear opacity of both lenses. Such eminent authorities as de Schweinitz, Zentmayer and Usher are doubtful of the correct classification of this case. (See Bibl. No. 301.) No further information is given. No consanguinity. Bibl. No. 290.

Fig. 255. *Alexander's Case.* Choroideremia in two brothers, the younger of whom was aged 31 years at the time of examination; he had been night-blind as long as he could remember, and complained of contracted fields of vision and of a ring scotoma; the defects of vision in both cases were very slowly progressive, but the central vision of II. 2 was, with a slight correction for myopia, still quite good at the time of examination. The fundi were quite white except in the macular regions and in spots at the periphery; the discs showed no appreciable amount of atrophy, the retinal arteries were slightly narrowed in II. 2 and more markedly so in his elder brother; lines of pigment, anterior to the retinal vessels, were described stretching across the fundi and producing a cobweb appearance. The elder brother had a posterior capsular cataract; varying amounts of deafness were present in the family. Nine siblings were all very well developed and healthy, the mother had a brother and a cousin who complained of bad sight especially in a dim light, and a nephew with weak sight. No consanguinity. Bibl. No. 265.

Fig. 256. *Dor's Case.* Chorio-retinitis affecting four siblings. The disease in each case was first noticed at about the age of 30 and was then characterised by night-blindness with spidery pigmentary lesions; then followed the appearance of round choroidal plaques scattered over the fundus; later white fibrous lines were to be seen in the retina; adhesions between the iris and lens next occurred, and lastly, cataract,

and almost complete blindness towards 50 years of age. The condition was not modified by treatment with mercury or salicylate and the patients were in other respects normally constituted, with no history of syphilis or tubercle in them or their parents. III. 2, aged 47, was almost blind and had two children aged 18 and 10 years (1910). III. 3, aged 45, had night-blindness and chorio-retinitis. III. 5, aged 43, was affected and had two living children aged 14 and 7½ years respectively. III. 6 died, aged 24. III. 8, aged 38, was normal and had a child aged 15. III. 9, aged 36, was normal. III. 11, aged 33, was affected and had two stillborn children. III. 12, aged 26, had not yet developed the disease. There is a history of sudden death and heart disease in former generations; thus I. 2 died suddenly (age unknown), also I. 11, aged 30; II. 1, 2, 3, 4 and 6 all died suddenly, II. 1 at age of 40, II. 2, aged 70, II. 3, aged 50, II. 4, aged 73, and II. 6 at the age of 45. The family attributed the trouble in gen. III. to dampness of the house, the members who did not develop the disease had lived elsewhere. No consanguinity. Bibl. No. 267.

Fig. 257. *Pöllot's Case.* Atypical chorio-retinitis and retinitis pigmentosa in the same pedigree. III. 2, Walter H., a student, aged 18, was night-blind and for a long time had been aware of blanks in his fields of vision and of dimness of vision; he was bodily and mentally healthy and had previously been diagnosed as having retinitis pigmentosa. On examination the chief features of the ophthalmoscopic picture consisted in a diffuse atrophy of the pigment epithelium, diffuse sclerosis of the choroidal vessels, and pigmentation in the periphery of the retina similar to that of retinitis pigmentosa; the papilla was of a greyish red colour, the retinal vessels narrower than normal; the choroidal vessels were seen to be of a yellowish colour indicating a high degree of sclerosis; in the macula regions were irregular reddish flecks and towards the periphery were many yellowish white patches; contraction of fields and the presence of scotomata were demonstrated: R. V. with $-2{\cdot}5$ D. $=\frac{5}{10}$, L. V. with $-3{\cdot}0$ D. $=\frac{5}{10}$.

It was reported that his elder brother had the same affection and had been relieved from military service on account of his eyes. A younger brother died aged 10 months.

The father of the sibship, his six siblings and his parents all had normal vision.

The mother, Frau Rosa H., II. 3, aged 46, had always seen badly and particularly so in the evening; R. V. = L. V. with $+3{\cdot}5$ D. cyl. $+0{\cdot}75$ D. axis h. $=\frac{5}{7{\cdot}5}$; fields were normal, no scotomata were present; the papilla was waxy and of a greyish red colour, the retinal vessels narrower than normal; the fundi at the periphery showed fine deposits of pigment typical of retinitis pigmentosa.

II. 4, the twin sister of II. 3 and aunt to the sibship III. 1–3, had been examined by Leber some years previously who reported that her fields were normal in daylight, she was not noticeably night-blind, V. $=\frac{6}{15}-\frac{6}{10}$, and deposits of pigment at the periphery of her fundi were typical of retinitis pigmentosa.

These twin sisters had three normal half siblings and nine normal half nieces and nephews as a result of the second marriage of their mother who had normal eyes but died aged 53 of "consumption." Their father, I. 4, died aged 46, of "consumption and pleurisy"; he had always seen very badly and was almost blind at the time of his death. Their uncle, I. 3, had to give up his work at an early date on account of his eyes and had very weak sight to the end of his life.

II. 4 married II. 5, who was short-sighted but otherwise normal, his parents and his brother also had normal eyes. They had four children, of whom one son died aged 10 months; a son, aged 11, had meningitis at the age of 6 months and was backward bodily and mentally; William W., aged 22, III. 5, had always suffered from night-blindness, he had been examined by Leber at the age of 8 years who found V. $=\frac{6}{20}-\frac{6}{15}$, fields slightly contracted, severe night-blindness, a number of large confluent patches of atrophy of the pigment epithelium in the neighbourhood of the disc with a marked development of pigmentation in the periphery; he was diagnosed as atypical retinitis pigmentosa. When examined 14 years later the condition was similar to that of his cousin, III. 2, and he was diagnosed as atypical chorio-retinitis pigmentosa with marked night-blindness, contraction of fields and ring scotomata. The eldest son, Otto W., aged 25, was night-blind, his fields had normal boundaries but small scotomata were present; the papilla was a good red colour, the retinal vessels of normal calibre, the macula region was of a dark brownish black colour and there were no very definite changes in the fundus.

III. 5 appears to have been delicate and to require a good deal of nursing as a child but otherwise there is no mention of other physical disabilities in this family. No consanguinity. Bibl. No. 277.

Fig. 258. *Oguchi's Case.* Night-blindness in five siblings, only one of whom was examined, a young man who possibly was a case of choroideremia. He, III. 2, was first noticed to be night-blind at the age of 6; his daylight vision was normal, colour sense was normal; fields in a bright light were normal, in a dim light were markedly contracted; light sense was defective; ophthalmoscopic examination showed the papilla and retinal vessels to be normal, there was a diffuse uniform greyish white coloration of the fundus in the equatorial and peripheral regions; the retinal vessels stood out in relief very prominently against the pale background and there was a marked white reflex along the course of the vessels. The choroidal vessels could only be seen in the periphery. In the right fundus, in the upper temporal periphery there was an elliptic patch almost the size of the disc, of a dark brown colour surrounded by a whitish grey reflex, lying between two arterial branches. There were numerous deposits of pigment to be seen. The patient was healthy with no history of syphilis; his eldest sister, aged 24, suffered from night-blindness as also did

his younger brothers, aged 17 and 12 respectively, and a sister, aged 7; it was not known whether his youngest sister, aged 4, was also affected. There was apparently another sibling whose condition is not mentioned.

The parents were first cousins, the two grandfathers being brothers. There was no knowledge of syphilis in the parents. It is a misfortune that there was no ophthalmoscopic examination of the night-blind siblings. Consanguinity. Bibl. No. 283.

Fig. 259. *Oguchi's Case.* Night-blindness in four brothers with probably choroideremia in one of them, the only case unfortunately which could be examined; several sisters had normal vision. The patient, Nagajama, aged 20, believed that his night-blindness, which was severe, had remained unchanged since childhood. On examination it was found V. R. = V. L. = $\frac{6}{12}$; fields were contracted to 50°; media were clear; papilla and retinal vessels were normal, the latter appearing dark and distinct to the finest twigs, in contrast to the greyish white fundus which was almost uniform from the papilla to the equator except for clearly defined patches here and there which showed the normal fundus colour; these patches were usually at the bifurcation of vessels and might be of the size of the disc; at the outermost periphery the fundus had its normal colour but not uniformly so. No consanguinity. Bibl. No. 283.

Fig. 260. *Koenig's Case.* (Taken from Nettleship.) Choroideremia in two brothers. III. 1, aged 20, asked for exemption from military service on account of night-blindness from which he had suffered since his earliest recollections; he could read small print accurately, but not easily, in a rather dim light; colour vision was good; fields a little contracted in full light, became extremely contracted on lowering the light; discs were normal, retinal vessels normal; over nearly the whole fundus in each eye the reflex was quite white from absence of choroidal tissue, but the yellow spot region, where the chorio-capillaris was still present, was of a more or less normal red colour; a few large choroidal vessels could be seen and a few pigment patches were present behind the retinal vessels at the periphery. A younger brother was similarly affected and his fundi presented almost exactly the same appearance except that in his case pigmentary deposits were rather more numerous. III. 1 was the eldest of a sibship of nine of whom seven were normal. Parents and grandparents saw quite well. No consanguinity recorded. Bibl. Nos. 86, 251, p. 375.

Fig. 261. *Oguchi's Case.* III. 3, seen aged 21, was the son of first cousins whose fathers were brothers, he had been night-blind since childhood, had normal vision in good daylight, and normal colour sense; his fields, in a bright light normal, became contracted in a dim light; his papilla was normal but was surrounded by a thick black ring; the fundus was of a whitish grey colour and the retinal vessels appeared dark and distinct on the pale background so that the smallest twig could be seen; the macula region was dark. The author gives a coloured plate of the fundus which is suggestive of choroideremia.

The patient's four brothers and one sister had normal vision, but a son of his father's elder brother, aged 25, was said to suffer from night-blindness. Consanguinity. Bibl. No. 283.

Fig. 262. *Zorn's Case.* This is an extremely interesting pedigree showing choroideremia, ? gyrate atrophy of the choroid and retina and atypical retinitis pigmentosa in three generations. I. 1 was not examined, she was reported to have suffered with her eyes since her youth and to see especially badly in a dim light, she could not find her way about in the dark. She had three children, of whom II. 2, Otto A., aged 39, was absolutely helpless in the dark and was dazzled on going from the dark into the light, he had been night-blind since childhood but thought his eyes were getting worse; R. V. with −2·5 D. = $\frac{5}{8}$ nearly, L. V. with −1·5 D. = $\frac{5}{7}$; fields were contracted to 20° and the whole of the L. upper temporal quadrant was missing; media were clear, papillae normal and retinal vessels were normal; the fundus was almost completely white, with some pigment deposits and choroidal vessels showing in places, at the yellow spot was a brownish black pigment fleck about half the size of the papilla; a coloured plate is given of the left fundus. II. 3, aged 33, may perhaps be described as a case of chorio-retinitis pigmentosa, she had some difficulty in seeing at night; R. V. = L. V. = $\frac{5}{5}$; fields were contracted to 10°—20°; media clear; papillae and retinal vessels normal; in the periphery of the fundus were atrophied patches of a yellowish white colour and pigment deposits. II. 5, the third child of I. 1, was normal.

II. 2 had seven children, of whom six were normal and one, Gertrude H., aged 13, had been night-blind since childhood; R. V. = $\frac{5}{6}$, L. V. = $\frac{5}{7}$; some hm.; fields contracted 40°—70°; the fundus was absolutely normal; possibly a case of retinitis pigmentosa *sine pigmento.* II. 3 had one child, a boy, aged 9, Walter H., who had been noticed to be night-blind for several years; R. V. = L. V. = $\frac{5}{7}$; fields contracted to 10°—20°; papillae and retinal vessels normal; in places the fundus is said to be completely white and pigmentation of the periphery is described but the condition is not typical of the condition described by Fuchs as gyrate atrophy of the choroid and retina. II. 5 had four children, of whom three were normal, and one, III. 8, Franz Z., aged 16, was night-blind; R. V. with −1·0 cyl. axis 0° = $\frac{5}{5}$, L. V. with +1·0 cyl. axis 90° = $\frac{5}{5}$; fields were contracted to 10°—20°; media were clear, papillae and retinal vessels normal; the whole fundus showed a diffuse atrophy of the pigment epithelium except at the macula region, and pigmentary deposits are described in the anterior layers of the retina. All members of the family were healthy and free from defect except in their eyes. No consanguinity recorded. Bibl. No. 323.

Fig. 263. *Tatham Thompson's Case.* Choroideremia in a youth, aged 18 (1898); a great-uncle, I. 3,

suffered badly from night-blindness and was said to have had similar eyes to the patient. III. 1, from his early infancy, had been noticed to hold objects close to his eyes, and to peer round at things as if he only saw straight in front; he had my. 3 D.; corrected vision for each eye $-\frac{6}{9}$; fields of vision were contracted to less than 10°; the fundus everywhere was dazzling white with retinal vessels coursing over, except at the macular region where chorio-capillaris were present and produced a red reflex; a single spot of pigment was visible; the retinal vessels were normal or slightly undersized; O. D. was pale pink in contrast with surrounding white; the condition was unchanged when seen again in 1904. Parents had good vision, they had eleven children of whom three died in infancy; no history of syphilis or tubercle. The author gives a pencil sketch of the fundus. No consanguinity. Bibl. Nos. 208, 251, p. 376.

Fig. 264. *Jackson's Case.* II. 1, aged 35, had always had defective vision and it had slowly become worse; V. $= \frac{4}{40}$; she was not night-blind; the retinal vessels were rather small; the whole central portion of the fundus showed choroidal atrophy with disturbance of pigment epithelium, the condition shaded gradually from complete atrophy at the centre to practically normal fundus at the periphery; there were relatively large pigment patches near the centre and minute brown specks were visible throughout the fundus; a coloured plate is given of the right fundus. II. 4, the youngest but one of the sibship, was examined by Dr Gratiot who reported that her eyes were like her sister's but that in her case the condition was more severe. Two brothers died young, one of them of diphtheria in infancy and the other at the age of 7 years from pulmonary affection, four sisters had good sight. The parents were third cousins. Consanguinity. Bibl. No. 233.

Fig. 265. *Wernicke's Case.* Gyrate atrophy of choroid and retina in a youth, aged 22, the youngest of a sibship of 10; a sister eight years older than he, probably was a similar case, for she was night-blind, had always seen badly and the surgeon who operated on her for cataract, which was bilateral, told her that she had a congenital defect of the fundus. II. 3 had always seen badly, he was night-blind and had small anterior polar cataracts; his papilla was normal and the retinal vessels were not narrowed; the fundus, over an area surrounding the papilla, was white, showing atrophy of the choroid, beyond this area was an irregular ring of normal fundus which again was surrounded towards the periphery by an area showing atrophy of the choroid. A very detailed description of the fundus is given by the author. The father died suddenly, aged 59; the mother was healthy and had normal eyes. No consanguinity. Bibl. No 256.

Fig. 266. *Fuchs and Cutler's Case. Atrophia gyrata chorioideae et retinae* in three sisters, the offspring of first cousins; their four brothers, aged 23, 20, 16 and 12 respectively, all had normal vision; three siblings had died young, two of them from diphtheria. The father was dead, but was believed to have had normal vision, the mother was examined and found to have normal eyes; there was no inherited or congenital eye disease known in the family of either.

II. 2, Gisela Geyer, aged 26, had R. V. with -18 D. $= \frac{5}{24}$, L. V. with -20 D. $= \frac{5}{24}$; fields were considerably contracted; there were small almost round opacities at the posterior pole of both lenses; she had no strabismus; on examination of the fundus there was found a large staphyloma surrounding the disc with peculiar lobulated protrusions into a zone of normal fundus, further towards the periphery there was a uniform zone of atrophy. The edges of the staphyloma and of the atrophic zone were sharp in outline and partially marked out with pigment; the fundus between them was quite normal. The atrophic zone appeared almost uniformly white with a very few choroidal vessels near its inner margin, towards the periphery it was covered with a dense network of black pigment. Both fundi were similar. She was subject to fainting fits, was married, and had three boys who saw well.

II. 3, Irma Prohaska, aged 24, had vision which was reduced to perception of light; at the age of 11 she suffered from night-blindness and had strabismus; she had opacities in anterior and posterior cortical layers of both lenses; her whole fundus showed an atrophic choroid except at one place outwards from the papilla where an area two or three times the size of the disc was red and surrounded by black pigment, some deposits of pigment were scattered over the atrophic areas; the discs showed a high degree of atrophy.

II. 5, Rose Prohaska, aged 21, had R. V. = finger counting at 2 m., L. V. with -10 D. $= \frac{5}{60}$; the right field was considerably contracted and the left slightly so; she had been night-blind for five or six years; she had strabismus of right eye and posterior polar cataracts in each lens; on the right, the papilla was surrounded by a staphyloma which was continuous at one point with a peripheral atrophic zone, on the left the staphyloma was nowhere connected with the atrophic zone; the main features of her fundi were the same as in the case of II. 2. Consanguinity. Bibl. No. 177.

Fig. 267. *Laurence and Hutchinson's Case.* This case, first described by Laurence in 1866, is believed to be the same family as the case described by Hutchinson in 1900; it has been placed by Nettleship and Usher under the heading of "*Atrophia gyrata chorioideae et retinae.*" The following description is taken from Nettleship's account of the case, for he discussed the case with Hutchinson and took some pains to try and remove the minor discrepancies which exist between the two accounts of the family. Hutchinson gives a coloured plate of the fundus in the case of II. 12, a girl, aged 16 when the drawing was made, whose sight began to fail about the age of 5 or earlier; a narrow zone of choroid immediately around the optic disc appears quite natural; then comes a very broad zone of incomplete atrophy, leaving only the large vessels, and even they are converted into white bands; about the equator the choroid becomes

gradually less atrophic, although the pigment epithelium and chorio-capillaris appear to be universally absent; some angular and stellate pigment deposits are present in the retina, but not very characteristic either in form or distribution; retinal vessels are stated to have been normal, but when seen again in 1876 they had become shrunken and the discs wavy, although there was no increase of pigment. When seen by Laurence in 1865 she was aged 7; there were already scattered irregular black deposits in the retina of various shapes, but mostly angular, branched or linear, and all the choroidal vessels were very plainly visible, the inter-spaces being paler than the vessels. Laurence described her irides as grey and hair light auburn, her sight as very defective and much worse at night, and her intelligence as dull. When last seen by Hutchinson (1876) she was about 18, had not begun to menstruate, was very nervous, and was considered by her mother to be losing power in her legs; she was the youngest in a sibship of ten. II. 2 was normal and has two normal children; II. 4, a fine man, had five normal children. II. 5 began to lose power in his legs at the age of about 4 years, and became paraplegic, is mischievous and passionate and had to be under care; at the age of 20 Laurence found him only 5 feet $3\frac{1}{4}$ inches high, obtuse in intellect since childhood, sight very defective especially after dusk, muscular power of legs very defective; fundi showed diffuse incomplete atrophy of choroid, absence of pigment epithelium, and a few scattered pigment spots; in fact, Laurence's description of this young man's fundus might almost be applied to Hutchinson's illustration of the sister's eye. II. 6, pitted by small-pox, was 4 feet $6\frac{1}{2}$ inches high when aged 18, legs semi-paralyzed; sight began to fail at about the age of 6, especially at night; fundi show changes like those in the other cases, but the choroidal atrophy was much more advanced, "the fundus has the appearance of a diffused staphyloma posticum." Hutchinson found much the same 10 years later. II. 7 died of small-pox aged 6 weeks. II. 8, 4 feet $4\frac{1}{2}$ inches high, was dull and inanimate like the other affected brothers; legs not so weak as in the other cases and he could run about well till the age of 6 years; vision failing since the age of 12, worse at night, fundi as in II. 5. II. 9, seen aged 22, was normal. II. 10 died of whooping cough at the age of 2 years. II. 11, seen aged 18, was normal. Refraction was hypermetropic in all the affected members; fields of vision stated to be apparently of full size, but there was nystagmus and eccentric fixation.

In all the affected males, development of the sexual organs was arrested, being, according to Laurence, no larger and less perfect than those of a child of 12 months.

The mother of this sibship was normal, she was the only child of parents who died young and knew of no nervous disease in her relatives. The father died suddenly after a sort of fit at the age of 52, he had had no serious illness but had always been very nervous, had much headache in the last years of his life with occasional pains in his limbs, especially on the left side, and for a month or two before his death there was numbness in his left foot; he was a well built man with good vision. The father had three normal brothers who had no children, and two sisters who were normal and had normal children. No consanguinity. Bibl. Nos. 55, 212, 251, pp. 371—3.

Fig. 268. *Jacobsohn's Case.* Probably gyrate atrophy of choroid and retina in father and son. III. 1, aged 20, had been night-blind since very early life; fields were very small; V. $= \frac{20}{100}$ and smallest print at 3 to 5 inches; discs and retinal vessels as in retinitis pigmentosa; the choroid was healthy over a large area including the disc and macula region, anterior to this was a zone over which large areas of the choroid were atrophied, its vessels sclerosed and the overlying retina abundantly pigmented. A coloured plate is given of the fundus. The patient was physically and mentally weak. His father, aged 48, had also been night-blind from earliest life and had a similar fundus, his condition had progressed and he had been quite blind for a year and a half. The mother, aged 54, had incipient cataract, myopia of 1·5 to 2 D. and a normal fundus, V. $= \frac{20}{50}$ in each eye. The grandparents were healthy and unrelated, a sister of the mother was very 'short-sighted.' No history of syphilis.

III. 1 had four siblings of whom two died in infancy, a boy died aged 8, and a sister aged 15 had normal vision. No consanguinity. Bibl. No. 155.

Fig. 269. *Van Duyse's Case.* Retinitis punctata albescens in three siblings. (Two excellent coloured plates of the fundi are given by the author.) II. 1, Josephine L., aged 20 years, had suffered from an extreme degree of night-blindness since the age of 2, and her light sense had become so reduced that it could not be measured by Förster's photometer, her vision was reduced to finger counting at 3 metres; colour sense was defective; she had slight horizontal nystagmus; she had black hair, brown irides, and had good general health; fields of vision were concentrically contracted; teeth were good and urine normal; the fundus showed slightly narrowed arteries with normal veins, the choroid was very dark with some yellowish patches at the periphery as wide as the large retinal veins, and there were present innumerable minute white dots over the whole fundus, but most abundant near the disc and less so in the macula region; the retinal vessels passed in front of the white spots. II. 2, Arthur, aged 19, was normal and healthy in all respects. II. 3, Maria, aged 18, had slight myopia and a normal fundus. II. 4, Auguste L., aged 12, was in an institution for the blind, he had suffered from very marked night-blindness since the age of 4 or 5 years; his fields were concentrically contracted; he had a horizontal nystagmus; he was myopic (R. 7·5 and 6·5, L. 8 and 5·5, normal axes); corrected vision $= \frac{1}{8}$; and his fundus was as in his sister's case sprinkled with white dots, the retinal arteries being narrowed and the choroidal trunks showing some sclerosis at the

periphery. II. 5, Louise, aged 7, had a normal fundus. II. 6, Raymond L., aged 5, was in an institution for the blind; he had shown evidence of very marked night-blindness since he first walked; his fields were greatly contracted and he had horizontal nystagmus; he was a very intelligent child; his fundus was sprinkled with white dots like those of his elder siblings, but they were the most abundant in his case at the periphery; there was sclerosis of some of the choroidal trunk vessels. There was no trace of pigment to be seen in the fundi of any of these cases. The father, aged 44, had normal vision, as also had the mother, aged 42. The mother had had four other children who had died in infancy of pneumonia, "dropsy," or croup. There was no history of syphilis. No consanguinity. Bibl. No. 241.

Fig. 270. *Lauber's Case.* Retinitis punctata albescens in four out of six siblings. The condition in this family was characterised by night-blindness with ophthalmoscopic changes; the fundi were covered with minute white spots which were absent only in the macular region over a limited area and were situated deeper than the retinal vessels, the discs and retinal vessels were normal; colour vision was normal except for some slight anomaly in the case of one boy; the fields were normal in a good light but considerably constricted in a dim light; the condition, the author considered, was evidently stationary. The sibship consisted of II. 1, male, aged 28, affected; II. 2, male, aged 25, examined and found normal; II. 3, male, aged 19, affected; II. 4, female, aged 15, affected; II. 5, female, aged 9, normal; and II. 6, female, aged $5\frac{1}{2}$, affected. The parents were first cousins once removed, the father, aged 56, was examined and found normal, the mother was not examined but was said to have normal eyes. Consanguinity. Bibl. No. 260.

Fig. 271. *Gayet's Case.* III. 2 had always suffered from night-blindness and been unable to go about alone after sunset or in a dimly lit room; he had been passed for military service and was urging his visual difficulties. He was found to have good central vision but contracted visual fields and very defective colour vision; the papillae were a little redder than normal, the retinal vessels a little narrowed, and there were an immense number of white spots covering the whole fundi from papilla to periphery, but less abundant and smaller in size in the papillary and macular regions; there were no pigmentary deposits and the retinal vessels passed in front of the spots; the retina had a greyish opalescent tint; he stated that his eyes were as they had been in infancy. He was not deaf but had no perception of shades of sound. III. 4, aged 13, sister to III. 2, presented a similar condition but in her case the white spots were less numerous, especially in the left fundus, and in the peripheral regions she showed changes characteristic of true retinitis pigmentosa; she also had very defective colour vision and no perception of shades of sound.

Two brothers and a sister, the first, third and fifth members of the sibship, had normal vision. The parents were healthy first cousins. A maternal uncle had very bad sight and the maternal grandfather was blind for several months before his death at the age of 70. Consanguinity. Bibl. No. 120.

Fig. 272. *Spengler's Case.* Nettleship considered this an atypical case of retinitis punctata albescens and the accompanying coloured plate poor. The parents and grandparents were healthy and had good sight; the two grandmothers were first cousins. III. 5, aged 12, was very fair, she had slight convergent strabismus and horizontal nystagmus; her light sense was very little reduced; colour sense normal; fields showed very little contraction even in a dull light; media clear; the papillae were a light yellowish red colour with no excavation; retinal vessels normal; the fundus was albinotic with dark irregular pigmentation of the macula region; the whole retina was covered with "thousands upon thousands" of white dots; there were also in the choroid larger yellowish spots of different sizes and shapes. The same description applies to III. 4, a boy aged 13. III. 3, aged 15, had a completely albinotic fundus with the same white spots but no yellow patches in the choroid; she also had patches of pigment at the periphery quite unlike those of retinitis pigmentosa. III. 2, aged 16, had ashy fair hair and a fundus similar to her younger siblings with no yellow patches in the choroid and fewer white spots. None of the siblings had contraction of visual fields or night-blindness. Consanguinity. Bibl. No. 216.

Fig. 273. *Griffith's Case.* II. 2, a silversmith, aged 48, came up complaining of night-blindness from which he had suffered all his life; there was no history of syphilis; his parents were first cousins; his sister, who also suffered from night-blindness, married her first cousin and had a son whose sight was normal. The author found R. V. L. V. $\frac{6}{36}$, not improved by glasses; the patient showed a marked deficiency in light sense, with fields which though normal for white and for colours in a good light became markedly reduced for colours in the slightest shadow; he had no central or ring scotoma; colour vision was normal; the discs were pale and somewhat waxy, the retinal vessels slightly constricted; there was a general mottled condition of the whole fundus but especially round the disc and macular region where there was a ring area covered with discrete yellow spots resembling Tay's choroiditis. Nettleship reports that the description of the spots is not quite characteristic, but that in all other respects the case is typical of retinitis punctata albescens. Consanguinity. Bibl. No. 195.

Plate XXII. Fig. 274. *Nettleship's Case.* Retinitis punctata albescens in two siblings. This history is of great interest as being one of the very rare cases in which typical retinitis punctata albescens has been seen to lose all its white dots. VI. 2, aged 21 (1887), was a healthy lad working on his father's farm; as long as he could remember he had been unable to see well in the dusk; with slight hm. as. corrected R. V. $= \frac{6}{9}$, L. V. $= \frac{6}{12}$; at posterior polar area were numerous single minute very white dots, evenly dis-

tributed and free from pigment, reaching close up to the fovea; the subjacent choroid looked perfect anteriorly the spots thinned off, but there the epithelium became disturbed and choroidal trunks visible; further towards the periphery the choroid was even paler and showed a little granular pigmentation; the discs were slightly hazy, the retinal vessels normal; there was nothing like retinitis pigmentosa anywhere; fields in daylight were reduced by 10°—15°, in dim light they were reduced to the 20° circle. The patient was seen again in 1894 and 1905 when no change had occurred but he thought that he adapted to changes of light less quickly. In 1913 VI. 2, now aged 47, was examined and *no white dots could be found in any part of either fundus*; disturbance of the hexagonal epithelium is described, also exposure of the choroidal vessels most marked in the lower part of each fundus, where in the R. were seen three definite pigment patches of characteristic bone corpuscle pattern; in the L. were several smaller patches of pigment not of the typical shape; the discs were pale and hazy, the retinal vessels perhaps slightly diminished, lenses and vitreous clear, vision as before.

One younger sister, VI. 8, aged 32 (1905), had the same condition, she had been night-blind since childhood; R. V. = L. V. = $\frac{5}{36}$; fields, in daylight full, were contracted in a dull light; the ophthalmoscopic appearances resembled those in her brother but the white dots were smaller and much more numerous. In 1913 the white dots were much less abundant, there were no pigment spots or patches in either eye, but the discs were markedly paler than her brother's and the arteries were very considerably shrunken; she said that her sight was no worse.

Of their siblings VI. 1 had hare-lip, VI. 3 and 6 died, aged 5, VI. 4 died in infancy, VI. 7 had hare-lip and died in infancy, VI. 5, 9 and 10 were normal. The parents were first cousins once removed. VI. 2 was born at 7 months and was only $9\frac{1}{2}$ months younger than VI. 1. Consanguinity. Bibl. Nos. 251, 299, pp. 387—9.

Fig. 275. *Collins and Nettleship's Case.* Retinitis punctata albescens (?) and retinitis pigmentosa in four siblings, three of whom have been examined by four ophthalmic colleagues at one time or another. The parents and grandparents on both sides were first cousins. Of the eight normal siblings, two died young, one of "water on the brain."

III. 1, aged 38 (1896), had noticed night-blindness for four or five years; refraction nearly em.; R. V. = $\frac{6}{18}$ partly, L. V. = $\frac{6}{12}$ partly; media clear; numerous fine, dull, white dots, chiefly at the periphery of the fundus, were described; discs were healthy, retinal vessels a fair size, fields contracted. A different surgeon in 1905 reported discs rather pale, retinal arteries too small, no pigment deposits, vision as before. Her brother, III. 2, aged 43 (1905), had noticed night-blindness for a year or two; slight hm. as. corrected gave R. V. = $\frac{6}{5}$, L. V. = $\frac{6}{6}$; definite retinitis pigmentosa of typical character was described at the periphery of both eyes; discs rather pale, retinal arteries too small. One of his children, a girl aged 11, was examined and found to have normal eyes. III. 4 was reported to be night-blind, but was not seen. III. 5, aged 20 (1895), was night-blind and intellectually dull; he had no retinitis pigmentosa, but at the periphery of the fundus were numerous discrete white spots; he died young of phthisis. In this family the white dots were confined to the periphery and night-blindness was not noticed until about 20 to 30 years of age. One of them, III. 2, with typical retinitis pigmentosa and no white dots, only noticed his night-blindness at the age of about 40. Consanguinity. Bibl. No. 251, p. 391.

Fig. 276. *Nettleship's Case.* Two sisters with retinitis punctata albescens. IV. 1, aged 19 in 1886, was seen again in 1901, 1907 and 1913; she had been night-blind all her life; hm. of 3·5 D.; vision and fields were normal in a good light but her fields were contracted by artificial light and light sense (Förster's photometer) was very defective; she was thin and delicate-looking from overwork. At the fundus of each eye an immense number of minute discrete dead-white dots were present at the equator and extended nearly as far back as the disc; the discs and retinal vessels were normal. In 1913 the night-blindness was no worse and ophthalmoscopic appearances were much as at the examination twenty-seven years before; there were no dots at the yellow spot and none at the periphery though the epithelium at the periphery had a granular appearance. IV. 4, aged 14 (1887), was seen again in 1892 when her condition was unchanged; she had white dots in her fundus exactly like those of IV. 1 but more numerous, they were wanting in the down-in part of each equator and peripherally to the equator where the stippling of the pigment epithelium was coarsened and ill-defined pale spots, apparently thinned choroid, were seen; at the extreme periphery were some circular dots of the same size but less white than the typical white dots and surrounded by pigment; with + 4 D. V. = $\frac{6}{9}$ partly; she was dusk-blind like her sister; she died aged 29 of phthisis.

Of the siblings IV. 5 was examined and fundi were normal; IV. 2, 3 and 6 were healthy and had perfect sight. IV. 7 died aged 2. The mother had been healthy but died from cardiac failure after pneumonia; two of her siblings died of phthisis. The father died aged 48 of diabetes. No consanguinity. Bibl. Nos. 251 (pp. 385—6), 299.

Fig. 277. *Ulrich's Case.* II. 1, a boy, aged 12, suffered from night-blindness and typical retinitis pigmentosa; the author describes in considerable detail the presence of fine thread-like opacities in the vitreous humour of both eyes which he believed to be the remains of embryonal vessels in the vitreous. II. 2, a sister, aged $8\frac{1}{2}$ years, also suffered from night-blindness and retinitis pigmentosa. II. 3, a sister, aged about 4, had retinitis punctata albescens. No further information or description of her case is given. No consanguinity. Bibl. No. 126.

Fig. 278. *Nettleship's Case.* Retinitis punctata albescens in II. 2, a male, aged 31 (1891). He reported that he had seen badly in a dull light as long as he could remember and that it did not get worse; in a good light he could see perfectly. It was extremely slow adaptation to dull light rather than dusk-blindness; an exposure of only three or four minutes to sunlight would blind him so that for the next five minutes he could not find his pipe in a shady room; after two hours in the afternoon sun in Florida where he had lived he was so blind at sunset that for some time he could not see a man close to him, but after an interval of an hour or less his night-blindness left him and he believed he could see as well as other people. V. R. = V. L. = $\frac{6}{6}$; hm. of 0·5 D.; Bjerrum's types $\frac{6}{12}$ slowly (against the authors $\frac{6}{6}$); characteristic white dots of retinitis punctata albescens were present at posterior part of fundus and as far forwards as equator, they closely surrounded the disc where also the nerve fibre layer of the retina was rather hazy; the yellow spot itself was free from white dots but the retina there showed a fine mottling; the dots often lay parallel to choroidal vessels; no dots were present at lower part of equator and he had once found he could see a little in the upper part of his field when he could not see at all in front; fields were quite full in daylight, contracted in a reduced light. His father had four normal children by his first unrelated wife; by his second wife, who was his first cousin, he had two children, the patient, and a girl aged 29, with perfect eyes. The patient died soon after he was examined in Florida of tubercular meningitis. Consanguinity. Bibl. No. 251, pp. 383—4.

Fig. 279. *Takayasu's Case.* II. 1, a well grown not badly nourished schoolboy, aged 10, was noticed to be night-blind when he was aged 7; on examination it was found that his refraction was emmetropic, R. V. = L. V. = $\frac{6}{6}$, pupils were normal, fields were very slightly contracted, colour sense was normal; his functional defect consisted in a marked lowering of central vision in a dim light; the fundus was covered with very small white points, only the regions of the papilla and the macula lutea remaining free, the spots were mostly round but towards the periphery were sometimes oval, in the equatorial regions the distribution was more scattered, sometimes the spots were confluent, they were always behind the retinal vessels, they were not bordered by pigment and there was no abnormal pigmentation of the retina. The author described him as a case of retinitis punctata albescens.

The parents were first cousins; three younger brothers were healthy but one of them suffered from night-blindness. Consanguinity. Bibl. No. 239.

Fig. 280. *Diem's Case.* Doubtful retinitis punctata albescens in a girl, III. 1, aged 18½ when examined, whose father suffered from a progressive retinitis pigmentosa but had never been night-blind, and whose uncle, II. 1, also suffered from retinitis pigmentosa and was in a home for the blind; II. 1 had seen badly in the dark since childhood. The father had five other siblings who were short-sighted but otherwise had normal eyes and of whom one, a sister, had been deaf since her youth, and another sister was epileptic. The paternal grandmother had been unable to read much at the age of 30, and at the age of 50 was blind to all except the perception of light; she had never been examined. III. 1 had a brother, aged 4, who was not night-blind and had a normal fundus. She herself had never been night-blind but as a school girl had noticed that she did not see so well as the other children; she was myopic and with correction R. V. = $\frac{6}{12} - \frac{6}{8}$, L. V. = $\frac{6}{18}$; her field of vision in full daylight was normal for the R. eye and showed some excentric contraction for the L.; in a reduced light the fields remained unchanged; colour vision was normal; media were clear, the papillae of a rosy colour with clear margin; retinal vessels were normal; surrounding the macula region there was a zone brightly sprinkled with masses of small yellowish white flecks, oval in shape with the long axis radiating from the macula, they were sometimes confluent and the retinal vessels invariably passed in front of them, the inner margin of this zone was clearly defined, the outer was less so, and on the temporal side there were protrusions of the flecked areas into the normal retinal tissues; the macula itself was quite normal. Towards the periphery at a distance of six or seven papilla's diameter from the macula was another zone showing yellowish white flecks of a rather different character, larger in size and more spaced out; beyond this zone the periphery was normal. No consanguinity. Bibl. No. 296.

Fig. 281. *Healy and Drinkwater's Case.* Retinitis punctata albescens in III. 1, a male, aged 23, when examined. He reported that he had had difficulty in seeing in a failing light since his earliest recollections but the disability had increased since he had joined the army. Healy describes how in a darkened room he fell over obstacles and groped his way about; R. V. = L. V. = $\frac{6}{12}$; his fields were contracted to 70° on temporal side, 30° on nasal side; media were clear; the fundi showed hundreds of whitish yellow opaque spots up to 1½ mm. in diameter lying apparently in the deeper layers of the retina, the retinal vessels passed in front of the spots which were superficial to the choroidal vessels; the spots were most numerous in the equatorial zone, fading towards the periphery, they were absent from the macular region and more numerous again in the immediate vicinity of the disc; the fundi were markedly tesselated and several branched collections of pigment were present along the veins in the equatorial zone. The retinal vessels were slightly narrowed, the discs a dirty greyish colour. The author gives a coloured sketch of the fundus.

Drinkwater investigated the family history and reports that the patient's mother, II. 2, her younger brother, II. 3, and her half-sister, II. 6, all had retinitis pigmentosa. The grandparents, I. 1 and 2, were

normal, I. 2 married twice and had affected children by both marriages, he had also two normal sons and three normal daughters by I. 3. II. 3 had eight normal children of whom the eldest was aged 16 years. II. 6 had two apparently normal daughters aged 7 and 1 year respectively. III. 1 had one normal brother.

III. 1 was also partially deaf which appears to have been due to an attack of scarlet fever or measles when he was aged about three years.

No consanguinity recorded. Bibl. No. 324.

Fig. 282. *Cohen's Case.* Retinitis punctata albescens in a sister and brother aged 6 and 13 years respectively; four siblings were unaffected and the parents were normal. This is the only case we have found reported of this condition in a coloured race.

For II. 2, V. $= \frac{2}{40}$, for II. 1, V. $= \frac{2}{70}$. The chief complaint was of night-blindness; no scotomata were present; fields and visual acuity were greatly reduced by diminishing the illumination; the fundi showed numerous discrete greyish white dots with ill-defined borders, varying in size from that of the diameter of a small retinal vessel to that of the disc, arranged concentrically around the equator and spreading towards the periphery; the macular and papillary regions were free from these dots; the retinal vessels passed in front of the dots; and pigmentary changes were present. No consanguinity recorded. Bibl. No. 308 A.

Fig. 283. *Wuestefeld's Case.* Retinitis punctata albescens in a girl aged 8, whose brother, aged 6, had retinitis pigmentosa.

II. 1 was brought up by her father, who stated that she had suffered from night-blindness for some considerable time. On examination it was found that she had myopia of 5 D. and 7 D. respectively in the R. and L. eyes; colour vision was normal; fields of vision were normal in daylight but much contracted in a dull light; light sense (Förster's photometer) $= \frac{1}{30}$. Ophthalmoscopic examination showed that the media were clear; the choroid extremely dark, which was specially striking as she had fair hair; the optic discs were rather pale, the retinal vessels normal; and the fundus presented a multitude of small white dots reaching close to the disc and macula, the smallest being barely visible and the largest equal to about three times the diameter of the retinal vessels in magnitude, no dots were in front of retinal vessels and their number was so great as to give a whitish aspect to the retina. II. 2, aged 6, also suffered in a less degree from night-blindness; he was too young for a complete examination but his choroid also was very dark, without white spots as in his sister and at the periphery there was a typical picture of early retinitis pigmentosa with bone corpuscle-shaped deposits of pigment; the optic discs and retinal vessels were normal. The urine in each case was free from sugar and albumen, and examination for syphilis in the case of II. 1 was negative. The author gives a coloured plate of the fundus of II. 1. No consanguinity. Bibl. No. 217.

Fig. 284. *Galezowski's Case.* Retinitis punctata albescens in two brothers, aged 34 and 21 respectively; a sister, aged 36, had normal eyes, no mention of other siblings between II. 2 and 3. The parents were first cousins and had excellent sight, and the grandparents (? one or both pairs) were also cousins.

II. 2 and 3 were robust with no developmental anomalies, they were noticed to be night-blind as soon as they were able to go about alone. In the case of II. 2 the central part of the fundus was of a greenish brown colour similar to that of Wuestefeld's Case (see Bibl. No. 217); the retina was covered with a multitude of small white spots which were extremely abundant and almost confluent towards the periphery and were less thickly distributed towards the papilla, at the macula none were to be seen; the spots were sometimes round, sometimes oval and there were no deposits of pigment anywhere in the retina; the papilla was rose coloured; the fields were slightly contracted in a good light and considerably more so in a dim light; visual acuity was $\frac{1}{2}$ in ordinary light and was rapidly lowered in a dim light.

In the case of II. 3 the same lesions were present but were less marked, the greenish reflex in the fundus was less marked and the white spots, perhaps a little larger, were less numerous and in parts of the periphery were absent; in his case there were some deposits of pigment typical of retinitis pigmentosa; his fields were less contracted and his vision less diminished than in the case of his brother. Consanguinity. Bibl. No. 231.

Fig. 285. *Cuperus' Case.* III. 2 was suffering from a defect diagnosed by the author as atrophy of the choroid with a high degree of sclerosis of the choroidal vessels diminishing in intensity towards the periphery, with a secondary atrophy of the retina and optic nerve. His two brothers appeared to be similarly affected, the defect appearing in all cases at about the same year of life. Of his four sisters, three were dead and were reported to have had good eyes, one was living and was reported to be short-sighted; she was not examined. The parents of this sibship had normal sight, the grandmother, I. 1, was reported to be blind when she died. III. 2 had seven children, all with good eyes.

III. 2, aged 70, had always been healthy, there was no history of syphilis or nerve disease in the family but he had advanced arterio-sclerosis; he smoked a little and took a little alcohol. His eyes were good until the age of 30 years but since then his central vision had slowly but steadily diminished until he had to give up his work; he had never been night-blind; he was treated by Mooren in 1869 and by Donders in 1874 but received no benefit. At the age of 70 his vision was reduced to finger counting, with excentric fixation; his fields showed absolute central scotomata with normal outer boundaries, the degree of illumi-

nation having no effect upon their size or form; media were normal. The fundi of both eyes were, in the neighbourhood of the papilla and of the macula lutea, a striking white colour; farther out towards the periphery the colour became light brown and in the outermost periphery the normal red colour of the fundus was present. The retinal vessels were small, the smaller retinal vessels having disappeared. The papillae were a light grey colour.

Snellen had examined III. 4 in 1875, he died aged 54; van der Meer examined III. 1 and found a condition exactly similar to that described in III. 2. No consanguinity. Bibl. No. 220.

Fig. 286. *Lindner's Case.* Night-blindness associated with a whitish grey coloration of the fundus in III. 1 the offspring of first cousins, his two siblings died the day after birth and his mother by a second unrelated husband had two normal children.

III. 1, aged 16, had been night-blind since childhood, his colour sense was normal, light sense was much lowered and his fields with normal outer margins in a good light became markedly contracted in a reduced light, there was a small central scotoma for red in the R. eye and a large absolute central scotoma for white in the L. The papillae was blurred but of a normal colour, the vessels were normal; the fundus in the region of the papilla was of a whitish grey colour except at the macula where there was a dark greyish red fleck; the whitish-grey colour extended on the nasal side to a distance of about 6 to 8 papilla's diameter, rather farther on the temporal side and to about half the distance above and below, and the fundus gradually became its normal red colour towards the periphery; the blood vessels stood out very clearly on the white background. Consanguinity. Bibl. No. 298.

Fig. 287. *Mauthner's Case.* This case is of interest as being probably the earliest described case of choroideremia; the following account is taken from Usher (see Bibl. No. 301) as we have been unable to see the author's description of the case:

"II. 1, a male, aged 32, had night-blindness and defective central vision; his condition had got worse after typhus fever fifteen years before; fields were contracted; refraction myopic, R. V. barely $\frac{5}{200}$, myopia $\frac{1}{12}$, L. V. $\frac{10}{40}$, myopia $\frac{1}{16}$; edge of each optic disc was blurred and retinal arteries were narrowed; fundi gave a glaring white-green reflex; occasional choroidal vessels and small pigment heaps were present; a network of vessels in the choroid was present at the macula of the right eye only; macula of the left eye appeared as a well-defined red-brown rhombic area; some lens and vitreous opacities were present in the left eye. The author considered that the choroid was quite absent in the left eye and that there were a few remains of it in the right eye."

His brother, II. 2, had exactly the same kind of bad vision and probably had the same defect; his paternal uncle saw badly. No consanguinity recorded. Bibl. Nos. 78, 301.

Fig. 288. *Mouchot's Case.* Retinitis pigmentosa in a brother and sister, the third and fifth born respectively in a sibship of seven. II. 3, aged 51, had first noticed that he saw badly in the evening fifteen years ago; he was now night-blind and had a concentric contraction of his fields, his central visual acuity was normal; papillae were normal; typical pigmentation of the retina was present in the equatorial region. He had had a history of pneumonia twice and of what was probably a simple conjunctivitis at one time; his six children had good vision.

II. 6, aged 38, also had six normal children; her complaint was of double vision and she had paralysis of the third nerve on the left side; at a later date she was found to have markedly reduced central vision, R. V. = L. V. = $\frac{1}{5}$, concentric contraction of fields and typical pigmentation in the equatorial zone of the retina; she made no complaint of night-blindness and was unaware that there was anything the matter with her eyes except the paralysis for which she was under treatment. Of their siblings II. 2 was an idiot and died aged 7; II. 5 died aged 30 of a pulmonary affection; three sisters were living and well. The parents lived to old age and were normal and healthy. No consanguinity. Bibl. No. 63.

Fig. 289. *Merrill's Case.* (Published by Loeb.) A woman who was suffering from retinitis pigmentosa married and had a son who had coloboma of the iris and choroid. No consanguinity recorded. Bibl. No. 261.

Fig. 290. *Rampoldi's Case.* Retinitis pigmentosa in four brothers, the offspring of consanguineous parents; all the brothers were suffering from pellagra from which disease the mother died. Consanguinity. Bibl. No. 125.

Fig. 291. *La Serre's Case.* This case is of some historic interest though it does not consistently belong to the group of diseases under consideration; it is included here because it has been reported as the earliest recorded case of hereditary night-blindness.

The author writing in 1688 describes a girl aged about 18 years who became night-blind every year about the month of May, the condition lasting for three or four months, after which she recovered and no trace of the defect remained. A paternal aunt and two children of this aunt were affected in the same way. No. consanguinity recorded. Bibl. No. 18.

Fig. 292. *Ovelgün's Case.* This case is of interest as being the earliest recorded case we have found of hereditary retinitis pigmentosa. The author, writing in 1744, was treating II. 1 who came to consult him

and who mentioned that his daughter, aged 14, and his son, aged 2 years, suffered from night-blindness and that the disease was inherited through his wife, she herself being normal, but the sons of two of her paternal uncles being affected in the same way as his own children. The disease appears to have progressed to blindness in one of the cases. No consanguinity recorded. Bibl. No 19.

Fig. 293. *Mouchot's Case.* A single case of retinitis pigmentosa in a sibship of eleven, the offspring of unrelated parents who had good sight. The father died aged 62 and the mother aged 63 of pulmonary affections, the father had been ill for a long time. Two brothers were living and saw well, seven brothers and one sister died between the ages of 19 and 23 years, probably from tubercular affection.

II. 1, aged 25, was completely blind at night; he had first noticed his difficulty at the age of 13; V. R. $=\frac{4}{20}$, V. L. $=\frac{1}{20}$; he had divergent strabismus, tension normal, media clear, fields contracted; his discs were pale, the retinal arteries thread-like and there was typical pigmentation in the equatorial region. The author gives a beautiful coloured plate of the R. fundus. There was no history of syphilis. No consanguinity. Bibl. No. 63.

Fig. 294. *Mouchot's Case.* Retinitis pigmentosa *sine pigmento* in a deaf-mute boy aged 16 who had been night-blind as long as he could remember; he was found to have some contraction of his fields, the discs were normal and his retinal vessels perhaps slightly narrowed. His parents were normal and unrelated; his sister and brother were normal. No consanguinity. Bibl. No. 63.

Fig. 295. *Magnus's Case.* Congenital retinitis pigmentosa in a blind girl whose elder brother also was born blind; one brother was normal. The parents were normal and unrelated. No consanguinity. Bibl. No. 133.

Fig. 296. *Pons' Case.* (The account of this case is taken from the article on Retinitis Pigmentosa in the *American Encyclopedia of Ophthalmology*, Vol. xv., 1919.) Retinitis pigmentosa in three sisters, all of whom were blind from birth; the fundi were typical of the disease. In all three sisters both eyes showed a marked bulging of the cornea which had been noticed by the mother shortly after birth in each case; in other respects the sisters were normal and their health was good. Two sisters died in infancy of whom one was said to have been blind; a brother and a sister with normal vision died in adult age; two living brothers had good eyes. The parents were normal and unrelated, and there was no history of eye disease in the ancestry. There was no evidence of syphilis. No consanguinity. Bibl. No. 284.

Fig. 297. *Richter's Case.* Congenital night-blindness in three members of a sibship of nine, one sibling died in infancy. The parents and their ancestry were believed to be free from the defect. No consanguinity recorded. Bibl. No. 24.

Figs. 298 and 299 are described in our section on Glioma retinae.

SECTION V

CONGENITAL NIGHT-BLINDNESS

Plate XXIII. Fig. 300. *Sinclair's Case.* Fourteen cases of congenital stationary night blindness in six generations. IV. 6, aged 50, and her son, V. 9, aged 11, were examined. For each case the ophthalmoscopic appearances were perfectly normal; V. $\frac{5}{6}$ in each eye; fields for white were full in daylight, under diminished illumination it was found that a moderate reduction of light produced no change in the visual fields, but when the illumination fell below a certain point the fields became very markedly reduced as compared with those of a normal person; Förster's photometer, after twenty minutes adaptation, required the opening to be 7 as compared with 2 for a normal eye; colour vision was normal.

Of the affected members nine were males, five were females; all had normal vision and full fields in a good light but all were night blind to such a degree that they were unable to go about alone after dusk. The night-blindness was in all cases congenital and non-progressive and was not associated with deafness or other hereditary defect. In 1907 the author informed Nettleship of the case in generation VI.; VI. 2—4 were still too young for examination. No consanguinity. Bibl. No. 235.

Fig. 301. *Sedan's Case.* Twenty-one cases of congenital stationary night-blindness in four generations, the affected individuals consisting of eleven males and ten females. An artillery officer in generation IV. was examined at the age of 30 when he had myopia of 3·5 D., colour vision normal, no definite contraction of visual fields and his fundi appeared to be perfectly normal; he had night-blindness which was not progressive and he stated that he had never been able to go about alone at night. The parents in generation I. appear to have been normal, both their daughters, four of their five grandchildren and ten of their nineteen great-grandchildren were affected. Ten years after the publication of this case Cutler (Bibl. No. 182) heard from the author that six more children had been born in generation V. of whom two were affected males; the exact parentage of these children was unknown. At a later date again Nettleship endeavoured to obtain further information of the family but was unsuccessful. No consanguinity recorded. Bibl. No. 136.

Fig 302. *Cutler's Case.* Congenital stationary night-blindness in three siblings of a sibship of thirteen. II. 3 was seen aged 42 (1881). On examination it was found V. R. = V. L. = $\frac{6}{24}$, or with weak concave glasses = $\frac{6}{12}$; he had a slight oscillating nystagmus; fundus was normal; central colour sense was normal; light sense = $\frac{1}{35}$; there was a concentric narrowing of the fields for white. The other members of the sibship to be affected were II. 2, a male aged 44, and II. 5, a female aged 28. The three were married and had normal offspring. No further information was available and the family could not be traced. No consanguinity. Bibl. No. 182.

Fig. 303. *Fuchs' Case.* This case was first published by Nettleship to whom it was sent by the author. Two normal and unrelated parents, Benowicz by name, had three night-blind children. II. 1, a girl, aged 15, was first noticed to be night-blind at the age of 3; R. V. = L. V. = $\frac{6}{16}$ to $\frac{6}{15}$ with + 1·5 D. cyl.; light sense by Förster's photometer was $\frac{1}{20}$; fundi normal. II. 2, a girl, aged 11, was also first noticed to be night-blind when aged 3; R. V. = $\frac{6}{15}$, L. V. = $\frac{6}{20}$ not improved by glasses; light sense = $\frac{1}{25}$; fundi normal. II. 3, aged 8, a boy, was also night-blind and had normal fundi. No consanguinity. Bibl. No. 251, p. 409.

Fig. 304. *Hudson's Case.* Congenital stationary night-blindness in a mother and her two sons. II. 2 was seen aged 22; he had suffered from night-blindness as long as he could remember, he thinks the condition is improving, at any rate it is getting no worse; he was a dentist's mechanic and could see well in a good light but if the light failed in the least degree his vision was at once below the normal; fundus was quite normal; fields were about $\frac{1}{3}$ contracted; R. V. = $\frac{6}{18}$, with $\frac{-1\cdot0 \text{ sph.}}{-2\cdot5 \text{ cyl. axis } 165^\circ}$ $\frac{6}{9}$, L. V. = $\frac{6}{18}$, with $-2\cdot5$ D. cyl. axis 160° = $\frac{6}{9}$; there was an entire absence of any ophthalmoscopic signs pointing to retinitis pigmentosa. His mother and elder brother were the only two members of his family, so far as he knew, to be similarly affected. No consanguinity. Bibl. No. 224.

Fig. 305. *Stücenart's Case.* Congenital night-blindness in ten members of four generations—both sexes being affected. I. 1, who lived to the age of 74, was night-blind; she had ten children of whom alternate individuals were born with this condition. One of her affected daughters, II. 2, who also lived to be 74, married and had three children, the first and third of whom were affected. Of these III. 1 had no children; III. 2 had very good sight and III. 3, a son, married twice, having one child, a son who was night blind, by his first wife and by his second wife the first two children died in early infancy of diphtheria, the third child, a son, aged 4 years, was night-blind, and the fourth child, aged 2 years, had apparently normal eyes. Normal members of the sibship II. 2—11, who married, had normal offspring. The affected members could see perfectly well in the daytime or in a well lit room at night though they were a

little short-sighted. The eyes on examination presented nothing abnormal. No consanguinity recorded. Bibl. No. 30.

Fig. 306. *Cutler's Case.* Congenital stationary night-blindness in three sisters aged 42, 40 and 37 years respectively (1895). II. 5, a Russian Jewess, came up complaining of hyperaesthesia retinae; she was hypochondriacal and had been night-blind all her life; V. R. with + 1·5 D. cyl. = $\frac{5}{6}$, V. L. with − 5·5 D. sph. = ? $\frac{5}{6}$; light sense after adaptation = $\frac{1}{25}$; fundus normal except for some narrowing of the retinal arteries. She had four children of whom one died in infancy and three are living and normal. In addition to her two night-blind sisters she had two normal sisters and three normal brothers; one sister had nine children and another had three children all of whom are normal (which sisters were married was unstated); one brother had seven normal children and another brother had three normal children by his first wife and six normal children by his second wife who was his cousin. The mother, I. 4, had cataract; the father, I. 3, had lost one eye from glaucoma; a paternal uncle, I. 2, became gradually blind and his daughter, II. 1, aged 15, was blind and was believed to have been born blind. Consanguinity. Bibl. No. 182.

Fig. 307. *Fuchs' Case.* This small pedigree of congenital night-blindness was sent by the author to Nettleship who first published it. II. 6, Rosa Bauger, aged 45, had stationary night-blindness; she was myopic, 7 to 8 D. and her corrected vision was $\frac{6}{18}$; her fields for white were decidedly contracted; the photometer showed very marked lowering of light-perception; the fundus was normal except for myopic changes and some opacities in the vitreous. She was the youngest in a sibship of five, the offspring of normal unrelated parents and she herself had four normal children. Her next elder sister, II. 5, was also night-blind, the other three siblings were normal but the eldest of these, a sister, II. 2, had one child who was night-blind. No consanguinity. Bibl. No. 251, p. 408.

Fig. 308. *Atwool's Case.* Congenital night-blindness in seven members of three generations, three males and four females being affected. III. 5 had never been able to see his way clearly at night; V. = $\frac{6}{6}$ in each eye; ophthalmoscopic appearances were normal. His father, II. 3, a naval officer, had more than once accidentally walked overboard from the bridge of his ship at night. A sister, III. 4, a hospital nurse, reported that she had been similarly affected as long as she could remember and was unable to go out alone in the dark; her refraction was hypermetropic, V. = $\frac{6}{6}$, fields and colour vision were normal and her fundi were dark but normal. Two brothers were normal, a sister, III. 1, was affected. Two paternal aunts, II. 1 and 2, and the paternal grandfather, I. 2, were also affected.

Nettleship made efforts to obtain further information of this family but had no success. No consanguinity recorded. Bibl. No. 180.

Fig. 309. *Langdon's Case.* Congenital stationary night-blindness without fundus changes in father and daughter. II. 1, aged 46 (1906), was given spectacles, and her R. V. with − 0·25 sph. − 1·50 cyl. ax. 100° = $\frac{6}{5}$, L. V. with + 0·25 sph. − 2·50 cyl. ax. 75° = $\frac{6}{5}$; the fundi were perfectly healthy. In 1909 R. V. with − 0·25 sph. − 2·25 cyl. ax. 100° = $\frac{6}{5}$, L. V. with − 3·25 cyl. ax. 75° = $\frac{6}{6}$. In 1910 she appeared again asking for her fields to be tested since she had all her life stumbled over objects and believed she had a scotoma; her fields were tested in a good light and found normal; her central light sense tested with de Wecker's charts = $\frac{4}{10}$ of normal for R. and $\frac{3}{10}$ of normal for L.

I. 1, father of II. 1, and a medical man, said that he had seemed to need a bright light to see even in boyhood; R. V. with + 1·5 D. sph. = $\frac{6}{5}$, L. V. with + 1·50 sph. + 0·25 cyl. ax. 120° = $\frac{6}{6}$; his fields were full in ordinary light; concentrically contracted in a dull light; no scotomata were present; fundi were normal; light sense by de Wecker's chart = $\frac{1}{2}$ of normal. His mother died at his birth and his father when he was aged 5, and no further family history could be obtained. No consanguinity recorded. Bibl. No. 304.

Fig. 310. *Fitzgerald's Case.* II. 1, a clergyman, aged 35 years, had been unable to see after sundown as long as he could remember; one of his three living sisters was also night-blind. His mother had fourteen children of whom two were still-born, seven died young of "water on the brain" and one son, II. 5, died aged 24 of probably tubercle. A distant cousin on the mother's side was also said to be night-blind. The patient, II. 1, had normal fundi, normal colour vision and slight myopia. No consanguinity. Bibl. No. 80.

Fig. 311. *Cant's Case.* (Published by Nettleship.) Night-blindness in two siblings, the offspring of first cousins. I. 1 had good sight, he died in middle age; I. 2 saw well. They had five children of whom II. 1, aged 24 (1908), was said by his mother to have been very short-sighted and night-blind since early childhood; he was examined by Nettleship and Usher and found to have myopia of about 10 D., retinal vessels were normal and fundus was normal except for moderate crescents; fields to rough hand test seemed full; his sight was conspicuously defective in a dim light. II. 2, aged 17, had myopia of about 3 D., she showed no shortness of sight till about the age of 13; she was not night-blind; fundus was normal. II. 3, aged 13, had been very short-sighted and night-blind since early childhood; she was found to have myopia of about 10 D., fundus was normal except for moderate crescents. The other two siblings were normal. Consanguinity. Bibl. No. 263, p. clviii.

Fig. 312. *Nettleship's Case.* II. 1, aged 60, suffered from night-blindness; her V., with + 1·5 correction, = $\frac{6}{18}$; fundus was normal except for a small patch of epithelial disturbance at the macula of the L. eye; there were striae in her lens. II. 2, aged about 50, had always had bad sight and suffered from night-

blindness; he could only see straight before him. II. 3 had ocular headaches but was not night-blind. No consanguinity recorded. Bibl. No. 251, p. 410.

Fig. 313. *Fuchs' Case.* (Published by Nettleship.) Two normal and unrelated parents named Wenzel had six children, II. 1—6, of whom the first four had normal eyes. II. 5, a labourer, aged 22, had always suffered from night-blindness; he was myopic −6 D.; corrected V. $= \frac{6}{18}$; fields for white were full; light sense by Förster's photometer $= \frac{1}{12}$; fundus was normal except for myopic changes. II. 6, a female, aged 19, was also night-blind but was said not to be myopic. No consanguinity. Bibl. No. 251, p. 409.

Fig. 314. *Bessonnet's Case.* Congenital stationary night-blindness in a mother and two sons. II. 1, aged 17 years, had suffered from night-blindness since an early age and was unable to go out alone in the evening; his parents could not remember that he had ever been any better than he was at the time of examination; his general health was excellent and he had normal vision in good daylight. Ophthalmoscopic examination revealed no abnormality; there were no scotomata and no contraction of visual fields. His mother and one of his brothers were similarly affected, in both cases there was nothing pathological to be found except night-blindness. No information is given of normal members of the family but the original account of the case was inaccessible and the above is taken from an abstract only. No consanguinity recorded. Bibl. No. 230.

Fig. 315. *Vieusse's Case.* II. 1, aged 40 years, reported that his parents had noticed at an early age that he became blind for two or three hours in the evenings, not even seeing large objects, and this condition had troubled him all his life. If he remained in a dull light all the day night-blindness did not develop in the evening; he had never noticed that fatigue affected the condition. In the day the pupils were very dilated and there was some contraction of fields but the fundal appearances were normal and there was no trace of pigment to be seen in the retina. A sister had the same symptoms as her brother but another brother, II. 2, had normal vision. The parents were first cousins with normal sight.

The patient was treated by protecting the eyes from bright light during the day either by means of tinted spectacles or by means of a dark veil.

The condition is not typical of congenital stationary night-blindness but it may be of some interest to include it here. Consanguinity. Bibl. No. 104.

Fig. 316. *Swanzy's Case.* II. 1, aged 27, was slightly amblyopic and had always been so, in the dusk his sight became very imperfect and as a child he had always needed to be led about as soon as twilight set in; the ophthalmoscopic appearances were normal; colour sense was normal; refraction was slightly hypermetropic. Of his siblings one brother and three sisters were also night-blind; the brother and one sister were abroad but the other two sisters were seen one of whom was emmetropic, the other slightly myopic; the night-blindness in the case of the two sisters who were seen was less severe than in the case of II. 1. The parents and ancestry were normal as far as was known. No consanguinity. Bibl. No. 83.

PLATE XXIV. Fig. 317. *Cunier, Truc and Nettleship's Case.* The pedigree of the Nougaret family of Vendémian showing a history of congenital stationary night-blindness was first published in 1838 by Cunier[1] who traced the defect through seven generations; seventy years later the history was brought up to date and considerably extended by Professor Truc and M. l'Abbé Capion, Curé of Vendémian, at the request of Nettleship who went over himself to examine certain of the cases and published the greatly enlarged pedigree extending now to ten generations in 1907[2]. A full history of the original discovery of the family and of the collection of facts is given in this paper where Nettleship also describes the nature of the country surrounding Vendémian and the conditions under which examination of individuals was carried out.

At the time of Cunier's work on the pedigree the ophthalmoscope had not been invented so that he was unable to definitely state the nature of the case and it was only in 1906 that Nettleship through Professor Truc was able to pronounce that the disease had been proved to be congenital stationary night-blindness, was not retinitis pigmentosa, and that further it was that type of congenital stationary night-blindness which affects and is transmitted by both sexes alike, is not characteristically associated with myopia and is never transmitted through a normal member of the stock.

Our efforts to hear whether any further cases of the defect have occurred in the family since Nettleship's publication have met with no success; the difficulty of the local patois and the tendency of the family to conceal the defect make it useless for anybody to try to obtain reliable information without the cooperation of workers living in the district.

Jean Nougaret, I. 1, a butcher, known as "le Provençal," born about 1637, is supposed to have introduced the defect into the parish of Vendémian; amongst his descendants the affected members now number 135 of whom 72 are male, 62 are female and one was of sex unknown; there appears to be some evidence to suggest that owing to concealment of the defect the real number of affected members may be even greater.

With regard to consanguinity, Nettleship noted forty cases of marriage within the stock, most of these cases occurred between distant cousins for the descendants of Jean Nougaret were Catholics and as such were forbidden to marry their first or second cousins without a special dispensation; many such marriages

[1] Bibl. No. 27. [2] Bibl. No. 243.

amongst normal branches of the family are not noted in the pedigree. V. 41, an affected male, married his second cousin, one of the females of V. 39; they had nine children of whom three were affected; VII. 63, an affected male, married VI. 121, his distant cousin, who was herself affected; this marriage resulted in two children both affected.

The cases examined by Nettleship were VII. 90, female, aged 46; VIII. 9, male, aged 51; VI. 76, female, aged 72, whose R. eye was nearly blind from glaucoma; VIII. 6, female, aged 55, her son IX. 8, aged 26 and granddaughter X. 3, aged 10 months; VII. 86, female, aged 58; VII. 100, male, aged 46 and his son VIII. 63, aged 16; VII. 115, female, aged 47 and her daughter VIII. 72, aged 21; VII. 63, aged 64, his wife VI. 121, aged 64 and three of his grandchildren IX. 27, 28 and 30, all of whom had normal fundi and were demonstrated to be night-blind; their refraction was mostly emmetropic or slightly hypermetropic; VII. 86 had myopia of 3 D., and they all had good vision in daylight. X. 3 was too young to test. In writing to Nettleship of the family the Curé said "the subjects of the night-blindness have no physical defects and see as well during the day as other people, indeed better according to their own statements, but on a moonless night they are completely blind; the adults learn to guide themselves at night in places with which they are familiar, and seem to recognise the presence of obstacles by some movement or displacement of the air, but unless the moon is up they cannot go beyond the village at night without either a guide or a lantern, and the night-blind children, not having learnt to compensate so well for the defect, have recourse to walking at night or in dark places with head erect, arms extended and hands open."

We should like to add here some tribute to the great contribution of labour and enthusiasm on the part of M. Chauvet, who originally drew up the pedigree for Cunier, and of M. l'Abbé Capion, the Curé, without whom it would have been impossible to obtain this record, who to quote Nettleship "devoted many hours of many days for nearly two years, with indefatigable patience, to the task of unravelling the complications of this genealogy." Consanguinity. Bibl. Nos. 27, 243.

Fig. 318. *Pagenstecher's Case.* Congenital stationary night-blindness affecting males only and transmitted by unaffected males or females. III. 3 brought his grandson, V. 1, to be examined, stating that the parents of the child had noticed lately that he was suffering from night-blindness. He himself, III. 3, suffered from the same condition as did one of his brothers, III. 5, all his four male cousins and his maternal grandfather, I. 1, who had told him that this condition had been inherited by the males of the family as far back as could be traced. I. 1 died in 1827, leaving a normal son, II. 2, and two normal daughters, II. 3 and 5. II. 2 married and had two night-blind sons; II. 3, the mother of III. 3, had two affected sons, one normal daughter and one normal son; II. 5 had two night-blind sons. In the next generation all were normal but IV. 2, the daughter of III. 3, had three sons, of whom one was night-blind. III. 3 was examined and found to have myopia of 3 to 4 D.; there was some opacity in the L. lens; ophthalmoscopic appearances were normal; on lowering the light his vision became rapidly reduced and there was a concentric contraction of his fields; colour vision was normal. V. 1 was night-blind and ophthalmoscopic appearances were normal; his mother, IV. 2, was examined, but no trace of night-blindness was found. V. 2 and 3 were probably too young to be examined and Nettleship was unsuccessful in his efforts, at a later date, to obtain further information. No consanguinity recorded. Bibl. No. 102.

Fig. 319. *Nettleship's Case.* Five cases of night-blindness from infancy or birth, limited to males and transmitted through unaffected females, associated with myopia. I. 1 and 2 had good vision, I. 2 was "mad" for some weeks before his death at the age of 77. They had eleven children of whom five died young, the two living sons, II. 1 and 6, had been night-blind all their lives and were not getting worse; II. 1, aged 40, wore glasses in the street and was probably myopic; II. 6, aged 28, did not wear glasses. Of the daughters II. 2 had two children with normal vision whose sex was not recorded; II. 4 had two sons of whom III. 3 was very night-blind and died of diphtheria aged 2 years; III. 4, aged 7 years, saw quite well at night. II. 7 had three sons one of whom, III. 5, aged 5, was noticed by his mother to be night-blind at the age of 12 months, his pupils were normal in their reaction to light but were rather large; refraction, myopia 4 D., moderate crescents were present; vessels were normal; there was an appearance of coarsening of the pigment epithelium in some parts but nothing incompatible with health; colour vision normal. His brother III. 6, aged 3, was night-blind and myopic; he had small crescents and a single minute dot of black pigment in the left upper periphery; he had large pupils and a fine lateral nystagmus. III. 7, aged 12 months, and III. 8, aged 3 years, were reported to have normal vision. No consanguinity. Bibl. No. 251, pp. 418—9.

Fig. 320. *Nettleship's Case.* This very extensive pedigree of congenital stationary night-blindness consists of two pedigrees previously published and believed to be unrelated, one by Stanford Morton[1] in 1893, the other by Nettleship[2] in 1908; the relationship was discovered and the combined pedigree was published in its completed form[3] in 1912.

The night-blindness here is of the type which is confined to the male sex and transmitted through the unaffected females and as is usual in this type is associated with a high degree of myopia and with a considerable amount of defective visual acuity, there is also associated in this case a prevalence of mental

[1] Bibl. No. 175. [2] Bibl. No. 251, pp. 419—21. [3] Bibl. No. 282.

instability. The degree of night-blindness was stationary in all cases, present from earliest recollection and was accompanied by no fundus changes other than those due to the myopia.

IV. 4 and IV. 8 are the earliest cases definitely known, but it was asserted by some relatives and denied by others that the grandfather of these brothers, probably II. 3, was also night-blind. IV. 4 died aged 12 of kidney disease, he was believed by VI. 10 and VI. 51 to be short-sighted. No information as to myopia in IV. 8.

Generation V. was free from night-blindness but two members, V. 9 and V. 17, were myopic and there was a fairly heavy infant mortality.

Of the sibship VI. 5—11 four out of six males were night-blind and myopic from the earliest recollection; this family was in Australia and information was given by VI. 10, a solicitor, whose reading glasses were R. – 8 D. sph., – 4 D. cyl.; L. – 4 D. sph., – 5 D. cyl.; axes nearly vertical; his sight was good when corrected. There is no measure of the refraction of VI. 5, 7 and 9. VI. 5, 6, 7 and 8 are married and have normal children of both sexes, one or two of whom are said to be slightly short-sighted. VI. 9 died young of rheumatic fever; VI. 10 is unmarried. Of the sibship VI. 12—23, VI. 20 died in infancy and three of the remaining six males are night-blind and myopic; and two males, VI. 17 and 19, who are not night-blind, are said to be "near-sighted," two females also, VI. 12 and 22, are said to be near-sighted. There is no measure of the refraction in this sibship. VI. 15, 17 and 23 have normal children. Of the sibship VI. 25—35 two out of three males were night-blind and myopic, one of them, VI. 31, being also mentally defective, three died in infancy, VI. 28—30, and one female, VI. 32, was night-blind to a less degree than her brothers but was not myopic. This is the only female in this pedigree to be affected and it was only after most careful investigation that Nettleship classed her as an undoubted case of the disease. She was aged 18, had a slight astigmatism and with a correction for this saw $\frac{6}{6}$ with each eye; her light perception appeared to be normal yet she had some difficulty in going about alone on a dark night, but it was chiefly on the basis of the perimetric results that Nettleship decided upon his diagnosis. VI. 31 was night-blind to a less degree than his brother VI. 35, he used – 5 D. spectacles from about the age of 17 till his death from intestinal obstruction at the age of 41; he had been in an asylum and was mentally defective. VI. 35 was under observation for a considerable period of years and his refraction was measured from time to time. At the age of 14 he had – 5 D. spectacles probably for distance, at the age of 21 his myopia was about 10 D. and increased to 13 D. by the age of 35; when last examined by Nettleship at the age of 41 (1911) there had been no further increase. The light sense with Förster's photometer after 20 minutes adaptation was about $\frac{1}{10}$th compared with Nettleship's; his fields were taken under varying conditions and are given in the original paper; he has always been very blind at night and for the rest he is a healthy vigorous farmer with dark brown irides and hair. There is no information of children from any members of this sibship.

The sibship VI. 36—47, the offspring of an unaffected daughter of IV. 4, have all perfect sight (VI. 36 died in infancy and so condition of sight was unknown), VI. 45 is believed to have died from suicide and VI. 46 was reported to be in an asylum. V. 17 married his first cousin and had ten children, VI. 51—65, of whom four died in infancy and the three males who survived were all night-blind and myopic; one female, however, VI. 53, who married and had seven children, did not transmit the disease. VI. 51 was a nervous type of individual, he was wearing – 4·5 sph. – 2·5 cyl., axis nearly vertical for each eye, and this appeared to exactly correct his refraction over an extensive period of years; V. = $\frac{6}{12}$ nearly; light sense with Förster's photometer was $\frac{1}{16}$ (no note of adaptation time); has been night-blind all his life. VI. 55 was night-blind and short-sighted and his eyes were said to be "not straight"; he lives abroad and no further particulars could be obtained. VI. 59 had been night blind all his life; he had had both external recti cut at the age of 19 and the L. eye was still somewhat divergent; at the age of 34 Nettleship found R. – 6 sph. – 2 cyl. V. = $\frac{6}{9}$; L. (divergent) – 6 cyl. – 5 cyl. V. = $\frac{6}{24}$; colour vision apparently normal; the R. fundus showed three or four small round dots of pigment but the O. D.'s and vessels were normal and there was nothing to suggest retinitis pigmentosa. VI. 48—50 were three normal offspring of V. 17 by a second unrelated wife. VI. 66—68 are three brothers of whom 66 and 67 died young and were epileptic and imbecile and 68 had a history of repeated pulmonary haemorrhages, he had excellent sight. Of the sibship VI. 69—74, VI. 71 is short-sighted, considers that he sees less well than other people at night and Nettleship had little doubt that he was night-blind in some degree though his relatives did not consider him to be so. VI. 74, a female, is said to be mentally very peculiar. The only remaining case of night-blindness in this generation is VI. 82, aged 50 (1911). He began to wear glasses at the age of 9 years; at the age of about 17 he was ordered – 8 D. and after this his refraction was observed from time to time and had increased little if at all when Nettleship finally examined him at the age of 50; at this time with correction R. V. = L. V. = $\frac{6}{12}$ part; colour sense was normal; fundus normal; choroids decidedly light; light sense after 20 minutes adaptation $\frac{1}{16}$ (compared with Nettleship's); fields were examined under a variety of conditions and are given in the original paper; he had been suspected of phthisis but developed into a hard-working rector with excellent health.

In generation VII. there are four affected individuals. VII. 45 and 46 the only two males in their sibship are both night-blind and highly myopic. VII. 46 also is said to be a little mentally deficient and to have nystagmus; the pupils of both brothers are said to be habitually large; the spectacles of VII. 45

are said to be about – 9 to – 12 D. The four sisters were intelligent and had excellent vision. VII. 49, aged 30 (1911), has been under observation since he was seen by Stanford Morton at the age of 12. He had fair vision then with his myopia corrected and perfect colour vision; night-blindness, with no visible fundus change, from earliest recollection, and concentrically contracted fields. Nettleship examined his refraction at the age of 13 and found for R. – 2·5 sph. – 2 to 3 cyl., V. $= \frac{6}{18} - \frac{6}{9}$; L. – 2 sph. – 2 cyl., V. $= \frac{6}{18} - \frac{6}{9}$ which was practically the same when examined again at the age of 30. Irides blue or blue-grey; light sense by Förster's photometer furnished with a plain sheet of white paper at the end, after 20 minutes adaptation nearly $\frac{1}{3}$ (compared with Nettleship's); fields were taken under varying conditions and can be seen in the original; there was a crescentric relative scotoma enclosing the blind spot. The other members of his sibship have normal sight.

VII. 56, the only child of VI. 85, writes from America that he wears spectacles constantly and that he cannot see after dusk, he sends the prescription for his spectacles showing them to be – 9 D. sph. For any further information about the members of this pedigree we must refer the reader to the original article. Consanguinity. Bibl. No. 282.

Fig. 321. *Newman's Case.* An interesting pedigree of congenital stationary night-blindness in males only transmitted through unaffected females only and associated with myopia and pterygium. I. 1, Joel Bryan, was a quaker in North Carolina, probably of English extraction; the condition of his eyes is unknown but his cousin, I. 3, a physician named Thomas Vause, is known to have been night-blind. II. 1, Margaret Uzzell, daughter of I. 1, had normal vision but transmitted the defect to three of her four sons; she had also five normal daughters. II. 2 was normal.

III. 1 was night-blind; III. 2 was believed to be normal and to have normal offspring. III. 4 and 6 were normal and had normal offspring. III. 8, aged 74 (1912), had been night-blind since infancy, he was also "short-sighted" and suffered considerably from pterygium; all his children were normal with regard to night-blindness but many of his grandchildren were affected. III. 9 was normal. III. 10, aged about 70 (1912), was night-blind, myopic and had a pterygium; he also had normal children but affected grandchildren. III. 11 had normal vision. III. 12 and her progeny were believed to be normal. III. 14 and her progeny had normal vision. III. 16, the only normal son of II. 1, had normal descendants.

In generation IV., of the children of III. 8, none were night-blind but six out of ten (4 males and 2 females) suffered from pterygium; members of other sibships of this generation were all normal.

In generation V., of the seven children of IV. 6 who suffered from pterygium, all were normal with regard to night-blindness but three males suffered from pterygium, two males and two females were normal, one of the females died in infancy. V. 8—14 consists of five normal females and two night-blind males, one of whom V. 14 had strabismus; V. 9 was reported to be night-blind and to have the associated defects; their mother, IV. 8, Mrs Brown, had pterygium but none of her children had this affection. Of the sibship V. 15—21, the offspring of the normal IV. 10 (Mrs Hobdy), five out of seven males were night-blind and three of these were also myopic and had strabismus. V. 22, the only son of IV. 12 who suffered from pterygium, was normal. V. 23—26 consists of two normal females and two night-blind males, one of whom was also myopic and had strabismus; their mother, IV. 14, Mrs Floyd, suffered from pterygium. V. 27—30 consists of two normal females and two night-blind males; their mother, IV. 18, Mrs Hurst, was normal. V. 33—36 consists of one normal male, V. 33, two night-blind and myopic males, V. 34 and 35, and one normal female, V. 36; their name was Montgomery. The only other affected member of this generation is V. 39, the only son of IV. 30, who was night-blind; his name and age were unknown. No consanguinity. Bibl. No. 300.

Fig. 322. *Cant's Case.* (Published by Nettleship.) Night-blindness without visible changes in the fundus in three myopic males. I. 1 lived to be 90, she became blind in her old age; her daughter, II. 2, had three children, of whom III. 2 was reported by his daughter to have been very short-sighted and night-blind all his life and had always had to be led about after dusk, he could see quite well in the day, he died aged 76; III. 4 and III. 6 had perfect vision throughout life. III. 2 married twice, by his first wife he had a daughter, IV. 2, by his second wife he had three sons and two daughters all with good sight. IV. 2 had an illegitimate son, V. 1, who was examined by Usher and Nettleship; he had been short-sighted and unable to see at night as long as he could remember; he had myopia of 7 D. in R. and 10 D. in L. at posterior pole with decidedly less at the periphery; his fundus was normal except for moderate myopic crescents; marked night-blindness was demonstrated; he had one child, VI. 1, aged 8, with perfect sight, normal fundus and no night-blindness, she had hm. of 2 D.

IV. 5, daughter of III. 2 by his second wife, had two children, a daughter aged about 20 with normal vision and a son, V. 5, who was night-blind and myopic. V. 5 had been given – 6 D. spectacles by Cant in 1889 when he was aged about 5 and was seen at intervals after this; at the age of 14 R. V. with – 10 D. $= \frac{6}{12}$, L. V. with – 9 D. sph. – 1·5 D. cyl. $= \frac{6}{9}$ partly; he was seen by Usher and Nettleship who demonstrated his night-blindness and noted his normal fundi.

V. 10, a grandson of III. 4, was reported to have been very short-sighted and the mother of V. 5 wrote that "she thought he was afflicted in much the same way as her son"; he died aged 25; he had about six siblings who all saw well. V. 12, a granddaughter of III. 6, was said never to have had good sight and eventually went blind, she was dead and no particulars were known.

IV. 5 and 6 had perfect vision. The parents of V. 5 were known to be unrelated. No consanguinity recorded. Bibl. No. 263, pp. clv—clviii.

Fig. 323. *Nettleship's Case.* Twenty-two males affected with congenital stationary night-blindness in three generations, the only four cases examined were also myopic. I. 1 and 2 were normal and unrelated; they had thirteen children of whom six were females with normal vision, five were of unknown sex, and two sons, II. 6 and 16, were reported to have been night-blind. II. 6 married and had two normal sons, four normal daughters; II. 16 had one normal son, two night-blind sons and two normal daughters. Of the unaffected daughters of I. 1 and 2, the eldest had one normal child, a son; II. 3 had two night-blind sons, one of whom was married and had a normal son; II. 8 had two unaffected daughters, III. 9 and 12, two night-blind sons, one of whom was married and had a normal son, and one unaffected son, III. 15. II. 10 had one unaffected son, three unaffected daughters and four night-blind sons, of whom one was married and had six normal daughters and two night-blind sons; another, III. 19, was examined by the author, he was myopic and had a normal fundus.

II. 13 had three night-blind sons, III. 23—25, and four normal daughters; one of the daughters was married and had one night-blind son and one normal son. III. 24, aged 26, was intelligent; he had a quick lateral nystagmus when looking sideways; colour sense was normal; he had always seen badly at night; with −11 D. R. V. = $\frac{6}{18}$, L. V. = $\frac{6}{36}$; the fundus showed no definite changes except myopic crescents and perhaps some pallor of the discs. III. 25 had high myopia and saw worse at night; his fundus showed no definite changes; he was very excitable, liable to fits and at times became demented.

II. 14 had one normal son, two night-blind sons and four normal daughters.

III. 9 had two normal daughters and two night-blind sons, IV. 3 and 4. IV. 3 was examined three times during a period of several years and the condition was not quite typical in his case; he was intelligent and healthy but saw so badly at night that he was unable to go about alone even in the house; his colour vision was normal; he had myopia of 4·5 D.; the choroid at the central regions was granular and pale as if from disease of the epithelium, also there were some scattered pigment spots of uncertain significance; neither the fundus condition nor the myopia progressed or changed in any way between the ages of 5 to 10 years during which he was under observation. III. 12 had two normal sons, IV. 7 and 8.

The defect in this family was confined to males and was transmitted by affected males and also by unaffected females. No consanguinity recorded. Bibl. Nos. 151, 251, p. 422.

Fig. 324. *Nettleship's Case.* II. 2, seen aged 51, had congenital stationary night-blindness; V. = $\frac{6}{9}$ with and without + 0·5 D. cyl.; his fundi were quite normal except at the lower periphery where he had on the right side one or two small patches of choroidal atrophy and on the left side a good deal of superficial disturbance of the choroid. No signs of hereditary syphilis. He was the eldest son of a father who was affected in the same way and who never became blind. Of his seven children III. 1, a daughter, was normal; III. 2, a night-blind son, had one child aged 2 years; III. 3 represents three living normal members (sex not given); III. 4 represents two children who died. The author was unable to obtain further information. No consanguinity recorded. Bibl. No. 251, pp. 404—6.

Fig. 325. *Cutler's Case.* I. 1, a mason by trade and a very strong and healthy man, who lived to be 80 years of age, suffered from night-blindness all his life; the condition was stationary and in a good light his vision was excellent; nothing was known of his ancestors. II. 2, the only child of I. 1, had good sight, as also had her husband; of her three sons two suffered from night-blindness, and of her four daughters one died in infancy and the other three transmitted the disease. Of the affected sons III. 5 died aged 9 years but had previously been examined by Professor Arlt; III. 8, a mason, was seen aged 46; he was an intelligent man with good health but had always suffered from night-blindness which was stationary; pupils were normal, media clear; the R. fundus was somewhat tessellated, the retinal pigment being uniformly rather scanty but not to a pathological degree; the vessels were perhaps a little narrow; there was no change since he was examined three years previously; colour vision was normal; R. V. = $\frac{6}{12}$ not improved by glasses, L. V. = $\frac{4}{60}$; light sense with Förster's photometer was $\frac{1}{49}$ (minimum opening of 14 mm. compared to 2 mm. for a normal person) with slight improvement after adaptation for 15 minutes; the lower temporal arteries were noted as being rather small relatively to the upper ones. III. 2, who died aged 22 years, was normal. III. 3, who was normal, had four sons, of whom IV. 1, aged 28 years, had myopia of 9 D. but no night-blindness; light sense normal; corrected vision = $\frac{6}{18}$; fundus had some spots of choroiditis. IV. 2 died aged 6; IV. 3 died aged 1 year; IV. 4, aged 21, had always been night-blind and near-sighted. R. V. finger counting, with −9 D. = $\frac{6}{24}$, L. V. $\frac{6}{60}$, with −9 D. $\frac{6}{24}$; he had a quick lateral nystagmus; pupils normal; central colour sense normal; light sense defective; fundus as in the case of his uncle III. 8. III. 6, herself normal, had two daughters who died in infancy, one son, IV. 5, who died aged 7 years and was believed to be normal and one son, IV. 6, aged 13, who was night-blind and had myopia of 2 D.; his light sense was $\frac{1}{36}$ after adaptation; corrected vision was $\frac{6}{18}$; fundus was normal except for a crescent and an oval disc. III. 8 had two sons and three daughters, all of whom were normal. III. 10 had two normal daughters and one son, IV. 12, aged 18, who was night-blind and slightly hypermetropic; V. = $\frac{6}{12}$ to $\frac{6}{18}$; central colour sense normal; light sense $\frac{1}{25}$ after adaptation; fundus normal. No consanguinity. Bibl. No. 182.

PLATE XXV. Fig. 326. *Pflüger's Case.* Seventeen cases of congenital stationary night-blindness in males only, invariably associated with myopia and nystagmus, and transmitted through unaffected females in four generations; in one woman, IV. 4, and four men, IV. 28, 30, V. 10 and 22, myopia was noted without night-blindness. Only two of the cases were examined; a male, aged 40, in generation IV. had myopia 6 D., corrected V. $= \frac{6}{18}$, R. convergent strabismus, varying rotatory nystagmus, colour sense normal, light sense much lowered, fundus normal except for a crescent down-out equal in size to O. D. A child aged 3, in generation V., was examined but notes of the case were missing; he had nystagmus and very severe night-blindness with no decided ophthalmoscopic changes. No consanguinity. Bibl. No. 124.

Fig. 327. *Nettleship's Case.* Two cases of congenital stationary night-blindness associated with myopia in brothers; the family history was fully worked out for five generations, a considerable amount of myopia was reported in other members of the stock but no further cases of night-blindness. The parents of the affected sibship were first cousins.

IV. 2, aged 47 (1900), had been night-blind all his life; he was myopic and began to use glasses at about the age of 12, he had -7 D. since the age of 25 but now had myopia of 9 D.; V. $= \frac{6}{6}$; fields were full in daylight but there was a slight concentric contraction in very dull artificial light after 15 minutes adaptation; photometer after 5 minutes adaptation showed light sense of $\frac{1}{50}$; colour vision good; teeth good, no signs of hereditary syphilis; fundi were perfectly normal except for myopic crescents; the night-blindness was not getting worse. The elder brother of IV. 2 was also night-blind and the younger brother, IV. 4, who died aged 39 and had very good vision, used to lead his affected brothers at night when they were boys; their two sisters, IV. 5 and 7, were not night-blind but IV. 5 was slightly short-sighted.

Short-sight was noted in the father, III. 3, and two of his brothers, also in his mother, II. 4, and in four other members of the stock, III. 10, IV. 14, 16 and 17. Consanguinity. Bibl. No. 251, p. 421.

Fig. 328. *Fuchs' Case.* (Published by Nettleship.) Night-blindness in three brothers associated with myopia in at least one of them. II. 1, aged 39, had well-marked night-blindness which had been noticed in very early childhood; refraction, myopia $-4{\cdot}5$ D. for right, $-3{\cdot}5$ D. for left, corrected V. $= \frac{6}{24}$; fields for white were full in a good light, a little contracted in a dim light; fundus normal. His two brothers were said to have the same defect but no statement is made as to their refraction. No mention is made of any normal members of the sibship. The parents had good vision; they were distantly related. Consanguinity. Bibl. 251, p. 416.

Fig. 329. *Förster's Case.* Congenital night-blindness in two brothers. II. 1 was seen aged 14 years, he had perfectly good sight in daylight but in the evening or a dull light needed to be led about by a guide; his fundus was normal and his visual fields full in a good light and only slightly contracted in a dull light. His brother, II. 2, was similarly affected whilst his other siblings and his parents had normal sight. No consanguinity recorded. Bibl. No. 37.

Fig. 330. *Donders and Maes' Case.* Congenital stationary night-blindness in a father and three of his sons; two younger sons and one daughter had normal sight. III. 1 was examined by Donders in 1854 when he was aged 16, he suffered from very pronounced night-blindness. III. 3 was examined by Maes in 1861 when he was aged 19; his vision was good in daylight and ophthalmoscopic appearances were normal; his night-blindness was less severe than that of his brothers. The parents were related "in the sixth degree." The father, II. 3, aged 58 in 1861, had suffered from stationary night-blindness since his youth. Consanguinity. Bibl. Nos. 33, 43.

Fig. 331. *Maes' Case.* Congenital stationary night-blindness in three brothers whose six sisters had normal vision; the parents and grandparents were normal and unrelated; several children of a maternal aunt were also said to be affected with the same disease but their mother had normal vision. One case only was examined, he a schoolmaster, had myopia of $\frac{1}{10}$, was night-blind and had a slight bilateral rotatory nystagmus. Ophthalmoscopically he showed signs of a commencing atrophy of the choroid and retina, there were no perceptible changes at the yellow spot. No consanguinity. Bibl. No. 43.

Fig. 332. *Ammann's Case.* Congenital night-blindness in five generations of the type that is confined to males and transmitted only through the unaffected females. Information of the family was scanty, for one case only, VI. 3, was examined; he had myopia of 9 D. and said that all the night-blind members of his family were also short-sighted and that all who saw well at night had ordinary sight. The family ancestor, Andreas Steiner, 1750—1838, I. 1, had good sight; nothing was known of his or his wife's ancestry; he had two night-blind sons and one normal daughter who transmitted the defect to all her three sons, and of her two normal daughters one who married transmitted the defect to two of her four sons; the children of the night-blind son, II. 2, were all normal but the two daughters who married transmitted the defect in the one case to an only son and in the other case to one out of four sons, the other three being normal. In generation V. there were four individuals affected and two normal males in an affected sibship. In generation VI. there was only one night-blind male, VI. 3, who was examined by the author; he had two normal brothers. The pedigree as here given is taken from an extension, with slight alteration, of the original pedigree as communicated by the author to Nettleship (see Bibl. No. 251, p. 415). No consanguinity recorded. Bibl. No. 197.

SECTION VI

GLIOMA RETINAE

(*a*) GENERAL ACCOUNT

Only a very brief account will be given here of the chief characteristics of glioma retinae; the subject is of great importance to the clinician but has been of no very great interest from the point of view of the student of heredity, because inherited cases are extremely rare and such family histories of the condition as exist are scanty and only in a few cases does knowledge extend beyond the single sibship with its parentage. Until recent times the condition was almost invariably fatal at a very early age and no family with a liability to the disease would be at all likely to survive; with the multiplication of hospitals and clinics, the great advance in surgical technique and the increased skill and knowledge which lead to an earlier diagnosis the fatality has become markedly reduced until now we know that provided the child is operated on early enough recovery may be expected. It is true that survival for the victims of glioma retinae inevitably involves the loss of one or both eyes but this deformity is not invariably a bar to marriage as we see from Figs. 333, 336—338, 340—343, 345 and 361 of Plate XXVI; indeed so active to-day is the instinct to protect those who have a serious handicap in life that marriage may come rather readily to these victims, and in every one of these cases in which an affected member survived and married the disease has reappeared in the next generation. It is possible of course that these cases were published because the affected offspring occurred and so the family came again into the hands of the medical profession; it would be of great interest to hear of cases in which affected members who have survived and married have had only normal offspring. Further, glioma retinae in an individual is to-day regarded as no bar to the marriage of his unaffected siblings or of other more remotely related members of his stock and yet a glance at Figs. 334, 335, 339, 342, 344 and 366 is enough to raise grave doubts as to whether any member of a sibship in which more than one member is affected ought to marry; added to this the observation that in certain sibships the disease is of such remarkable dominance, as for example in Fig. 349, where all the eight children of a sibship were affected, or in Fig. 339, where ten children of a sibship of sixteen died from the disease and two of the remaining six siblings died in infancy from other causes, brought before us the necessity for a review of all available material if we would avoid the occurrence of suffering in the next generation as a result of the application of the increased skill and knowledge in this. Accordingly we decided to search through the literature and collect for this volume all cases recorded in which more than one case had occurred in the same stock. The disease is rare and, on the basis of frequencies given by Wintersteiner, Adam, Vetsch, Plant, von Graefe, Trantas, Caspar, Stieren, Lowtzow and Alvarado, probably accounts for not

more than ·03 °/₀ of all patients suffering from disease of the eyes, so that multiple cases in the same family become of great significance.

Glioma retinae is a new growth of the retina which occurs exclusively in very young children and is malignant in that it infiltrates surrounding structures, may extend by proliferation of the primary growth, by continuity along the optic nerve to the brain or may be widely disseminated by means of the lymph channels or blood stream forming metastases in the glands, bones or occasionally distant organs of the body. The condition has been variously described in the literature of the subject under the title of *fungus medullaris oculi*, *fungus haematodes*, encephaloid degeneration of the retina, *carcinoma oculi*, *cancer atrophicus oculi*, *medullary sarcoma retinae*, glio-sarcoma, neuro-epithelioma and neurocytoma, names which collectively suggest many of the fundamental characteristics of the tumour which is of rapid growth, may be extremely haemorrhagic and of a soft or spongy consistency; superficially the microscopic appearance of the tumour resembles that of a small round-celled sarcoma but on close examination of a fresh specimen the cells of glioma retinae are discovered to be peculiar to it and to differ from those of sarcoma, they possess large nuclei and relatively very little cytoplasm which in a fresh specimen appears to be drawn out to form long thin interlacing processes or fibrils; the cells tend to occur in ring-like formation, typical of the condition, which have come to be known as 'rosettes'; the name of glioma retinae was given to this growth by Virchow[1] from the belief that it originated in the connective tissue of the retina and was therefore comparable in nature to the cerebral glioma which originates in the neuroglia of the brain, but Treacher Collins[2] has pointed out that the tumour is composed of cells which resemble those of which the whole retina is composed in the third month of foetal life before the differentiation of its layers, and it has been suggested that neurocytoma or neuro-epithelioma is the more applicable name for the condition which is possibly due to misplacement of retinal cells during foetal life, these cells retaining their primitive character and subsequently multiplying to form a parasitic growth.

We should like to quote from the description of a case by Hayes[3] in 1767 as illustrating the entire lack of recognition of the condition at that time by even so close an observer as John Hunter: the patient was a child aged 3 years who was brought to Hayes with an affection of both eyes in 1764, some defect having been first noticed by the parents in the left eye when the child was aged 15 months; Hayes was puzzled by the case and consulted with John Hunter and other surgeons—he says "None of them however pretended to understand the case..."; a foreigner who had obtained great reputation as an oculist was then consulted, "he giving the most confident assurances of restoring the right eye and even some hopes of retrieving the other, she was put under his care. He said it was a liquefaction of the crystalline humour, a case he had often met with, but after two months' strict perseverance in a very whimsical course of medicine the patient grew much worse...." Hayes then operated in the presence of John Hunter, he "passed a needle as for cataract operation thinking the condition was due to an excess of secretion," but then the true position became evident and

[1] Bibl. No. 13. [2] Bibl. No. 46. [3] Bibl. No. 3.

Hunter removed the eye. The child died a few months later and the *post-mortem* examination is described. This case is of rather special interest from its association with John Hunter, it is not however the earliest case which may be identified as belonging to our subject; Paw[1] for example describes a case, with subsequent *post-mortem* examination, of a tumour the size of two fists protruding from the left eye of a boy aged 3 years seen in 1597.

In 1809 Wardrop[2] discusses 17 cases of glioma retinae which he has collected, he describes the external appearances and the appearance on dissection and distinguishes between this condition and cancer[3]; he notes that in every case, which he has seen or heard of, all treatment including extirpation had been unavailing except a doubtful instance in a woman aged 58 (and we know now that this was certainly not glioma retinae) which had not recurred after 10 months. He adds that in no case had the eye been extirpated in the very early stages—a very significant and important observation as we now know; for if the course of the disease may be regarded as passing through three stages—Stage I in which the eye is blinded and a whitish or golden yellow reflex is seen in the pupil[4] due to the growth behind the lens, Stage II in which the intra-ocular tension is raised and the eye becomes painful, Stage III in which the growth spreads along the optic nerve or through the cornea—the probability of cure appears to be almost entirely dependent upon the stage at which operation is performed, as is well illustrated by Adam's[5] analysis of 43 cases treated by him as follows:

Stage of disease	No. treated	No. cured	No. in whom there was recurrence
I	5	5 = 100 °/₀	0
II	14	12 = 85·7 °/₀	2 = 14·3 °/₀
III	16	1 = 6·3 °/₀	15 = 93·7 °/₀
?	8	6 = 75 °/₀	2 = 25 °/₀

Much has been written on the subject of glioma retinae, frequent reference is made to the fact that multiple cases are known to occur in the same family and several extremely valuable attempts have been made to collect all the available material on the subject and to give statistical information as to the sexual incidence, age of onset, distribution of metastases when they occur, cure and recurrence of the disease and bilateral or unilateral nature of the disease; we would specially refer to the works of the following writers—Hirschberg[6], Vetsch[7], Lawford and Collins[8], Marshall[9], Wintersteiner[10], Adam[11], and Berrisford[12]; these authors consider the disease as a whole, paying no special attention to the hereditary cases.

[1] Bibl. No. 1. [2] Bibl. No. 5.

[3] Hey, writing to the editors of the *Medical and Physical Journal* in 1804, says that fungus haematodes is described as a spurious aneurysm by one surgeon and that another gentleman considers it a species of cancer but that both are wrong.

[4] An appearance described by Beer as 'amaurotic cat's eye.' [5] Bibl. No. 44.

[6] Bibl. Nos. 17, 18. [7] Bibl. No. 24. [8] Bibl. No. 27. [9] Bibl. No. 30.

[10] Bibl. No. 31. [11] Bibl. No 44. [12] Bibl. No. 50.

We have been able to collect 36 small family histories of glioma retinae from the literature giving records of 128 cases, each of which belongs to a stock in which one or more further cases of the disease occurred; the history is in many cases extremely scanty, the sex of the individual not being given nor his age at the time of onset, nor whether or no he had normal siblings; we have however from the severity of the condition the assurance that the diagnosis is in all cases almost certainly a correct one and that cases are very unlikely to have been screened.

The age of onset of glioma retinae is very indefinite so far as actual age in years or months is concerned; we are frequently told the age at which the parents first noticed that all was not well with the child, but observation of their children's welfare differs greatly from parent to parent; in other cases we are only told the age at which the child was first taken to the doctor, which again gives little indication of the age of onset of the disease or the length of time during which it has been progressing; several authors[1] have given age frequency distributions but we feel that all that we can insist upon is that the disease is one of infancy or early childhood, that it may already be present at birth and that only very rarely does a case occur later than the age of 7 years.

On looking through our histories for evidence of associated disease in the affected or unaffected members of our stocks, we find no significant relationships and repeatedly the affected child is described as being healthy and well-developed in all other respects; there is no evidence suggesting that other forms of malignant disease tend to occur in these stocks, a mother of affected members may be seen to have died from cancer of the breast in Fig. 335, Fig. 360 shows a father who died from cancer of the stomach, Fig. 366 a father who died from sarcoma of the thorax, but considering the great prevalence of malignant disease in the general population we cannot feel that these cases have any special significance; the case of coloboma of the choroid and iris in Fig. 363 in the normal sibling where two brothers had glioma retinae is suggestive but other pedigrees give no support to the theory that other congenital defects or anomalies might reasonably be looked for in association with glioma retinae. The stillborn babies of Figs. 343 and 345 are again suggestive, but on examination we can find no evidence of any specially high rates of stillbirth or of infant mortality in the recorded families.

With regard to consanguinity in parentage and its effect upon the production of glioma retinae we have no knowledge, in only two of the families has any statement on the subject been made and in neither case was consanguinity present; we are thus unable to make any statement as to whether consanguinity in parentage is a significant factor in the etiology of glioma retinae.

Our material again is too scanty to allow us to make any statistical statements concerning the sex incidence of the disease, the frequency and relative mortality of its bilateral or unilateral nature and the proportions of affected and unaffected in the sibship. We have in actual numbers an excess of males affected, but we cannot insist

[1] For example see Adam, Bibl. No. 44. Vetsch, Bibl. No. 24. Berrisford, Bibl. No. 50.

upon this excess on the basis of so small a sample; further we have a considerably higher proportion of bilateral affections in our hereditary cases than is given by Berrisford for his presumably chiefly isolated cases; but again this point is very indefinite for though the bilateral cases may be regarded as positive information the unilateral reports merely indicate that bilateral affection had not occurred, and in some cases all that this can be taken to mean is that when death intervened no affection of the second eye had yet appeared; we should need far more information and a consideration of the death-rates in the two groups before we could insist upon an excess of bilateral affections in hereditary cases.

It is hoped that the few pedigrees we have been able to collect showing the heritable nature of glioma retinae in certain stocks may stimulate more interest in this aspect of the disease, and that observers who meet with multiple cases in the same stock will endeavour to keep such families under observation and report upon their subsequent histories, inquiring always for information concerning collateral branches of the family.

(β) BIBLIOGRAPHY

This bibliography gives full references to all hereditary cases of glioma retinae found in the literature and to authors referred to in the text.

1 Paw, P. Observationes Anatomicae Selectiores. Hafniae, 1656. Obs. xxiii. Tumor oculorum. "Anno 1597 die 7 April. Praesentibus Chirurgis M. Johanne Simonis & Alberto, puerulo trienni aperui caput. Hic aliquot mensibus ingenti laborarat tumore ex oculo sinistro, adeo quidem ut integer bulbus ocularis cum musculis omnibus foras protuberaret in tantamque accrevisset molem ut duos pugnos protuberantia aequaret. Huic duabus ante mortem septimanis alius tumor ortus fuerat, prope musculum temporalem sinistrum quem ablata cute vidimus peculiari (eaque crassa satis) membrana obductum intra cutem craniumque haerere. Cranium exiguum habebat foraminulum, per quod materiam ejecerat natura. Ablato cranio vidimus ocularis tumoris materiam intra cranium & duram matrem collectam universam integro plane & illaeso cerebro. Aperto utroque tumore vidimus eos substantia cerebro plane simili repletos, permixto sanguine concreto, haud aliter ac si molae substantiam vidisses." This is the earliest description found which we think may be taken to refer to a case of glioma retinae.

2 Bidloo, G. Exercitationum Anatomico-chirurgicarum Decades duae. Lugdun. Batavorum, 1708. See chapter on "oculi prolapsu" pp. 173—179.

3 Hayes. The Case of a diseased Eye. *Medical Observations and Inquiries.* Vol. iii., pp. 120—137. London, 1767.

4 Ford, E. A Case of Proptosis. *Medical Communications.* Vol. i., pp. 95—100. London, 1784. The author describes a case of glioma retinae in a girl aged 3 years; the eye was extirpated but recurrence and death followed in 1781; a detailed account of the *post-mortem* examination is given and metastases in the brain are described.

5 Wardrop, J. Observations on Fungus Haematodes. Edinburgh, 1809.

6 Beer, J. Lehre von den Augenkrankheiten. Wien, 1817.

7 Maunoir. Mémoire sur le fongus médullaire et hématode. Paris, 1820.

8 Lerche, W. Merkwürdige Entartung des linken Augapfels bei allen männlichen Kindern einer Familie. *Vermischte Abhandl. aus dem Gebiete der Heilkunde.* Bd. i., §§ 188—196. St Petersburg, 1821. See Fig. 350. This gives the earliest family history of glioma retinae which we have found recorded.

9 Bauer, F. Dissertation sur le fongus médullaire de l'œil. Paris, 1830.

10 Lawrence, W. A Treatise on the Diseases of the Eye. London, 1833. A very interesting account of fungus haematodes is given, pp. 604—635. The author distinguishes between the melanotic sarcoma of the choroid in adults and the fungus haematodes of children; he reports that extirpation of the eye even at an early period is unavailing.

11 Middlemore, R. A Treatise on the Diseases of the Eye and its Appendages. London, 1835. Describes a case of glioma retinae in two sisters: the first case was born 1832 and at the age of six months the disease was first noticed, the child died 1835 with growths on her head and neck; the second sister born in November, 1833, was noticed to have the same affection early in 1834. Refers also to a familial case of fungus haematodes in Birmingham.

12 Sichel, J. Iconographie Ophthalmologique. pp. 562—588, Pl. lvi, lvii. Paris, 1859. See Fig. 359.

13 Virchow, R. Pathologie des Tumeurs. Translated by Paul Aronssohn. New York, 1869. T. ii., pp. 148—165, discusses the pathology of glioma retinae and suggests this as the name for the condition. Date of original work, 1863.

14 Graefe, A. von. Zur Casuistik der Tumoren. *Archiv f. Ophthalmologie.* Bd. x., Abth. 1, S. 176—220. Berlin, 1864.

15 Calderini, G. Enucleazione del bulbo dell' occhio. *Osservatore Gazzetta delle Cliniche di Torino.* Anno 1867, p. 54. Torino, 1867. We are indebted to Professor Grignolo for an abstract of this paper. See Fig. 356.

16 Graefe, A. von. Zusätze über intraoculare Tumoren. *Archiv f. Ophthalmologie.* Bd. xiv., Abth. 2, S. 103—144. Berlin, 1868. See Figs. 344, 346.

17 Hirschberg, J. Anatomische Untersuchungen über *Glioma Retinae. Archiv f. Ophthalmologie.* Bd. xiv., Abth. 2, S. 30—102. Berlin, 1868. No family histories referred to.

18 Hirschberg, J. Der Markschwamm der Netzhaut. Berlin, 1869.

19 Knapp, H. A case of *glioma retinae*, operated on at an early stage and exhibiting some new and peculiar anatomical conditions. *Archives of Ophthalmology and Otology.* Vol. ii., pp. 36—51. New York, 1871. Describes an isolated case of glioma retinae in a boy aged 8 years with a detailed description of the microscopical appearance of the retina after enucleation had been performed.

20 Wilson, H. Describes a family history of glioma retinae at a meeting of the Pathological Society of Dublin. Reported *British Medical Journal*, April 6. London, 1872. See Fig. 349.

21 Thomson, J., and Knapp, H. Ein Fall von Retinalgliom, klinisch ausgezeichnet durch Familienprädisposition zu Gliom und anatomisch durch die klar nachweisbare Entstehung der Neubildung aus der inneren Körnerschicht. *Archiv f. Augen- u. Ohrenheilkunde.* Bd. iv., S. 79—82. Wiesbaden, 1874. See Fig. 335. Further information was published of this case in 1898. See Bibl. No. 32.

22 Zinke, E. G. Gliosarcoma of the Eyeball. *The Clinic.* Vol. ix., p. 87, and Vol. xii., p. 37. Cincinnati, 1875 and 1877. We are greatly indebted to Dr F. E. Lutz of the American Museum of Natural History for sending us an abstract of these papers. See Fig. 365.

23 Schoenemann, C. Beitrag zur Casuistik des *Glioma Retinae*, pp. 1—20, Inaugural Dissertation. Marburg, 1880. See Fig. 355.

24 Vetsch, U. Glioma of the retina. *Archives of Ophthalmology.* Vol. xii., pp. 43—63. New York, 1883. Describes twenty-three isolated cases and discusses some statistics of glioma retinae.

25 Macgregor, A. Glioma of retina. Three cases in a family of five. *Medical Times and Gazette.* Vol. ii. for 1885, pp. 45, 46. London, 1885. See Fig. 358.

26 da Gama Pinto, J. R. Untersuchungen über intraoculare Tumoren. Netzhautgliome. Wiesbaden, 1886.

27 Lawford, J. B. and Collins, E. Treacher. Notes on *Glioma Retinae* with a report of 60 cases. *Royal London Ophthalmic Hospital Reports.* Vol. xiii., pp. 12—37. London, 1890. These authors had no instance in which more than one member of the family had suffered from glioma of the retina.

28 Brown, J. F. Glioma of the retina, with a history of three cases in one family. *Journal of Ophthalmology.* Vol. iii., pp. 151—154. New York, 1891. We have to thank Dr F. E. Lutz of the American Museum of Natural History for a copy of this paper. See Fig. 347.

29 Flexner, S. A peculiar glioma (neuroepithelioma?) of the retina. *Johns Hopkins Hospital Bulletin.* Vol. ii., No. 15, pp. 115—119. Baltimore, 1891. See Fig. 298.

30 Marshall, C. D. Notes on *Glioma Retinae. Royal London Ophthalmic Hospital Reports.* Vol. xiv., pp. 456—477. London, 1897. See Fig. 299.

31 Wintersteiner, H. Das Neuroëpithelioma Retinae. Leipzig u. Wien, 1897. See Fig. 357.

32 Thompson, J. L. Glioma of the retina. *Journal of American Medical Association.* Vol. xxxi., pp. 628—632. Chicago, 1898. See Figs. 335, 364.

33 Steinhaus, J. Zur Kenntniss der Netzhautgliome. *Centralblatt f. Allgemeine Pathologie u. Pathologische Anatomie.* Bd. xi., S. 257—262. Jena, 1900. See Fig. 334.

34 Maher, W. O. Glioma of the retina. *The Australasian Medical Gazette.* Vol. xxi., p. 413. Sydney, 1902. See Fig. 362.

35 Newton, R. Earle. Glioma of retina. A remarkable family history. *The Australasian Medical Gazette.* Vol. xxi., pp. 236, 237. Sydney, 1902. See Fig. 339.

36 Snell, S. Glioma occurring in two members of the same family, in one instance (fatal) both eyes being affected. *Trans. of Ophthalmological Society of United Kingdom.* Vol. xxiv., pp. 230—233. London, 1904. See Fig. 348.

37 Fuchs, E. Glioma of the Retina. *Text-Book of Ophthalmology.* 2nd American Edition, pp. 464—467. London, 1905. See Fig. 363.

38 Owen, S. A. *Glioma Retinae. Royal London Ophthalmic Hospital Reports.* Vol. xvi., Part iii, pp. 323—369. London, 1905. See Fig. 342.

39 Snell, S. A further instance in which glioma occurred in more than one member of the same family. *Trans. of Ophthalmological Society of United Kingdom.* Vol. xxv., pp. 261—266. London, 1905. See Figs. 341, 354.

40 von Hoffmann. Report of an interesting case of inherited *Glioma Retinae.* Given at the 35th meeting of the German Ophthalmological Society at Heidelberg 1908. Reported *Archives of Ophthalmology.* Vol. xxxviii., p. 45. New York, 1909. See Fig. 340.

41 Seefelder, R. Über Anomalien im Bereiche des Sehnerven und der Netzhaut normaler fötaler Augen, ein Beitrag zur Gliomfrage. *Archiv f. Ophthalmologie.* Bd. LXIX., S. 463—478. Leipzig, 1909.

42 Gouvea, H. de. L'hérédité des gliomes de la rétine. *Annales d'Oculistique.* Vol. CXLIII., pp. 32—35. Paris, 1910. See Fig. 338.

43 Stieren, E. A report of three cases of *Glioma Retinae*. *Ophthalmic Record.* Vol. XX., pp. 113—118. Chicago, 1910.

44 Adam, C. Statistisches, Klinisches und Anatomisches über das *Glioma Retinae*. *Zeitschrift f. Augenheilkunde.* Bd. XXV., S. 330—350. Berlin, 1911. See Figs. 351—353.

45 Caspar, L. Ein Fall von vererbtem Netzhautgliom. *Centralblatt f. praktische Augenheilkunde.* Bd. XXXV., S. 161—163. Leipzig, 1911. See Fig. 336.

46 Collins, E. T. and Mayou, M. S. An international System of Ophthalmic Practice, pp. 115—121. London, 1911.

47 Wehrli, E. Zu den Seefelderschen "Urformen der Gliomes" und zur Gliomgenese. *Archiv f. Ophthalmologie.* Bd. LXXIX., S. 166—179. Leipzig, 1911.

48 Hansell, H. F. A case of bilateral glioma of the retina. *American Journal of Diseases of Children.* Vol. IX., pp. 485—489. Chicago, 1915. Describes an isolated case with no family history but emphasises the importance of heredity as an etiological factor.

49 Purtscher, D. Zur Kenntnis des Markschwamms der Netzhaut und seiner spontanen Rückbildung. *Centralblatt f. praktische Augenheilkunde.* Bd. XXXIX., S. 193—206. Berlin, 1915. See Fig. 366.

50 Berrisford, P. D. Statistical notes on *Glioma Retinae* with a report on forty-one cases. *Royal London Ophthalmic Hospital Reports.* Vol. XX., pp. 296—331. London, 1916. See Fig. 342.

51 Haas, H. K. de. Een geval van glioom. *Nederlandsch Tijdschrift voor Geneeskunde.* J. 52, bl. 1529. Amsterdam, 1916. See Fig. 361.

52 Hester, J. H. Glioma of the Retina. *Pediatrics.* Vol. XXVIII., pp. 193—197. New York, 1916. Describes an isolated case and refers to the familial nature of the disease.

53 Dimmer, F. Einen Fall von doppelseitigem Netzhautgliom. *Münchener Medizinische Wochenschrift.* Bd. LXIV., S. 23. München, 1917.

54 Griffith, A. Hill. Hereditary Glioma of the Retina. *Trans. of Ophthalmological Society of United Kingdom.* Vol. XXXVII., pp. 242—247. London, 1917. See Figs. 333, 343.

55 O'Connor, D. F. *Glioma retinae et atrophia bulbi. Archives of Ophthalmology.* Vol. XLVI., pp. 298—311. New York, 1917.

56 Maghy, C. A case of bilateral Glioma of the Retina in a girl twenty years of age in which the second eye was excised after an interval of nearly eighteen years. *British Journal of Ophthalmology.* Vol. III., pp. 337—340. London, 1919.

57 Pockley, F. G. A. Describes a case of hereditary retinal glioma at a meeting of the Ophthalmological Society of New South Wales. Reported in *Medical Journal of Australia.* Vol. I., 6th year, p. 121. Sydney, 1919. See Fig. 337.

58 Traquair, H. M. Hereditary Glioma of the Retina. *British Journal of Ophthalmology.* Vol. III., pp. 21, 22. London, 1919. See Fig. 345.

59 Comas, L. Five cases of Glioma of the Retina in one family. *Journal of American Medical Association.* Vol. LXXV., p. 1664. Chicago, 1920. See Fig. 360.

(γ) INDEX TO CHRONOLOGICAL BIBLIOGRAPHY AND AUTHORS OF PEDIGREES. *GLIOMA RETINAE*

Adam (44, Figs. 351—353).

Bauer (9), Beer (6), Berrisford (50, Fig. 342), Bidloo (2), Boyd (Fig. 364), Brown (28, Fig. 347).

Calderini (15, Fig. 356), Caspar (45, Fig. 336), Collins (27, 46), Comas (59, Fig. 360).

Dimmer (53).

Flexner (29, Fig. 298), Ford (4), Fuchs (37, Fig. 363).

Gouvea (42, Fig. 338), Graefe (14, 16, Figs. 344, 346), Griffith (54, Figs. 333, 343).

Haas (51, Fig. 361), Hansell (48), Hayes (3), Hester (52), Hirschberg (17, 18), Hoffmann (40, Fig. 340).

Knapp (19, 21, Fig. 335).

Lawford (27), Lawrence (10), Lerche (8, Fig. 350).

Macgregor (25, Fig. 358), Maghy (56), Maher (34, Fig. 362), Marshall (30, Fig. 299), Maunoir (7), Mayou (46) Middlemore (11).

Newton (35, Fig. 339).

Owen (38, Fig. 342).

Paw (1), Pinto (26), Pockley (57, Fig. 337), Purtscher (49, Fig. 366).

Schoenemann (23, Fig. 355), Seefelder (41), Sichel (12, Fig. 359), Snell (36, 39, Figs. 341, 348, 354), Steinhaus (33, Fig. 334), Stieren (43).

Taylor (Fig. 341), Thomson (21, 32, Figs. 335, 364), Traquair (58, Fig. 345).

Vetsch (24), Virchow (13).

Wardrop (5), Wehrli (47), Wilson (20, Fig. 349), Wintersteiner (31, Fig. 357).

Zinke (22, Fig. 365).

(δ) DESCRIPTIONS OF PEDIGREE PLATES

PLATE XXVI. Fig. 333. *Griffith's Case.* (Smith family.) Four cases of hereditary glioma of the retina in a sibship of seven. III. 1, John, aged 5 months, 1903, had both eyes removed for glioma; he died, aged 5, after operation for removal of a tumour in R. upper jaw and palate; secondary growths were found in the kidney. III. 2, Ethel, aged 12, 1917, had both eyes normal. III. 3, Lucy, aged 9 months, 1906, had both eyes removed for glioma; she died, 1907, from measles. III. 4, William, aged 9 months, 1908, had both eyes removed for glioma; he died of this disease two years later. III. 5, stillborn. III. 6, Mary Elizabeth, seen 1913, aged 1 week, no glioma was then seen but it had developed 5 months later, left eye first affected and removed, right eye not removed; child died of broncho-pneumonia 8 months later. III. 7, aged 10 weeks, shows no sign of disease yet. III. 2 and III. 7 were bottle fed and the mother ascribes their immunity to this. II. 2, aged 22, had her right eye removed for a "growth" at the age of 9 months. No consanguinity recorded. Bibl. No. 54.

Fig. 334. *Steinhaus' Case.* Glioma retinae in two generations, five individuals being affected. Thus, in generation II, the third, fifth and sixth born members of a sibship of ten were affected. II. 4, a boy, was operated on in 1875, when he was aged 2 years, for glioma of one retina, this was followed a few months later by recurrence and death. II. 6, a girl, was also operated on in 1877 at the age of 2 years for unilateral glioma retinae; there was no recurrence and the other eye remained healthy; the patient was alive and well in 1900. II. 7, a girl, was operated on for unilateral glioma retinae at the age of 7 years; the tumour was in a late stage of development and she died a few weeks after the operation. Nineteen years after the first case occurred, the eldest brother, II. 2, brought up his daughter, aged 4 years, who was found to have a retinal glioma on the left side; the eye was enucleated (1894) and there had been no recurrence or affection of the right eye. Four years later, 1898, II. 2 brought up his 8 months old son having noticed something wrong with the left eye for a week; a small retinal glioma was found and the eye was enucleated; so far there has been no recurrence or affection of the other eye. No consanguinity recorded. Bibl. No. 33.

Fig. 335. *Thomson and Knapp's Case.* This case was first published in 1874 when the parents, II. 1 and 2, had only two children both of whom had glioma retinae. III. 2, aged 1 year, was seen to have glioma retinae in the R. eye; her parents had noticed a metallic shimmer in the pupil of this eye three months previously; they reported that a brother of the patient, III. 1, had had the same disease; thus a reflex was noticed in the pupil of one eye when he was aged 2 years, six months later the globe ruptured and after another five months the child died; his tumour had been very haemorrhagic and bled at the slightest touch.

At this date (1874), a male cousin on the father's side, III. 8, had died of the same disease in the L. eye when he was aged 2 years; and further an aunt of the father had had two children who died of the same disease between the ages of 2 and 4 years. Macroscopic and microscopic descriptions of the tumour in the case of III. 2 are given.

In 1898 further information of this family is published; the parents II. 1 and 2 had then had fourteen children, five of whom had died of glioma retinae; the aunt, I. 3, had had a third child who had died of the disease, and she herself had died of cancer of the breast. A letter from the mother, II. 1, is quoted as follows—"First child affected with cancer of the eye was a boy born in September, 1869, no medical attendant, he died in August, 1871. The second child was a girl born in August, 1872, disease was noticed in the R. eye in 1873, the eye was removed; seven months later cancer appeared in the other eye and she died in August, 1875. The third child, a boy, was born in 1880; he had cancer in one eye at the age of 3 months and died in 1882. The fourth child, a girl, was born in September, 1883; the disease appeared in her R. eye in 1885 and she died in 1887. The fifth child, a girl, was born in 1888; the disease was noticed in her R. eye in 1890; she died in 1891."

The mother also states that she has five normal sons and four normal daughters. No consanguinity recorded. Bibl. Nos. 21, 32.

Fig. 336. *Caspar's Case.* Glioma retinae in mother and daughter. In 1892, II. 2, aged 2 years, had her L. eye enucleated for glioma retinae; she lived to marry and in 1911 her $1\frac{1}{4}$ years old daughter was noticed to have a similar-looking yellow tumour in her right eye. The eye was enucleated and found to be filled with glioma. I. 1, the mother of II. 2, had a large congenital angioma of the L. upper lid and forehead. No consanguinity recorded. Bibl. No. 45.

Fig. 337. *Pockley's Case.* Glioma retinae in an infant of 18 months. The father, II. 4, had both eyes removed for glioma in infancy and two of his sisters had had both eyes removed "for growths" in infancy. The mother, II. 5, was blind in one eye, there was cataract and no projection, she had also a "partial" cataract in her other eye. Her mother, I. 1, was also blind in one eye from an unknown cause. No consanguinity recorded. Bibl. No. 57.

Fig. 338. *De Gouvea's Case.* Glioma retinae in a father and two daughters. I. 1 had enucleation of his R. eye performed for glioma retinae when he was aged 2 years; the result was excellent and he married at the age of 21. He had seven children, of whom the first was normal; the second, a daughter, had

bilateral glioma retinae and died aged 2 years; the third, also a daughter, had bilateral glioma retinae and died aged 5 months, and the remaining four children are alive and healthy. No consanguinity recorded. Bibl. No. 42.

Fig. 339. *Newton's Case.* Glioma retinae in ten members of a sibship of sixteen. II. 1 died at 6 weeks of bronchitis. II. 2, aged 25, alive and healthy. II. 3, aged 23, alive and delicate. II. 4 had glioma of the R. retina with enucleation performed at $2\frac{1}{2}$ years, local recurrence and death occurred a few weeks later. II. 5 had bilateral glioma retinae which caused rupture of the eyeball and death at 3 years. II. 6, aged 19, alive and healthy. II. 7 died, aged 2, of glioma of L. retina with rupture of the globe. II. 8 died, aged 3, of bilateral glioma retinae with ruptured globes. II. 9 had the right eye enucleated for glioma at the age of $3\frac{3}{4}$ years, death occurred at 5 years from a local recurrence. II. 10 died at 9 months of bronchitis. II. 11 died, aged 3 years, of a bilateral ruptured glioma retinae. II. 12 had bilateral glioma retinae and died at $2\frac{1}{2}$ years from cerebral implication. II. 13, aged 8, alive and healthy. II. 14, also II. 15, died, aged 3 years, of bilateral ruptured glioma retinae. II. 16, the patient was brought up by her mother at the age of 2 years with the story that she had appeared to be blind for fully twelve months. Both pupils were occupied by a mass which completely involved the lens and was growing forward into the anterior chamber. The tension was greatly increased, the globes feeling like balls of wood and the pain was intense, there was no evidence of secondary growths; operation was refused on the prognosis being given. One of the father's brothers was said to have died in infancy of some eye complaint the nature of which could not be determined. No consanguinity recorded. Bibl. No. 35.

Fig. 340. *Hoffmann's Case.* Bilateral glioma retinae in a child aged 1 year. The mother, now aged 28 years, had had her right eye enucleated by Hoffmann's father for glioma retinae at the age of 2 years. No consanguinity recorded. Bibl. No. 40.

Fig. 341. *Taylor's Case.* This case was reported by Johnson Taylor during the discussion following a paper by Snell at a meeting of the Ophthalmological Society in 1905. He said that some years ago he had excised a child's eye for glioma retinae, glioma subsequently developed in the other eye and the child died; the mother of this boy had had an eye excised in early life, and he believed that that also had been for glioma. Bibl. No. 39.

Fig. 342. *Owen and Berrisford's Case.* Six cases of glioma retinae in a small pedigree. I. 2, Thomas Grover, had his left eye removed for glioma retinae when 5 months old in 1859; his son, II. 1, Frank Grover, had one eye removed for glioma by Mr Ridley in 1898 at age of 3 years, he remained well till the age of 15 when he died of "paralysis." I. 3, Beatrice Wallbank, sister to I. 2, had eight children of whom II. 2, Nellie, and II. 3, Charlie, had glioma in both eyes and died aged 4; II. 4, Julia, had glioma in one eye and died aged 4 and II. 7, Gordon, had glioma of both eyes and died aged $3\frac{1}{4}$ years. II. 5, were three normal females, II. 6, a normal male. No consanguinity recorded. Bibl. Nos. 38, 50.

Fig. 343. *Griffith's Case.* (Jones family.) Three cases of hereditary glioma of the retina in a sibship of three born alive. II. 1, stillborn. II. 2, Doris, aged 3 (1906), right eye removed for glioma, now aged 13 with left eye normal. II. 3, George, aged 3 years (1907), right eye removed for glioma, now aged 10 with left eye normal. II. 4, Florence, aged 7 (1913), had right eye removed for glioma, her left eye had been previously removed at age of 1 year and 10 months. All children were breast fed. The mother, I. 2, had her right eye removed for glioma in 1879 at age of $2\frac{1}{2}$ years. No consanguinity recorded. Bibl. No. 54.

Fig. 344. *Von Graefe's Case.* Glioma retinae in a child whose parents were apparently healthy, but several siblings of the mother were said to have died of "Augenkrebs" in their first year of life. No further information is given but there can be no doubt that the "Augenkrebs" of the maternal sibship was glioma retinae. No consanguinity recorded. Bibl. No. 16.

Fig. 345. *Traquair's Case.* Glioma retinae in a father and his two children. I. 1 had his left eye removed "for a tumour" at the age of six months; he survived to marry in 1912. Of his children, II. 1, was stillborn in 1913; II. 2 was born 1914, his parents noticed something wrong with his R. eye at the age of six weeks and at eight months the eye was removed. In June, 1916, glioma of the L. retina appeared and the orbit was exenterated in 1917. Metastases occurred all over the body and death supervened in 1918. II. 3 was born 1916, her parents noticed something wrong in her L. eye at the age of six weeks. Operation was refused and death occurred from broncho-pneumonia soon afterwards. No consanguinity recorded. Bibl. No. 58.

Fig. 346. *Von Graefe's Case.* Glioma retinae in two siblings, the other members of the family healthy. No further information is given. No consanguinity recorded. Bibl. No. 16.

Fig. 347. *Brown's Case.* Glioma retinae in three siblings of a sibship of eight. The parents, aged 40 and 42 respectively, are healthy and have good family histories with no record of cancer or tumours in any of their relatives. III. 1 was seen and glioma was presumably diagnosed in the left retina when he was aged 10 months, the eye was not immediately enucleated as had been advised; five months later signs of the same disease appeared in the right eye and shortly after he became totally blind; he died aged 22 months. The next three children were healthy boys. III. 3, another brother, was seen by the author, who diagnosed

glioma retinae of the left eye when aged $3\frac{1}{2}$ years; the eye was enucleated and the child was well and free from any sign of recurrence two years later. III. 4, a boy, was seen aged 29 months to have some trouble with his left eye, he was taken to the doctor two months later and the eye was enucleated, glioma retinae being again diagnosed; ten months later the child was well and showed no signs of recurrence. Since this time a twin boy and girl have been born who remained healthy and showed no sign of eye trouble at the age of five months. No consanguinity recorded. Bibl. No. 28.

Fig. 348. *Snell's Case.* Two cases of glioma retinae in a sibship of three. III. 1 had both eyes affected, the parents refused operation until it was too late and the patient died. III. 3, aged $4\frac{1}{2}$ months, had glioma of right retina. The parents and their siblings were normal. I. 1 alive and healthy, I. 2 died in childbed, I. 3 and 4 cause of death unknown. No consanguinity recorded. Bibl. No. 36.

Fig. 349. *Wilson's Case.* Glioma retinae in eight siblings. Three of the children died from glioma retinae, one died from a tumour at the base of the brain and the remaining four were still alive when the history was reported. No consanguinity recorded. Bibl. No. 20.

Fig. 350. *Lerche's Case.* Glioma retinae in four children of a sibship of seven. The growth occurred in the left eye of three boys and was bilateral in the case of a girl, II. 2. The parents and three daughters were quite healthy. No consanguinity recorded. Bibl. No. 8.

Fig. 351. *Adam's Case.* II. 1 was seen, aged 2 years, with bilateral glioma retinae; a reflex had been noticed in the left eye since birth; the preauricular and submaxillary glands were enlarged; enucleation was performed but the child died three weeks after operation. Two years later a brother, II. 2, aged 2 years, was seen; he also had bilateral glioma retinae which was more advanced in the right eye than in the left; enucleation was followed by recurrence and death. No information of other siblings is given. No consanguinity recorded. Bibl. No. 44.

Fig. 352. *Adam's Case.* Glioma retinae in two brothers. II. 1, seen, aged 2 years, had glioma of the right retina; enucleation was performed and later exenteration of orbit but recurrence and death occurred two years later. II. 2, seen, aged 2 years, had glioma of the right retina, symptoms of which had been present for six months; the orbit was exenterated but recurrence occurred. No information of other siblings. No consanguinity recorded. Bibl. No. 44.

Fig. 353. *Adam's Case.* Glioma retinae in two brothers. II. 1, seen, aged 3 years, had glioma of the right retina with phthisis bulbi of the left eye as a result of septic irido-choroiditis in the first year of life; the R. orbit was exenterated but recurrence occurred and the child died. II. 2, seen, aged 11 months, had glioma of the left retina, a reflex had been noticed in the pupil for several weeks. Enucleation was performed and no recurrence had occurred at the time of the child's death a year later from scarlet fever. No consanguinity recorded. Bibl. No. 44.

Fig. 354. *Snell's Case.* II. 2, aged $2\frac{1}{4}$ years (1905), was brought up by his mother who had noticed a yellow cast in his L. eye since he was aged 3 months and there had been a similar appearance in his R. eye for the last 3 months; the sight was very imperfect in each eye; glioma was diagnosed and both eyes were removed; there had been no recurrence up to date. The mother had had one other child, II. 1, who had had bilateral glioma and had had one eye removed; she died aged $2\frac{3}{4}$ years. The diagnosis was confirmed by microscopic examination. No consanguinity recorded. Bibl. No. 39.

Fig. 355. *Schoenemann's Case.* Glioma retinae in two brothers with four normal siblings and healthy unrelated parents. II. 2 was seen, aged 3 years, with glio-sarcoma of the right eye in an advanced condition, the parents had noticed it two years previously; the tumour was extirpated, but metastases were present and death occurred. II. 3 was seen, aged 10 months, when glioma retinae at an early stage was diagnosed in the left eye; the eye was enucleated and no recurrence had occurred when the child died of diphtheria six months later. No consanguinity. Bibl. No. 23.

Fig. 356. *Calderini's Case.* Glioma retinae in three siblings. II. 3, aged 6, was seen with glioma of the L. retina which had been first noticed eleven months previously; the eye was excised, but the child died four days after the operation of suppurative meningitis. Her two sisters had already died from glioma retinae, one of them after a long illness and the other from a recurrence after operation. Eight siblings remained free from eye disease but died of phthisis. No consanguinity recorded. Bibl. No. 15.

Fig. 357. *Wintersteiner's Case.* Glioma retinae in two siblings. II. 2, seen, aged 2 years, had been blind in his R. eye since birth, the other eye being normal; glioma retinae was diagnosed and the eye enucleated; the boy died a month later of meningitis. A brother was reported to have died of the same disease. The author gives a very full account of the macroscopic and microscopic appearances of the excised eye. No consanguinity recorded. Bibl. No. 31.

Fig. 358. *Macgregor's Case.* Glioma retinae in three members of a sibship of five; the father was living and in good health, the mother died, aged 34, of "disease of the liver and heart." II. 1 had the L. eye removed at the age of 2 years, the tumour recurred in the stump, the R. eye became affected and the child died. II. 2 had the L. eye removed at the age of 3 months, nine months later the R. eye became affected and the child died after a few months. II. 3, aged 6 years, was healthy. II. 4, a boy, aged 4 years, was

seen with a large tumour of the R. eye, the L. eye had been removed at the age of 17 months and it was nearly 2 years later before the R. eye became affected; he died a few days after admission to hospital. II. 5, aged 15 months, had no symptoms of glioma retinae. No consanguinity recorded. Bibl. No. 25.

Fig. 359. *Sichel's Case.* Glioma retinae in four children of a sibship of five. The parents were well and had excellent health and there was no cancer known in the family of either of them. They had already lost two children from "cancer of the eye" when the mother brought up Pierre C., II. 4, aged $3\frac{1}{2}$ years, in 1835 for an affection of his R. eye. The pupil was dilated and immobile, the iris greyish and slightly discoloured, the reflex known as "amaurotic cat's eye" was present and vision was completely abolished. Operation was urged and refused by the parents who had seen recurrence after operation in a former child. When it was too late the parents asked for operation, which was performed and followed by recurrence and death. A detailed account of the autopsy and microscopical appearance of the growth is given. After the death of II. 4 another male child was born. His mother brought him up when he was several months old and his eyes were perfectly healthy. In 1839, when he was aged about 14 months, glioma was noticed in his L. eye. Operation was refused and the condition progressed until the child died. No consanguinity recorded. Bibl. No. 12.

Fig. 360. *Comas' Case.* Five cases of glioma retinae in a sibship of eleven. The affected members were three females and two males of whom only one, a male, was still alive; he, now aged 12, was enjoying good health, though blind, both eyes were enucleated, one at the age of 2 years, and the right eye 6 months later, the resection of the palpebral conjunctiva and suture of eyelids had also been performed. There had been eight enucleations and five operations for recurrence in members of this family. The father died of gastric cancer; the mother and six living children were in good health. No consanguinity recorded. Bibl. No. 59.

Fig. 361. *De Haas' Case.* Glioma retinae in the left eye of a child who had had its right eye enucleated for the same disease three years previously. The author's father had removed the right eye of the child's father for glioma retinae in 1882. No further information concerning the family history is given. No consanguinity recorded. Bibl. No. 51.

Fig. 362. *Maher's Case.* In 1896 the author was consulted about the eyes of II. 2, James H., aged 18 months; he had glioma of the R. retina and the eye was enucleated; a few weeks later the L. eye was enucleated for the same condition. II. 3, Marion H., had both eyes removed for glioma retinae at the age of 2 years. II. 4, Isabella H., had her L. eye removed for glioma retinae at the age of 1 year. All the four children of this sibship were seen by the author at the ages of 8, 7, 5 and $3\frac{1}{2}$ years respectively when they were in excellent health. It is possible that this is the same family as the one described by Pockley in 1919 (see Fig. 337). No consanguinity recorded. Bibl. No. 34.

Fig. 363. *Fuchs' Case.* Glioma retinae in two children of a sibship of three, the third child, II. 3, when seen aged a few months, having a congenital coloboma of the iris downward as well as a coloboma of the choroid. II. 1 was seen when aged 4, and operated on; he died of a recurrence about 6 months later. II. 2 was operated on when aged 2; he died of a recurrence about a year later. No consanguinity recorded. Bibl. No. 37.

Fig. 364. *Boyd's Case.* In a discussion on the family history of glioma retinae presented by Thomson (see Fig. 335), Boyd reports that he had a case, II. 3, whose brother and sister had died of the same disease; his case also died and thus three out of five children in this family had died of glioma retinae. The parents were both healthy. No consanguinity. Bibl. No. 32.

Fig. 365. *Zinke's Case.* Glioma retinae in two brothers. II. 1 was reported to have commenced to squint with the left eye at the age of six months, subsequently loss of vision, protrusion of the eye and sudden death occurred. II. 2 represents three healthy siblings. II. 3 began to squint with the left eye at the age of six months, the condition remained stationary for a year during which time the child appeared to be otherwise in perfect health; an attack of diphtheria was associated with an acute inflammatory condition which developed in the left eye and which did not subside, vision was lost but the child was not taken to a surgeon until he was aged 4 years when there was a large tumour projecting from the orbit and he was suffering severe pain; gradual loss of sight had also been noticed in the right eye and on examination an intra-ocular tumour was found on this side also. The left eye was enucleated but a rapid recurrence and metastases occurred and the child died six months after the operation. The father was dead, cause not stated, the mother was insane. No consanguinity recorded. Bibl. No. 22.

Fig. 366. *Purtscher's Case.* Five cases of glioma retinae in two generations. The father, I. 1, died of sarcoma of the thorax, the mother, I. 2, was healthy. Of their eleven children, II. 1, Karl, aged 32, was normal; II. 2, Ludmilla, was normal, and had three normal children, two boys and one girl; II. 4, Josefa, aged 30, was first examined at the age of 20 (1907), she had seen badly with the left eye in childhood and suffered from severe headaches; her left vision was reduced to finger counting at $\frac{3}{4}$ m. to the temporal side and this was found to be due to a large sharply bounded white area with vandyked edges, in many places pigmented, situated upwards, outwards and below the optic disc; the diagnosis was held to be between

choroiditis and a neoplasm; she was seen again in 1914 and in 1915 was recommended to the Fuchs' clinic in Vienna where a diagnosis of arrested glioma was made; a small atrophic area indicating the same condition was also found in the right eye. II. 5, Josef, aged 29, was normal; II. 6, Thomas, died aged 1 year; II. 7, Johanna, aged 25, was reported to have not very good sight; II. 8, Ella, aged 24, herself normal, had two boys with glioma retinae; II. 10, Hubert and II. 11, Therese, aged 23, were normal; II. 12, Engelbert, died, aged $9\frac{1}{4}$ years, of bilateral glioma retinae and II. 13, Ferdinand, died, aged 2 years and 8 months, of bilateral glioma retinae.

Of the two affected children of Ella, III. 5, Walther, died, aged $3\frac{1}{4}$, of glioma retinae; III. 4, Karl, aged 5, was first seen, aged 4, when his left vision was reduced to finger counting and a yellowish white mass, slightly prominent, occupied the macula region; he was seen at the Fuchs' clinic and an arrested gliomatous process was diagnosed; there was ophthalmoscopic evidence of a similar condition in the right eye. No consanguinity recorded. Bibl. No. 49.

PLATE XXII. Fig. 298. *Flexner's Case.* Glioma retinae in three siblings. II. 1 had an eye enucleated at the age of 6 months for this disease; this was followed by a recurrence and death. II. 2, aged 4 months, had an eye enucleated for glioma retinae which was first noticed by the parents five weeks previously; two weeks after operation the disease appeared in the other eye, the parents refused operation and the child was not seen again. Two years later, II. 3, aged 4 months, was seen with glioma retinae; the parents refused operation and the child died. The author does not refer to any normal siblings. There was no history of malignant disease in the ancestry of the children; the father was alcoholic at one time and had a consequent amblyopia which is the only record of eye disease in the family. The author gives a detailed account of the pathology of the growth in the case of II. 2. No consanguinity recorded. Bibl. No. 29.

Fig. 299. *Marshall's Case.* Three cases of glioma retinae in a sibship of six. II. 6, Ada Lydia W., aged 2 years, was brought up with a history that for about 2 months a whitish appearance had been seen in the right eye; glioma was diagnosed and the eye excised. On examination under chloroform a glioma was seen in the left eye; further operation was refused by the parents and the child died suddenly in convulsions after about 7 months. A white mass was seen inside the eye of II. 1, at about 2 years of age; no operation was performed and she became worse until the eye ruptured and she died in convulsions, aged $3\frac{1}{2}$ years. II. 2 died in convulsions, aged 3 months; eyes not examined. II. 3 had his right eye removed for glioma when aged about 9 months; at the age of 15 years, he had good sight in the left eye and excellent health. II. 4 and 5, aged 9 and 7 years respectively, are normal. No consanguinity. Bibl. No. 30.

PEDIGREE PLATES

NOS. I–XXVI

[Issued by the Galton Laboratory for National Eugenics

JOHN DALTON

BORN 6 SEPT. 1766. DIED 27 JULY 1844

From a copy of the Engraving in the Department of Prints and Drawings, British Museum.

COLOUR VISION AND ITS ANOMALIES

Introductory and Historical. Any attempt to give a complete account of the efforts which have been made throughout the ages to explain the nature of vision and of colours would be quite outside the scope of this work, for the subject is one of great complexity, belonging equally to the physicist, the physiologist, the psychologist, the ophthalmologist, the comparative anatomist and the pathologist, all of whom, or their predecessors, have been at work upon it since a very early date. This book is intended primarily for the student who is interested in the inheritance of colour-blindness, and we propose to give him a skeletal account only of the historical aspect of the subject of colour vision with a brief description of the colour vision of the normal eye, the modification of colour vision under pathological conditions, the phenomena of accidental colours[1] and of congenital colour-blindness.

At the outset of any historical sketch of the subject we think sympathetically with Galen, who says in this connection: "We have now spoken of almost everything concerning the eye except one single matter which indeed I had rather not describe at all, so that neither the difficulty of the explanation nor its length might cause me to be hated[2]"; or again, when we try to arrive at a conclusion concerning the strength or weakness of the theories which have been built up and ever modified in an attempt to make them more consistent with later observed facts, we realise that, though this process has been at work since long before the time of Galen, few of us have much more confidence in the stability of our 'visions' than he had when he said—"Let us not dream too long, O brethren, nor too deeply, lest our beatific visions turn into insufferable nightmares[3]."

We shall consider first the contributions to our knowledge derived from the early Greek writers; for if it be true that Alcmaeon, who lived about 500 B.C., first practised dissection, it can be of little use to consider theories held before that date. In the pseudo-Hippocratean treatise Περί Σάρκων we are told that the connection between eye and brain is formed by a vein passing from the membrane which covers the latter to each of the two eyes and that the substance of the brain is prolonged through this vein into the eyes where it forms the transparent membranes which cover them; in this transparent membrane, we are told, the light and all bright objects are reflected and by this reflexion we see[4]. Surely then, if we consider with certain authorities that these views may be attributed to Alcmaeon, whom we know to have dissected eyes, we may give to him the credit of possibly first realising that the image of objects seen is formed in

[1] See p. 137.

[2] Galen also writes: "I would explain to thee in few words, O thou hideous blasphemer of Nature, if I did not well know that thou would'st contradict when I come to explain the act of vision."

[3] For these picturesque, if free, American translations from Galen see *Bibl.* No. 377. For the original references see *Bibl.* No. 6, Lib. x, Cap. 12.

[4] *Bibl.* No. 299, p. 12; see also Hippocrates, *Omnia Opera.* Francofurti, 1624, p. 253.

the retina and that we only perceive the objects because of the association of the retina with the brain. We find however no recognition of this fact in other early writings, and indeed as recently as 1919 we read in a standard American work[1] that Leonardo Da Vinci first demonstrated that the visual image was formed in the retina; the retina was not so named in the treatise above referred to, but its recognition and fundamental importance to the theory of vision is fully grasped. Leonardo Da Vinci certainly explains more definitely the formation of the image in the retina and its inverted character[2], but he was clearly not the first writer to record the fact.

Early attempts to explain the sensation of colour appear on a first reading to be crude and fanciful, but on further reflection it would seem that we have not really advanced so great a step in our knowledge of the mechanism of colour vision even at the present day; much precision has been acquired in our description of colour vision and its variations, but we are still only able to enumerate theories to explain its mechanism, and a close consideration of our knowledge—that colour is dependent upon the nature of the light reflected from an object which by its stimulation of certain percipient elements in the retina leads to the sensation of colour, not possibly the colour of the light as it left the object, but that colour modified by a variety of conditions such as the character of the media through which the light has travelled outside the eye and its passage through the lens, aqueous and vitreous humours and retina within the eye—will find much analogous to the early conceptions of, say, Empedocles. Empedocles first propounded the doctrine that (i) Like perceives like; (ii) All bodies send forth emanations; (iii) All structures of the body have pores in them. From these premises he deduced that if an emanation from some object fits into a pore of one of the human structures a characteristic perception of the object is produced in the individual; for example, emanations of colour arise which may pass into all the pores of the body but only fit the pores of the organ of vision, and therefore we only see colour with the eye and do not perceive colour with, say, the ear, the pores of which do not fit the emanations characteristic of colour[3]. If we replace the emanations of Empedocles by the reflected light from an object and replace the pores of the eye which fit the emanations by the percipient elements of the retina which are sensitive to light of different wave lengths, we must agree that the fundamental conception of the nature of colour vision held to-day contains much that is in close agreement with the view propounded by Empedocles two thousand years ago.

It appears to the writer that these observations of (?)Alcmaeon and conceptions of Empedocles may well be regarded as the forerunners of our knowledge to-day, though other Greek writers are not without interest in this respect; thus Theophrastus first seems to have recognised variation in visual characters which he explains as follows: "All eyes are not constituted alike of the contrary elements[4]; some have in them more

[1] *American Encyclopedia and Dictionary of Ophthalmology.* Art. 'Vision.'

[2] *Bibl.* No. 39; *Bibl.* No. 7, Ch. cccxvi. [3] Taken from Beare, *Bibl.* No. 299, pp. 14–23.

[4] Early Greek conceptions of vision were largely influenced by three observed factors: (i) the image in the pupil; (ii) the flash of light on pressure of the eyeball; (iii) the presence of fluid in the eye—which were held to demonstrate the presence of an image, fire and water in the eye. Possibly the idea of fire in the eye was fostered by the red seen in some human pupils and the brilliant colours produced by the tapetum in some animals.

fire and less water than others, some less fire and more water, some again have the fire in the centre and others at a point outside this, which affords the reason why some animals see more keenly in the daytime, others by night[1]." Democritus again makes a very astute observation; he discusses in some detail the characters of objects which are associated with different colours and asserts that colour has no objective existence but that the colours of bodies are due to the position of the atoms in them[2].

We should scarcely expect a metaphysician to contribute greatly to the knowledge of his day on a subject requiring for its elucidation a close observation of facts as the basis of reasoning, but it cannot fail to be of interest to consider the contribution of so great a genius as Plato to the theory of colours and colour vision. An examination of Beare's work and of Jowett's translation of Plato's *Dialogues* leads one to the conclusion that Plato contributed nothing to the existing knowledge on the subject, but we would urge that the following passage, taken from Beare, is approaching the recognition of some relation between light and colour. "For the power of seeing may be in the eye, and the man who possesses it may strive to exercise it; also colour may be present in the object, but if a third thing called light be not present the eye can see nothing, the colour must remain invisible"[3]—even though Plato possibly refers to light merely as opposed to darkness and obviously failed to realise that colour was an attribute belonging to light rather than to the object. Further, we owe to Plato in the *Theaetetus* our knowledge of the Heraclitean theory of colours[4]. Theaetetus asks, "Then what is colour?" Socrates replies:

"Let us carry out the principle which has just been affirmed that nothing is self-existent and then we shall see that every colour, white, black, and every other colour, arises out of the eye meeting the appropriate motion and that what we term the substance of each colour is neither the active nor the passive element but something which passes between them and is peculiar to each percipient; are you certain that the several colours appear to every animal—say, to a dog—as they appear to you?"

"Indeed I am not," replies Theaetetus[5]. Again,

"When the eye and the appropriate object meet together and give birth to whiteness and the sensation of white which could not have been given by either of them going to any other object, then, while the sight is flowing from the eye and whiteness from the colour-producing element, the eye becomes fulfilled with sight, and sees and becomes not sight but a seeing eye; the object which combines in forming the colour is fulfilled with whiteness and becomes not whiteness but white, whether wood or stone or whatever the object may be which happens to be coloured white[6]."

In the same dialogue we find: "But now, since not even white continues to flow white and the very whiteness is a flux or change which is passing into another colour and will not remain white, can the name of any colour be rightly applied to anything[7]?" It would seem then that we at any rate owe to Plato the first suggestion, taken possibly from Heraclitus, that individual colours do not necessarily appear the same to all people. May we take this as an indication of the recognition of colour-blindness in his day?[8] And further, Plato seems to have first raised the question of the existence and character

[1] *Bibl.* No. 299, p. 20. [2] *Bibl.* No. 299, p. 37. [3] *Bibl.* No. 299, p. 48.
[4] The writer has been unable to find any account of the Heraclitean theory of colours elsewhere.
[5] *Bibl.* No. 1, Vol. III, p. 375.
[6] *Bibl.* No. 1, Vol. III, p. 378. See also Greenwood (*Bibl.* No. 341), to whose work we are here indebted for references. [7] *Bibl.* No. 1, Vol. III, p. 407.
[8] We fear not, but we feel that the statement might well have led Plato's followers to a recognition of the facts.

of the colour sense in animals; we find ourselves more in sympathy with his hesitancy on this point than with the rather crude statement of Aristotle: "All other animals[1] are endued with the perception of colours, sounds, smells and taste[2]." Plato's discussion on colours in the *Timaeus* is much less interesting and suggestive; he describes the mixture of certain colours and concludes:

"There will be no difficulty in seeing how other colours are to be mingled and assimilated in accordance with probability. He however who should attempt to test the truth of them in fact would forget the difference of the human and divine nature. For God only has the knowledge and also the power which are able to combine many things into one and again dissolve the one into many. But no man either is or will be able to accomplish either of these operations[3]."

And now, a few words about Aristotle's theories of colour and colour vision. Here we set out expecting to find a marked advance, for we have a great master in observational methods applying his genius to all natural phenomena; yet we find it difficult to say exactly in what his contribution to the knowledge of our subject consists. Truly he insists upon an association between light and colour when he says, "In order to understand colour we must obtain a true view of the medium of vision—light[4]," and again, "Colour is a phenomenon in light[5]," but then we do not know what he held to be the nature of light; he discountenanced the view held by many of his predecessors that light issued from the eye[6], asking, "If this were so, what is darkness?" but, he states, "Light is a presence and therefore they are wrong who like Empedocles suppose it to move locally and come by a process unperceived by us through successive places from the sun to the earth. Reason and observation are both opposed to this view[7]." Aristotle also was fully alive to the phenomena of reflexion: "Reflexion is an important mode of the production of colours[8]"; and again, "All phenomena of illumination by fire or light are explained by the reflexion of light, a matter of which the ancients were very ignorant...reflexion is always and everywhere taking place[9]"; and many other examples might be quoted. Thus one feels regretful that having reached so far he did not advance a step farther and definitely recognise that the colour of an object depends upon the nature of the light reflected from that object. Aristotle further did valuable service in reviewing and criticising the theories of colour and colour vision set up by previous writers, and, as we shall see later when we consider accidental colours, he first appears to have noticed such phenomena as the effects of contrast and after-images; his observations in this respect, however, are curiously incomplete.

Much was known at an early date of the nature and laws of reflexion and of the general nature of refraction; thus Cleomedes, probably in the first century B.C., noted that a ring at the bottom of an empty vessel which was invisible to the eye became

[1] The mole is excepted. [2] *Bibl.* No. 3, p. 91. [3] *Bibl.* No. 1, Vol. II, p. 562.
[4] *Bibl.* No. 299, p. 57. [5] *Bibl.* No. 299, p. 58.
[6] John Heath, as late as 1610, writes:

"It must be questioned in philosophy
Whether the sight thats resiant in the eye
Be first by sending out those radiant streames
Or els by taking in reflexed beames.
Might I, with my poore skill, resolve the doubt,
I should determine 'twere by sending out.
So nimbly doe we others faults discrie,
So blind we are when we looke inwardly." *Bibl.* No. 11.

[7] *Bibl.* No. 299, p. 58. [8] *Bibl.* No. 299, p. 65. [9] *Bibl.* No. 299, p. 66.

visible on filling up the cup with water, and he advocated the possibility of the sun remaining visible after it had set below the horizon[1]. Pliny observes: "If a thick plate of this metal (silver) is highly polished and is rendered slightly concave, the image or object reflected is enlarged to an immense extent[2]"; and again: "We find that globular glass vessels filled with water when brought in contact with the rays of the sun become heated to such a degree as to cause articles of clothing to ignite[3]." Ptolemy discusses vision and reflexion at plane and concave mirrors and measures angles of refraction[4], but it was not until many centuries later that the laws of refraction were discovered.

It is impossible in a work which must be limited to trace in any detail the development of theories of colour vision throughout the ages; we therefore propose to pass over the centuries after Aristotle until we come to the 17th century with its outstanding feature —the work of Isaac Newton; but before doing so we should like to express our gratitude to the late Professor Beare, from whose valuable work so many of the foregoing quotations have been taken.

We leave then the early Greek writers with the knowledge that colour is a phenomenon of light, hinting that individual colours do not appear identical to all people and beginning to consider problems concerning the colour sense in animals. We have not found that any of these writers with their, in some cases, exceedingly acute powers of observation ever definitely noted a ray of white light to be split up into its component rays of diverse colours; nevertheless we feel that they have given a definite lead to the physical, the physiological, the psychological and the anatomical aspects of the subject. In the centuries which follow, progress in knowledge of the physical aspect of the subject largely predominates and indeed it is only in relatively recent times with the development of minute anatomy and experimental biological research that the other aspects of the subject have received a corresponding impetus to progress. To the student who is sufficiently interested and has the requisite leisure to follow the track farther in the earlier centuries of our era we recommend the works of Alhazen[5], of Persian origin, of Battista della Porta[6], of Kepler[7] and of Aguilon[8].

The 17th century marks a period of great activity in all branches of science, and one notes the names of many individuals such as Descartes, Boyle, Grimaldi, Huygens and others who did pioneer work and undoubtedly contributed to the knowledge of the nature of light and colours, but their works in this respect have been to some extent overshadowed by the discoveries of Newton and the authority which he carried. Thus Descartes established and published the laws of the refraction of light[9]; the facts had previously appeared in a manuscript written, but not published, by Willebrord Snell a few years earlier, but Descartes makes no reference to this; further, he made a decided advance in the knowledge of the formation of the rainbow[10].

Theodorich in 1311 gave the first explanation of the rainbow in a manuscript which remained unpublished until Venturi brought it to light in 1814[11]; Antonius de Dominis also wrote a treatise explaining the phenomena of the rainbow which was

[1] *Bibl.* No. 4, Cap. 6, pp. 124–5.
[2] *Bibl.* No. 5, Lib. XXXIII, Cap. 45.
[3] *Bibl.* No. 5, Lib. XXXVI, Cap. 67.
[4] *Bibl.* No. 187.
[5] *Bibl.* No. 8.
[6] *Bibl.* No. 9.
[7] *Bibl.* No. 10.
[8] *Bibl.* No. 13.
[9] *Bibl.* No. 14, pp. 17–29.
[10] *Bibl.* No. 14, pp. 265–84.
[11] *Bibl.* No. 44.

published in 1611[1], though Newton tells us[2] that it was written twenty years previously; Descartes' work however was an advance upon the description of de Dominis and corrected errors in the explanation of the second bow, but Newton writes: "Whilst they understood not the true origin of colours it's necessary to pursue it here a little further," which he proceeds to do in the light of his discovery of the compound nature of light and of the entirely dependable relationship between the colour of a homogeneous ray and its refrangibility[3], "a little further," as if indeed he was aware that he still had only a partial truth; it was not however until long afterwards that on the basis of the wave theory of light it was explained that the colour of homogeneous light depends, as does its refrangibility, entirely on the period of a wave or on the time of passage from one wave crest to the next.

Now we cannot resist giving a few quotations illustrative of the work of Boyle on the theory of colours published in 1663[4], a year before Newton began to consider and experiment upon the nature of colour; the charm of his writing grips one and indeed indicates a very acute observation, combined with a considerable amount of experimental ingenuity, and we suspect that this work has hardly received the consideration which it deserves; nevertheless, to read Newton after Boyle is like being suddenly reminded of the arduous nature of the quest for truth and the responsibilities of such work after reading poetry in a sunny garden. Boyle discusses anew all the old problems, such as the factors concerned in the production of the sensation of colour: "For there are some, especially chymists, who think that a considerable diversity of colours does constantly argue an equal diversity of nature in the bodies wherein it is conspicuous, but I confess I am not altogether of their mind[5]," and he aptly illustrates the complexity of the problem by giving as examples the differing colours of contiguous feathers in birds, "which are probably as near in properties as place," or, on the other hand, the differing colours which arise in the process of tempering steel, the colours in this case at any moment of the process being an infallible index to the nature of the product,

> "And I confess I have taken much pleasure to see the colours run along from the parts of the steel contiguous to the flame to the end of the instrument and succeed one another so fast that if a man be not vigilant to thrust the steel into the tallow at the very nick of time at which it has attained its due colour he shall miss of giving his tool the right temper."

After elaboration and discussion of these points the author concludes:

> "Indeed it is the light itself which, after a certain manner, either mingled with shades or some other ways troubled, strikes our eyes that does more immediately produce that motion in the organ upon whose account men say they see such or such a colour in the object: yet because there is in the body that is said to be coloured a certain disposition of the superficial particles whereby it sends the light reflected or refracted to our eyes thus and thus altered and not otherwise, it may also in some sense be said that colour depends upon the visible body[6]."

It was an easy step from this for Boyle to point the way to the explanation of colours produced[7] by such processes as pressure on the eyeball, blows on the head, violent fits of coughing and so on.

[1] *Bibl.* No. 12. [2] *Bibl.* No. 26, p. 127. [3] *Bibl.* No. 26, pp. 126–34.
[4] *Bibl.* No. 16. [5] *Bibl.* No. 16, p. 669. [6] *Bibl.* No. 16, p. 671.
[7] Descartes, writing twenty-five years before Boyle, points out that to the jaundiced individual everything looks yellow. *Bibl.* No. 14, p. 66.

"If we consider the matter more attentively we shall see cause to suspect, if not to conclude, that though light do more immediately affect the organ of sight than do the bodies that send it thither, yet light itself produces the sensation of a colour; but as it produces such a determinate kind of local motion in some part of the brain, which though it happen most commonly from the motion whereinto the slender strings of the retina are put by the appulse of light, yet if the like motion happen to be produced by any other cause, wherein the light concurs not at all, a man shall think he sees the same colour[1]."

This is, so far as we have been able to find, the first attempt to explain such phenomena as the flash on pressure of the eyeball since the early Greeks' interpretation of it as indicating the presence of fire in the eye. Boyle passed sunbeams through a triangular prism and discussed the rainbow painted on the wall; he says: "Nor will it follow that because there remains no footsteps of the colour upon the object when the prism is removed, that therefore the colour was not real, since the light was truly modified by the refraction and reflection it suffered in its trajection through the prism[2]"; this same experiment a few years later in Newton's hands was incomparably more illuminating, yet Boyle's work is of great interest and value as a review of the many different theories of colour held then and previously; his experiments were suggestive and he himself had no illusions concerning the limitation of his knowledge; he said that he taught only "that the beams of light modified by the bodies whence they are sent (reflected or refracted) to the eye produce there that kind of sensation men commonly call colour," and he adds that in order to give a perfect account of the theory of vision and colours:

"I would first know what light is, and if it be a body (as a body or the motion of a body it seems to be) what kind of corpuscles for size and shape it consists of, with what swiftness they move forwards, and whirl about their own centers. Then I would know the nature of refraction, which I take to be one of the abstrusest things (not to explicate plausibly, but to explicate satisfactorily) that I have met with in physicks[3]."

Before proceeding to consider Newton's contribution to the knowledge of the nature of colours, brief mention must be made of the celebrated and now rather scarce work of Grimaldi on light and colour, published in 1665[4]; there is not, so far as we have discovered, anything new in the work which is of special significance with regard to the question of colour or colour vision; the chief interest of the work consists in the sections concerning the properties of light, from the fact that the author appears to have been the first investigator to assert that the transmission of light was not instantaneous, and he further proposes a sort of undulatory motion for light, thus definitely predicting Römer's demonstration of the velocity of light from observations on the eclipses of Jupiter's satellites in 1676 and Huygens' enunciation of the wave theory of light in 1690[5]. Grimaldi also describes the expansion of the solar rays when passed through a prism, but he did not explain the phenomenon.

One year after the publication of Grimaldi's work, Isaac Newton, at the age of twenty-three years, began his investigations on the nature of colours; he writes:

"In the beginning of the year 1666 (at which time I applied myself to the grinding of optic glasses of other figures than spherical) I procured a triangular glass prism, to try therewith the celebrated phenomena

[1] *Bibl.* No. 16, p. 671. An interesting early reference to what were afterwards named by Buffon accidental colours.

[2] *Bibl.* No. 16, p 693.

[3] *Bibl.* No. 16, p. 695.

[4] *Bibl.* No. 17.

[5] *Bibl.* No. 23. First published in 1690, but written, according to the author's preface, twelve years previously.

of colours. And for that purpose having darkened my chamber, and made a small hole in my window shuts, to let in a convenient quantity of the sun's light, I placed my prism at his entrance, that it might be refracted to the opposite wall. It was at first a very pleasing diversion to view the vivid and intense colours produced thereby: but after a while applying myself to consider them more circumspectly, I was surprised to see them in an oblong form; which, according to the received laws of refraction, I expected would have been circular. They were terminated at the sides with strait lines, but at the ends the decay of light was so gradual, that it was difficult to determine justly what was their figure; yet they seemed semicircular. Comparing the length of this coloured spectrum with its breadth, I found it about five times greater; a disproportion so extravagant that it excited me to a more than ordinary curiosity of examining from whence it might proceed."

There follows the classical account of Newton's experiments (too long to quote fully here and too beautiful to describe in words other than the author's), with the conclusion: "And so the true cause of the length of that image was detected to be no other than that light consists of rays differently refrangible, which, without any respect to a difference in their incidence, were, according to their degrees of refrangibility, transmitted towards divers parts of the wall," and the author's doctrine of colours is propounded in thirteen propositions from which the following extracts are taken:

"As the rays of light differ in degrees of refrangibility, so they also differ in their disposition to exhibit this or that particular colour. Colours are not qualifications of light, derived from refractions, or reflections of natural bodies (as it is generally believed,) but original and connate properties, which in divers rays are diverse. Some rays are disposed to exhibit a red colour, and no other; some a yellow and no other; some a green, and no other; and so of the rest....To the same degree of refrangibility ever belongs the same colour, and to the same colour ever belongs the same degree of refrangibility....The species of colour, and degree of refrangibility proper to any particular sort of rays, is not mutable by refraction, nor by reflection from natural bodies, nor by any other cause, that I could yet observe. When any one sort of rays has been well parted from those of other kinds, it has afterwards obstinately retained its colour, notwithstanding my utmost endeavours to change it....Yet seeming transmutations of colours may be made where there is any mixture of divers sorts of rays, for in such mixtures the component colours appear not, but, by their mutual allaying each other, constitute a middling colour....There are therefore two sorts of colours. The one original and simple, the other compounded of these. The original or primary colours are red, yellow, green, blue, and a violet-purple, together with orange, indigo, and an indefinite variety of intermediate gradations. The same colours in specie with these primary ones may be also produced by composition: for a mixture of yellow and blue makes green. But the most surprising and wonderful composition was that of whiteness. There is no one sort of rays which alone can exhibit this. It is ever compounded, and to its composition are requisite all the aforesaid primary colours, mixed in a due proportion."

Newton would observe facts and deduce from his observations, but he must always have a foundation of experimental knowledge and had a fundamental dislike to propounding a theory which was not built upon this plan; it apparently gave him annoyance to have his theory of colours referred to as an hypothesis. He says: "I do not take it amiss that the Rev. Father calls my theory an hypothesis inasmuch as he was not acquainted with it....if I had not considered them as true, I would rather have them rejected as vain and empty speculation, than acknowledged even as an hypothesis[1]." After discussing his experiments on colours, he says: "But to determine more absolutely what light is, after what manner refracted, and by what modes or action it produces in our minds the phantasms of colours, is not so easy. And I shall not mingle conjectures with certainties."

Newton, at a later date, after a much more detailed analytical investigation of the nature and phenomena of colours, propounds sixteen queries[2] to encourage the search of others, and these queries are some of them concerned with the problem of the mechanism of colour vision. Thus:

[1] *Phil. Trans.* Vol. VII, p. 4093. London, 1672.

[2] *Bibl.* No. 26, pp. 132–7.

"Do not the rays of Light in falling upon the bottom of the eye excite vibrations in the *Tunica Retina*? Which vibrations, being propagated along the solid fibres of the optick Nerves into the Brain, cause the sense of seeing. For because dense Bodies conserve their heat a long time, and the densest Bodies conserve their heat the longest, the vibrations of their parts are of a lasting nature, and therefore may be propagated along solid fibres of uniform dense matter to a great distance, for conveying into the Brain the impressions made upon the organs of sense."

And again: "Do not several sorts of rays make vibrations of several bignesses, which according to their bignesses excite sensations of several Colours, much after the manner that the vibrations of the Air, according to their several bignesses, excite sensations of several sounds?[1]"

One inevitably concludes from the literature that Newton adhered to the corpuscular theory of light, and it has even been stated by a well-known German physicist discussing the undulatory theory of light, that there is no other instance in the whole history of modern physics in which the truth was so long kept down by authority. If this be true we must assuredly blame the unworthy followers of the great scientist, for Newton himself writes:

"But I knew that the properties which I declared of light were in some measure capable of being explicated, not only by that, but by many other mechanical hypotheses. And therefore I chose to decline them all, and to speak of light in general terms, considering it abstractly, as something or other propagated every way in straight lines from luminous bodies without determining what that thing is, whether a confused mixture of difform qualities or modes of bodies or of bodies themselves, or of any virtues powers or beings whatsoever. And for the same reason I chose to speak of colours according to the information of our senses as if they were qualities of light without us[2]."

It is of some interest to set down the statements of the Lucasian Professor of Mathematics in Cambridge, published in 1669, on the nature and origin of colour; he declares:

"White is that which discharges a copious light equally clear in every direction. Black is that which does not emit light at all, or which does it very sparingly. Red is that which emits a light more clear than usual but interrupted by shady interstices. Blue is that which discharges a rarefied light as in bodies which consist of white and black particles arranged alternately. Green is nearly allied to blue. Yellow is a mixture of much white and a little red. Purple consists of a great deal of blue mixed with a small portion of red[3]."

Clearly Newton learnt little on these subjects from his tutor! Newton himself says of his discovery of the different refrangibility of the rays of light, that it is "in my judgment the oddest if not the most considerable detection which hath hitherto been made in the operations of nature[4]."

It is not within the scope of this work to consider in any further detail the historical aspect of the theory of colours and the nature of light or the growth and development, and in some cases modification of the ideas originated by Newton.

Previous to the year 1684 we have found no single statement which we could urge as a definite recognition of the phenomena of colour-blindness, a sufficiently surprising fact in the light of our present knowledge of its nature and frequency; but at this

[1] Newton, further, in this section of his work strongly suggests the problem of the evolution of stereoscopic vision; he says, "For the optick Nerves of such Animals as look the same way with both eyes (as of Men, Dogs, Sheep, Oxen, &c.) meet before they come into the Brain, but the optick Nerves of such Animals as do not look the same way with both eyes (as of Fishes and of the Chameleon) do not meet, if I am rightly informed." *Bibl.* No. 26, p. 137.

[2] *Bibl.* No. 20, p. 5087. [3] *Bibl.* No. 59, p. 15. [4] *Bibl.* No. 59, p. 39.

date we find the first account of a case of total colour-blindness which, though probably not itself of congenital origin, may well have called the attention of the scientific world to the subject and one would expect that some discussion of the case would follow and other instances be recorded. Dr Turbervile, of Salisbury, writes:

"A maid two or three and twenty years old came to me from Banbury, who could see very well, but no colour beside Black and White. She has such Scintillations by night (with the appearances of Bulls, Bears &c.) as terrified her very much; she could see to read sometimes in the greatest darkness for almost a quarter of an hour[1]."

This case was almost surely not of congenital origin, but due to hysteria or to some cerebral affection; the astonishing fact is that it called forth no comment and nearly a hundred years passed before another case of colour-blindness was recorded; an interesting reference however was made in the interval by Porterfield, who writes, in 1759:

"Before I leave this subject it may not be improper to take notice of a very gross tho' vulgar error, into which the greatest Part of mankind fall, when they imagine that every Body has the same Sensation of the same Object. As for instance, we are ready to believe that everybody sees Snow white, the Heavens blue, the Meadows green, and all other visible objects after the same manner as we see them....Nevertheless, it is certain that there is no manner of Reason for our thinking so....Thus the motion which causes Redness in me may cause the Sensation of green or blue in another, or even some other new Sensation which no body has ever felt or dreamed of[2]."

In 1777 we find our earliest record of an undoubted case of congenital and hereditary colour-blindness[3]. The case is described by Huddart and tells of how a Quaker named Harris, at the age of about four years, found a child's stocking and observed that people called it a *red* stocking, though he did not understand why they gave it that denomination as he himself thought it completely described by being called a stocking; he observed also that other children could discern cherries on a tree by some pretended difference of colour, though he could only distinguish them from the leaves by the difference of size and shape. He could never do more than guess the name of any colour, yet he could distinguish white from black or black from any light or bright colour. Grunert[4] reports this as a case of total colour-blindness, but other authorities dispute this view on the grounds that Harris could see as far off as other children, and no reference is made to photophobia or nystagmus. Two of his brothers were similarly affected, and an examination of one of them supports the view that the case was not one of total colour-blindness—at any rate in the brother[5].

One year later, in 1778, another case of congenital and hereditary colour-blindness[6] is described by Scott[7], himself a member of the affected family, who says: "I do not know any green in the world; a pink colour and a pale blue are alike, I do not know one from the other; a full red and a full green the same, I have often thought them a good match...[8]." This case is further of special interest in that the author's sister was affected and, in accordance with the demands of some modern theorists, her father, her two sons and a member of her mother's stock were also colour-blind.

[1] *Bibl.* No. 21.
[2] *Bibl.* No. 29, pp. 345–7.
[3] See Plate XXVIII, Fig. 401.
[4] *Bibl.* No. 34, p. 144.
[5] For a full description of the history, see Descriptions of Pedigree Plates.
[6] See Plate XXXVIII, Fig. 570.
[7] *Bibl.* No. 35.
[8] A delightful account of this case is fully quoted in the Descriptions of Pedigree Plates.

Strange as it may appear, these two extremely arresting histories called forth no comments in the literature of the day, and no attempts to seek out and investigate the phenomenon in this or in any other country. No further reference to the subject has been found until sixteen years later when, in 1794, the distinguished colour-blind chemist, John Dalton, proceeded to scientifically examine and describe the defect in his own vision[1]. The great interest and importance of his communications may be judged from the following extracts:

"I was always of opinion, though I might not often mention it, that several colours were injudiciously named. The term pink in reference to the flower of that name seemed proper enough; but when the term red was substituted for pink, I thought it highly improper: it should have been blue, in my apprehension, as pink and blue appear to me very nearly allied; whilst pink and red have scarcely any relation."

Dalton became convinced of a peculiarity in his vision in 1792 on observing the colour of the flower *Geranium zonale* by candlelight.

"The flower was pink but it appeared to me almost an exact sky-blue by day; in candle-light, however, it was astonishingly changed, not having then any blue in it, but being what I called red, a colour which forms a striking contrast to blue. Not then doubting but that the change of colour would be equal to all, I requested some of my friends to observe the phaenomenon; when I was surprised to find they all agreed that the colour was not materially different from what it was by day-light; except my brother who saw it in the same light as myself."

He concluded that the difference between some colours seen in daylight and in candlelight was indefinitely more perceptible to him than others; of the solar spectrum he says:

"I see only two or at most three distinctions—these I should call yellow and blue; or yellow, blue and purple. My yellow comprehends the red, orange, yellow and green of others; and my blue and purple coincides with theirs. That part of the image which others call red appears to me little more than a shade or defect of light; after that the orange, yellow and green seem one colour which descends pretty uniformly from an intense to a rare yellow, making what I should call different shades of yellow. The difference between the green part and the blue part is very striking to my eye: they seem to be strongly contrasted. That between the blue and purple is much less so. The purple appears to be blue much darkened and condensed."

There follows a detailed consideration of each colour as seen by himself and others in daylight and in candlelight, with some investigation of the modification of colour by moonlight, lightning and electricity. He concludes by enunciating a theory to explain the phenomena of his defect:

"The first time I was enabled to form a plausible idea of the cause of our vision was after observing that a sky-blue transparent liquid modified the light of a candle so as to make it similar to day-light and of course restored to pink its proper colour by day, namely light blue....At the same time that it exhibited the effect of a transparent coloured medium in the modification of colours it seemed to indicate the analogy of solar light to that resulting from combustion; and that the former is modified by the transparent blue atmosphere as the latter is by the transparent blue liquid. Now the effect of a transparent coloured medium, as Mr Delavel has proved, is to transmit more, and consequently imbibe fewer of the rays of its own colour than of those of other colours. Reflecting upon these facts I was led to conjecture that one of the humours of my eye must be a transparent but coloured medium, so constituted as to absorb red and green rays principally, because I obtain no proper ideas of these in the solar spectrum; and to transmit blue and other colours more perfectly. What seemed to make against this opinion however was that I thought red bodies, such as vermilion, should appear black to me, which was contrary to fact....It appears therefore almost beyond a doubt that one of the humours of my eye...is a coloured medium, probably some modification of blue."

Dalton adhered to this view and instructed that a post-mortem examination should be made after his death to confirm the fact, but when this was done nothing abnormal was

[1] *Bibl.* No. 40.

found in the humours or tunics of the eye[1]; on this occasion his brain also was examined and an imperfect or deficient development of the anterior lobes is described—to the satisfaction of the phrenologist who localises in that region the appreciation of colour. It is a sad pity that this examination of a colour-blind eye should have occurred at a time when histological methods were not yet sufficiently refined for any abnormality to be detected in the retinal elements or in the minute structures of the brain. Dalton's memoir is of great importance from the historical aspect of our subject, and marks the inauguration of an epoch, lasting continuously up to the present day, characterised by untiring efforts to understand the mechanism of colour vision and the source of the defect in the colour-blind. To him must be given the credit for awakening so universal an interest, though it is difficult to say whether the direct stimulus was his clearly reasoned account of his own defect or whether it consisted in the fact that he first began to test the colour vision of others who believed themselves to be normal, and demonstrated that the defect was by no means a rarity[2].

Two main lines of investigation have been pursued since the time of Dalton, facts have been observed and theories have been evolved; in most recent accounts of the subject the various theoretical considerations have received great prominence; and the extent to which facts appear to fit or not to fit the demands of theories, which have been propounded, amended and modified, have been considered in great detail and with conspicuous ability. This aspect of the subject has been fully dealt with by Sir J. H. Parsons in his most excellent volume on Colour Vision[3], and by other writers; we have therefore determined to omit all theoretical considerations—those due to Young, Helmholtz, Hering and Edridge-Green, as well as the less famed systems—from our account, and to confine ourselves to a description of the facts which have been observed concerning the colour sense of the normal and of the abnormal. The evolution of theories to explain facts and their modification to meet the needs of a further accumulation of facts is undoubtedly one possible method of reaching the truth, but it is a painful method to some minds, fraught with many pitfalls to all, and some of us are content to collect and analyse facts and correlate our findings, in the confidence that one day this process will lead its followers to enunciate not a theory but a doctrine of Colour Vision.

Normal Colour Vision. Brewster held that colours should be arranged in seven classes, each of which depends upon different principles; his classes consist of (i) Transparent coloured fluids, transparent coloured gems, transparent coloured glasses, coloured powders, and the colours of the leaves and flowers of plants; (ii) Oxidations on metals, colours of Labrador feld-spar, colours of precious and hydrophanous opal and other opalescences, the colours of the feathers of birds, of the wings of insects and of the scales of fishes; (iii) Superficial colours, as those of mother-of-pearl and striated surfaces; (iv) Opalescences and colours in composite crystals having double refraction; (v) Colours from the absorption of common and polarised light by doubling

[1] *Bibl.* No. 73.

[2] Dalton used to test the colour vision of his pupils: he found on one occasion that two out of twenty-five were colour-blind.

[3] *Bibl.* No. 371.

refracting crystals; (vi) Colours at the surfaces of media of different dispersive powers; and (vii) Colours at the surface of media in which the reflecting forces extend to different distances or follow different laws[1]. We shall assume, however, that the classification of colour vision in man need not concern itself with the mode of production of the phenomenon of colour or the principle which determines this or that particular colour, but is concerned solely with the recognition of any individual colour of specified luminosity, saturation and hue, whatever may be the source of its origin; for the ultimate recognition of any particular colour is certainly brought about primarily by the stimulation of the percipient elements of the retina, the source of the stimulus being light in every case[2], and whether it be reflected or refracted or transmitted, or simple or compound light need not concern us at the moment. For any refined investigation of colour sense it is necessary to be fully alive to all these differing sources of stimuli even though our percipient elements may not be able at this present stage of evolution to discriminate between them; and further, in any consideration of the colour sense in animals, whose sensibility to stimuli differs in many cases markedly from that of man, we cannot be too minute in our consideration of the factors contributing to any particular stimulus, but for the detection of gross defects in colour sense such as are revealed in the colour-blind members of our pedigree stocks, very simple tests usually suffice to reveal their deficiencies. Again, such problems as are suggested by the observation, for example, that red and green spectral lights when compounded result in a sensation of yellow, but the mixture of red and green pigments does not produce a yellow pigment, or that blue and yellow spectral lights, if compounded, give a sensation of white, whilst blue and yellow pigments on mixture produce a green pigment, can all be explained by the different physical conditions of the experiment, but they do not concern the question of normal or abnormal colour vision, or the ability or inability to perceive and identify, say green, whether it belongs to any one of the classes enumerated by Brewster. Nevertheless, there are many difficulties to be faced in enunciating the phenomena of normal colour vision; a scarlet geranium is not always a scarlet geranium even to the individual possessed of a normal colour sense.

Some mention of *accidental colours* would perhaps be of interest at this point, as they throw considerable light upon the delicacy and instability of the mechanism which brings about the vision for colours, and are concerned with such effects as are produced by fatigue, contrast, adaptation, and excessive stimulation of the visual apparatus. The name of 'accidental colours' was given by Buffon in 1743; he was writing of 'couleurs naturelles' depending on properties of light, and continues:

"mais il en est d'autres qui me paroissent accidentelles et qui dépendent peut-être plus de notre organe que de la lumière. Lorsque l'œil est frappé ou pressé, on voit des couleurs dans l'obscurité, lorsque cet organe est mal disposé ou fatigué on voit encore des couleurs; c'est ce genre de couleurs que j'ai cru devoir appeller *couleurs accidentelles*, pour les distinguer des couleurs naturelles, et parce qu'en effet elles ne paroissent jamais que lorsque l'organe est forcé ou qu'il a été trop fortement ébranlé[3]."

Certain of the phenomena of accidental colours as here defined were recognised in the early days when the Greek philosopher noted the flash in the eye produced by

[1] *Bibl.* No. 59, p. 89.

[2] Omitting such temporary sensations of colour as may be produced by pressure on the eyeball, blows on the head, fits of coughing and all other phenomena of accidental colours.

[3] *Bibl.* No. 28.

pressure on the eyeball, and interpreted the observation as an indication of the presence of fire within the eye; indeed, when we examine Aristotle's works, we feel, if our faltering knowledge of Greek and Latin does not mislead us, that he was very close to a recognition of all the chief phenomena of accidental colours; thus in his statement that the sky surrounding a halo appears blacker because of the whiteness of the halo we see his appreciation of the effect of contrast; in his statement that the organs of sense retain the impressions they have received we see his recognition of the persistence of retinal images; he writes, that having gazed for a long time at a single colour whether white or green, we see the same colour wherever we turn our eyes; this is a curious observation and suggests the recognition of positive after-images but not of the negative phase; again, Aristotle observes the effect of dazzling and says that if you look at the sun or anything else that shines and then turn away from it, you will see the object first as it really is, then it will change to red, then to purple, then to black, after which it will fade away[1]. Galen, with characteristic scorn, writes:

"Remind thyself how the power of sight is injured by a strong and shining light. How the eyes of Xenophon's soldiers suffered who had to march so long through snow-covered fields. Yes, perhaps thou knowest nothing at all about that. It would in fact not astonish me if thou hadst never disturbed thyself in any way concerning Xenophon. I believe too that thou hast never heard of Dionysius, tyrant of Sicily, who caused to be erected above his prison a tiny structure, very bright and shining being washed with chalk, or that into this building he led his prisoners after a long confinement in the dungeon, or how those who were suddenly transported from darkness into brilliant light looked into the splendours with joy, only to be completely blinded; for they were not in condition to endure the sudden and absolute incidence of the radiant brilliancy[2]."

Thus, the effects of over-stimulation of the retina and facts concerning adaptation were well known, and made use of in the devising of refined systems of torture at an early date.

An examination of works on optics belonging to the centuries which follow rarely fails to produce references of interest in this connection, in most of which the influence of Aristotle's statements is conspicuous; Ptolemy[3] describes a rotating disc with sectors or partial sectors of different colours appearing of one colour, or with rings of one colour, and makes other observations of a like nature; he, also Alhazen[4] and Kepler[5], described coloured after-images, but each of them, doubtless on the authority of Aristotle, notices only the positive after-image; it is not until 1613 that we find the first account of negative after-images. At this date Francis Aguilon[6] describes how, after looking fixedly at a latticed window for some time and then shutting the eyes, an image of the window is seen, in which however the transparent areas appear dark and the opaque bars appear luminous; he explains the phenomenon as being due to the action of the light from the transparent areas weakening the corresponding parts of the retina, in other words, being due to fatigue.

Nicolas Peiresc[7], in 1634, describes positive and negative after-images seen after looking at latticed windows and the variation of their character with the conditions of the experiment. Kircher[8], in 1646, and de la Hire[9], in 1694, make similar observa-

[1] *Bibl.* No. 2.
[2] *Bibl.* No. 6, Lib. x, cap. 3.
[3] *Bibl.* No. 187.
[4] *Bibl.* No. 8.
[5] *Bibl.* No. 10, pp. 169, 170.
[6] *Bibl.* No. 13.
[7] *Bibl.* No. 31.
[8] *Bibl.* No. 15.
[9] *Bibl.* No 25.

tions; further, they notice the successive images, differently coloured, seen on all sides after looking at the sun, but the classical account of this phenomenon, considerably amplified and illustrating the danger of such experiments, is described by Newton in a letter to John Locke, written in 1691. He writes:

"I looked a very little while upon the sun in the looking-glass with my right eye, and then turned my eyes into a dark corner of my chamber, and winked to observe the impression made, and the circles of colours which encompassed it, and how they decayed by degrees, and at last vanished. This I repeated a second and a third time. At the third time, when the phantasm of light and colours about it were almost vanished, intending my fancy upon them to see their last appearance, I found to my amazement that they began to return, and by little and little to become as lively and vivid as when I had newly looked upon the sun. But when I ceased to intende my fancy upon them, they vanished again. After this, I found that as often as I went into the dark, and intended my mind upon them, as when a man looks earnestly to see any thing which is difficult to be seen, I could make the phantasm return without looking any more upon the sun; and the oftener I made it return, the more easily I could make it return again. And at length, by repeating this without looking any more upon the sun, I made such an impression on my eye, that if I looked upon the clouds, or a book, or any bright object, I saw upon it a round bright spot of light like the sun; and, which is still stranger, though I looked upon the sun with my right eye only and not with my left, yet my fancy began to make the impression upon my left eye, as well as upon my right. For if I shut my right eye, and looked upon a book or the clouds with my left eye, I could see the spectrum of the sun almost as plain as with my right eye, if I did but intende my fancy a little upon it; for at first, if I shut my right eye, and looked with my left, the spectrum of the sun did not appear till I intended my fancy upon it; but by repeating, this appeared every time more easily. And now, in a few hours' time, I had brought my eyes to such a pass, that I could look upon no bright object with either eye, but I saw the sun before me, so that I durst neither write nor read: but to recover the use of my eyes, shut myself in my chamber made dark, for three days together, and used all means to divert my imagination from the sun. For if I thought upon him, I presently saw his picture, though I was in the dark. But by keeping in the dark, and employing my mind about other things, I began in three or four days to have some use of my eyes again; and by forbearing a few days longer to look upon bright objects, recovered them pretty well, though not so well, but that for some months after the spectrum of the sun began to return as often as I began to meditate upon the phenomenon, even though I lay in bed at midnight with my curtains drawn; but now I have been very well for many years, though I am apt to think, that if I durst venture my eyes I could still make the phantasm return by the power of my fancy...and so your question about the cause of this phantasm involves another about the power of fancy, which I must confess is too hard a knot for me to untie[1]."

We have quoted this letter fully, not only because it is a historic description of an interesting experiment not lightly to be repeated, but because it brings forward so vividly the close association between the psychological and physiological aspects of vision and reveals the complexity of some of the physiological processes involved.

Buffon[2] therefore was wrong in his statement that Jurin, who published in 1738, first made observations on accidental colours—we believe however he was right in considering himself to be the first to call attention to certain peculiar associations between natural and accidental colours; thus he describes how, after gazing fixedly on a red paper and then transferring the gaze to a white paper, a green image of precisely the same shape as the red paper is seen; similarly he describes how gazing on a yellow paper in place of the red leads to a blue after-image, a green paper to a purple after-image and a black paper to a white after-image; he states that the yellow impression was stronger than the red and that therefore the blue after-image remained longer than the green. Buffon accordingly appears to have first recognised this phenomenon of what came to be known as Complementary Colours[3]. This publication stimulated a considerable amount of experiment and enquiry into the nature of

[1] *Bibl.* No. 58, pp. 217–19.

[2] *Bibl.* No. 28.

[3] Complementary Colours being such that their combination produces a sensation of white.

after-images and complementary colours. Knowledge of the facts accumulated, and here we find indications of the origin of the two historic theories which have been enunciated to explain the mechanism of colour vision known by the names of their originators, the Young-Helmholtz and the Hering theories of colour vision; the forerunners of the Hering theory[1] holding the after-image of complementary colour to be of the nature of a reaction following strong stimulation, and the forerunner of the Young-Helmholtz theory, in the person of Scherffer[2], proclaiming in 1761,

"Perhaps the Creator has so constructed the entire organ of vision that each kind of ray can only act upon such of the parts of which the eye is composed as are particularly appropriated to it....It may be that a continuous action of, for instance, red light, may so change the order and arrangement of the parts of the back of the eye...that those rays may be no longer strong enough to communicate to these parts the necessary vibratory movement, until a little rest shall have restored them to their condition...and during this time the other rays of different kinds will not cease to act[3]."

Scherffer did instructive and sometimes amusing experiments; thus he painted a portrait with greenish face, white hair and eyebrows, black sclerotics and white pupils in such a way that the after-image of the picture had the normal colouring; he further examined the solar spectrum and determined for each of Newton's seven divisions the complementary colour. Another notable contribution of this period to the investigation of complementary colours was made by Robert Waring Darwin[4], who objected to the term 'accidental colours' being applied to them "as if subjected to no established laws"; he introduced the term 'ocular spectra' as a more fitting designation (which however has not been retained) and proceeded to classify the phenomena. Darwin repeated the observations of Buffon, but widened the scope of these experiments and tentatively suggested an explanation of their occurrence—thus, in his conclusion he writes:

"The various colours produced in the eye by the pressure of the finger, or by a stroke on it, as mentioned by Sir Isaac Newton, seem likewise to originate from the unequal pressure on various parts of the retina. Now as Sir Isaac Newton has shewn that all the different colours are reflected or transmitted by the laminae of soap bubbles, or of air, according to their different thickness or thinness, is it not probable that the effect of the activity of the retina may be to alter its thickness or thinness, so as better to adapt it to reflect or transmit the colours which stimulate it into action? May not muscular fibres exist in the retina for this purpose which may be less minute than the locomotive muscles of microscopic animals? May not these muscular actions of the retina constitute the sensation of light and colours; and the voluntary repetitions of them, when the object is withdrawn, constitute our memory of them?"

An interesting and ingenious suggestion concerning the mechanism of colour vision[5].

From this time up to the present day much has been written on the subject of accidental colours and on the nature of after-images; the phenomena are extremely varied and illusory, depending for the particular manifestation upon such factors as intensity of the exciting stimulus; on the time of exposure and area of retina stimulated; on the state of health of the individual; on whether the accidental colour is seen with closed or open eyes; if closed, on how lightly the lids are closed and how much light is allowed to pass through the eyelids; on whether the eye is dark or

[1] See e.g. Venturi. *Bibl.* No. 42, p. 275.
[2] *Bibl.* No. 30. See also *Bibl.* No. 41.
[3] We are indebted to Mr Burch for the translation of this exceedingly interesting passage. *Bibl.* No. 270, p. 205.
[4] *Bibl.* No. 38.
[5] For other 18th century accounts of the phenomena of accidental colours see *Bibl.* Nos. 15, 27, 29, 32, 33.

light adapted at the time of the experiment; on the retinal experience prior to the experiment and to some extent on the idiosyncrasies of the individual.

Hartridge, in his interesting account of "the subjective phenomena of vision[1]," suggests the general nature of the reaction of the retina to the stimulus of light in the following diagram. The primary response, after a definite latent period, he considers

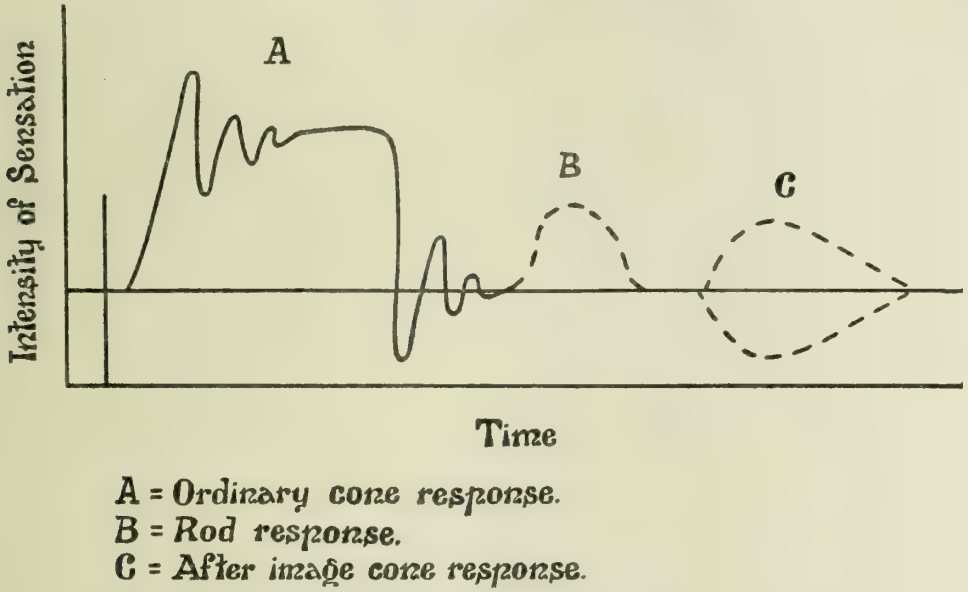

DIAGRAM 1. Curve representing diagrammatically the sensations aroused when the eye has been stimulated by a flash of light. Hartridge, in Starling's *Principles of Human Physiology*, 3rd edn., 1920, p. 566. (By permission of Professor Starling.)

to be due to the reaction of the cones; this is followed under certain conditions by a second response which (1) is not seen when the eye is light-adapted; (2) is strongest for green light and is absent for red; (3) is absent from the fovea; (4) is not seen by persons suffering from night-blindness; and (5) is always of a bluish-grey colour. All these characteristics, as we shall see later when considering the function of different retinal elements, are suggestive of the reaction of the rods; following this again comes the after-image, which, he says, certainly concerns the cones and may concern the rods; of the after-image he writes:

"It has however the peculiarity that, so long as it lasts, the part of the retina affected gives a diminished response to a stimulus of the same type as that which it had previously received. For example, if the first stimulus was one of white light, then a second white light stimulus, falling in the period occupied by the after image of the first, would not be recorded by the retina with the normal intensity....If the second stimulus occupies a larger area of the retina than that on which the first stimulus fell, the first area stimulated appears dark on the bright ground corresponding to the second area. If the first stimulus is coloured, say, red, and no stimulus follows, the secondary image is found to have the same colour; but if a second stimulus of the same colour falls on the retina during the secondary image, then as before the area first stimulated appears dark on the bright area occupied by the second area. If on the other hand the second stimulus be one of white light, the sensation received is one of the complementary colour, the reason being that the red constituents of the white light are partially excluded by the after-image of the first stimulus, but not so the other spectral colours, and the image which is seen is therefore a blue-green one."

This account definitely suggests that the positive after-image of the same colour as the primary stimulus occurs when there is no secondary stimulus, and that the

[1] *Bibl.* No. 390.

presence of a secondary stimulus determines the presentation of a negative after-image whose colour can be invariably predicted provided the colours of the primary and secondary stimuli are known.

We must not think, however, that the reaction of the retina to stimulation is the only factor to be considered, but must recognise also the equally vital factor of cerebral excitation with its resultant consciousness, without which none of the phenomena would occur; there is no doubt that much confusion in the interpretation of the phenomena has arisen in the past from the neglect of this factor, the full significance of which was possibly first fully emphasised by McDougall as late as 1901, when he demonstrated that change of apparent sensation could by no means be taken to infer a simultaneous change in the retinal processes involved; he refers to the well-founded hypothesis that perpetual change in the afferent nervous impulses reaching the cerebrum is an essential condition of continued consciousness, and after a considerable series of experiments, he concludes—"These observations seem to me to establish beyond question that a ray of light that usually excites a vivid image may continue to produce in the retina the normal chemical changes without continuing to affect consciousness, if the reinforcing factors of novelty of stimulus and muscular reaction be excluded[1]."

This brief sketch of certain of the phenomena of accidental colours will, we hope, suffice to remind the readers of some of the fundamental facts which have to be reckoned with in any consideration of the mechanism of visual sensation; very full accounts with experimental details giving the varied effects of the conditions indicated above are described by Plateau[2], Chevreul[3], Moigno[4], Aubert[5], von Helmholtz[6], Hering[7], Burch[8], McDougall[9], Edridge-Green[10], Parsons[11] and many other writers; full bibliographies are given by Helmholtz, by Plateau and by Parsons. The bibliography of Plateau (giving brief extracts of many papers), concerned only with subjective phenomena of vision and yet extending over forty pages, will give some idea of the volume of literature which had appeared on the subject before 1877.

The Solar Spectrum. Let us now consider the spectrum of sunlight as it is presented to the average individual with a normal colour sense. Most modern text-books of physiology will give the reader a wave length at which the spectrum becomes visible to the average observer, the wave lengths at which the red will change to orange, the orange to yellow, the yellow to green, the green to blue-green, the blue-green to blue, the blue to violet, and finally the wave length at which visibility will cease; these values vary within considerable limits from one observer to another under precisely similar conditions or possibly in the same observer at different times, and an examination of this fact alone will readily convince us that the perception of colour is a graduated quality and that there is little that is rigid and stationary about it. It is only, however, when we attempt to make definite statements about the appearance of the solar spectrum that the extreme instability and elusiveness of our colour

[1] *Bibl.* No. 272, pp. 62–3.
[2] *Bibl.* No. 124.
[3] *Bibl.* No 63.
[4] *Bibl.* No. 110.
[5] *Bibl.* No. 92.
[6] *Bibl.* No. 332, Bd. II.
[7] *Bibl.* Nos. 197, 293.
[8] *Bibl.* Nos. 263, 270.
[9] *Bibl.* No. 272.
[10] *Bibl.* No. 387.
[11] *Bibl.* No. 371.

sense, as well as its limitations, becomes apparent; we speak of the visible spectrum, for stimuli still continue to exert their characteristic effects over some considerable range of wave length beyond the extreme limits of visible red and violet; thus at the long-waved end we know that infra-red rays are present which stimulate certain of our sensory end-organs and produce the sensation of heat, though their effect cannot be perceived by the retinal percipient elements; again, at the short-waved end, we are aware of the chemically active ultra-violet rays which can be perceived by none of our sensory organs, though there is evidence suggesting that they have possibly very far-reaching stimulative effects on the general metabolism and vitality of the individual subjected to their action. It is not always remembered, moreover, that the intensity of these effects throughout the spectrum are graduated quantities, the heat effects being at a maximum in the infra-red region and at a minimum towards the violet end of the spectrum, whilst the chemical action is at a maximum in the ultra-violet region and at a minimum towards the red end; we feel that these facts may well be the basis of the marked influence of colour experienced by certain persons, and, coupled with the known variation of energy in the different spectral rays, certainly suggest the use of light of different wave lengths, visible as well as invisible, as therapeutic measures. Another factor only second in importance to the changes of hue in the spectrum is the change in luminosity[1], a factor which is indeed extraordinarily difficult to define in few words and yet is of primary importance in all considerations of colour sense; indeed the neglect of this factor has nullified a considerable amount of early work on comparative colour vision, done at a time when it was not fully recognised that different colours under the same intensity of illumination vary markedly in luminosity; and further that animals appear to be very sensitive to difference in luminosity, even though they may be colour-blind, as also are individuals with an inability to distinguish between different colours—a fact which is well brought out by the cases of colour-blind engravers who have at various times attributed great success in their profession to the ease with which they know the exact relative tone to give to each colour in nature.

The fact that colours of the spectrum vary in luminosity was realised long ago. Thus Newton writes:

"But it's further to be noted that the most luminous of the prismatick Colours are the Yellow and Orange. These affect the Senses more strongly than all the rest together, and next to these in strength are the Red and Green. The Blue compared with these is a faint and dark colour, and the Indigo and Violet are much darker and fainter so that these compared with the stronger Colours are little to be regarded[2]."

It was not, however, till 1814–15 that Fraunhofer[3] first presented a quantitative measure of the luminosity of equal areas of (to our senses) monochromatic light under an average intensity of illumination, and gave us the first determination of what is known to-day as the curve of luminosity in the spectrum (see Diagram 2); this curve, we now know, is only true under strictly defined conditions, viz. (i) for a definite intensity of illumination; (ii) for an eye with normal perception of colours, and (iii) for central fixation.

[1] For description of a method of measuring the luminosity of spectral colours, see Abney, *Bibl.* No. 232, pp. 78–80.

[2] For the purposes of the optical construction of telescopes. *Bibl.* No. 26, p. 71.

[3] *Bibl.* No. 46.

At a later date Purkinje[1] in 1825 noted that the relative brightness of different pigments varied markedly with a change in illumination; thus in twilight blue is brighter than red[2], whereas at a certain average illumination both colours appear of equal luminosity. Helmholtz demonstrated the same facts to hold for spectral colours[3]. The work of Fraunhofer and Purkinje was followed by an immense amount of careful experimental work on the relative brightness of colours under differing conditions: to give only a very brief summary of certain of the conclusions reached, it has been found that if two differently coloured fields have the same brightness for an average illumination, their brightness will no longer be equal after a change in the intensity of illumination; if the illumination of each be equally diminished, the colour of shorter

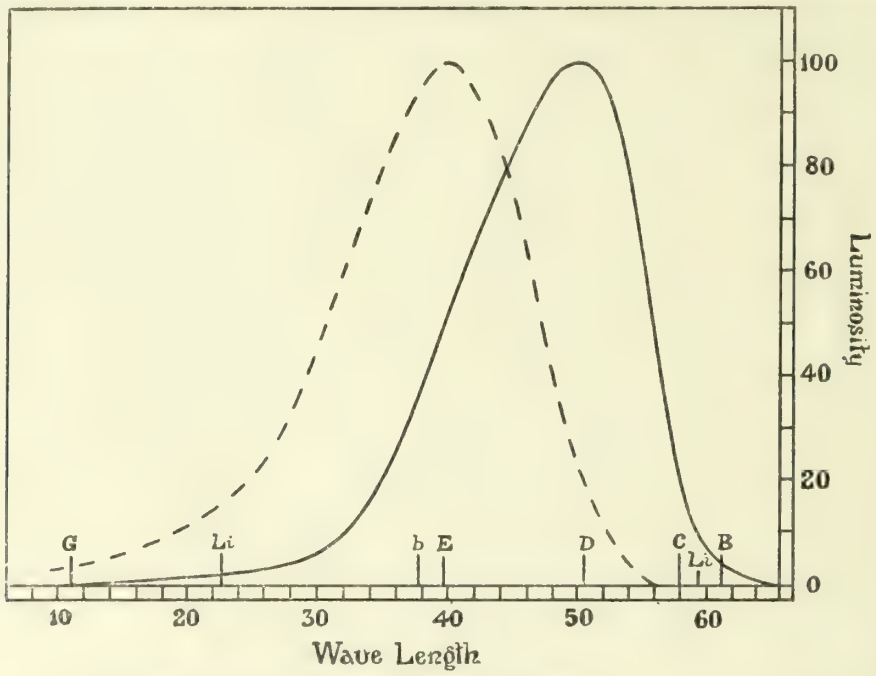

DIAGRAM 2. Luminosity curves after Abney, *Phil. Trans.* Vol. 183 A, p. 557, 1892. (By permission of the Royal Society.)

wave length will now be the brighter (see Diagram 2), whereas, if the illumination be increased, the colour of longer wave length will be the brighter; even this statement requires to be qualified, for if the illumination be progressively increased, a limit is reached beyond which the relative brightness of all colours remains stationary. If the illumination be progressively decreased, a limit is reached at which a curve is obtained precisely similar to that found to be characteristic of cases of congenital total colour-blindness at greater intensities of illumination. In other words, the curve of luminosity in total congenital colour-blindness under average conditions of illumina-

[1] *Bibl.* No. 52, Bd. II, p. 109.

[2] This fact is strikingly illustrated in a flower garden at dawn: such flowers as delphiniums appear blue, whilst the scarlet geraniums still appear black.

[3] *Bibl.* No. 332, Bd. II, S. 144–55.

tion differs from that of normal colour vision, in that the maximum value is displaced towards the short-waved end of the spectrum: this fact is of great importance and should throw some light on the phenomenon of colour-blindness; it has been made much use of by Hess in his very enlightened studies of colour vision in animals, in which he demonstrates that for fish and bees the luminosity curve is precisely similar in character to that found to hold for the totally colour-blind man, and hence regards it as confirmatory of his determination by other means of the colour-blindness in fish and in bees. As will be seen from Diagram 3 the red-blind man also has a characteristic curve of luminosity in the spectrum differing from the normal in the same direction, but less markedly than does the curve for the totally colour-blind. These facts, suggesting some

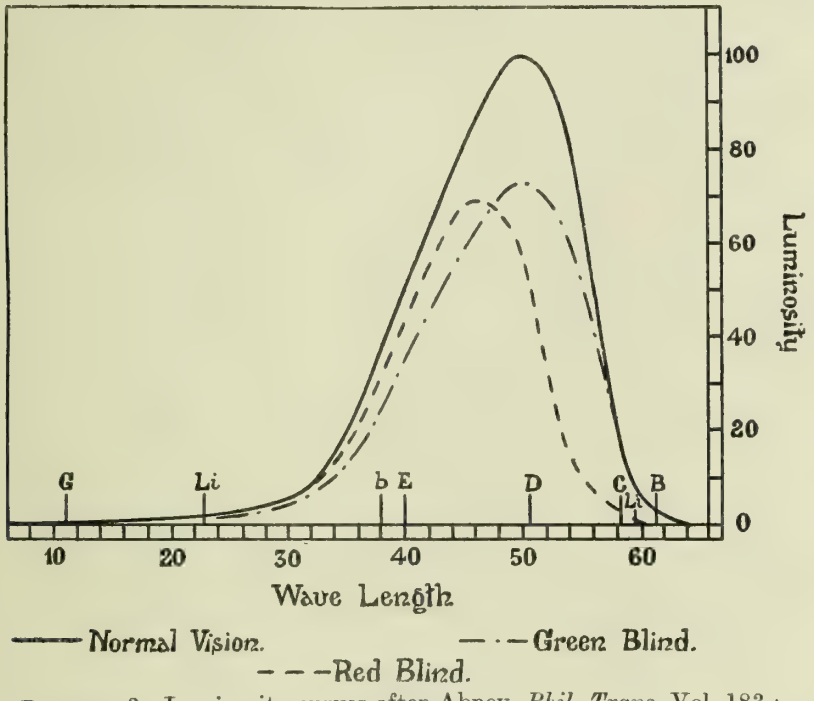

DIAGRAM 3. Luminosity curves after Abney, *Phil. Trans.* Vol. 183 A, pp. 554 and 557, 1892. (By permission of the Royal Society.)

real point of similarity between vision in a dim light and the vision of the colour-blind man, are of considerable significance in the light of the duplicity theory of retinal function, under which hypothesis the cones are regarded as being primarily concerned with colour vision and the rods with vision in a dim light, and have led to much investigation concerning the distribution of rods and cones in the retina of man and animals, followed by attempts to correlate the findings in this respect with such discoveries as concern luminosity curves and colour discrimination in ex-centric vision in man, or with the activities of animals by day or night and a determination of their colour discrimination. We may as well admit at the outset that though an enormous amount of data has been accumulated touching on these aspects of the problem of colour vision, the results are extremely disappointing; facts given appear to be conflicting, and authorities contradict one another to a degree which to the investigator, who can

claim to be neither a physicist nor a physiologist nor a histologist, but seeks merely for evidence from all sources on the facts he looks for in order to present some reasonable account of colour vision to the student of hereditary colour-blindness, is indeed bewildering.

Before considering the areal differentiation in the anatomical structure of the retina in man, and such parallel changes as have been demonstrated to exist in the discrimination of colour, we should like to call attention to Diagram 4, showing the luminosity curves for central and for ex-centric vision; we see at once that as our retinal area of stimulation is taken further from the *fovea centralis* the maximum value of the

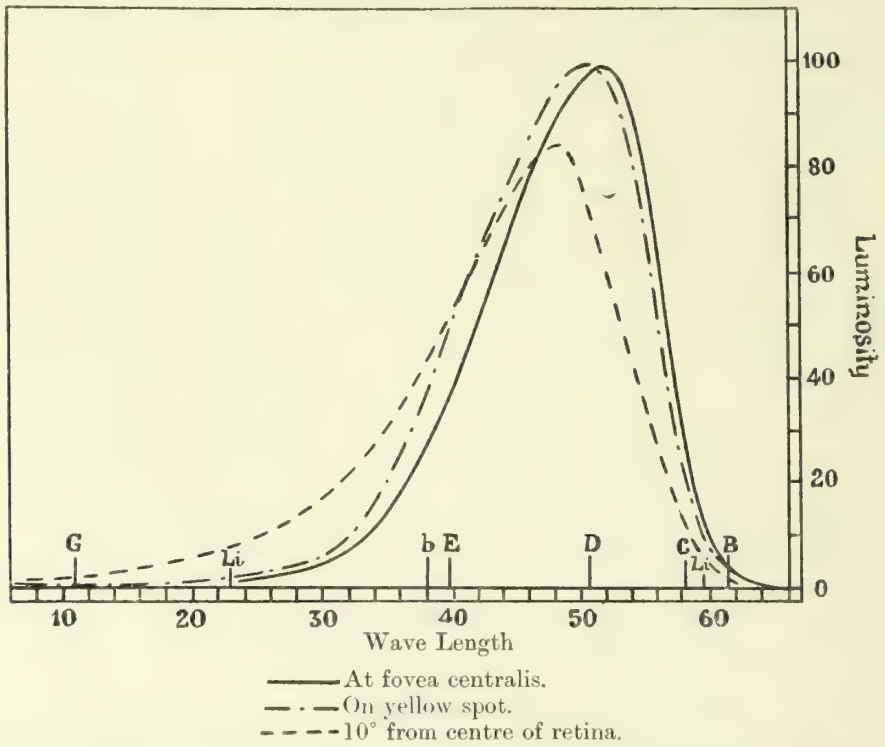

Diagram 4. Luminosity curves after Abney, *Phil. Trans.* Vol. 183 A, p. 537, 1892.
(By permission of the Royal Society.)

curve travels towards the short-waved end of the spectrum and is already at 10° distance approximating towards the curve given for red-blindness, but this difference in the two curves can be entirely accounted for by the special absorptive properties of the colouring matter in the macular region and has no significance as indicating fundamentally differing conditions of vision outside the macular region; this view is fully borne out by curves determined by Polimanti (see Diagram 5 *a*) showing very close agreement between the luminosity curves for peripheral and central vision under ordinary conditions of lighting, and by the curves of von Kries (see Diagram 5 *b*) showing the wide divergence between the peripheral luminosity curve and the curve for the dark adapted eye.

We have, accordingly, the following facts concerning curves of luminosity which

may have a bearing upon the question of the mechanism of colour vision: the curve given for central vision by the normal eye in a greatly reduced light is practically identical with the curve given for central vision by the totally colour-blind eye under average intensity of illumination, each of them differing widely from the curve for peripheral areas of the normal eye under average conditions of illumination, which closely approximates to the curve for central fixation under similar conditions. For a more refined analysis of luminosity curves, under varying conditions, with methods of measurement and full experimental details, see Vierordt[1], Draper[2], Brodhun[3], Hillebrand[4], Kohlrausch[5], König and Dieterici[6], König and Ritter[7], Abney and

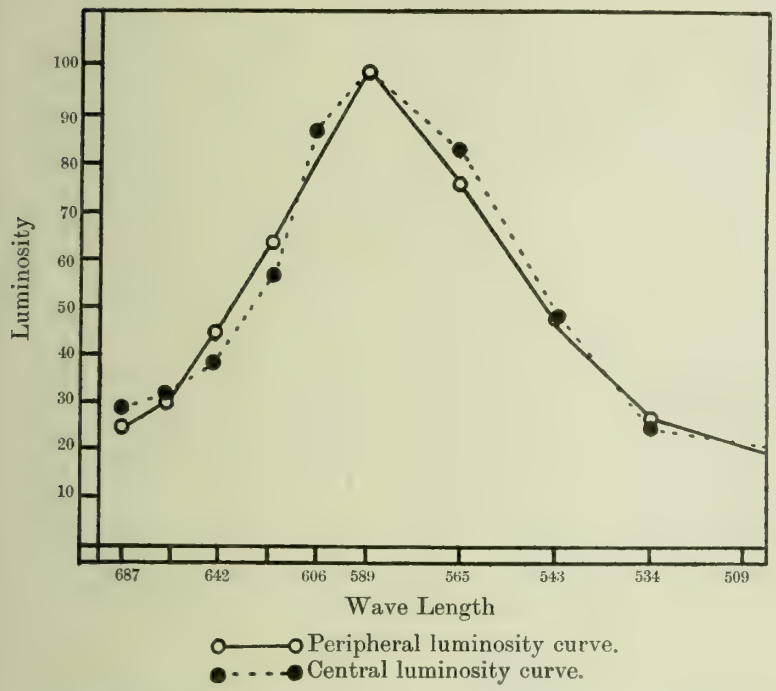

DIAGRAM 5*a*. Luminosity curves after Polimanti, *Zeitschrift f. Psychol. u. Physiol. d. Sinnesorgane*, Bd. XIX, S. 272, 1899.

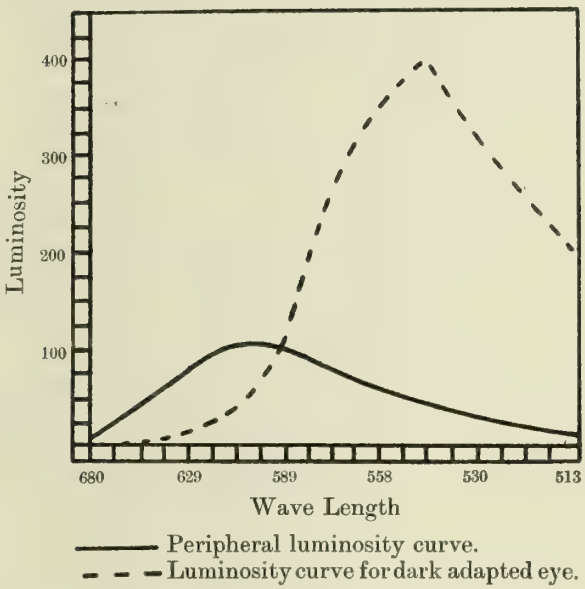

DIAGRAM 5*b*. Luminosity curves after von Kries, *Zeitschrift f. Psychol. u. Physiol. d. Sinnesorgane*, Bd. XV, S. 256, 1897.

Festing[8], Helmholtz[9], Polimanti[10], and Parsons[11]; reference will be found in these works to many further papers bearing upon this section of our subject.

The Structure of the Human Retina. Diagram 6, taken from Greeff, is given here for the benefit of readers who are not very familiar with the variety and type of structures which are found in the human retina; it must be borne in mind that this illustration is diagrammatic only and that the actual microscopic appearances vary markedly in certain very significant respects according to the particular area of the retina through which the section is taken, as well as with the conditions of lighting to which the eye has been subjected immediately before death; the diagram however

[1] *Bibl.* No. 101.
[2] *Bibl.* No. 130.
[3] *Bibl.* Nos. 195, 221.
[4] *Bibl.* No. 207.
[5] *Bibl.* Nos. 414, 415.
[6] *Bibl.* No. 228.
[7] *Bibl.* No. 283.
[8] *Bibl.* Nos. 194, 203, 226.
[9] *Bibl.* No. 332, Bd. II.
[10] *Bibl.* No. 259.
[11] *Bibl.* No. 371.

will suffice to indicate the relative positions of the pigment epithelium, the retinal percipient elements known as the rods and cones, and their association with the ganglion cells in immediate relation to the fibres of the optic nerve along which visual impulses travel to the cortical centre in the brain situated in the occipital lobe; further, a photo-chemical substance known as visual purple, which is bleached by the action of light and regenerated by contact with the pigment epithelium, is present in the outer limbs of the rods.

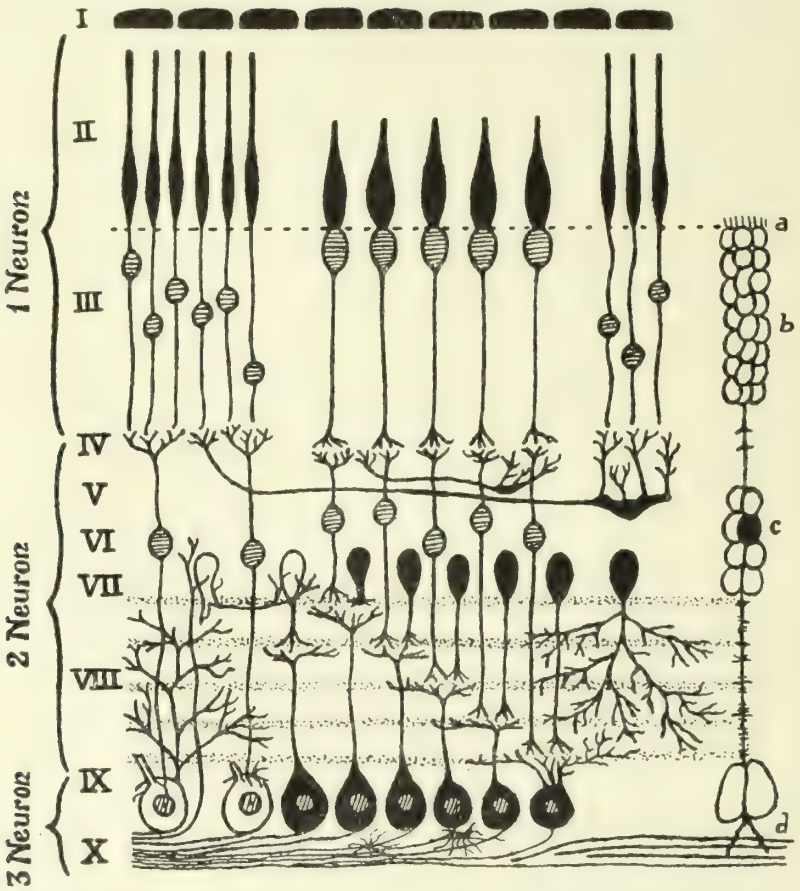

Diagram 6. Retinal rods and cones and their connections (diagrammatic), after Greeff. Graefe-Saemisch: *Handbuch der gesam. Augenheilkunde*, Bd. I, Kap. v, S. 86. Zweite Aufl., 1904. (By permission of the Editor.)

I = Pigment epithelium. II = Layer of rods and cones. X = Fibres of optic nerve.

When light falls upon the retina certain changes can be noted to occur; there is a migration of pigment from the pigment epithelial layer into the spaces between the rods and cones with a contraction and shortening of the cones, which retract upon the external limiting membrane, and swelling of the outer limbs of the rods; these changes only occur if the cerebral connections are intact[1], and they are associated with other changes such as the disappearance of chromatin granules from the ganglion cells, bleaching of the visual purple, and the tendency of the retina to

[1] *Bibl.* Nos. 186, 199, 204.

become acid in reaction; these reactions take place more readily under the action of violet light than for light of longer wave lengths. Again, when the retina is stimulated by light an electrical response can be demonstrated which differs for light of different wave length and differs also according to whether the eye has been in the light or in the dark previous to the investigation; the electrical response is at a maximum for yellow rays in the light-adapted eye and for green rays in the dark-adapted eye, a discovery which is of special interest in view of the luminosity curves which, as we have seen, show a maximum which moves from the yellow region of the spectrum for the light-adapted eye to the green region when the eye is dark-adapted[1]. Thus we see that colour exerts a characteristic action in the retina itself, but just as we get no perception of light or form if there is destruction of the visual cortex in the occipital region or interference with the optic tracts leading thereto, even though the retinal structures are normal, so we have no proof to the contrary but some evidence to be considered later in favour of the suggestion that we shall have no perception of colour if certain other cerebral areas be destroyed, though we retain our perception of light and form and have normal retinal structures—and this, remembering that purely ocular conditions may also very substantially alter our perception of colours, as for example in certain conditions of the lens[2].

In 1759, Porterfield writes[3]: "It falls here to be observed that tho' the Retina be expanded upon the whole Bottom of the eye as far as the *Ligamentum Ciliare*, yet it is not all equally sensible[4]." When we look for some difference of structure associated with this suggested variation of function, we find the following features to be characteristic of different areas or retinal zones. Towards the periphery rods largely predominate in the rod and cone layer, and the cones, which are few in number, are thick and short; on approaching the macula region the cones increase, relatively, in number and their form undergoes modification; at the macula region cones only are present and they are now so modified in structure as to resemble rods; they are closely packed in this region and the nucleus which, in other areas of the retina, is near the base of the cone proper is now removed to some distance from it. These changes are admirably illustrated in the following diagram, taken from Greeff[5]. Other characteristics limited to the macular region are the absence of visual purple[6], the absence of retinal blood vessels and the presence of a yellow pigment.

We have failed to find any indication of an association between retinal area and corresponding modification of function in the direction of colour sense in our examination of the literature concerning the luminosity curve of ex-centric vision and the

[1] *Bibl.* Nos. 89, 116, 286.

[2] Remembering also that retinal stimulation with the formation of images may take place without perception if the attention is withheld.

[3] *Bibl.* No. 29, Vol. II, p. 221.

[4] Kepler, at a much earlier date, notes that ex-centric vision does not give satisfaction, but merely invites the eye to turn in this or that direction for the purpose of securing a sharper view.

[5] *Bibl.* No. 265.

[6] Edridge-Green maintains that the outer segments of rods and cones are bathed in a fluid into which visual purple, secreted by the rods, diffuses and thus is able to obtain access to all parts of the outer layer of the retina, including the macula region where no rods are present. He says he has found visual purple not in but between the cones of the fovea. *Bibl.* No. 387, p. 43.

luminosity curve for central vision of the colour-blind man; when we look for direct confirmation of this lack of association by investigation of corresponding fields of colour vision by perimetric methods, it becomes at once apparent that there is a good

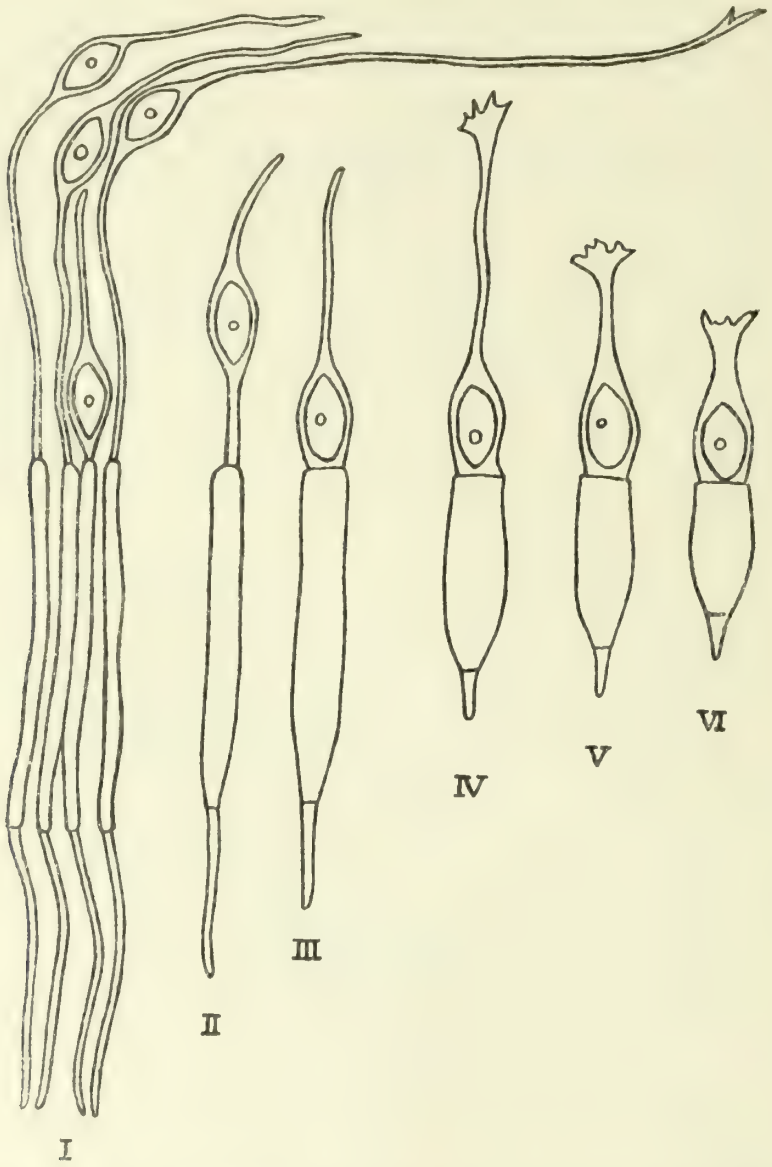

DIAGRAM 7. Retinal cones, after Greeff. Graefe-Saemisch: *Handbuch der gesam. Augenheilkunde*, Bd. I, Kap. v, S. 114. Zweite Aufl., 1904. (By permission of the Editor.)

I. Fovea centralis. II. Macula lutea. III. At periphery of macula lutea. IV. Midway between ora serrata and macula lutea. V. 3 mm. from ora serrata. VI. At ora serrata.

deal of conflicting evidence on the subject which has arisen from a lack of recognition in the earlier work of the influence of such factors as size of coloured object to be identified and intensity of illumination. Thus Abney, writing in 1898, concludes from

his investigations involving hundreds of observations which were made and repeated over a period of three years:

(i) "That where an image is received on the centre of the retina the reduction in intensity of the radiation which will just fail to produce the sensation of light depends (within limits) on the size of the image. (ii) That the smallest diameter of the image and not its area determines the necessary reduction in intensity. (iii) That the reduction in the intensity of the light of an image falling excentrically, which will just fail to produce the sensation of light, follows the same law as if the image were received centrally. (iv) That the visual brightness of illumination of a small and a large aperture when illuminated with the same light differ, and that such visual brightnesses are connected by a simple law. (v) That the reduction in the brightness of an image just sufficient to extinguish the sensation of colour varies with the size of the image and follows a definite law which however differs from that for the extinction of light. (vi) That all fields for colours will have the same boundary when the intensity of the coloured ray is properly adjusted. (vii) That there is a simple connection between the intensity of a colour and the extent of field. (viii) That the colour fields depend on the size of the object viewed, and that the dependence appears to follow a simple empiric law. (ix) That the retina is most sensitive to light at its central part, and the sensitiveness differs towards the periphery[1]."

Again, Ferree and Rand write in 1921:

"The variable factors which influence the apparent limits of colour sensitivity are the wave-length and purity of the stimulus, the intensity of the stimulus and the visual angle, length of exposure of the eye, the method of exposure (moving or stationary stimulus), accuracy and steadiness of fixation, the intensity of general illumination of the retina and its state of adaptation, the breadth of pupil and the brightness of the pre-exposure and surrounding field. By a sufficiently wide variation of intensity alone the fields of colour sensitivity may be made to have almost any breadth within the field of vision, to differ radically in shape and even to change or reverse their order of ranking as to breadth....Without great precision in the control of intensity it is obvious that reproducibility of result cannot be obtained and little significance can be attached to extent or shape of field, to order of ranking as to breadth of field or to any variations from time to time or from person to person in these important features[2]."

These quotations will suffice to indicate the subtle nature of the problem, and it must at once be granted that given a sufficiently powerful stimulus the whole retina, even to the outermost limits, is able to discriminate all colours; nevertheless the fact has been repeatedly demonstrated by experienced observers, using a variety of methods, that under certain conditions in which all colours can be readily discriminated by the central retinal areas, a zone surrounding this area interprets red, yellow and green as yellow; blue, blue-green and violet as blue; in other words, this zone is dichromic under the conditions of the experiment; further, it is surrounded by a peripheral retinal zone which is again, under the conditions of the experiment only, totally colour-blind. It is clear that colour sensitivity is at a maximum in the central retinal area, and that as the distance from the centre increases stronger stimulation is required before perception takes place, the first colours to be lost being red and green. We think we may agree with those who advocate the view that the relative colour-blindness of ex-centric retinal zones is suggestive of diminished sensitivity to colour only and is not analogous to the phenomenon of congenital colour-blindness to be considered presently. The temptation is great to at once attribute this diminished sensitivity to the diminution in the number of cones as we approach the retinal periphery and to herald the phenomenon as a demonstration of the integrity of the duplicity theory that the cones are concerned primarily with vision of colour, and the rods with vision in a dim light. We shall, however, merely call attention here to the association, and will seek for further confirmation of this association between structure and function in the retinae of animals. Further information and full experimental details may be

[1] *Bibl.* No. 247.

[2] *Bibl.* No. 395.

sought in the works of Schelske[1], Fick[2], von Kries[3], Hess[4], Abney[5], Parsons[6], Greenwood[7], Ferree and Rand[8], Aubert[9], Charpentier[10], etc.

On the Association of Retinal Structure and Function in Man and in Animals. On setting out upon this section, after dealing with the very elusive and difficult conceptions concerned with luminosity curves and retinal zones, our spirits rose and we hoped that we should now by an examination of experimental work find definitely what retinal structures are or are not essential to an appreciation of colour, but we very soon found ourselves faced by innumerable difficulties which are beyond the scope of this investigation to tackle at first hand. The sort of questions we need to ask ourselves are as follows: (i) What is the significance with regard to colour vision of (*a*) the retinal pigment epithelium and choroidal pigment, (*b*) the photo-chemical substance varying in character but presumably present in all retinae, (*c*) the layers of rods and cones, (*d*) the coloured oil globules present in certain retina? (ii) What is the source and significance with regard to colour vision of the immensely varied fundal conditions indicated by the opthalmoscopic appearances shown to us by Lindsay Johnson[11] for a large number of mammals, and by Casey Wood[12] for birds, and what is their possible effect in modifying colour vision? (iii) Are we able to come to any conclusion at all from the determination of colour vision in animals made by a great number of experimenters who have reached an almost equally great number of differing estimations, each of which tends to open up further problems and to reveal a further lack of essential knowledge? We think sadly at this point of the death, at a relatively early age, of Hess, to whom we feel so greatly indebted for his experimental work on the colour vision in animals, indeed we are indebted to him for more knowledge on the subject than to any single other worker, and we hoped he would continue to throw light into the dark places for many years to come. (iv) What inferences, if any, may be drawn from any modifications in retinal structure found to be associated with the habits of any animal, for example, the tendency to absence or paucity of retinal cones in creatures which pursue their characteristic activities by night? To consider some of these points in a little more detail: It would hardly have occurred to us, in the light of what we know to hold for the case of albinism, to regard the retinal pigment epithelium as of any fundamental importance in the mechanism of colour vision, but certain modern writers, notably Schanz[13], have built up a theory of colour vision on such a basis, which is ingenious and not without interest. Schanz reminds us that light can have no effect unless it is absorbed, that the retinal rods and cones cannot absorb light, and that light absorption takes place in the pigment layer of the retina; he considers that we are justified in assuming that electrons are expelled from this pigment by the absorbed light, the rods and cones possibly acting like antennae, collecting the electrons and conducting them to the central organ; light of different wave lengths he supposes to correspond to electrons of varying speed, and Purkinje's phenomenon is explained on the assumption that the electrons from red

[1] *Bibl* No. 89. [2] *Bibl.* No. 131. [3] *Bibl.* Nos. 167, 243, 244.
[4] *Bibl.* No. 206. [5] *Bibl.* No. 247. [6] *Bibl.* No. 371.
[7] *Bibl.* No. 341. [8] *Bibl.* Nos. 378, 389, 395, 412. [9] *Bibl.* No. 78.
[10] *Bibl.* No. 200. [11] *Bibl.* No. 271. [12] *Bibl.* No. 381.
[13] *Bibl.* No. 402.

have less energy than those from blue, and therefore when the intensity of illumination falls the red light fails to stimulate and appears black; Schanz further suggests that perhaps in congenital colour-blindness the pigment epithelium is not absolutely black, and that therefore colours of certain wave lengths are not absorbed. This is all very attractive, but let us see what Pearson, Nettleship and Usher[1] say about the colour perception in albinism.

"Colour perception in albinos appears to be as good as in other people[2]....Thus in 1848 Wartmann tested an albinotic brother and two albinotic sisters aged 14, 12 and 10 and their albinotic cousin aged 5; further he tested two albinotic cousins of another pedigree, aged 32 and 25, with great care and found colour vision normal in all six. In 1881 Dr von Forster recorded the result of an exhaustive examination of the colour perception, by general methods, in a perfectly albinotic, well-developed girl aged 18 with 6 D. of myopia and acuteness of vision corrected, one-sixth of normal; her colour perception was excellent even for the finer shades. In the case of an albino lady from Cape Town tested by Mr Herbert Parker in London there seemed to be a slight defect for green, but as the patient was but poorly educated, had very bad sight and was examined only once, the case is not a very strong one. In the family of Fig. 311...the non-albinotic brother had well-marked colour-blindness and had changed his occupation in consequence, but the two living albinos themselves were found to have normal colour vision. In Fig. 46 an incompletely albinotic boy had perfect colour-perception although his father and several other relations (none of whom showed any trace of albinism) were colour-blind. The colour-perception was also examined in sixteen albinos by Mr C. H. Usher, two by Mr Lawford, five by Professor La Gleyze, one by Mr Fisher, one by Professor Koster and one by Mayerhausen. In the 37 cases referred to in this paragraph decided defect was found in Mayerhausen's case only."

It is clear that albinism carries with it no liability to defective colour vision; it remains to be considered whether the clinically complete albino has no pigment demonstrable on microscopic examination of the retinal pigment epithelium. Again on reference to the memoir quoted above containing an analysis of all available evidence on the subject and to a later paper by Usher[3], we may conclude as follows: it is usual in albinism to find no pigment in the iris stroma and no pigment in the choroid, but clinically complete albinism cannot be held to infer complete absence of pigment from the retinal pigment epithelium, though in two cases examined the condition may be inferred to have held; in one of the cases the eyeball was that of an infant and no trace of pigment was found in the eye. We know that the pigment of the retinal epithelium is laid down very early in foetal life, and we think we may safely assume that this finding would not have been reversed had the infant survived to adult life; in the second case sections of the iris only were examined after an iridectomy preliminary to cataract extraction in a case under Nettleship, and the posterior epithelium was found to be absolutely without pigment. Again, we think it may be assumed that there would be no pigment in any part of the retinal epithelium of this case, for usually the pigment is found to be most abundant at the back of the iris, and least so in the cells of the true retinal portion of the epithelium. We have no information concerning the colour vision in either of these cases. In all other cases examined (with the possible exception of Buzzi's case of 1784) some pigment has been found in the retinal epithelium; it is described as 'brown,' 'very light,' 'of light brown tint,' 'much less than normal,' and so on; the defect would appear to be rather one of quantity than of quality, and in our ignorance of any corresponding change in its

[1] *Bibl.* No. 364, Part II, p. 294.

[2] Dr Sachs, himself an albino, writes in 1812: "Leucaethiopes nec achromatoblepes nec acyanoblepes sunt. Sibi quidem ipsi omnes colores, eosque non aliter ac ceteri plerique Homines cernere atque discernere videntur." *Bibl.* No. 43, p. 75.

[3] *Bibl.* No. 403.

absorptive properties we must admit that the evidence we have of normal colour vision in the case of many albinos cannot be held to definitely disprove the proposition that the retinal pigment plays some fundamental part in the mechanism of colour vision. We may add in this connection that quantity of pigment, as measured by fairness and darkness of individuals or by light and dark races, appears to have no association with colour sensitivity.

Thus we can find no convincing evidence that the pigment of the epithelium is or is not of fundamental importance in the mechanism of colour vision; the pigment of this structure is sensitive to light, but the changes in it induced by light are extremely slow. Evidently we are not yet acquainted with the real significance of this epithelium, which may well lie in some property other than that of its pigmentary content. The position is this—absence of pigment leads to albinism, a condition associated with serious disabilities of vision which used to be attributed to the lack of pigment, even though precisely the same disabilities of vision had been repeatedly noted in cases of Total Colour-Blindness where pigmentation was believed to be normal; we now know that the defective vision of albinism is probably not due to lack of pigment at all, and we have no reason to believe that the presence of pigment is necessary to vision. In Retinitis Pigmentosa, a disease in which there is marked degeneration of the pigment epithelium and of the rods and cones, starting in the periphery of the retina and slowly progressing towards the centre, we get an associated night-blindness at a very early stage of the disease: it has been suggested from this that the defect of the pigment epithelium possibly interferes with the formation of visual purple in the rods and is thus the source of the night-blindness, yet there is no night-blindness in albinism when pigment is absent, and moreover there may be no colour-blindness in retinitis pigmentosa when the epithelium has degenerated. It would appear that the dependence of the formation of visual purple upon the pigment epithelium is due to some other property than that of the presence of pigment, and the integrity of the epithelium does not appear to be necessary to colour vision. Remembering that light can only produce effect when it is absorbed, the obvious suggestion that follows is that perhaps the visual purple may be the factor concerned which is able to discriminate between different wave lengths, and set up some corresponding impulse which ultimately leads to the sensation of colour. Visual purple is a photo-chemical substance found characteristically in the outer limbs of the rods of the retina, certainly of most vertebrates and probably of all, possibly also in invertebrates, but there has been a considerable difference in the conclusions of various investigators on this point; it has certainly never been demonstrated to be present in cones, and if it is present in the rod-like cones of the fovea in man, or in the case of those creatures whose retinae are said to be free from rods altogether, it can only be in very minute quantities; it is found in certain nocturnal animals, *e.g.* the owl, in large quantities and in other nocturnal animals, *e.g.* some bats; its presence has been denied by some authorities, and has been demonstrated by others to occur in very minute traces only. For a full summary of the discoveries concerning visual purple, with bibliographies, we must refer the reader to Hess[1] and Parsons[2] and must confine ourselves here to a brief statement

[1] *Bibl.* No. 354, pp. 733–8. [2] *Bibl.* No. 371, pp. 12–15.

only of the chief properties demonstrated to hold for this substance. The most significant feature of visual purple is its sensitiveness to light; it bleaches under the action of light and the intensity of the action varies for different wave lengths, and is for most creatures at a maximum for a wave length of 500 $\mu\mu$; in fishes the action is at a maximum at a wave length of 540 $\mu\mu$, which is of special interest if we believe, following Hess, that fish are colour-blind. The following very striking diagram suffices to indicate that there are close relations between the thresholds of vision of the dark-adapted human eye, the absorptions of light by the human visual purple and the energies absorbed in bleaching rabbit's visual purple for different spectral lights. If we invert the

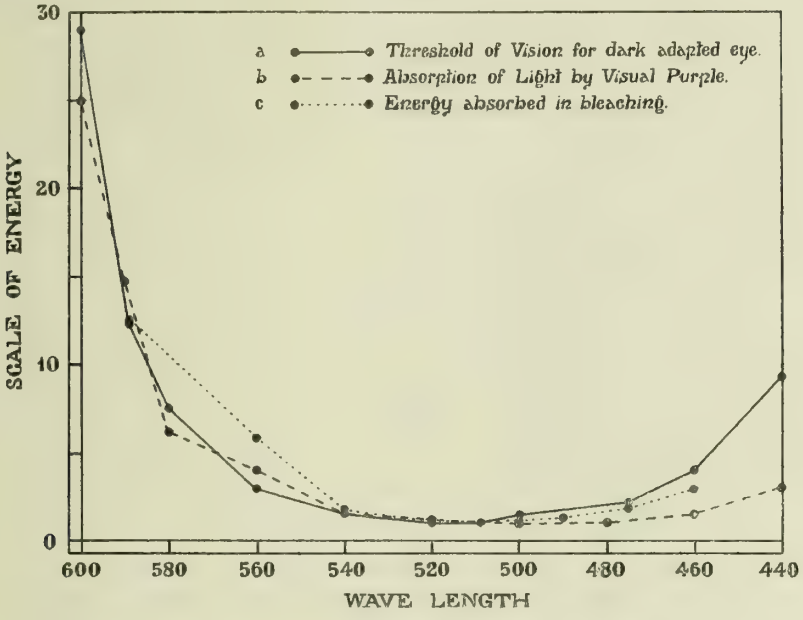

DIAGRAM 8. After V. Henri and Larguier des Bancels, *Journal de Physiologie et de Pathologie générale*, T. 13, pp. 841–56, 1911.

Curve *a* gives the relative luminous energy needful at the threshold of vision for the dark-adapted eye, from the observations of Schaternikoff on man. Unit energy at 509 $\mu\mu$.

Curve *b*. Quantities of light which must fall upon the same solution of human visual purple for this solution to absorb the same quantity of energy, from the observations of A. König. Unit of light at 500 $\mu\mu$.

Curve *c*. Quantities of energy producing the same amount of bleaching in the visual purple of rabbits, from the observations of Trendelenburg. Unit energy at 509 $\mu\mu$. (Trendelenburg determines the "velocities of bleaching" by the reduced absorption of the visual purple after timed exposures to the given light. One would like to have a curve for the first sensible bleaching for comparison.)

curve for bleaching, we obtain the "bleaching values" of the several spectral lights and this will clearly follow closely the human achromatic scotopic luminosity curve, and accordingly the luminosity curve in a good light of the totally colour-blind man. We cannot say what significance, if any, can be attached to this association, or whether on the basis of it the possibility of visual purple being primarily concerned with vision in a dim light is a reasonable proposition; the extreme rarity of the substance in certain nocturnal animals is against such a view, but again, on the other hand, since the substance reacts strongly to blue light and hardly at all to red light, the proposition might explain how in the evening blues become relatively more conspicuous and reds

relatively dark. When visual purple has been bleached by the action of light it is rapidly regenerated on being placed in contact with the retinal pigment epithelium, even in the excised eye through the tissues of which no blood is circulating. We must conclude with regard to visual purple that we have no knowledge that it is intimately concerned with the mechanism of colour vision, but that an examination of its qualities in the human totally colour-blind eye would be of great value and might throw some light on the nature of the defect. We do know, however, from the well-known observations on optograms, that visual purple is concerned with the formation of images in the retina.

The Neuro-epithelial Layer of the Retina. At a first glance the consideration of the function of the rods and cones would appear to offer some facts of real significance to aid in the solution of such problems as are concerned with the mechanism of colour vision, but we very soon find ourselves faced with innumerable difficulties. At the very outset of the enquiry when we ask ourselves what anatomically is the distinguishing criterion between a rod and a cone we can give no satisfactory answer; certain elements of a particular retina we should all agree to be cones from their shape and relationships and properties internal and external, but I know of no criteria which must be fulfilled in order to constitute any individual element as definitely a rod or a cone. We have seen that there appears to be a definite association of function with the distribution of rods and cones in the human retina and that where, for example, cones are plentiful distinctness of vision is at a maximum and colour sensitivity is correspondingly high, but we are nevertheless far from being in a position to state that cones are primarily concerned with the mechanism of colour vision. When we consider that in cases of retinitis pigmentosa, a disease in which the chief pathological finding indicates a severe degenerative process specifically affecting the retinal rods and cones, we get a gradual progressive defect of visual acuity and no corresponding defect of colour vision, which remains practically normal so long as there is any vision for form left at all, we should at any rate pause before regarding the rods and cones as of fundamental importance in the discrimination of colour, although we may readily grant the dependence of visual acuity on their integrity. We know of no acquired[1] pathological condition affecting only cones and leaving the rods healthy, and all attempts to correlate absence of rods or cones in animals with the ability or inability to discriminate between different colours have led to evidence which is not in the least conclusive; we have spent much time in trying to collect information of a comparative nature which would help our investigation, but are inevitably driven back to the conclusion that the primary need is a *post-mortem* examination of a colour-blind eye, and we feel that until such an examination has been made it is perhaps not economical to plan elaborate programmes of work which might well be shown by such an examination to be off the lines upon which progress can be made. It is astonishing enough, considering the number of enlightened men who have been known to be colour-blind and the frequency of the defect in the male population of Europe, that only one opportunity to seek for a correlated structural defect has yet

[1] There is evidence of congenital developmental defect affecting primarily the cones of the central area in Larsen's case of total colour-blindness (*Bibl.* No. 399), and one leading to a reduction in the number of rods and anomalies of the pigment epithelium in Oguchi's case of night-blindness recently published (*Bibl.* No. 424).

occurred, for a little advertisement of the need is surely all that is necessary—yet time goes on and we seem no nearer to the possession of such valuable material.

We are told by Edridge-Green that rods are not percipient elements at all and that their function is to secrete visual purple, that is to say they constitute a type of secreting gland; yet creatures said to have only rods in their retinae undoubtedly see; is Edridge-Green's theory wrong or are the so-called rods really a species of cone? Again, we have become accustomed to regard visual purple or some corresponding photo-chemical substance in the retina as necessary to vision; what occurs in retinae which contain no rods? Is the observation that such retinae are to be found in error or is the belief that only rods secrete a photo-chemical substance in error or is the supposition that a photo-chemical substance is necessary to vision at fault? All these questions need to be answered and should present no great difficulty once we know what we really mean by a rod and a cone, but in the present state of our knowledge it seems to me perfectly idle to talk of the function of retinal rods and cones—the present classification of rods and cones on the basis of general shape, relationships to other retinal structures, reaction to light, position of nucleus, and presence of visual purple is entirely built upon what is seen in the human retina and when applied to lower forms of life breaks down and raises a number of questions which we are unable to answer. If the position be that what is called a cone in one retina resembles a rod in the retina of another creature or *vice versa*, surely the only reasonable classification must be based on function which in its turn depends upon an associated characteristic minute internal structure.

What do we know of the minute internal structure of retinal percipient elements? On seeking an answer to this question the following beautiful pictures were found amongst a considerable number of other less well-defined examples: now if Figs. 1 and 2 may be accepted as free from effects due to *post-mortem* shrinkage,

Fig. 1. Rod from retina of the bird *Uria troile.*

Fig. 2. Cone from retina of *Uria troile.*

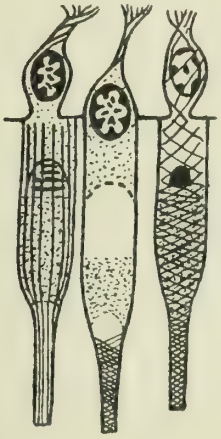

a b c

Fig. 3. Cones from *Thalassochelys.*

DIAGRAM 9.

After Franz. Oppel, *Lehrbuch der vergl. mikroskop. Anatomie der Wirbeltiere*, Bd. VII, S. 17 and 21, 1913. (By permission.)

observer's technique and observer's imagination, they present certain well-defined differences which must surely represent different functions and a basis for classification might be found, but when we turn to Fig. 3 the difficulties of the problem become manifest; Fig. 3 belongs to a creature said to have one type of percipient element only, but surely we must on the contrary hold that this creature has a minimum of three types of percipient elements and the physicist might suggest their corresponding behaviour under the stimulation of light waves.

Clearly we are not in a position yet to offer any suggestion concerning the function of rods and cones in the mechanism of colour vision: we are seeking further knowledge, at first hand, on this aspect of the subject. Authors referred to in this section include Greeff[1], Franz[2], Hesse[3], Kallius[4], and Patten[5].

On the assumption that the mode of regeneration of a degenerated structure has some bearing on the probable function of the structure we are tempted to add here the following quotation, taken from Uhlenhuth[6]:

"If an eye of a larva of the European Fire Salamander is severed from the optic center and is grafted with a flap of surrounding skin to another larva of the same species, the retina of the grafted eye undergoes a more or less severe degeneration, but after a short time begins to regenerate and the normal condition of the retina may be established completely.... Pigment epithelial cells detach themselves from the pigment epithelium and migrate freely into the detritus masses; here they assume phagocytic function so that the masses of detritus are quickly removed from the eye. In the beginning, the part regenerated is an undifferentiated mass of cells. Later on an epithelial-like granular layer is formed which by regeneration of fibrous layers is differentiated into the inner and outer granular layers and into the ganglionic layer. Finally the rods and cones regenerate from the outermost cells of the outer granular layer. At this time the activity of the pigment cells is stopped entirely. Eyes have been preserved $3\frac{1}{2}$ years after having been grafted showing all the functional elements of the retina present, though the grafted eyes are severed from nerve centers."

We think it is of significance in any consideration of the function of rods and cones to bear in mind their apparently complete regeneration, when nutrition is supplied, whilst severed from all connection with the central nervous system. The author showed slides demonstrating the completely regenerated retinae and also showed a living specimen of *Amblystoma tigrinum* with an eye which had been grafted 8 months previously.

Colour Vision in Animals. The question of the colour vision in animals only concerns us in so far as it can throw light on the mechanism of colour vision in man, and thus suggest the probable nature of the defect in the colour-blind. If we can clearly demonstrate that a particular animal can discriminate between different colours by means of its visual apparatus and that some other animal is totally unable to perceive difference of colour, then we might reasonably seek for some corresponding difference in retinal structure; but in our opinion we are hardly in a position to do this until we have more knowledge of the minute internal structure of rods and cones and of their range of variability with a classification of percipient elements on such a basis. Should we find definite changes in structure invariably associated with an ability or disability to discriminate between different colours, we might then assert that the retinal elements are primarily concerned in the mechanism of colour vision and should hope to confirm our assertion on a post-mortem examination of a totally colour-blind eye. Should we

[1] *Bibl.* No. 265. [2] *Bibl.* No. 361. [3] *Bibl.* No. 288.
[4] *Bibl.* No. 300. [5] *Bibl.* No. 251. [6] *Bibl.* No. 384.

on the other hand find no such invariably associated differences of structure with function, we can assuredly not assume that the retinal structures are not primarily concerned in the mechanism of colour vision; the source of the defect in such a case may well be one of incapacity to pay attention, or to look at what is seen, in other words the defect in such a case may rest entirely with the brain which is unable to bring through to consciousness the analysis which may have been achieved in the retina.

The problem of the determination of colour vision in animals is an exceedingly promising field of work, but it is one in which the greatest caution is needed and the unwary will certainly fall into innumerable pitfalls at every point of the investigation. There are clearly two distinct sections to this problem, one of which is concerned with anatomical considerations and the other of which depends upon the determination of function: we have already indicated lines upon which, in our opinion, knowledge should be sought for the former section. With regard to the determination of function a great variety of investigations, many of them involving much patience and labour, have been

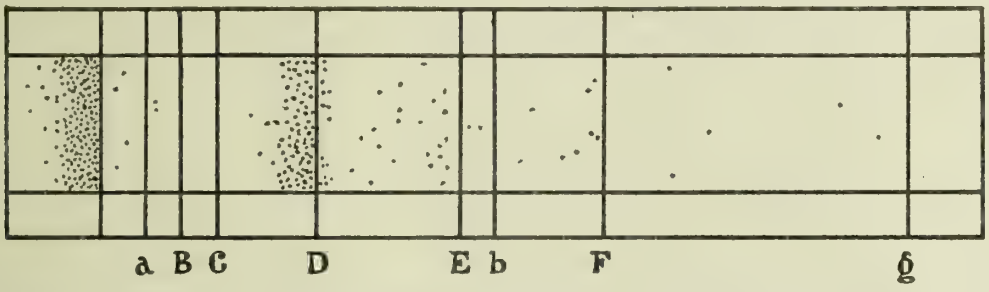

DIAGRAM 10. Influence of light of special wave lengths on *Bacterium photometricum*. After Engelmann, *Archiv f. d. gesam. Physiologie*, Bd. XXX, Pl. L, S. 95. Bonn, 1883.

carried out primarily in Germany, America, Belgium and in this country during the last fifty years or so, but the earlier experiments mostly fail to lead to any conclusions which can be accepted to-day in the light of further knowledge which has accumulated concerning the phenomena of vision, the reaction of tissues to stimuli and the specialisation of sensation in different animals: and of later experiments, those which are perhaps the most convincing to us—the experiments of Hess—are not by any means universally accepted. It is needful in all such experiments to recognise that apparent preference for a colour does not necessarily carry with it a visual perception of colour, for certain lower organisms are known to be extremely sensitive to the physical properties of certain wave lengths as was demonstrated by Engelmann[1] for the extreme case of *Bacterium photometricum*, which organisms, when exposed to the influence of the spectrum, grouped themselves as shown in Diagram 10.

Again, the Chameleon as we know changes the colour of its skin within limits according to the colour of its environment, and moreover if the animal is blinded the characteristic change does not take place; we cannot however deduce that the Chameleon perceives colour though it would appear as if colour has some specific action

[1] *Bibl.* No. 171.

upon its retinal structures which cause determining reflexes to come into operation, reflexes which are probably sympathetic in nature and quite unconnected with the central nervous system if we may allow our opinion to be guided by similar phenomena in some fish.

It is undoubtedly a fact that certain animals are very sensitive to difference of luminosity even though they cannot be demonstrated to distinguish between different colours, and the neglect of this factor in the earlier experimental work is one of the most serious pitfalls into which the observers fell; indeed any evidence based on experiments with colours which did not eliminate this source of error must be at once discarded. It appears, from an examination of the accounts of experimental work, to be relatively easy to demonstrate that animals perceive difference in luminosity and extraordinarily difficult to demonstrate, in such a way as to convince the scientist, that animals perceive difference in colour, which is of itself a fact of significance and predisposes one to the view that perhaps most animals are not capable of distinguishing between different colours; thus Yerkes[1], after a long series of experiments on the Dancing Mouse, concludes that if colour vision for this creature exists at all it is extremely poor, but on the other hand he was able to train his mice to distinguish between two lights differing in brightness by one-tenth only; Hess[2] demonstrated for certain fish that they have a luminosity curve which is closely similar to that of a totally colour-blind human eye and he further shows that a bait of one colour placed on a background of another colour, whose luminosity is the same as that of the bait, is ignored by the fish, whilst a bait of one colour placed on a background of the same colour but of a different luminosity is immediately snapped up. These experiments are very suggestive and Hess deduced from them the view that fish are totally colour-blind, but this conclusion has been challenged and has not met with general acceptance, and whilst the cautious scientist reserves his opinion, the fisherman continues to ply his art with many and gaily coloured flies. It is a sad loss that Hess is no longer alive to meet the attacks of his opponents in this field and to carry further his exceedingly ingenious methods of enquiry, but there are indications that such experimental work will be carried out along similar lines during the next twenty years in pursuit of a determination of colour sense in different animals.

Now, with regard to the specialised senses of animals, can we be sure that if an animal perceives differences which we perceive by means of our visual apparatus it also achieves the perception by similar means? Most assuredly we cannot. The little that we can insist upon concerning the greater sensitivity of many creatures to sound waves and their highly specialised tactile or olfactory sensitivities is sufficient to make us extremely cautious in making any assumption as to how any creature other than oneself perceives any single phenomenon. The observations made by Whitaker[3] and by Hartridge[4] on the flight of bats illustrates this point. Whitaker, having sealed the closed eyes of a *Vespertilio nattereri* with wax and satisfied himself that the creature was rendered absolutely blind, set the animal free in a room which was not known to it; the bat, after a few minutes of rather hesitating fluttering, appeared to fly about

[1] *Bibl.* No. 316.
[2] *Bibl.* Nos. 333, 343, 354.
[3] *Bibl.* No. 306.
[4] *Bibl.* No. 396.

quite freely, avoiding all obstacles in its flight; the author observed for example that it flew under chairs without the tips of its wings touching any part of the chair, also when he held a walking stick perfectly still in its path it swerved suddenly when only a few inches from the stick which it did not touch. Hartridge made similar experiments in what he believed to be an absolutely dark room; his bats avoided threads in their path and appeared to know whether the door was or was not sufficiently opened for them to pass through. Whitaker may of course have been mistaken in thinking his bat was at the time blind, but he states that scientists have made similar observations on bats whose eyes had been removed; Hartridge also may have misjudged the absolute darkness of his room, but the fact appears to be fairly well established that the bat avoids obstacles in its flight by some sense or senses other than that of vision in our sense of the word, and whether the particular sense which guides it be that of touch localised in the wing membranes or in the skin of the nose, or whether it be the highly specialised development of the ear, does not concern our argument and the warning it carries.

Another fact, which is, in the opinion of the writer, of some significance and certainly has a suggestive value, is the absence of all indication of a perception of colour in the daily associations of dogs, cats, horses, cattle and perhaps all mammals, but there appears to be a general consensus of opinion in favour of the belief that birds recognise different colours; indeed, brightly painted screens proved so effective as a lure for the attraction of the red-legged partridges of the Lesghian mountains, that the Russian government some years ago forbade the use of them in order to prevent the extermination of the bird[1]. When we examine the literature it appears that all attempts to demonstrate a perception of colour in mammals (excepting the monkey) have either failed to do so or are extremely unconvincing, whereas for hens and pigeons Hess[2] was able to define the limits of their visible spectrum which coincides, he considers, with ours at the red end and terminates short of ours in the blue-green region towards the short-waved end[3]; he was able, further, by fastening grain coloured green to the ground and scattering freely other coloured grain, to show that these birds quickly learned that green grains were of no use to them and never attempted to pick them up but quickly removed all the rest; they could evidently distinguish readily between red and green and other colours within the range of their visible spectrum, and the shortening of their range may be partly, if not wholly, accounted for by the absorptive properties of the coloured oil globules in their retinae. Similar observations were made by Hess for certain reptiles[4].

It is quite clear then that the available material concerning the comparative study of retinal structure and of retinal function is at the moment entirely inadequate for the purpose of throwing any light upon the mechanism of colour vision in man, but we hope that this state of affairs will soon be changed when retinal structures are classified on a basis which may be applied to all organisms, and when the need for more cooperation between the zoologist and the physiologist is fully appreciated. Some of the authors not yet referred to whose works have been consulted with regard to this

[1] *Bibl.* No. 238.

[2] *Bibl.* Nos. 308, 309, 354, 379.

[3] Honigmann confirms this conclusion and further demonstrates a hypersensitivity for the red end of the spectrum. See *Bibl.* No. 398.

[4] *Bibl.* Nos. 342, 354.

section are Graber[1], Lubbock[2], Bulman[3], Slonaker[4], Kinnaman[5], Torelle[6], Wery[7], Plateau[8], Porter[9], Hess[10], Nagel[11], Samojloff and Pheophilaktowa[12], Smith[13], Cole and Long[14], and Watson[15].

On concluding this general introduction one is struck by the elusiveness of the phenomena of colour vision and by the sadly little we really know about it; we talk of the range of the visible spectrum and of the variability of the range, as well as of the variability of the sensitivity to colour under constant conditions, but we give no measure of these factors, and indeed know little or nothing that we can express in definite terms of the variability, with regard to colour vision, of the individual from time to time or that within the race. Various attempts have been made to express such characteristics in terms of statistical constants which would enable us, if adequate, to compare races and individuals, and perhaps lead to a knowledge of some of the laws governing the phenomena, and we feel that much progress will most assuredly be made along these lines when suitable series of observations on a sufficiently large scale receive adequate statistical treatment. Houstoun has made notable endeavours in this direction and we feel that his microscopic apparatus for the measurement of sensitivity of colour discrimination, together with apparatus on the principle of Lord Rayleigh's instrument for measuring the differing amounts of homogeneous red and green spectral lights which must be combined to match a given homogeneous yellow, are valuable tools within the reach of some of us. Certain series of observations have already been taken but have up to now led to rather barren results, nevertheless further investigation along these lines is certainly needed.

It is of course extremely difficult to get an uncomplicated measure of the functioning of any sense organ; other factors complicate the reaction and are of surpassing difficulty to eliminate. The writer's personal impression, for example, after testing some 600 men and women with Houstoun's apparatus, is that the test is a very good test of all sorts of psychological traits, and tells the observer a great deal about the mentality of the subject under examination; it tells about his quickness of reaction and soundness of judgment, about his reaction to fatigue, his ability to profit by experience, his caution, his ingenuity in deducing facts, his honesty of purpose and so on, and we feel that divergences, from such factors, may far outweigh what is undoubtedly a real though less marked degree of difference in colour sensitivity. Similarly for Lord Rayleigh's apparatus, an analysis of the variations in readings from the same individuals from time to time with a careful investigation of the probable errors of observation in the individual needs to be undertaken before any results can be deduced from series of observations hitherto published, excepting the fact that the extreme readings, characteristic of anomalous trichromatism, to be considered later, are evidently not extreme variations of the normal frequency distribution of readings, but constitute a definite anomaly. Nevertheless, we feel that much can be learned from these instruments if all disturbing factors are carefully guarded against and allowed for, and the observations receive the full value of modern statistical tools.

[1] *Bibl.* No. 179. [2] *Bibl.* No. 201. [3] *Bibl.* Nos. 208, 255 [4] *Bibl.* No. 246.
[5] *Bibl.* No. 275. [6] *Bibl.* No. 285. [7] *Bibl.* No. 292. [8] *Bibl.* No. 303.
[9] *Bibl.* Nos. 289, 304. [10] *Bibl.* Nos. 308, 309, 333, 334, 342, 343, 354, 379, 382.
[11] *Bibl.* No. 311. [12] *Bibl.* No. 313. [13] *Bibl.* No. 365. [14] *Bibl.* No. 330. [15] *Bibl.* No. 338.

TOTAL COLOUR-BLINDNESS

A. CONGENITAL. B. ACQUIRED.

A. *Congenital total Colour-Blindness*, or achromatism as it is better described, is undoubtedly a very rare condition, for after a detailed examination of the literature we have only succeeded in finding records of about one hundred and nineteen cases published during the last one hundred and forty-seven years. If we examine the accounts of these cases in detail we find a rather unusual amount of uniformity in the phenomena described; this uniformity is in itself a feature which is so contrary to what experience has led us to expect, with regard to the variability in all natural phenomena or in the manifestations of defect in structure leading to incomplete function, that we feel the need to be specially cautious and critical and to direct our endeavours particularly to the search for links between this condition and the other types of anomaly in colour vision.

We are told very generally that all colours to the achromatic eye are differentiated by their light and shade only, black and white are recognised and differentiated and all other colours are represented as greyish, the tone varying with the colour and its brightness; coloured pictures are to the totally colour-blind indistinguishable from steel engravings, and the solar spectrum appears to them as a streak of light of graduated intensity frequently described as "brightest in the middle." Certain other factors are found so frequently associated with total colour-blindness that they have come to be recognised as a definitely associated syndrome and are sought for in every case; such symptoms are (i) amblyopia, (ii) photophobia, and (iii) nystagmus; with these almost universally associated symptoms we might perhaps include (iv) shortening of the red end of the visible spectrum, and (v) displacement of the brightest part of the spectrum from the yellow towards the green; with perhaps less general features of the condition we would mention (vi) the frequent presence of central scotomata in the fields of vision—we say "perhaps less general" in this case because the inability to demonstrate a central scotoma does not necessarily carry with it the positive fact of its absence.

To consider these characteristics in greater detail. It is customary to accept as a fact the statement that in total colour-blindness no colour is seen and the whole of nature is represented to the affected individuals in black and white or shades of grey; this may be true but it is an extremely difficult fact to demonstrate and I can quote no single case in which any two different colours ascertained to have the same luminosity value have been stated to be absolutely undifferentiated, and though it appears to be a fact that the achromatic eye is able to match every colour of the spectrum with a suitably chosen grey, this test has not been made in the great majority of our recorded cases and in its absence we should be sorry to insist upon the totality of the inability to discriminate between different colours in all cases included under this heading. Grunert however speaks in no uncertain voice, he writes " Wie überall, so

ist auch bei unseren Fällen die Farbenblindheit eine ausnahmlos sich auf alle Farben erstreckende...[mit Recht wird der bekannte Fall von Becker bei den neueren Bearbeitungen ausser Betracht gelassen; denn das sonst ganz farbenblinde Mädchen erkannte eigentümlicher Weise noch Braun[1]]." Six years later Nettleship himself gave us a warning on this point when he wrote "there is always colour-blindness, and in the severer cases it is, as the title indicates, total, but in some milder cases the want of colour sense is less pronounced[2]." Now Becker's case is of extraordinary interest as being one of the only two cases on record of unilateral total colour-blindness which cannot definitely be attributed to pathological processes; the author believed the case to have been, with great probability, congenital, and the child at the early age of 3 years noticed and called attention to the fact that as she lay in bed the carpet differed in colour when she lay on her right and left sides; there was no associated amblyopia and no photophobia or nystagmus or other defects; at the age of 17 the vision in each eye was $\frac{6}{6}$ with correction for myopia of similar amount in each; the fundus was normal and fields were full; a fact of significance which perhaps tells in favour of retaining the case in our series is that a maternal uncle was colour-blind[3]—unfortunately we have no knowledge of the nature of his colour-blindness. Now, it is right to receive this case with caution but we are convinced that it is not justifiable to reject it on the basis that the girl was able to recognise brown, and we are not at all sure that it is justifiable to reject it on the grounds of the associated $\frac{6}{6}$ vision with absence of photophobia and nystagmus and normality of the visible spectrum: we shall consider these points again but in the meantime will deal with the second case of unilateral total colour-blindness described by Piper in 1905[4]. This case is that of a man aged 49 who from his youth had difficulty in recognising and distinguishing between colours; he never had any eye disease or been under treatment for his eyes until twelve years previously when he had asked for spectacles to be prescribed on account of asthenopic symptoms. After a very full and detailed examination the author concludes that the left eye[5] is totally colour-blind and the right eye[5] violet-blind with some weakness in the red and green sense also. Now the description which this man gives of the different regions of the spectrum as seen by his totally colour-blind eye does suggest that the whole range is not to him a streak of light of graduated intensity though it is not far removed from this; he describes most of the regions as bluish or grey-blue, but when he describes 587 $\mu\mu$ as sky blue, 557 $\mu\mu$ as grey and lilac, 499 $\mu\mu$ as yellowish grey, and 477 $\mu\mu$ as reddish grey, we must suspect that he sees in the series something more than different amounts of light and shade though that "something more" is evidently far removed from what we think he ought normally to see. Probably everybody reading the full account of this case would agree that this eye should be classed as totally colour-blind, but also it is difficult to escape from the acceptance that the eye is not strictly speaking achromatic and we must pause therefore before rejecting a case from the series on the plea that brown, say, is recognised. Again, we

[1] *Bibl.* No. 281, p. 171.
[2] *Bibl.* No. 337, p. cxxviii.
[3] See *Bibl.* No. 128, Fig. 399.
[4] *Bibl.* No. 297.
[5] We think this is a misprint in the author's concluding statement. The right eye appears to have been the totally colour-blind member.

have, as in Becker's case, an almost total absence of the conditions laid down as characteristic of the congenital anomaly, e.g. Piper's case had no nystagmus, no photophobia, no central scotomata, the visible spectrum was normal in length and had its maximum brightness in the yellow-orange as for the normal eye, but the visual acuity is reduced in each eye and is $\frac{6}{36}$ for the right, $\frac{6}{18}$ for the left eye, not improved by glasses. Now the author himself appears to accept the case as one of pathological origin on the grounds of the absence of the conditions usually regarded as characteristically associated with congenital total colour-blindness, and he may be right in his conclusion, but we maintain that he is not in a position to say that these usually associated conditions are invariable accompaniments of the congenital anomaly; the author makes no suggestion as to the nature of the pathological defect but notes paleness of the temporal side of the papillae more marked in the right eye, with a slight peripheral retinitis in the left eye only; the maculae are described as normal, perhaps a trifle granular in the right; all will agree that such signs as these are consistent with a perfectly normal sensitivity for colour. Again, the case of Harris described by Huddart in 1777[1] is accepted by Grunert and others as a case of congenital total colour-blindness, though we suspect the case was more truly achromatic than Becker's case; we are told "that he could never do more than guess the name of any colour, yet he could distinguish white from black or black from any light or bright colour; dove or straw colour he called white and different colours he frequently called by the same name though he could see a difference between them when placed together." The acceptance of this case is of considerable importance; for by doing so one is committed to the view that congenital total colour-blindness may exist in association with good visual acuity, for Harris notes that other children "by means of their difference of colour could see the cherries at a greater distance than he could, though he could see other objects at as great a distance as they"; further there is no mention of photophobia or nystagmus in this case and the only one of his affected brothers who was examined was almost certainly a case of dichromatic vision. This case has never, so far as we know, been rejected because Harris could see a difference between colours when placed together, but its rejection has been suggested on the grounds of the absence of amblyopia, which brings us to another point.

The temptation to reject a case from the series on account of its good visual acuity is very great, for the severity of the amblyopia is so striking a feature in the great majority of cases, and indeed it is usually through this symptom that the case comes into the hands of the ophthalmologist. Nettleship, writing in 1887, says: "I have as yet seen only one totally colour-blind person, a female, who was not amblyopic and only two or three who were not decidedly day-blind[2]." When we examine the reports of cases in which visual acuity has been definitely stated to be diminished—seventy-eight in number—we find that it is the exception for the visual acuity to be higher than $\frac{1}{3}$ of the normal, and it is very frequently as low as $\frac{1}{10}$; in many cases it is merely stated that amblyopia is present and in others that the case is typical, and in cases in which one sibling is described, other members of the family are said to be similarly affected;

[1] *Bibl.* No. 34. [2] *Bibl.* No. 198.

we have, however, definite evidence of what may be conceded to be total colour-blindness in association with good vision in five cases, viz. (i) Nettleship's case quoted above; (ii) Huddart's case quoted above; (iii) Becker's case quoted above; (iv) Raehlmann's case[1], and (v) Galezowski's case[2]. Of cases (i) and (ii) we are able to add no more to what has already been stated; case (iii) would appear to be atypical in every single particular, excepting achromatism, which Grunert and others do not accept; the case was unilateral, the vision perfect, no nystagmus or photophobia are mentioned, the spectrum is unshortened and its brightest part is in the region of the sodium line. Case (iv) is again atypical in all respects, the patient, a female, had had $\frac{6}{6}$ vision, no nystagmus or photophobia are described, the visible spectrum was *lengthened* at both ends, and though the brightest region was in the green, the yellow region appeared like a black streak; this patient had a son with dichromatic vision and her father, her paternal aunt, and her sister's son were "colour-blind[3]." Case (v) again is not at all helpful, the author describes a man of letters, aged 46, who had known no colours since infancy, all objects appeared to him black, grey or white; he had myopia and his eyes were very weak, but we are told that his vision was good and he could read small print; he had nystagmus; one cannot fail to feel doubtful of this good vision in a myope who had come to consult an ophthalmologist about eyes which were very weak.

We think the conclusion is inevitable—perfectly good vision is not incompatible with total colour-blindness, but where it is found the whole picture is so modified from that which is characteristic of the usual congenital state, as to suggest some fundamental difference in the (?) anatomical source of the colour-blindness, and we hope to be able to obtain further light on the nature of this difference when we consider the question of acquired total colour-blindness. It is surely of significance that in at any rate three of these five cases relations were known to be "colour-blind," suggesting that the defect was inherent and not an acquired pathological state. That the amblyopia of the totally colour-blind is in any degree secondary to errors of refraction in these people is absolutely negatived by an examination of the facts; of fifty cases in which the refraction has been measured, twenty-five were hypermetropic or had hypermetropic astigmatism, eighteen were myopic or had myopic astigmatism and seven were emmetropic; those stated to be emmetropic were mostly amongst the severely amblyopic, and in the other cases the errors were usually small and such as would produce no amblyopia under ordinary conditions. The question then arises as to whether there is evidence of any defect in the retinal structures of the fovea in these cases which could possibly account for the amblyopia as well as for the colour-blindness; and here we must admit at once that only a microscopic examination of a congenitally totally colour-blind eye can give us positive information, for if there is such structural defect underlying the phenomenon it is extremely unlikely that such would be demonstrable by the ordinary ophthalmoscopic examination; it is true that in a number of cases we are told that the papillae are pale[4]; we read of a doubtful haze or congestion about

[1] *Bibl.* No. 118. [2] *Bibl.* No. 96. [3] See Fig. 385.
[4] *Bibl.* Nos. 125, 144, 217, 281.

the yellow spot[1]; of slight pathological changes in the region of the fovea[2]; and we find repeated reports of a yellowish-red patch in the macula region[3]; but in the great majority of cases we are told that the fundi were normal and no pathological changes were noted in the macula region; undoubtedly such changes as have been noted are repeatedly described in individuals having a perfectly good vision for form and colour, and all that we can insist upon is that absolutely normal ophthalmoscopic appearances may be found in association with severe amblyopia and total colour-blindness of congenital origin. We find two records of ophthalmoscopic examinations of totally colour-blind eyes under red free light, by which means it is possible to demonstrate the yellow coloration of the macula region: the observers, Wölfflin[4] and Waardenburg[5], each report of his case that no yellow colour was present in the macula region, and that further in one case the customary oval macula reflex was absent; it is deduced from this that definite structural developmental defect of the macula region is indicated. We have no knowledge of the colour vision in certain cases of albinism such as those examined after death by Manz[6], by Fritsch[7] and by Carron du Villards[8], or during life by Affolter[9] in which no yellow colour was found at the macula, but in other cases of albinism, as Usher[10] reports, yellow colour is present at the macula, and we can hardly regard it as at all probable that this factor alone is the source of the defective vision in either albinism or total colour-blindness.

It is surely extremely suggestive that in a condition such as albinism, so curiously resembling total colour-blindness with regard to its typical disabilities of vision, and similarly characterised by amblyopia, photophobia and nystagmus, the only four cases in which microscopic search for a fovea has been made (Nettleship[11], Usher[12], Fritsch[13], Elschnig[14]) were all found to have no fovea or an imperfectly developed one, and Ichikawa[15], who examined the macula region of six living albinos with the ophthalmoscope, found that there was no differentiation corresponding to the appearance of the macula and fovea in the normal eye, and that the arrangement of the retinal blood vessels at this region was different from that seen in normal eyes, in that instead of converging regularly towards a fovea they met and crossed each other irregularly[16]. Usher concludes, with regard to albinism, "that pending further investigation of the macular region in the human eye there is reason to regard the imperfectly developed or absent fovea as possibly the chief cause of the defective vision and nystagmus." It is a fact of great significance that in a condition characterised by frequent gross developmental errors in the foveal area, no associated defects of colour vision are found; we cannot at once assert that total absence of any differentiated foveal area is compatible with normal colour vision, but such is obviously suggested and requires verification. To continue our comparison between the two conditions of albinism and congenital total colour-blindness, we find that the chief determining characteristics of each disease, namely absence of pigment in the former and colour-blindness in the latter, are present in the one case only; the totally colour-blind individual has, or may

[1] *Bibl.* Nos. 144, 198. [2] *Bibl.* Nos. 159, 279, 335. [3] *Bibl.* Nos. 274, 276, 284, 323, 353.
[4] *Bibl.* No. 423. [5] *Bibl.* No. 422. [6] *Bibl.* No. 123. [7] *Bibl.* No. 307.
[8] *Bibl.* No. 62. [9] *Bibl.* No. 376. [10] *Bibl.* No. 403. [11] *Bibl.* No. 301.
[12] *Bibl.* No. 403. [13] *Bibl.* No. 307. [14] *Bibl.* No. 360. [15] *Bibl.* No. 362. [16] *Bibl.* No. 403.

have, a normally pigmented fundus and the albino has, or usually has, normal colour vision; if then the symptoms common to the two cases should be proved to be due to defective development of the fovea, we might venture to hazard a prediction that some further associated defect is added to this in the case of congenital achromatism, for if the developmental error in the two cases differed in degree only we should expect to find colour-blindness in at least some proportion of our cases of albinism, and we have no evidence to support this expectation; our prediction is supported by the fact that in congenital total colour-blindness we may have certain features in addition to the achromatism which are not usually found with albinism, namely, the frequent presence of central scotomata in the field of vision and alterations in the visible spectrum. It is difficult to form any estimation of the true frequency with which central scotomata are present, but of the thirty-three cases in which a definite statement has been made, we are told that they were found in thirteen cases and were not demonstrated to be present in twenty cases; now in consideration of the extreme difficulty in detecting the presence of a small scotoma, when there is an associated nystagmus, we cannot feel justified in assuming that where scotomata have not been demonstrated they are necessarily absent, nevertheless some cases have been examined with such care and elaboration as to give us confidence in the statement that scotomata are not always present in cases of congenital total colour-blindness. Hess held this view in 1902, when he concludes, "Bei unkomplizierten Fällen von totaler Farbenblindheit ist ein zentraler Gesichtsfeldausfall nicht vorhanden"; but other authorities did not agree with this conclusion, and a good deal of rather bitter controversy has centred round this point by those who supported the hypothesis of colour vision being a function of the retinal cones only, and who appear to have held the view that this theory was inconsistent with a demonstrated perception of form in the region of the retina where cones only are present. When Grunert wrote, examination for central scotomata had been made in nineteen cases of total colour-blindness; in eleven cases (including the anomalous case of Raehlmann's) no scotomata were found, eight cases gave positive results, that is to say, a percentage of 42·1 cases had central scotomata; including cases examined since that date 39·4 per cent. of cases have given positive results. Thus with a tendency to more elaboration in methods of testing the percentage of demonstrable cases of central scotomata has not increased, and this fact, though the number of cases is very small, does, so far as it goes, bring a measure of support to Hess's conclusion.

To consider now the question of the visible spectrum as seen by the totally colour-blind of this section: there seems to be no doubt whatever that in the typical case the spectrum described by these people is identical with that seen by the normal eye under the condition of dark adaptation, that is to say, the stimulative power of the long-waved rays is absent or diminished, the maximum stimulus is received from the green region of the spectrum instead of from the yellow, and the stimulative action of the short-waved rays is markedly increased. It has not been customary to examine the visible spectrum in the case of albinism, but Rugg Gunn[1] investigated

[1] *Bibl.* No. 366.

the point in nine albinos in 1914, and Usher has further considered the question; of Rugg Gunn's cases two were children, and he considered their tests unsatisfactory; six of them, he thought, were negative—they said the greatest brightness was in the yellow and they claimed to see the red end of the spectrum; the ninth was a young man with a high degree of myopia, a very pure albino with snow-white hair and irides practically devoid of pigment—he could see no red end of the spectrum at all, and said the brightest portion was green; this man was not colour-blind, and could distinguish all colours except red. Usher writes (Nov. 15, 1924):

"A male albino, aged 54, examined with a large spectroscope yesterday and a small one to-day could see the colour at each end of the spectrum fully, I should say, when allowance is made for nystagmus and defective vision; it was almost the same as two of us saw. The brightest part to him is in the yellow.'

Thus it would appear to be usual in albinism to find a normal visible spectrum, and we must assuredly search for some very fundamental defect in the case of congenital colour-blindness which is absent from the case of albinism. Of the thirty-four cases of total colour-blindness in which the spectrum has been examined, the brightest region in every case except two is described as being in the green or displaced towards the green, the two exceptions being Becker's[1] anomalous case and a case described by Magnus[2]; the shortening of the red end of the spectrum is not so uniformly described; we are told of normal limits in nine cases.

The following table shows the resemblances and differences between the manifestations of these two conditions and the condition of the normal dark adapted eye.

	Total Colour-blindness	Albinism	Dark adaptation
Onset	Congenital	Congenital	—
Amblyopia	Present	Present	Present
Nystagmus	Present	Present	Absent
Photophobia	Present	Present	Present
Retinal pigment	Normal	Deficient	Normal
Colour vision	Absent	Normal	Modified
Central scotomata	Frequent	Absent	Present
Red end of spectrum ...	Usually shortened	Usually normal	Shortened
Brightest region of spectrum	In green	In yellow	In green
Light sense	Normal or raised	—	Raised
Adaptation time	Reduced	—	Reduced or absent
Vision in lowered light ...	Improved	Not improved	—
Fovea centralis	Present but abnormal in only case examined	Usually defective or absent	Normal
Sex incidence	57·5 % ± 3·2 males	55·8 % ± 0·9 males	—
Frequency	Very rare	Relatively common	—
Consanguinity in parents ...	In 27·40 % of cases*	In 29 % of cases	—
Associated defects	Rare	Frequent	—
Hereditary transmission ...	Usually confined to one generation	Marked	—
Prognosis	Condition is stationary	Some improvement may occur	—

* Probably the percentage should be much higher as explained in the text.

Certain facts appear to indicate that in the dark adapted eye the macular region is not functioning, and vision is being carried on in the more peripheral areas. This is

[1] *Bibl.* No. 128. [2] *Bibl.* No. 143.

certainly suggested by such conditions as Retinitis Pigmentosa, in which the peripheral areas of the retina first become atrophied and the condition is shown clinically by night-blindness, and a normal visual acuity and colour vision in a good light up to the period of the late stages of the disease, when the atrophic processes have closed in upon the macula itself; also it is quite simple, as Usher has suggested to us, to demonstrate in a dark room that the macula is blind in light sufficient for the peripheral parts of the retina to perceive white objects. Take a 20 mm. square piece of paper, observe it at 1′ or 2′; reduce the light until it is invisible, then turn the eye up or to one side and it again becomes visible[1]. The absence of nystagmus in the dark adapted state does not in the least detract from the interest of the general resemblances in the light of our knowledge that nystagmus is to be looked for in any condition in which, during early infancy, some factor is present preventing a clear image being received upon the fovea, and thus interfering with the normal development at this time of the co-ordinating cerebral centres concerned in the movements of the eyes. In dark adaptation the eye may be described as being in an irritable state: the pigment is withdrawn from the percipient elements and the retina is sensitive to slight stimulation and is dazzled by ordinary light; the question then arises whether we may possibly have in congenital total colour-blindness some factor leading to an inherent irritability of the retinal structures in which the blurred images and photophobia are due to excessive reaction to stimuli, the colour-blindness being also due to the fact that stimuli from any wave length produce vibrations affecting too wide an area and thus tending to bring about a sensation of all colours, and so of white or grey, instead of each type of vibration being restricted to one perception; or could the error be explained by a defect in the mechanism by means of which the pigment of the retinal epithelium advances to the protection of the percipient elements under the stimulus of light? An argument against this is perhaps given by the case of albinism in which pigment is or may be totally absent, and yet we find normal colour vision. Another factor which is evidently modified in dark adaptation is the visual purple which tends to accumulate in this state, and which is bleached under the action of light, and it seems reasonable to ask whether a source of defect may be either in the mechanism of the secretion of visual purple or in its chemical properties, but we have no facts to support such a proposition and cannot see how such a defect should so fundamentally affect the vision for colours.

When we come to consider other less complete defects in colour vision we shall find an undoubted short series of unilateral cases which do predispose one to the view that defects of colour vision can arise from ocular sources; the alternative in such cases is a lesion affecting the optic nerve fibres in front of the chiasma, preventing the passage of impulses concerned with the discrimination of colour, but not affecting the transmission of impulses concerned in a clear image for form, and it is very difficult to conceive what must be the nature of such a defect.

[1] Some recent work suggests that this effect ceases to become evident after a prolonged period in the dark. Photometric observations are apt to be misleading if carried out without exact means of measurement and control over the experimental conditions, and it is not possible to make more definite statements. The subject was investigated by von Kries, *Zeitschrift f. Psychol. u. Physiol. d. Sinnes-organe*, Bd. xv, S. 327–51, 1897.

Let us consider now what information exists concerning anatomical changes in the eye of the totally colour-blind. There have been, so far as I know, only two microscopic examinations of a monochromatic eye—one by Pergens[1] and one by Larsen[2]; and it is a great misfortune that in neither case was an examination of the brain also made. In Pergen's case the achromatopsy was acquired and followed a recovery from typhus fever in a woman aged 23; before her illness the patient had, so far as she knew, always had good colour vision, though she had never been tested; after her illness her sister noticed that she wore ill-assorted colours and the patient first realised that she could no longer recognise colours; it was on this account that she consulted the author who found that she had no nystagmus, fundi were normal, R.V. $= \frac{6}{5}$, L.V. $= \frac{6}{4}$, fields for white were normal but no colours were recognised; a variety of tests were made, the visible spectrum was not shorter than normal and the maximum brightness was in the yellow or yellow-green region; there was no trace of hysteria or other nervous affection, her memory had not suffered, her speech was fluent and hearing good. The achromatopsy remained unchanged until the death of the patient from phthisis five years later, the author had in the interval examined her several times with the same result; after her death the eye with a stump of the optic nerve were removed and examined microscopically, the retina showed no signs of degeneration, there was no indication of disease affecting the cones, and the retina differed in no way from the normal; the stump of the optic nerve contained only normal fibres; the author concludes that there was disease of the colour-perceiving central elements which had become affected through typhus. Thus Pergen's case is a corroboration of the clinically observed fact that total colour-blindness with good vision for form can follow from a disease whose disturbing processes are carried on outside the eye, but it further tells us that in such cases the retinal structures and optic nerve may appear to remain entirely normal.

The second case of a microscopic examination by Larsen is, if we correctly assume it to be a case of congenital total colour-blindness, of still greater interest for our purpose; we have only found a brief reference to this case in an account of a meeting of an Ophthalmological Society in Vienna, in 1921, at which Larsen demonstrated the case; the microscopic appearances are verbally described, but no clinical history of the case is given, and no sections of the eye are reproduced. The right eye was imperfectly fixed so that some post-mortem degenerative changes occurred in the layer of rods and cones, nevertheless the author was able to demonstrate that cones as well as rods were present and that the cones were present in their usual numbers. The left eye was more successfully treated and a section through the fovea showed that the cones of this region were short and plump, where they are normally found to be long and slender, and that they had either very short outer members, or these were wholly absent; surrounding the fovea was a region characterised by short thick cones, and in between these a series of shorter rods; a little distance from the centre the retinal structures appeared to be wholly normal, there were long slender rods and shorter robustly built cones, the cones were here noted to have very good conical-shaped outer members and

[1] *Bibl.* No. 278. [2] *Bibl.* No. 399.

the author was able to assert that in the totally colour-blind eye there were no fewer cones than in the normal eye[1]. There was evidently in this case a developmental defect of the fovea and macular regions, but in the absence of a clinical history it is difficult to draw conclusions; we should expect such a defect to give normal vision in a dull light, and defective vision in a bright light; we might reasonably look for an associated nystagmus and perhaps for photophobia; also if the characteristic spectrum of the dark adapted eye follows to any extent from the withdrawal of pigment from the outer limbs of the retinal percipient elements, we might perhaps look for something similar to occur when the elements are shortened or their outer members absent; the results are of great interest so far as they go, and serve to stimulate our anxiety for repeated and more complete reports of this nature. Thus Larsen's microscopic examination indicates a possible explanation of all the associated symptoms of total colour-blindness of congenital origin, but it only explains the achromatism if we can insist upon the integrity of the cones of the foveal region as a necessity for the discrimination of colour: a short distance from the centre the cones are described as normal in number and structure, and yet, so far as our observations go, we do not know that these affected individuals see colours normally in their peripheral regions. We know that the percipient elements are developed from neuroblasts and thus it is not unreasonable to look for further defects in allied structures such as those of the cerebral receptor areas; we know moreover that disturbances of cerebral origin from pathological processes may cause total colour-blindness without any affection of the retinal structures. We are thus led to the suggestion of a possibly associated cerebral defect in our cases of congenital total colour-blindness: the two unilateral cases of Becker and Piper remain to puzzle us on this hypothesis, but these two cases are so entirely anomalous; we do not know definitely that either case was congenital, and it may well be that some disease may have been present preventing the passage of specialised impulses along the optic nerve, through a lesion in front of the optic chiasma, even though there was no evidence of such lesion ophthalmoscopically. The primary needs towards a solution of our problem would appear to be (i) further microscopic examinations, such as Larsen's, accompanied by a complete clinical description of the case; (ii) a corresponding examination of the brain, and (iii) an examination as to whether the total colour-blindness really does extend to the peripheral limits of vision when the stimulus is sufficiently great.

Concerning the etiology of congenital total colour-blindness, no predisposing factor other than that of an inherent defect of unknown nature can be suggested, yet the hereditary factor is evidently a very limited one, for about 20 % of all recorded cases appear to have no similarly affected relatives and show no other hereditary defects; moreover the defect of total colour-blindness, when it is of congenital origin, usually carries with it such severe disabilities, that the affected members are extremely unlikely to remain undetected. Again, a very high proportion of cases are in the offspring of consanguineous parentage; we are convinced that this factor is of great

[1] We have made considerable efforts to get more information about this case, but our letters to the author either failed to reach him or met with no response.

significance, though as we should anticipate the percentage of affected members in the offspring remains practically unchanged as we pass to the group in which no consanguinity is known to be present; a similar relation has been demonstrated for Retinitis Pigmentosa and Congenital Stationary Night Blindness. In our present case we find no fewer than 27·4 °/₀ of cases have consanguineous parents—and this is a very high percentage—yet, of the children of such parents 51·5 ± 4·1 °/₀ are affected, whilst of the children of non-consanguineous parentage 47·0 ± 3·1 °/₀ are affected, a percentage which is not significantly different from the former, having regard to the high probable errors in such small samples.

One is reminded of the group of Congenital Stationary Night Blindness in which both sexes are affected; the defect in this case, as in our present one, manifests itself as a disordered function, and the underlying structural defect which is inevitably present is microscopic in character; the particular disorder differs fundamentally in the two cases, in the one case the peripheral vision is primarily affected, and we find no disability of vision in a good light, in the other case central vision is affected, and indeed the usual daylight vision appears to be more or less in abeyance. It is, of course, tempting to suggest for the one case a developmental defect in the rods and for the other case a developmental defect in the cones; Larsen's case supports this view for total colour-blindness in the anomalous cones found in the foveal region; and in the only post-mortem example of a case of congenital night blindness which has been made[1] there was noted to be a greatly extended area in which cones only were present, and also anomalies in the character of the pigment epithelium; we are not told, however, of definite abnormality with regard to structure or frequency of the rods in the peripheral regions of this retina, and cannot be sure that the abnormality in the pigment epithelium and in the formation of visual purple may not be the source of the functional derangement in this case. Both the conditions we are considering are extremely rare and characteristically associated with no other defect, which latter fact predisposes one to look for an ocular defect as the source of the trouble, for surely any inherent cerebral defect would be liable to present a wider sphere of variation. When, however, we consider the hereditary factor in the two conditions, the pictures are widely contrasted; congenital night blindness gives us large extensive pedigrees, showing the disease passing through many generations, whilst in our present meagre series of family histories of total colour-blindness, illustrated in Plate XXVII, we are in no single case able to insist upon the occurrence of the disease in more than one generation, and in one case only[2] can we point to the condition in more than a single sibship; again, in congenital night blindness of the type under consideration, it is the rule to find one parent affected, whereas in total colour-blindness we see that in every case except one the parents were believed to be normal, and in the exceptional case, described by Nettleship and Holmes Spicer[3], we are told that the father of three affected sons "probably had the same disease," and we are given none of the facts on which this probability was based; in the six or possibly seven cases

[1] *Bibl.* No. 424.

[2] See Fig. 393, showing two families of first cousins affected.

[3] See Fig. 393.

in which an affected member has children[1], they are invariably reported to have normal vision. Of course, the extreme rarity of the disease adds greatly to the significance of multiple cases in the one family when they occur, and eliminates entirely, even for so short a series of pedigrees, the possibility of such associated cases being the result of chance; the evidence of heredity in these cases is firmly established, for the occurrence of a congenital rare condition, such as this, in several siblings can only be explained by their relationship to the common parentage and thus by some defect or extreme variation in the germinal cells of one or both parents.

The question of the relationship of this severe defect of colour vision to the defect usually known as red-green blindness or dichromatism will be considered in the section dealing with that condition, but we may at once state that the cases of dichromatism noted in three or possibly four of our pedigrees (see Figs. 320, 383, 388 and 401) may very well be conceded to be chance occurrences in the light of the knowledge we have of the frequency of dichromatism in the general population. The following bibliography numbers refer to cases of congenital total colour-blindness—34, 36, 55, 71, 79, 96, 104, 125, 128, 143, 144, 159, 164, 185, 198, 212, 214, 216, 217, 218, 230, 241, 249, 252, 253, 254, 256, 260, 261, 262, 274, 276, 279, 281, 284, 291, 297, 305, 323, 335, 344, 349, 352, 353, 359, 374, 385, 399, 421, 422, 423.

B. *Acquired total Colour-Blindness* does not properly concern the *Treasury of Human Inheritance*, and no attempt, therefore, will be made to consider the question or review the literature on the subject in any detail. The only reason for including it here at all is the possible light that the phenomena of acquired colour-blindness may throw upon the congenital and hereditary condition; all therefore that we propose to do here is to give a few examples, chosen from the literature, indicating the undoubted occurrence of colour-blindness as a result of cerebral lesions.

A glance at the diagram on the opposite page will show how the optic nerve of each eye is made up of two sets of fibres corresponding to the right and left halves of the retina respectively; at the chiasma *C*, the fibres from the inner half of each retina are seen to decussate and pass with the fibres from the outer half of the retina of the other eye to the opposite cerebral hemisphere, where they finally come to an end in the optic radiations of the cerebral cortex in the occipital regions. Clearly then if we have a unilateral affection of vision, the media being normal, the lesion must be located either in the retinal structures of the affected eye or in the corresponding optic nerve in front of the chiasma. We know that in Retinitis Pigmentosa, a disease affecting primarily the retinal percipient elements, we find disabilities of vision ushered in by no diminution of colour sense; in optic atrophy, on the other hand, we find disabilities of vision almost invariably associated with a restricted colour sense, which may be entirely abolished long before vision for form is lost; these facts do suggest that the seat of the defect in acquired unilateral conditions lies rather in the mechanism, by means of which the impulse is transmitted to the cerebral cortex, than in the mechanism which receives the stimulus in the eye; I think we may go so far as to make a definite prediction to the effect that, provided the percipient elements

[1] See Figs. 388, 390, 394, 396, 400, omitting Raehlmann's anomalous case.

are normally developed, they are able to discriminate between the stimuli characteristic of different wave lengths, and register the same as long as there is any vision for form at all. One has only to recall the phenomenon of "Saturday Night Paralysis," or post-operative paralyses[1], to realise how extremely readily the transmission of impulses along nerve fibres can be interfered with; indeed it is seen in the optic nerve

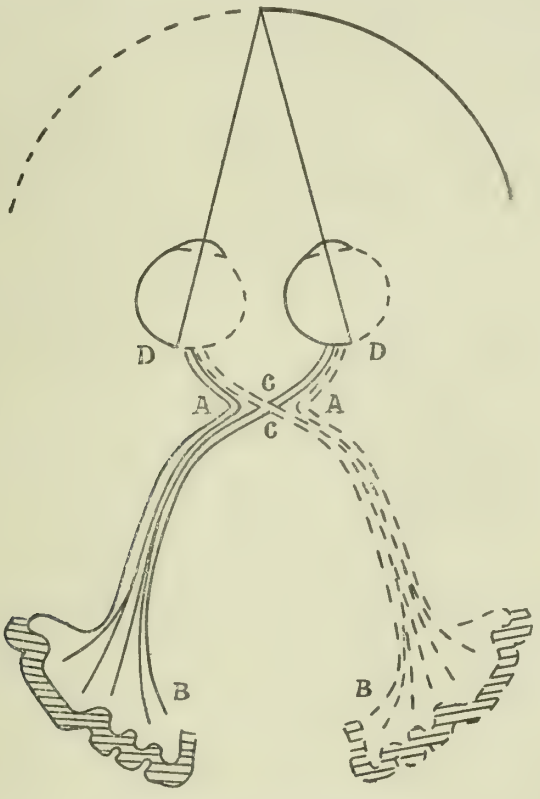

DIAGRAM 11. Diagrammatic representation of the optic conduction pathways, showing how the right halves of each retina are projected to the right cerebral hemisphere, and the left halves of each retina to the left cerebral hemisphere.

itself in the very rapid interference of the functions of this nerve under such conditions as raised intra-ocular tension, or from an oedematous condition of tissues causing pressure at the optic foramen, without having recourse to such gross lesions as tumours along the tract; when the passage of impulses is thus interfered with, one would certainly expect to find defective vision for form associated with the defect in colour vision, at any rate with the more severe defects, and indeed such association is usually found in cases of optic atrophy in which disease degrees of colour-blindness are almost invariably found if sought for; the alternative to this view must entail the existence of specialised fibres in the optic nerve for the transmission of impulses concerned in the perception of colour which is not easy to conceive. There is, moreover,

[1] In each of these examples we have a depressive effect due to alcohol, or to an anaesthetic combined with pressure.

some evidence suggesting the view that the transmission of impulses concerned in the perception of colour is a more delicate operation than the transmission of impulses concerned in the vision for form or perception of light, and it may well be that a depressing influence may show itself by its affection of the former operation at a stage when it is not yet of sufficient potency to affect materially the visual acuity; this view is supported by the fact that in temporary disabilities of vision arising from toxic processes or trauma, the colour vision appears to be the first function interfered with and the last to recover. We do not, however, feel disposed to insist that this delicacy in the transmission of impulses concerned with colour is seated in the nerve itself, it may well be that any interference in the, shall we say, smoothness of transmission may blurr the perception by the cortical receptors; on this hypothesis no case of amblyopia, of which the source lies in the optic nerve, should be unattended by modifications in colour vision, which fact is not definitely established, but many examples might be given to support the suggestion in cases of optic atrophy (see Benedict[1], Leber[2], Hormuth[3], Köllner[4], etc.), or in cases of amblyopia of toxic or infective origin, of which the following history by Holmes[5] is typical. Mrs S., aged 35, had always enjoyed good health; in the sixth month of her first pregnancy she had for two weeks serious symptoms such as albuminuria, generalised oedema, pericardial effusion, orthopnoea and headache; she became totally blind, and immediate induction of labour was imperative; she was then totally blind for three weeks and absolutely colour-blind for three months, white and black being first distinguished; three months later blue tints began to appear, then yellow, brown and red, and finally green; only after five years was her colour sense entirely normal. For other examples see Hays[6], Chisholm[7], etc. In the absence of post-mortem examinations one cannot be sure that such cases do not result from a toxic effect acting upon cerebral perception areas, instead of, or in addition to, their action on the transmitting nerve fibres, though they are usually associated with no other disturbances of the special senses with corresponding perceptive areas in the cerebral cortex, whilst anatomical peculiarities of the optic nerve fibres do expose them to the effect of toxic influences.

Thus, with regard to acquired total colour-blindness of unilateral incidence, we may be assured that the interference is almost certainly operating on the fibres of the optic nerve within the eye or in front of the chiasma. The following account of a case was published by Lindsay Johnson so late as 1922:

"We have reasons for believing that there is a colour centre in the brain. A remarkable case bearing on this point occurred in the author's practice. The patient was suffering from a form of creeping paralysis which gradually affected the limbs of the left side. At the same time, as more and more of the muscles became paralysed, the sense of colour slowly vanished in the corresponding eye, until ultimately the patient could see no colour at all, everything appearing black, grey, and white, like an engraving. This was tested by getting the patient, who was a good water-colour painter, to make a coloured drawing of the spectrum, first with the sound eye and then with the colour-blind one. Notwithstanding the absence of all sense of colour, vision was hardly affected at all, and the colour sense remained perfect in the right eye, while that of the left eye never returned."

[1] *Bibl.* No. 90.
[2] *Bibl.* No. 100.
[3] *Beiträge zur Lehre von den hereditären Sehnervenleiden.* Heidelberg, 1900.
[4] *Bibl.* No. 321.
[5] *Bibl.* No. 156.
[6] *Bibl.* No. 65.
[7] *Bibl.* No. 99.

The puzzling nature of this observation will be at once obvious and it is to be regretted that the author by an oversight omits to mention the examination at his request of this very woman by Abney thirty years earlier. The case is then said to be one of optic atrophy and the paralysis is explained as the result of a slight stroke; we are not told what the visual acuity was with the affected eye, but since the colour sense was completely abolished and the light sense was shown by Abney to be anomalous, we are inclined to be doubtful whether at this time the "vision was hardly affected at all." The importance of this case for our purposes consists in

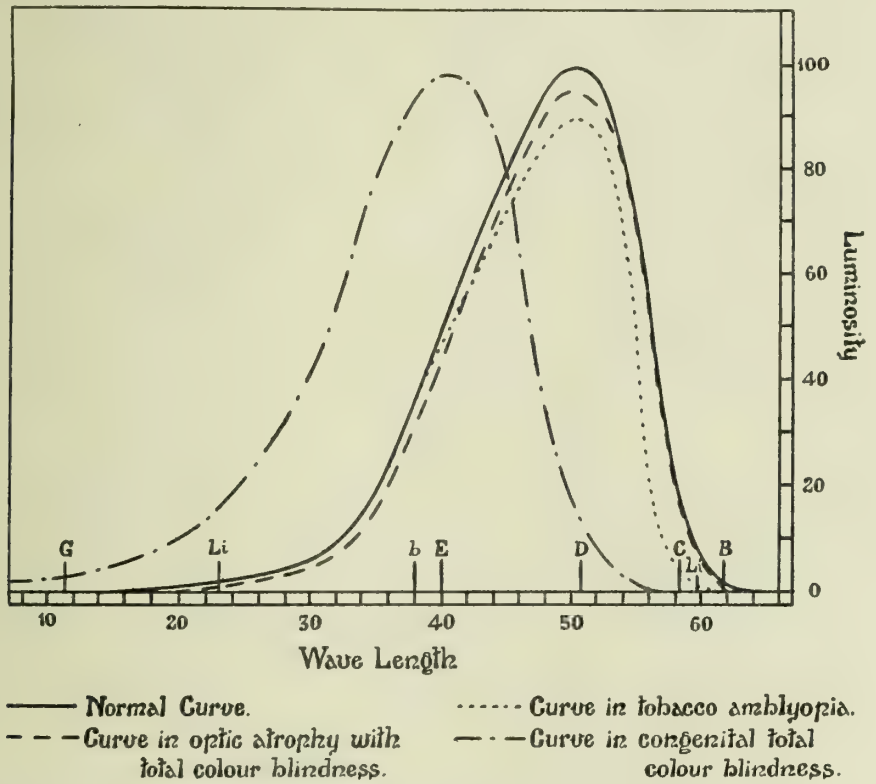

Diagram 12. Luminosity curves, after Abney, *Proc. R. Soc.* Vol. xlix, pp. 494, 505, 1891. (By permission of the Royal Society.)

the fact that here we have a case of acquired unilateral total colour-blindness for which an adequate examination of the luminosity curve has been made and found to be closely resembling that of the normal, showing practically no shortening of the red end of the spectrum and a maximum brightness in the usual region; a similar position is shown, in the same paper, to hold for a case of severe defect in colour vision in a case of toxic amblyopia due to nicotine poisoning. These curves differ markedly from that characteristic of congenital total colour-blindness as is shown in the adjoining diagram and undoubtedly suggest some fundamental difference in the origin of the defect in the congenital and acquired conditions.

Further evidence of the origin of acquired colour-blindness in an interference with the functions of the optic nerves is given by those cases in which the inner half only

of each retina shows the defect, usually described as bi-temporal hemiachromatopsy; such cases cannot be explained by any lesion of the cerebral cortex nor by intra-ocular conditions, but a glance at Diagram 11 will suggest their source in an affection of the optic nerve fibres in the region of the chiasma itself, no other explanation being at all likely on anatomical grounds; the source of the defect is evidently a local one and the phenomena are such as we would expect to occur in cases of enlargement or tumour of the pituitary body, which occupies the posterior angle of the chiasma, causing a pressure atrophy on the inner part of each tract with which it is in contact and leaving the outer fibres from the temporal areas of each retina unaffected. Such cases are seen associated with symptoms characteristic of disease of the pituitary body or in which its enlargement has been demonstrated by X-ray examination and are always associated with some diminution of visual acuity over corresponding areas. For examples of bi-temporal hemiachromatopsy see Bollack[1], Noyes[2], Behr[3], Lenz[4], Kerry[5], Kümmell[6], also Wilbrand and Saenger[7].

Defects of colour vision confined to the outer half of one or both retinae are extremely rare but they should be looked for as the result of lesions, in the outer angle of each tract at the chiasma, such as aneurism of the carotid arteries which occupy this position, gummatous tumours etc.; such cases are however liable to be associated with such severe symptoms as to render it unlikely that a limited hemiachromatopsy would be recognised.

We shall consider now cases of colour-blindness which may have their origin in a defect of the cerebral cortex and thus when associated with good visual acuity suggest or even demonstrate the existence of a special localised centre for colour discrimination in the brain itself, quite separate from the centres for form or for perception of light. The clinical picture produced by any lesion either of the optic nerve fibres posterior to the chiasma or of the cerebral cortex at the terminus of the tract, affecting colour discrimination, is one of what is known as homonymous hemiachromatopsy, that is to say, if the lesion is on the right side, the right half of each retina is insensitive to colour distinctions, the left half of each retina being similarly affected if the lesion be on the left side; if visual acuity be affected over a similar area we cannot be sure that the lesion is not in the optic nerve fibres, but if the visual acuity remains practically unaffected the chances are in favour of a lesion affecting the cerebral receptor apparatus. It is conceivable that total colour-blindness of both eyes may have its origin in the cerebral cortex if there be a bilateral lesion or, perhaps, if there be a general toxic affect acting on both centres, though in the latter case one would certainly look for defects of other cerebral functions; but it is not conceivable that total colour-blindness of one eye only, or of the inner halves of each retina only or of the outer halves of each retina only, should be the result of a cortical lesion.

In 1888 Verry[8] reports that a woman aged 60 complained of inability to read easily, for several weeks she had felt fatigued after reading a few lines; visual acuity

[1] *Bibl.* No. 404. [2] *Bibl.* No. 169. [3] *Bibl.* No. 328. [4] *Bibl.* No. 400.
[5] *Bibl.* No. 294. [6] *Bibl.* No. 348. [7] *Bibl.* No. 371A, S. 38–39.
[8] *Bibl.* No. 202.

with correction of $+2D = \frac{3}{4}$, ophthalmoscopic appearances were normal, no scotomata were present in the visual fields but there was a slight concentric contraction of fields in all directions; tested with colours she was found to have an absolute hemiachromatopsy affecting the left half of each retina; the case was diagnosed as a right homonymous hemiachromatopsy with an associated sensible diminution of visual acuity and perception of light; no other cerebral symptoms were present, there was no aphasia, and no paresis or paralysis of the extremities. The history revealed that the patient had had on three or four occasions what are described as slight attacks consisting of noises in her head followed by vertigo, severe pain at the vertex, sometimes vomiting but never loss of consciousness; death occurred after a severe attack with loss of consciousness and left hemiplegia. At the post-mortem examination a haemorrhagic cyst was found between the floor of the horn of the left lateral ventricle and the basal surface of the occipital lobe; from an examination of the area destroyed the author concludes that the centre for the colour sense will be found in the most inferior part of the occipital lobe, probably in the posterior part of the lingual and fusiform convolutions.

In 1899 Mackay and Dunlop[1] described how a man aged 62, who had great mental capacity and good health, suddenly found himself unable to recognise even vivid colours, though he had always had a good colour sense, and unable to read his letters; on examination it was found that his pupils reacted normally and were equal, media were clear, the fundi were normal, visual acuity was $\frac{6}{12}$ in each, fields were contracted and colour sense was completely suppressed for all colours all over both fields, every colour appearing grey; intellect was clear; a diagnosis was suggested of double homonymous hemianopsia, complete for colour sense, incomplete for form sense, due to symmetrical cortical lesions in or near the calcarine fissures. During the two months following this examination the patient acquired greater facility in reading but there was no restoration of colour sense; he then had a right sided hemiplegia and died. At the post-mortem no lesion explaining the hemiplegia was found, motor areas and tracts were healthy and the optic nerves were healthy, but both occipital lobes were affected by patches of atrophy; thus there was found a severe atrophy of the posterior part of the fusiform convolution on both sides, there was atrophy of the lower part of the optic radiation on both sides and both the grey and white matter of the calcarine fissure remained unaffected. The authors conclude that the total loss of colour sense in association with a bilateral lesion of the fusiform convolution so well defined and symmetrical make it difficult to avoid the conclusion that the grey matter of that convolution is probably concerned in the perception of colours.

We shall refer to one further publication, namely that of Lenz[2], in which is described two cases of defect in colour vision extending to all regions of the spectrum, acquired in association with apopletic attacks; the cases are fully described and after the death of the patients detailed macroscopic and microscopic examination of the occipital region of the brains are made; the paper is well worth a careful study but the cases are complicated by the severity and multiplication of lesions and illustrate the extreme

[1] *Bibl.* No. 258. [2] *Bibl.* No. 400.

difficulty of determining in such cases the particular lesion to which a sensory defect may be attributed. The author considers that his cases do not support the suggestion of a special centre for colour discrimination localised in the fusiform gyrus, on the contrary he is led to the belief that the cause of the disorder must be looked for in an affection of the optic conduction pathway. Of special interest in the second case described is the fact that the maximum brightness in the spectrum was by this patient displaced towards the green region, and further he showed an improvement of vision in a dim light.

Thus, all we can really insist upon with regard to the genesis of acquired colour-blindness is that such disorders may occur as a result of some interference with the passage of impulses in the optic nerve fibres, and there are indications that the interference may be of such a nature as to affect colour vision appreciably whilst leaving form sense intact. It is of course inconceivable that an affection of the cerebral cortex where the fibres terminate should not produce a similar train of symptoms, but it has not been established that there is a centre for colour discrimination separate from that for general visual acuity, nor has the investigation of cases of acquired colour-blindness yet added in any way to the solution of such problems as concern the mechanism of colour vision, though perhaps when we consider acquired colour-blindness in relation to partial colour-blindness affecting only the discrimination of particular wave lengths, to be described in the next section, we may find the acquired anomalies more instructive.

CONGENITAL COLOUR-BLINDNESS

The title of this section was first applied to that defect of colour vision which most commonly occurs, and which shows itself primarily in a difficulty in the identification of red and green, by Brewster at a time when the condition was fully recognised but its varieties had not yet been classified; it has always been felt that the name was unsatisfactory, that it was applying a general description to a particular variety of the anomaly, that it suggests an absolute deficiency whereas the condition described is rather of the nature of a modification of the normal reaction, that it does not lend itself to a ready reference to the affected individuals as apart from the defect and so on; but the difficulties were not found easy to overcome and the name has retained a hold and is the one in popular use up to the present time. Other suggested designations have been idiopts, by Whewell, which was too like idiots to receive favour; Daltonism, introduced by Pierre Prevost of Geneva after the great chemist who first scientifically described the condition of which he was himself an example; this name is still in general use in France but it was distasteful to the people of this country to so vividly perpetuate the association of a defect with the name of a distinguished scientist. Again, the condition has been described as chromatopseudopsy, chromamaurosis, dyschromatopsy, chromatodysopia, chromatometablepsia, anerythropsia, and acritochromasy. Finally Sir John Herschel suggested the term dichromic vision, from his recognition of the dichromatic nature of the vision in such cases, and the terms dichromatic vision and red-green blindness or red-blindness and green-blindness, with their corresponding modern synonyms protanopia and deuteranopia, are now in use in the scientific literature of all countries. Now, though Herschel undoubtedly introduced the term dichromic vision as a result of his examination of Dalton's case, he did not first point out the dichromic nature of the vision of the colour-blind, as is so frequently stated; for Wardrop[1], writing of a case in 1818, states:

"he has a distinct perception of colours purely yellow or blue such as gamboge or Prussian blue. These colours he never mistakes either when seen separately or when lying amongst other colours, and all other colours seem to him only modifications of these. The colours which appear in the solar spectrum for example are to him only two, viz. blue and yellow. He experiences great difficulty in distinguishing the different kinds of green, most of those modifications of colour called green appearing to him either yellow or blue in proportion as one or other of these colours predominates."

Herschel's letter to Dalton[2] on this point is however of such great interest that we are tempted to reproduce it in full:

Slough, *May* 20, 1833.

My dear Sir,

Nothing but the pressure of a work which I have been preparing for immediate publication, and which I have at length got off my hands no longer than this morning, would have prevented so long my replying to your most obliging letter and thanking you for the valuable information contained in your replies to my optical queries. They agree on the whole with the views I had taken of this singular affection of vision and seem to throw much light on the matter.

[1] *Bibl.* No. 48.

[2] Now in the possession of Professor Karl Pearson. This famous letter has already been partially reproduced in Henry's *Life of Dalton.*

It is clear to me that you and all others so affected perceive *as light* every ray which others do. The retina *is excited* by every ray which reaches it, nor, so far as I can see, is there the slightest ground for believing that any ray is prevented from reaching it by the media of the eye. This, I know, is contrary to your opinion, but I speak advisedly and after careful consideration. Yourself and all others whose vision is of this class (Whewell calls them *idiopts*, I don't like the word, it is too like idiots) call them however what we may, it is evident they *see* by rays as strictly homogeneous as prismatic or absorptive analysis can make them, whether we should call those rays red, blue, yellow, or any other names. This is one important step gained, and this your replies to my queries fully prove.

The question then is reduced to one of pure sensation. It seems to me that we have three primary sensations where you have only two. We refer, or can only refer in imagination, all colours to three, red, yellow, blue. All other colours we think we perceive to be mixtures of these and can produce them by actual mixtures of powders of these hues, whereas we cannot produce those hues by any mixture of others. Thus green is yellow + blue, orange is yellow + red, purple is blue + red, brown is black + red or black + orange or black + yellow as the case may be, it is essentially sombre and depends for its effect *as brown* entirely on the proximity and contrast of bright hues. Now to eyes of your kind it seems to me that all your tints are referable to two, which I shall call A and B, the equilibrium of A and B producing *your* white, their negation your black and their mixture in various proportions your compound tints. With regard to what sort of sensations A and B are, of course we can no more tell than you can tell what our α, β and γ (red, yellow and blue) are.

Only this appears to me demonstrated by all the cross examination I have ever been able to give any persons so affected with what I think after all may be termed "Dichromic Vision"—as well as by your answers to my queries—viz.: that the same rays which excite in us the sensation of (blue) excite in you the sensation B—and that rays which excite in us the two distinct sensations α and β, excite in you only the one sensation A. I will not be positive that it is always so strictly definite. I think on the contrary that there are occasional though rare cases of imperfect dichromatism, where an obscure perception of *some difference* between α and β exists, without amounting distinctly to a conviction that it is anything more than that the one is rather a harsher sort of the other.

I should like much to know whether you have ever attempted to reduce all sensations of colour to a mixture of certain primary sensations, as Mayer has done into red, yellow and blue—and with what success, or whether you have time and inclination to make the attempt. I speak with reference to no theory of light or of the constitution of the spectrum which does not seem to me to touch the subject any more than questions about *bitter*, *sweet* or *salt* can be resolved by talking of the chemical analysis of the things tasted.

[1]Allow me now a few remarks on your letter itself, and if I am prolix, pardon me, since the privilege of your correspondence is too high not to be largely used, and I will venture to hope that I may at your leisure be again indulged should I not overshoot my mark and tire your patience instead of engaging your attention.

In any explanation of the difficult permeability of gases to *certain sounds*, I by no means take for granted a quiescent state of the particles. It is sufficient that they exist intermixed and can act as obstacles to each other. I can imagine a thousand ways in which this may happen without mutual non-elasticity. For instance, a particle A of a gas A when driven towards two particles a and b, one of them (a) of the gas A and the other (b) of the gas B, may act on *both* by elasticity as gas but on (b) also by a chemical affinity or elective attraction to which a is indifferent. Thus it may tend to generate different velocities in a and b, and thus to propagate a double sound, each pulse of which running on with a different velocity will have to struggle on alone, continually subdividing and enfeebling itself.

Your account of the cannon shots which gave a lengthened sound strikes me as very curious and important as an acoustical fact. If I mistake not it contains the germ of an explanation of that most puzzling objection to the undulatory theory of light which arises from the necessity of admitting a slight difference of velocity between the red and violet rays in their passage through dense media. For, as the shot when it issued from the gun was instantaneous but became prolonged to 2^s in traversing 30 miles of air, it is evident that the whole wave could not have travelled with equal speed (unless indeed we grant numerous echos from objects surrounding the gun within 2 or 3000 feet). Now if this be possible in air or mixed gases, it may be so in the ether, which, among the particles of dense media may be entangled, or mixed with other elastic matter such as electricity &c.

When I first explained to myself the phenomena of thunder by the successive transmission of sound, I had no knowledge of any explanation but that of echos from clouds. I have since found it in Print and I believe (as I have not the books by me) it originated with either Playfair or Robison, in some article in the Encycl. Brit. prior, I imagine, to 1808. It seems one of those things which occurs naturally to a thinking mind.

The approaching limit of my paper warns me to conclude. I would gladly look forward to meeting at

[1] The remainder of this letter is not concerned with colour vision, but we feel sure the reader will agree that no apology is needed for reproducing the whole.

Cambridge in June one whom I have so many years been in the habit of looking up to with respect and veneration, but have never yet been fortunate enough to meet—or but for a moment.

Believe me, dear Sir,
Yours very faithfully,
J. F. W. Herschel[1].

Thus, whilst giving Herschel full credit for this exceedingly interesting communication, we must not forget Wardrop's contribution with its evidence of the recognition of the dichromic nature of vision in colour-blindness and its comments on the variation in the anomaly,—"These defects exist in some people to a much greater degree than in others." The historical aspect of colour-blindness has already been briefly considered in a former section and nothing further can here be added.

Frequency and Geographical Distribution of Colour-Blindness. There is no doubt of the fact that the anomaly of colour-blindness has been found to be prevalent in all countries of the world and amongst all races, primitive or highly civilised, wherever it has been sought; further, we can find no evidence to suggest that the condition occurs more frequently in the less civilised races as we might expect on the hypothesis that the defect is a primitive characteristic atavistic in origin, but this statement is merely to be taken as negative in character and full recognition should be given to the difficulty of the determination of colour vision on a large scale amongst primitive peoples and the frequent uncertainty with regard to blood relationships between the individuals of such a population.

It has been stated that the condition is specially prevalent amongst Jews, amongst Quakers, amongst deaf-mutes, and so on, and various suggestions have been made to account for these observations, but the methods of testing and conditions of testing have been very varied and we know that the defect itself is so varied in character and so elusive in some undoubted cases that we can insist upon nothing more definite with regard to its frequency than the very widespread distribution of the anomaly wherever it is looked for. Grant Allen[2] gives an interesting summary of the knowledge available concerning the occurrence of colour-blindness amongst primitive races, and Joy Jeffries[3] gives statistics concerning the frequency of the anomaly in different European countries and different classes of the community as determined by a long series of observers: in considering these statistics it must be remembered that most of the observers relied mainly upon tests with coloured wools and we now know that this test, if used alone and not confirmed by other methods of testing, may be misleading. The following table presented by one of the witnesses giving evidence before a Committee of the Royal Society who were investigating colour vision in 1892[4] illustrates well the caution needed in accepting the earlier estimates of the frequency of colour-blindness: the data refers to candidates for employment on the Midland Railway—a selected body of men at the outset, for the markedly colour-blind man usually, but not invariably, knows of his defect and tends to avoid occupations in which it will hamper his progress; on this account alone one would expect a much lower percentage of affected men than would occur in a random sample of the population, but a further point of interest in this table is in the marked increase in the percentage of rejected men in the half-year

[1] See also Herschel's article on 'Light' in *Encyclopaedia Metropolitana*, pp. 434–5. London, 1854.
[2] *Bibl.* No. 127. [3] *Bibl.* No. 132. [4] *Bibl.* No. 224, p. 314.

ending in December as compared with the percentage for the half-year ending in June of the same year for the whole series. It is difficult to know how to account for this; may it be due to lack of uniformity in the conditions of testing at different periods of the year? or may it be that sensitivity to colour differs with the time of year, with the amount of daylight and sunshine, and that border line cases which may

Half-year ending	No. examined	No. affected	Percentage
June 1884	722	20	2·77
December 1884	1019	39	3·82
June 1885	551	17	3·08
December 1885	922	37	4·01
June 1886	557	8	1·43
December 1886	521	12	2·30
June 1887	642	10	1·55
December 1887	520	12	2·30
June 1888	625	2	0·32
December 1888	726	13	1·79
June 1889	637	6	0·94
December 1889	1035	19	1·83
Average per annum	1413	32·5	2·18

just pass the test when sensitivity is at a maximum may be detected under less favourable conditions? There is insufficient data here upon which to base any conclusion, but the possibility of a seasonal variation in acuteness of colour sensitivity is certainly suggested by the knowledge we have of such phenomena as are concerned with after images, fatigue or the effect of former experience in modifying judgment of colour.

The subject of the frequency and detection of colour-blindness has attracted an unwonted amount of attention owing to the fact that the outstanding feature of such cases as we are considering consists in an inability to identify red and green or a liability to confuse these colours, and thus affected individuals constitute a menace to the community if employed by railway companies or marine services whilst unable readily or under difficult circumstances to distinguish between coloured signals and harbour lights of general use. There appears to be a good deal of difference of opinion amongst the colour-blind themselves as to whether they may or may not safely act as railway guards, navigators, etc.; some say they would have no fear and would never confuse red and green signal lights because they differ so markedly in luminosity, whilst others say that they would never dare to act in such a capacity. In the light of the knowledge we now have of the prevalence of the anomaly it seems probable that the menace has been overestimated, for it is only since a comparatively recent date that such tests have been instituted; yet, as Nettleship shows in his analysis of cases of accident due to defects of sight, published in 1913, there are relatively very few cases in which colour-blindness has been proved to be the cause or has even been suggested as the cause of railway or shipping accidents; nevertheless it is clearly desirable that any man with a deficiency in his colour vision should seek employment elsewhere than on the railways or at sea.

We have purposely abstained from giving any definite figure for the frequency of colour-blindness, for until we can be sure what is the inherent relationship between anomalous trichromatism and colour-blindness and in face of the difficulty in deciding where weak colour sensitivity passes over the boundary and may be classed as colour-blindness we can have no assurance on the matter. We shall however quote the percentages of affected members of several population groups determined by an investigation of the Ophthalmological Society in 1881: the tests were made by skilled observers throughout who say:

"Colour-blindness is here taken as implying a defective recognition of the difference between colours. No account is taken of incapacity to distinguish between different shades of colours or even of an inability to distinguish between such colours as blue and violet or blue and green, when these are the sole defects. It is perfectly and clearly distinguished from a defective naming of colours and from deficient acuteness of vision."

Their figures for affected males refer only to pronounced cases of deficiency but for affected females in almost every case refer to cases of slight character. Pehaps the most striking feature of the Table here given is the very high percentage of pronounced

	Males		Females	
	No. examined	Percentage affected	No. examined	Percentage affected
General Population	14,846	3·5	489	0·4
Jews	949	4·9	730	3·1
Quakers	491	5·9	216	5·5
Deaf and Dumb ...	145	13·7	122	2·4

cases of colour-blindness amongst male deaf mutes[1] and the equally high percentage of slight cases (relatively to the value for the general population) amongst females of the special groups.

Description of dichromatic Vision. We have already in the general introduction to this section given some account of the nature of the defect of red-green blindness as described by Dalton who was himself so notable an example: all we propose now to add to that is a summary of the conclusions arrived at by Pole[2], another distinguished example of the condition, who after a very detailed and full investigation of his own and other cases, assisted by suggestions from Herschel and Maxwell and accompanied by a most valuable survey of the knowledge on the subject at that date, concludes as follows:

"The solar spectrum shows, to a dichromic eye, only two hues—a warm and a cold one—separated from each other at a rather uncertain colourless point, called the Neutral Point, lying in the normal blue-green, between Fraunhofer's lines *b* and *F*. The warm hue occupies the whole of the less refrangible part to the left of the dividing place; the cold hue occupies the whole of the more refrangible part to the right hand. These two colours will be complementary with respect to the patient's white. The two colours are modified throughout the length of the spectrum by variations in their saturation, or their luminosity, or both....My neutral point, or division between the colours, lies at a somewhat uncertain wave length not far from 500, and appears a dull colourless hue, not white, but a sort of grey. Starting from this and proceeding to the left hand towards *b*, the sensation of the yellow immediately enters, at first very faint

[1] Probably many of these cases are not of congenital origin and are due to diseased retinal conditions following a syphilitic parentage.

[2] *Bibl.* No. 236, pp. 444–45.

and pale, being much diluted with white; but as I go farther the saturation gradually increases until, beyond *E*, the colour becomes a beautiful resplendent, fully-saturated yellow. The place of maximum strength is difficult to determine, but it is probably shortly before reaching the line *D*. Soon after passing *D* the colours begin to fall off, but the change now is of a nature different from that above described in coming from the neutral point. There is here no dilution with white; the saturation remains full and constant, the change being a diminution of *luminosity* only. This diminution goes on gradually, giving an appearance like that of the shading of a round column in an engraving, and it increases in darkness till the visible spectrum ends. But the saturation of the colour is fully maintained the whole way, and some good authorities maintain that it even increases towards the end.

"The disposition of the colour impressions in the more refrangible divisions of the spectrum is precisely similar. Starting from the neutral point, and proceeding towards the right hand, the blue colour enters, at first much diluted with white, but gradually strengthening till it becomes brilliant and fully saturated between *F* and *G*. Beyond this it is gradually darkened, but still preserving its saturation till it disappears....

"The extra spectral hues, which were conceived by Newton to connect the red end of the normal spectrum with the violet end, and are now called 'purples,' are also visible to the dichromic eye; those near the red have the warm colour; those near the violet have the cold colour; the place of separation being a Second Neutral or Colourless Point near the red end, which is to the normal eye a deep crimson or red violet....

"According to many trials with different persons, I see the full length of the spectrum ordinarily visible at both ends, the red end being perfectly distinct, as far as it is visible to any normal-eyed person who has tried it with me. The violet end seems often to vary with normal eyes.

"As to the luminosity in different parts of the spectrum, Dr Huggins made some trials with me in 1879, and we found that my impressions of the gradations, throughout, seemed to agree fairly well with the normal ones, as originally determined by Fraunhofer in 1815....How far the actual intensity of the luminous impression on my eyes may compare with the normal one (which may probably itself vary), I know no means of determining; all I can say is that my two colours appear to me exceedingly vivid and brilliant, and that I find by experience I am more sensitive than many normal-eyed people to slight variations in them.

"It must be further explained that although the dichromic patient, as his name implies, sees only two varieties of *hue*, yet the *colour-impressions* he derives from them are very numerous and diversified in character, and this is the reason why his defect so often escapes notice. He hears of the variety in colour presented by nature, and he knows that nature also offers great variety to him; but he does not know, till he is taught, that the variety is of a different kind in the two cases."

Pole said it was absurd to talk of red-blindness or green-blindness, since in all cases of dichromatic vision there was a difficulty in the recognition of both colours; nevertheless red-green blindness is by no means an invariable deficiency but is characterised by variations of which two clearly defined types may be differentiated, in one of which weakness of reaction to stimulus by long waved rays predominates and gives the typical red-blindness or protanopia, as it is now more generally termed, and in the other of which there is a relatively greater weakness in response to the shorter waved rays characteristic of green-blindness or deuteranopia. The consideration of the differences and variation of these two types is discussed and summarised by Greenwood[1], who gives references to the original investigations of von Kries on the subject. We must remember however that though it is frequently possible to group cases of colour-blindness under these two headings the defect is almost certainly graduated in character, ranging from cases in which there is very gross defect, such as that described by Pole, to cases in which there is merely a weakness of colour sensitivity which may well pass as colour-blindness if the tests are conducted under conditions in which the stimulus is not sufficiently exciting, and which on the other hand undoubtedly merges insensibly into what would pass as normal colour vision. Moreover, not only do we find great variability in the type of colour-blindness classed under the general heading of red-green blindness, but there is a marked instability in the deficiency to be noted in many

[1] *Bibl.* No. 341, pp. 141–52.

individuals: thus the medical student IV. 7 of Fig. 583 assured me that his colour vision varied greatly from day to day; when his general health was at a high level he was convinced that he saw colours more readily, and he tells of the to him memorable occasion when he was feeling particularly vigorous and on looking through his microscope at a slide stained with eosine and haematoxylin was astonished at the display of colours before him: he had never noticed anything so striking in microscopic work before though he had frequently examined slides similarly stained. Again III. 12 of Fig. 578, a by no means severe case, had noticed how much her colour perception varied from day to day; on some days she was sure she could pass tests which on other days she could not attempt. Schuster[1], in testing normal individuals with Lord Rayleigh's colour box, notes that repeated observations on the same day agree much more closely than observations on the same individual at different times. The whole question of the variability of colour vision is an inherent source of difficulty in the problem of its description and elucidation; too often we concern ourselves with a consideration of the discrimination of hue only, but there is no doubt that the three fundamental characters of sensitivity to hue, saturation and luminosity with the variability of each are all involved in the general problem.

Now the point arises as to whether the mental picture stimulated in the normal by the presentation of yellow and blue really corresponds to the two fundamental colours seen by the dichromate; there has been much controversy centred around this point due largely to the opposition to this view on the part of Edridge-Green. Edridge-Green's labours in the field of colour vision have certainly provided great stimulus to investigation, they have compelled other writers to review their own conclusions, and have brought about reforms in methods of testing of which nobody doubts the value; but, though we may be grateful to him for original suggestions, we frequently find ourselves unable to follow his theoretical views. He appears to assume that in the evolution of vision, approximately, the present length of the spectrum was visible as a streak of light of graduated intensity, before any differentiation of colour was recognised: he then reasons that the first two wave lengths to be further differentiated, as colours, would be the two most physically different characters situated at the extreme ends of the spectrum, in what we now know as the red and violet regions; these specific reactions do not, however, remain confined to their present range, but as evolution progresses their range is extended until they meet in the centre of the spectrum. From these premises he deduces that the power to react specifically to stimuli characteristic of these two regions, is what is retained by the dichromic eye whose deficiency is, on this hypothesis, to be attributed to atavism. Edridge-Green says: "there is a great deal of evidence to show that this is how the colour sense was first developed," and he finds support for this view in his examination of the colour-blind. We find difficulty in accepting these propositions, for the following reasons:

(i) The frequent shortening of the visible spectrum at one or both ends, and the tendency to extend the visibility into the infra-red and ultra-violet regions in other

[1] *Bibl.* No. 219.

cases, suggests that our present normal limits are unstable quantities of no great evolutionary antiquity, at their present values.

(ii) Why should the extreme ends of the spectrum, where stimulative action on the retina, as measured by luminosity, is at a minimum, be expected to be the first regions to be differentiated as colour? Should not the wave length of the highest stimulative power, in the yellow region, rather be considered as possibly the first character to be sensed as such? Perhaps, if we knew more about the inherent physical relationship between complementary colours, we could find an explanation of the perception of blue in association with yellow under such a hypothesis.

(iii) The colour-blind themselves, in the experience of most observers, appear generally to recognise a good yellow and a good blue with confidence and without hesitation; they rarely call these colours by other names, but, on the other hand, they may also, with less assurance, call other colours yellow and blue; we are not concerned at this point of our argument with the question as to whether the mental conception of either of these colours is the same to the colour-blind as it is to the normal individual, but we would suggest that there is a definite stability in the interpretation by them of the stimulus which we recognise as yellow or blue, and which the colour-blind have learnt to call by the same name. The position is wholly otherwise when reds or greens are presented to them; they will frequently say, when asked to name either, "It might be anything," or they will say, "It is very dark, so I suppose it is red." It is not easy to believe that the man who cannot see a scarlet hunting coat on a green field—or who, like Dalton, can reconcile his Quaker principles with the wearing of a scarlet doctor's gown, because it is to him a dull colour like the leaves of the trees—has not some specific inadequacy in his response to the stimulus of those colours, when he will, at the same time, recognise and name yellow and blue without a moment's hesitation.

(iv) An inherent instability in the reaction to the stimulus from red and green is further suggested by the fact that when we pass from the highly specialised foveal vision to extra-foveal vision an increased stimulus is required for the perception and recognition of red and green in retinal areas, which are still able to recognise yellow and blue without any reinforcement of the stimulus; again, in toxic states in which colour vision is temporarily affected, the red and green sensations are usually first lost and the last to return.

Wilson[1] reports the case of a medical man who was thrown from his horse and received injuries which necessitated a long rest in bed, on account of symptoms of severe cerebral injury: he ultimately recovered and was able to resume his professional activities, but for the rest of his life his perception of colours, which had been formerly normal and acute, was both weakened and perverted; red and green in all their shades were now indistinguishable from each other, but bright blue and yellow he never mistook; the patient was greatly shocked on visiting his garden after his recovery to find that a favourite damask rose had become in all its parts, petals, leaves and stem, of one uniform dull colour.

[1] *Bibl.* No. 76, p. 39.

Another interesting case, reported by Tyndall, is quoted by Joy Jeffries[1]: A sea captain was accustomed when time lay heavy on his hands to occupy it by working at embroidery; one day whilst so engaged his power of distinguishing colours suddenly vanished and from that time to the date of the report, twelve years later, he remained colour-blind; he had a keen perception for blue and never made a mistake regarding it, but when two bundles of worsted, one a light green and the other a vivid scarlet, were placed before him he pronounced them to be both of the same colour, and he could discern no difference between a green and a red glass placed side by side between him and the window. On intense stimulation one day he recognised red and was delighted to renew his acquaintance with the colour. Such cases undoubtedly suggest that the perception of stimuli which are usually interpreted as red and green is relatively unstable as compared with the perception of yellow and blue.

We suspect that much light might be thrown upon the question of the relative stability of colour sensations, and perhaps on the mechanism of colour vision, by a study of the phenomena of chrupsia, or coloured vision, but an adequate consideration of this problem is outside the scope of the present work: we can merely try to encourage interest and further experiment and classification by a few remarks, and suggest the following queries as a possible basis of enquiry. Is erythropsia, or red vision, induced by intense irritation of the colour-perceiving apparatus? Is xanthopsia, or yellow vision, induced by a depressive action on the colour-perceiving apparatus?

Xanthopsia is of relatively frequent occurrence in association with jaundice, and with the action of santonin, and a good deal of experimental work has been carried out by the use of this drug, but there is much disagreement in the description of the phenomena; there appears, however, to be a measure of agreement in the observation that the condition of santonin reaction is characterised by (*a*) a stage of violet vision followed by (*b*) a stage of yellow vision, and it is generally suggested that the violet vision represents a stage of irritation and the yellow vision a stage of reaction, or even paralysis, of the hitherto stimulated function; some say that there is violet-blindness in stage (*b*), others experience no even relative violet-blindness: the yellow of the yellow vision is described as a greenish yellow, and is probably complementary to the violet of the preceding violet vision. Some observers insist that the retinal periphery only is affected by santonin, and that the macula region has completely normal colour perception throughout the experiment, others modify or deny this rather fundamental point. Nagel, a deuteranope, experimented on himself; Raehlmann experimented on a protanope, but they do not appear to agree in their conclusions; thus, Raehlmann says that dichromatic vision becomes monochromatic under the influence of santonin, that the dichromate sees in the spectrum one colour only, namely blue, which is maintained throughout the short-waved half of the spectrum, whilst the long-waved half is colourless or greyish white; Nagel maintains that his vision does not become monochromatic; he says that very definite changes occurred in the appearance of the warm colours from yellow-green to the extreme red end of the spectrum; as the poison began to act the appearance was at first pale and

[1] *Bibl.* No. 132, p. 51.

unsaturated, then gradually it became pure white or slightly grey, nevertheless his vision was not monochromatic because this only held for spectral colours, and that pigments, coloured glass, coloured liquids and paper, appeared to him throughout in their usual colours; further, he carried out tests with wools precisely as he would have done in an unpoisoned state. All seem to agree that the yellow vision of santonin differs fundamentally from vision through a yellow glass, as evidenced by observations on light sense and adaptation time. Knies experimented on himself and notes, amongst other features, a lengthening of both ends of the spectrum, followed by a shortening. Nagel emphasises the different susceptibilities of different people: he had very unpleasant general symptoms, with hallucinations of smell, which reached an almost intolerable intensity, and the action of santonin on vision commenced after 5–10 minutes, whilst for others the same dose produced no general symptoms, and the action on colour sense was first noticed an hour after taking the drug.

We feel convinced that further experiments and the classification of cases of red, yellow, blue, green and violet vision would reveal some correlation between the source and nature of the irritant, and the reaction to it, which might throw much light upon the relative stability or instability of the various colour sensations, and illuminate the question of the evolution of colour vision. The works of the following authors may be consulted with regard to the condition of chrupsia: Hilbert[1], Nagel[2], Rose[3], Raehlmann[4], Szili[5], Siven[6], Knies[7], Szokalski[8], Purtscher[9], Heermann[10], Mackenzie[11], Somya[12], Hirschberg[13], Dobrowolsky[14], Phipson[15], Smith[16], Farquharson[17], Berger[18], Steinheim[19], Yamaguchi[20], Kesteven[21], Vaughan[22].

(v) Returning, after this digression, to a consideration of facts which appear to tell in favour of regarding blue and yellow as approaching to the fundamental colours of dichromic vision, we shall now consider the evidence supplied by the rare but well-authenticated cases of one-eyed colour-blindness, in which the other eye has normal colour vision. Porterfield, in 1759, writes[23]: "Experiments are not wanting whereby it appears that the same object is seen of different colours according as it is viewed with the right or left eye. When these colours are very different it is easy to perceive the difference by shutting the eyes alternately." He adds that Monsieur de la Hire has given us a method whereby the least difference may be easily known. It is not until 1871, however, that we find an account published of a case of unilateral colour-blindness, with an attempt to describe the difference in the sensation of the two eyes, and this case by Woinow[24] is of doubtful value as it was atypical in some respects, and we cannot be sure that it was congenital in origin; the patient appears to have had a hysterical fear of red which affected her painfully when seen with either eye,

[1] *Bibl.* Nos. 181, 188, 250, 319.
[2] *Bibl.* Nos. 277, 325.
[3] *Bibl.* Nos. 87, 88, 91.
[4] *Bibl.* No. 260.
[5] *Bibl.* No. 193.
[6] *Bibl.* No. 327.
[7] *Bibl.* No. 267.
[8] *Bibl.* No. 66.
[9] *Bibl.* No. 192.
[10] *Bibl.* No. 60.
[11] *Bibl.* No. 74.
[12] *Bibl.* No. 231.
[13] *Bibl.* No. 189.
[14] *Bibl.* No. 196.
[15] *Bibl.* No. 84.
[16] *Bibl.* No. 220.
[17] *Bibl.* No. 105.
[18] *Bibl.* No. 184.
[19] *Bibl.* No. 183.
[20] *Bibl.* No. 339.
[21] *Bibl.* No. 165.
[22] *Bibl.* No. 315.
[23] *Bibl.* No. 29, Vol. I, p. 128.
[24] *Bibl.* No. 108.

but more particularly when seen with her affected eye; the author diagnoses the case as unilateral green-blindness, but there appears to have been some weakness of the vision for red also, and, so far as it goes, it brings a measure of support to the view that vision for red and green are relatively unstable.

The second case of unilateral colour-blindness, described by von Hippel[1], is of much greater value, as it was typical with regard to this anomaly and was very fully examined by the author, and later by Holmgren[2], to whom von Hippel introduced the case, primarily with a view to discovering what were the fundamental colour sensations of the colour-blind; after a long series of tests and experiments the agreed conclusions of the investigators were that the patient's left eye was normal and his right eye was red-green-blind; for his affected eye the two fundamental tones were pronounced to be yellow and blue, the yellow stretching over that part of the spectrum usually seen as red, orange, yellow and green, and terminating in the blue-green, where there is a narrow neutral belt, and the blue stretching over the remainder of the spectrum; interesting tests with after-images were carried out on this case and were found to be normal with the left eye, but with the affected eye all after-images from red, orange, yellow and green were given as blue, after-images from blue and violet were given as yellow.

Other cases of unilateral colour-blindness or colour anomaly have been described, and whilst no case has been found to conflict with the conclusion of von Hippel, many of the cases are incompletely described or are atypical in some respect, or are pathological in origin, and so are not individually of much value for purposes of the determination of the fundamental colours of the colour-blind, but they do collectively bring much support to the contention that the sensations of red and green are relatively unstable, and that these are the perceptions which most readily depart from the normal. Perhaps the most definite support to von Hippel's conclusions is to be found in the case of unilateral protanopia described by Hayes[3]; the patient was fully tested and on being asked to look through a spectroscope with her colour-blind eye, and arrange coloured papers in a series corresponding to what she saw, she matched the spectrum by (i) three varying shades of grey; (ii) yellow; (iii) greenish yellow; (iv) greenish blue; (v) blue; (vi) violet. This case had a colour-blind maternal grandfather, which supports the probability that the case was of congenital origin, and belonged to the usual type of congenital red-green blindness. Of cases which have a unilateral anomaly of colour vision which appears to affect primarily the perception of red and green, that described by von Kries[4] is perhaps the most interesting. Von Kries describes his case as one of congenital unilateral green weakness, and amongst other tests he gives the patient definite wave lengths through the spectroscope, and notes what he sees with his normal and with his anomalous eye respectively; the results as quoted below suggest a definite weakness in the response to the red stimulus as well as to the green on the part of the affected eye.

[1] *Bibl.* Nos. 141, 155.
[2] *Bibl.* No. 157.
[3] *Bibl.* No. 347.
[4] *Bibl.* No. 386.

Von Kries' case of deuteranomalous Vision.

Wave Length	Normal Eye	Affected Eye
627	Red	Considerably yellower
608	Light red	Yellow with trace of red
591	Reddish mixture	Pure yellow
573	Slightly greenish yellow	Slightly greenish yellow
559	Grass green	Almost pure yellow
535	Green	Yellow with slight shimmer of green
515	Green	Greenish yellow (very different)
505	Green	Weak yellowish green
496	Green	Almost colourless (maximum difference)
488	Blue green	White
480	Greenish blue	Grey blue
464	Blue	Blue
460	Violet	Blue

Other unilateral cases of colour-blindness or anomalous colour vision of varying types have been described by Becker[1] and Piper[2], Holmgren[3], Snell[4], Shufeldt[5] and Hermann[6], by Kolbe[7], Hegner[8], Donders[9], Kirschmann[10], Reichert[11], Niemetschek[12] and Samojloff[13]. Although perhaps none of these cases have a further definite bearing on what are the fundamental colours of the red-green blind, either from lack of a detailed examination, or because of the anomalous or atypical characteristics of the case, nevertheless they constitute an undoubted guarantee of the fact that the two eyes of an individual do not invariably lead to the same impression from the same coloured stimulus, and further that when a distinction between the response of the two eyes to a stimulus is present, it is a specific distinction and has to do with the perception of certain colours only, other colours appearing identical to the two eyes.

Now, though we raise these difficulties, or what appear to the writer to be difficulties, in the acceptance of Edridge-Green's suggestions concerning the evolution of vision and the fundamental colours of the dichromate, we fully recognise the wide experience and long years of study on which his conclusions are based, and need to pay attention to the fact that he himself formerly held other views and was led by his analysis of cases to modify the same. Thus he writes[14]:

If in the evolution of the colour sense the first two colours to be discriminated were red and violet, these two colours should be most representative of the two colour sensations. I am now convinced that this is the case and that the two colours seen correspond to a red and a violet with less colour difference between them and less saturated colours. Two cases which I have examined throw light upon this point. One was colour blind with one eye only and he said that he saw the spectrum with this eye as nearly all grey but with a tinge of red at one end and a tinge of violet at the other. The other case was a woman who had become totally colour-blind as a sequel of ear disease. She was sent to me when she had regained a certain amount of colour sensation. She also saw the spectrum nearly all grey with red at one end and violet at the other. In those congenital cases in which the two sensations are separated by a wide neutral portion the observer emphatically declares that the two colours which he sees are red and violet. In other cases in which there are several differences of colour to be seen in each of the two divisions of the spectrum there is more difficulty. Many dichromics of this kind declare that yellow and blue are the two colours which they see in the bright spectrum. I also stated in my earlier writings that yellow and blue were the two most representative colours because of their superior luminosity and the fact that they occupy central positions in the two colours (*sic!*).

[1] *Bibl.* No. 128. [2] *Bibl.* No. 297. [3] *Bibl.* No. 157. [4] *Bibl.* No. 225. [5] *Bibl.* No. 173.
[6] *Bibl.* No. 164. [7] *Bibl.* No. 166. [8] *Bibl.* No. 369. [9] *Bibl.* No. 177. [10] *Bibl.* No. 227.
[11] *Bibl.* No. 375. [12] *Bibl.* No. 97. [13] *Bibl.* No. 314. [14] *Bibl.* No. 387, pp. 192–3.

Other characteristics of the vision of the colour-blind are as follows: The condition with regard to colour discrimination remains unchanged throughout life, no real improvement in powers of discrimination occurs, though in certain cases it may be possible to train individuals with only relatively slight affection so as to enable them to evade the catch provided for them in some particular test. The vision for form may be entirely normal, and we can find no evidence that any particular anomaly of refraction tends to occur in association with colour-blindness.

Dichromatism is often found to be associated with a very marked appreciation of difference in tone which appears to account for the fact that we are repeatedly told that the colour-blind make very good engravers and indeed in some cases attribute their excellence in this branch of art to the very fact of their colour-blindness; thus there is no lack of sensibility to intensity of stimulus but the defect would rather appear to be due to the lack of a definite factor of a specific nature concerned with the analysis of the stimulus. The effect of artificial light on colour is generally much more marked to the dichromatic than to the normal individual, and the change produced appears to be of a more fundamental character entirely altering the nature of the sensation instead of merely modifying it; Dalton called attention to this fact and tells of how a pink flower was to him "astonishingly changed" by candle-light; Wilson further investigated this point on a number of cases and concludes that the colours whose aspect varies most markedly to the colour-blind, when under the influence of artificial light, are reds as contrasted with greens and pinks as contrasted with blues. Thus artificial light would appear to affect the colour-blind with regard to their most characteristic difficulties and indeed they will frequently volunteer the information that they see more variety in colour under conditions of artificial lighting. To give one example only, the very severe case v. 35 of Fig. 582 said that he was unable to play cards by daylight because he could see no difference between their differently coloured backs but by lamp light he could sort the two packs without difficulty. Such facts as these led to the suggestion that coloured spectacles might be useful as a palliative to colour-blindness, but each case of the defect seemed to require a different lens to suit his peculiarities and the idea of manufacturing spectacles for the colour-blind on a commercial scale has not been found practicable. We thought, however, it would be of interest to do some actual testing of colour-blindness under the influence of different coloured lights, and though our experiments were rather crude they led to results which were of considerable interest.

We tied up the ordinary electric lamp, in a dark room, in little bags made of coloured silks and tested the subject with Edridge-Green's cards: all who were tested read the cards much more easily under the influence of red, orange and yellow lights than in daylight; in some cases the subject read all the cards without hesitation which he had been entirely unable to read in daylight; he was of course still unable to say what colours he saw, but these lights made colours appear to him markedly different which he had judged to be identical in daylight. We were particularly interested to see what effect green light would have upon the colour-blind who were unable to distinguish between red and green in daylight; the effect differed totally from that of

red light, he could usually read none of the cards in green light which he had read with ease in red light and in one case when asked to look at the light first shaded with red and then with green and to say whether they were alike in colour or different, the subject laughed and thought we must be joking, for the colours were as different to him as two colours could be; yet this same student, ten minutes earlier, had sorted red, orange and green beads together as being alike, and called them brown. On showing this student a bottle of liquid which to the normal is bright green when seen against a dark background and pure yellow when held up to the light, he could see no difference between the green and the yellow, and called both yellow. It is difficult to see what are the fundamental differences in the physical conditions of the tests involved which enable a student who is unable to see green letters on a red ground because both colours are to him alike, or to see any difference between a bright green and a clear yellow liquid, or to see any difference between red, orange and green beads, to insist that a red and green shaded lamp are of totally different colours appearing to him to have nothing in common. This is merely one example of the anomalies which are so characteristic a feature and so difficult to explain in the vision of the colour-blind.

One further anomaly we will mention—it is the conspicuous effect of distance on colour discrimination in certain of the colour-blind; an interesting example of this is given by the case of IV. 7 in Fig. 583 whose determination of colour varied very markedly with his distance from the coloured object and he himself believed that there was a critical distance at which he could recognise, say, red. For his case it would seem that greater stimulus due to greater apparent size of the near object was perhaps the determining factor, for he certainly could not distinguish red dots from black ones when being tested for reaction time by means of a dotting machine, even though they were quite close, but he maintained that the red flowers of the gum tree in Australia remained indistinguishable from their leaves until he approached within a certain critical distance at which they "suddenly flashed out before him"; tests devised to bring out this point, as described later in the history of the case, certainly confirm the modification of his judgment of colour with distance. This is not an infrequent anomaly, many cases are described in the literature in which red and green can be discriminated when close at hand but become indistinguishable when moved to a distance at which their form is still clearly defined. Wilson quotes a number of interesting examples[1] and contrasts the position with that of the ordinary myope who is able to see an object as a red blot at a distance which precludes him from giving any opinion on its form. Surely such cases suggest no complete loss of any specific function but rather a sluggishness in response to a specific stimulus, and one is reminded of the dichromic zone of the normal retina in which average stimuli lead to no perception of red and green but enforcement of stimulus to this area is accompanied by full recognition and discrimination between these colours.

Again, one calls for an anatomical examination of a colour-blind excised eye: one such examination only we have reference to, and the report of it by Pergens[2] gives no description of the examination but merely states that nothing abnormal was found.

[1] *Bibl.* No. 76, pp. 49–51. [2] *Bibl.* No. 278.

When we look for other defects or anomalies characteristically associated with colour-blindness we can find no evidence at all that such exist; we certainly expected to find a tendency to deafness occurring as an associated defect, from a knowledge of the high percentage of colour-blindness reported amongst deaf-mutes by the Royal Society's Commission on Colour-Blindness already referred to, but in only two out of our whole series of pedigrees are we told of an associated deafness, and only one colour-blind individual was himself a deaf-mute; in two further pedigrees we read of an associated lack of musical ear. Associated eye defects appear to be extremely rare and of no apparent significance. One pedigree with an associated digital deformity is reported and occasional cases of mental defect or epilepsy are noted, which can be regarded as of no significance in the light of the frequency of such diseases in the general population. Of course our information is incomplete and may be misleading, for colour-blindness does not necessarily take its victim to the doctor or to the ophthalmologist, and information about associated defects is not likely to be asked for by the non-medical observer nor volunteered by the individual who is being tested; nevertheless other eye defects have been too frequently sought for to be overlooked if at all frequent, and we are inclined to the view that colour-blindness is probably not characteristically associated with other hereditary defects and is in this respect markedly contrasted to such conditions as blue sclerotics, aniridia, ectopia lentis, microphthalmos, coloboma iridis, ophthalmoplegia, etc. We might even tentatively suggest that perhaps these sex-limited hereditary diseases, following their typical mode of descent, are as a group found to be characteristically associated with no other defects; such would appear to be the case for congenital stationary night-blindness (with myopia) and haemophilia so so far as can be judged from the *Treasury of Human Inheritance*. Evidence, however, is admittedly incomplete and the whole subject needs to be investigated.

Congenital Colour-Blindness in Women. This to any marked degree is no doubt relatively rare, but we have succeeded in collecting records of 91 cases. It is repeatedly stated on theoretical grounds that in order for colour-blindness to become manifest in women the father must be colour-blind and the mother must also be a carrier, and further that all the sons of a colour-blind woman must be colour-blind: these views have met with so widespread an acceptance that in some published cases a man is said to be probably colour-blind solely on the theoretical grounds that his daughter has a colour-blind daughter. We hoped to be able to firmly establish or to deny these hypotheses, and indeed we are able to deny them in as far as we have a record of a single sibship containing three colour-blind females, the father of whom has been definitely tested and pronounced to have normal colour vision[1], and in several unquestionable cases colour-blind women have been demonstrated to have sons with normal colour vision[2]. Nevertheless the hypotheses referred to do undoubtedly hold over so wide a range of cases that we feel there must be some physical basis tending always to produce these associations, and if we quote figures from our pedigrees which show that 74·6 °/₀ of colour-blind women are known to have colour-blind fathers (omitting cases where there is no knowledge of the parents), 91·1 °/₀ of colour-blind

[1] See Fig. 569.

[2] See Figs. 407, 418, 440, 583.

women are known to have mothers who come from colour-blind stocks, and 84·7 % of the sons of colour-blind women are known to be colour-blind, we must urge the reader to receive them as suggestive only and to bear in mind that the two former values would probably be raised if knowledge were more complete and all parents believed to be normal had been tested.

The Inheritance of Colour-Blindness. A glance at the pedigrees accompanying this section will leave no doubt in the mind of any individual that the condition of congenital colour-blindness is strongly inherited and further that it belongs to that group of inheritable diseases which is mainly manifested in males and transmitted by their unaffected daughters but not by themselves directly to their sons. The condition however is not invariable in any single one of these characters and does not appear to conform at all rigidly to the laws of sex-limited hereditary defect of this type, whether this is due to the fact that the condition is of common occurrence and therefore extreme cases of the defect are often met with and affection in both parental stocks is frequent or whether it is due to more fundamental causes we are unable to say, but we feel that there are, for example, perhaps too many cases in which an affected father has affected sons for them all to be accounted for by a lack of knowledge concerning the mother's stock.

With regard to the pedigrees themselves the material is such as to make the statistician thoroughly unhappy, for we know perfectly well that a large proportion of those individuals entered as normal have not been scientifically tested, and we know also that many of the cases amongst the earlier published records have been tested by means of wools alone which may be entirely misleading; further, a glance at the pedigrees of Anomalous Trichromatism on Plate XLI must fill all of us with doubts as to whether a large number of the members classified as normal would not be found to be anomalous trichromates if tested by means of the necessary apparatus and whether in such a case they should not be regarded as slight cases of colour-blindness rather than as normal individuals.

To set against these rather devastating doubts we cannot read accounts of the majority of the cases of colour-blindness described without becoming satisfied that the affected cases are rightly placed in this group, so that our percentages of affected members of sibships will at any rate, we feel, give minimum values. The great majority of described cases too were well aware of the defect in themselves or their relations from difficulties met with in daily life and mistakes made with regard to colours; in several large pedigrees, notably Usher's case of Fig. 408, every affected member knew himself to be affected before he was tested and no tested case who believed himself to be normal was found to be affected. We ease our doubting minds by such assurances but are fully conscious of the fact that in making definite deductions we lay ourselves open to the criticism of anybody who holds views which differ from those we may deduce from an analysis of the material and we look forward to the day when our knowledge of Anomalous Trichromatism and its occurrence in members of colour-blind stocks will enable us to apply a corrective factor, and if it be found neccessary to include cases of this anomaly amongst those of colour-blindness.

We shall not then attempt at present any but the simplest analysis of the pedigrees, and hold that the values given in the table below as an indication of the intensity of inheritance may be taken to represent approximately the case for gross defects of colour vision; if it be true, as we have some reason to believe, that the grade of defect tends to be inherited and that in general one may expect to find severe cases in one pedigree and slight cases in another pedigree but not two widely divergent grades of defect in the same pedigree, then the inclusion of slight cases of colour-blindness arising from a more subtle method of examination should not seriously alter the factors of the table. In making the table sibships containing affected members only have been considered; all sibships for which information is incomplete, with regard to sex and numbers of normal members as well as affected members, have been rejected and the usual procedure has been carried out with regard to children who were too young to be tested, still-births and children who died young. A large number of normal females occur in the sibships of whom no information is given with regard to their marriage or offspring and we feel assured that there has been a selection with regard to this information and that females with affected sons tend to be noted whereas females with only daughters or with normal sons only, tend to be regarded as outside the picture and to have no note taken of their marriage. Selection of such a nature however, as well as errors due to methods of testing, will affect each column of the table which should therefore be comparable, and distinctions between the columns may be taken as to be of some real significance where the numbers are adequate.

Now several facts become at once apparent. The close resemblance between the percentages given in Columns 2 and 3 and between those in Columns 4 and 5 suggests that there is no fundamental difference in the conditions holding for the corresponding groups; in other words where the mother is *not known* to be of affected stock she probably does carry the defect in the large majority of cases and this fact suggests that in every case of colour-blindness the mother of the affected individual is a prominent causative factor: this conclusion is of interest in the light of the result of the investigation into the transmission of haemophilia by Bulloch and Fildes, who state that "From a very careful consideration of all the facts we do not feel convinced that we are justified in concluding that haemophilia is capable of being propagated through the male[1]." That the affection of the father does modify the transmission of colour-blindness is undoubted; indeed he is almost certainly the ultimate source of the defect in his grandsons or great-grandsons in a large percentage of cases, but here the comparison with haemophilia can no longer be made owing to the fatal nature of the latter disease and the rarity of cases in which the result of a marriage between a haemophilic male and a female of affected stock can be followed.

A second point of interest shown by Columns 2–5 of the table is the marked *reduction* in the percentage of affected males when the father is affected as compared with the value when he is normal, as if the liability of the daughters to the disease incident upon the involvement of both parents is in some way associated with a limiting effect upon the affection of the sons. The percentage of daughters who transmit the

[1] *Treasury of Human Inheritance*, Vol. I, p. 185.

Distribution of affected cases.*

	Both parents affected (2)† (1)	Father affected. Mother's stock affected. (19)† (2)	Father affected. Mother's stock not known to be affected. (30)† (3)	Both parents normal. Mother's stock affected. (198)† (4)	Both parents normal. Mother's stock not known to be affected. (53)† (5)	Father normal. Mother affected. (23)† (6)
Number of affected sons	4	17	32	344	115	50
Number of affected daughters	5	22	22	8	1	1
Number of normal sons	0	18	34	222	53	11
Number of normal daughters	0	38	41	406	94	30
Number of daughters with affected sons ...	—	9	14	41	19	—
Number of daughters with normal sons ...	—	2	1	37	14	—
Percentage of affected sons	[100]	$48{\cdot}6 \pm 5{\cdot}7$	$48{\cdot}5 \pm 4{\cdot}1$	$60{\cdot}8 \pm 1{\cdot}4$	$68{\cdot}5 \pm 2{\cdot}4$	$82{\cdot}0 \pm 3{\cdot}3$
Percentage of affected daughters	[100]	$36{\cdot}7 \pm 4{\cdot}2$	$35{\cdot}0 \pm 4{\cdot}1$	$1{\cdot}9 \pm 0{\cdot}5$	$1{\cdot}1 \pm 0{\cdot}7$	$3{\cdot}2 \pm 2{\cdot}1$
Percentage of daughters with affected sons‡	—	$[81{\cdot}8 \pm 7{\cdot}8]$	$[93{\cdot}3 \pm 4{\cdot}4]$	$52{\cdot}6 \pm 3{\cdot}8$	$57{\cdot}6 \pm 5{\cdot}8$	—
Percentage of males in sibships	—	$36{\cdot}8 \pm 3{\cdot}3$	$51{\cdot}2 \pm 3{\cdot}0$	$57{\cdot}7 \pm 1{\cdot}1$	$63{\cdot}9 \pm 2{\cdot}0$	$66{\cdot}3 \pm 3{\cdot}3$
Average size of family		5·0	4·3	5·0	5·0	4·0

* All values given in this table refer to sibships containing affected members only.

† Number of sibships. No sibships known to be of consanguineous parentage are included; such sibships are too few in number to be of value for comparative purposes.

‡ Percentages probably too high owing to selection in the formation of pedigrees. Only daughters known to have sons are included.

defect is much raised when the father is affected; the values given in the table refer only to sibships containing affected members and are based on very few cases, but the same high value is maintained if we consider the daughters of affected fathers who have no affected sons and the mother of such sibships is probably not a carrier; we have examined 50 such sibships and find 84 daughters with affected sons, 16 daughters whose sons are all normal, or 84°/₀ of the daughters with sons have affected sons. We have already pointed out that these percentages are based on probably selected material and are almost certainly too high, but the same argument applies to the percentages of daughters with affected sons when both parents are normal and there is no reason to suppose that the selection would be greater in one case than in the other; thus it would appear that the difference in the percentages for these two groups is an expression of the fact that the carrier mother is a much less potent element than the affected father with regard to the passing on of the liability to transmit the defect. This point is confirmed by the case of congenital stationary night-blindness (with probably the same selection of material raising each percentage) for which the percentage of daughters with affected sons when both parents are normal and the mother of affected stock is 66·7 whereas the corresponding value for all sibships in which the father is affected is 86·2.

One further point in the table is of significance, it is the increasing percentage of males in the sibships in a series parallel with the increasing percentage of affected males in the sibship: it is true that here again we have a selection of material affecting all the percentages due to the fact that we are dealing with affected sibships only and therefore have almost entirely eliminated sibships containing only females, nevertheless we feel that the rise is too great to be explained by such a selection and is an expression of some basic fact. The very low value of Column 2 is based on very small numbers and is probably of no great significance. The percentage of males in affected sibships for congenital night-blindness and haemophilia is in each case 57·3: this value is subject to the same type of selection as the corresponding values for colour-blindness and is in fairly close agreement with our values for the groups in which both parents are normal and the mother's stock affected.

On the whole I think that this simple survey of the facts deduced from my data is encouraging and certainly brings a measure of support to the pedigrees: I feel that perhaps the doubts which I set out with are to some extent justifiably allayed and am now stimulated to provide additional family histories with a more searching analysis of *all* their members than has been applied to the majority given here, and thus to try and confirm my suggestion that the present series of pedigrees of gross defects in colour vision will not be modified appreciably by the inclusion of slighter cases which may hitherto have escaped notice.

I have made little reference throughout this introduction to Nettleship's work on colour-blindness, but the pedigrees give ample evidence of his interest and of the importance of his contributions to the subject; no fewer than 35 pedigrees of my collection are due to him and many of these are amongst the most interesting of the series; he spared himself no efforts with the means at his disposal to get complete

information and test cases personally wherever it was possible to do so. At the time of his death some of his best pedigrees were still in process of completion and were later prepared for press by Usher.

With regard to Plate XLI, giving pedigrees of Anomalous Trichromatism and Colour-Blindness, I include this short series here to show the nature of the material already available[1] but I am hoping it may become feasible to study at first hand the problem of the inheritance of Anomalous Trichromatism, and propose to make no suggestions concerning this anomaly until I have more knowledge of the nature of the defect and its relationship to normal colour vision and to colour-blindness.

I have to express my great indebtedness to Mr C. H. Usher who has helped the writer with criticism and suggestion throughout this work, and who moreover, at the outset of the investigation, handed over for use a large amount of material which he had already collected, including a very full bibliography and a number of unpublished pedigrees which had been sent to him, as well as full notes of a number of published histories. I also have to thank him and Dr Sigrid L. S. Pearson for reading the completed manuscript and offering a number of suggestions.

I am much indebted to Miss I. McLearn for the preparing of the pedigree plates for reproduction.

NAME INDEX TO THE CHRONOLOGICAL BIBLIOGRAPHY AND TO THE AUTHORS OF PEDIGREES[2]

Abney (194, 203, 214, 226, 232, 247, 262, 346), Affolter (376), Aguilon (13), Aitken (126), Alhazen (8), Allen (127), Alter (280), Andree (120), Angelucci (204), Aristotle (2, 3), Aubert (78, 92).

Bannister (147), Beare (299), Becker (128, Fig. 399), Behr (328), Bell (Figs. 412, 444, 445, 451, 504, 508, 578, 581, 582, 583, 586), Benedict (90), Berger (184), Berry (138), Bickerton (175, 215, Fig. 562), Bjerrum (284, Fig. 398), Boehm (79, Fig. 382), Bollack (404), Bowditch (405, Fig. 580), Boyle (16), Brailey (148), Brewster (59), Brodhun (195, 221), Bronner (77, Figs. 495, 531), Brown (103), Buffon (28), Bull (149), Bulman (208, 255), Burch (263, 264, 270), Burckhardt (95, Figs. 427, 532, 534, 535, 579), Burd (329, Fig. 454), Butter (51, Fig. 590).

Camerer (119, Fig. 506), Cantonnet (359), Carron du Villards (62), Charpentier (200), Chevreul (63), Chisholm (99), Clemens (81), Cleomedes (4), Cohn (129, 150, Figs. 422, 464–478, 510, 542, 543), Colburn (241, Fig. 384), Cole (330), Colquhoun (57), Combe (54, Fig. 408), Cornaz (70, 72, Figs. 448, 491), Cornish (238), Correspondent (151, Fig. 515), Cunier (64, Fig. 431).

Dalton (40), Darwin, R. W. (38), Davenport (351, Fig. 528), Descartes (14), Desmarres (82), Dewar (116), Dieterici (228), Dobrowolsky (196), Döderlein (394, Fig. 600), de Dominis (12), Donders (104, 152, 176, 177), Dor (139, 185, Fig. 377), Draper (130), Dunlop (258).

Earle (68, Figs. 407, 499), Edridge-Green (317, 331, 383, 387, 388), Elschnig (360), Engelking (411), Engelmann (171 186), Eperon (178).

Farquharson (105), Ferree (378, 389, 395, 412), Festing (194, 203, 226), Fick (131, 229), Fischer (22), Fontan (172), de Fontenay (140, 153, Figs. 414, 424, 483, 484, 544, 547), Franz (361), Fraunhofer (46), Fritsch (307), Frost (154, Fig. 507), Fukala (248).

Galen (6), Galezowski (96), Gall (49, Fig. 482), Galloway (340, Fig. 553), Gates (233), Geiger (106), Gertz (352, 353, Fig. 397), de Godard (32, 33), Göthlin (372, 421, Figs. 400, 403, 511–513, 526, 527, 593, 598), Gotch (286), Goubert (94), Govi (187), Graber (179), Greeff (265), Greenwood (341), Grimaldi (17), Groenouw (287, Fig. 545), Grunert (281, Figs. 376, 380, 391), Gunn (366), Guttmann (318, Figs. 596, 599).

Hartridge (390, 396), Harvey (56), Hayes (347, Fig. 574), Hays (65, 83), Heath (11), Heermann (60), Hegner (369), Helling (50, Fig. 548), Helmholtz (332), Henry (73), Hering (205, 209, 210, 216, 229, 234, 249, 293, Fig. 379), Hermann (164), Herschel (85), Hess (206, 211, 249, 274, 308, 309, 333, 334, 342, 343, 354, 379, 382, 397, Figs. 379, 565, 592, 594, 595), Hessberg (335, Fig. 389), Hesse (288), Hilbert (180, 181, 188, 250, 319), Hillebrand (207), von Hippel (141, 155), de la Hire (25), Hirschberg (189), Hochecker (111, Figs. 538, 559), Hogg (190, 191, Figs. 533, 573), Holmes (156), Holmgren (142, 157), Hombres-Firmas (71), Honigmann (398), Hooke (18), Horner (117, Figs. 420, 589), Houstoun (373, 380, 406), Huddart (34, Fig. 401), Hunt (222), Huygens (23).

Ichikawa (362), Irving (102).

Jeaffreson (109), Jeffries (132, Figs. 493, 501–503, 505, 516–521, 563), Jerchel (363, Fig. 432), Johnson (271, 407), Juler (344, Fig. 378), Jurin (27).

[1] No sibships containing cases of Anomalous Trichromatism are included in the brief analysis given above.

[2] Bibliography numbers are always placed before pedigree numbers.

Kallius (300), Kepler (10), Kerry (294), Kesteven (165), King (58), Kinnaman (275), Kircher (15), Kirschmann (227, 266, Figs. 560, 564) Klainguti (409, 413, Figs. 436, 438, 446, 566, 577, 585, 588), Knies (267, 268, 269), Koehler (158), Köllner (320, 321), König (228, 256, 282, 283), Kohlrausch (414, 415), Kolbe (166), Kreyssig (212), von Kries (133, 167, 242, 243, 244, 257, 386, 416), Kümmell (348), Küster (133).

Landolt (125, 159, 217, 374, Figs. 375, 396), Larsen (399), Leber (100), Legg (160, Fig. 582), Lenz (400), Little (161), Long (330), Lubbock (201), Lutz (349, Fig. 426).

McDougall (272, 295, 296, 322), Macé (134), Macgowan (168), McHardy (162, Fig. 525), Mackay (258), McKendrick (116), Mackenzie (74), Magnus (121, 122, 143, Figs. 395, 459–463, 539, 540, 541, 550), Manz (123), May (323), Merzbacher (336), Moigno (110), Mottram (383), Myers (324).

Nabours (417, Fig. 443), Nagel (276, 277, 310, 311, 325, Figs. 447, 551, 552, 571), Neovin (24), Nettleship (144, 198, 301, 302, 326, 337, 355, 364, 367, 370, Figs. 368–373, 386, 388, 390, 392, 393, 404, 406, 407, 409, 411, 415, 421, 423, 430, 433, 434, 439–441, 453, 494, 498, 529, 530, 558, 567, 568, 569, 590), Newton (19, 20, 26), Nicati (134), Nicholl (45, 47, Figs. 412, 576), Niemetschek (97, Fig. 480), Noël (80), Noyes (169).

Oguchi (424).

Panas (230), Parker (312), Parsons (371, 391, 401), Patten (251), Pearce (273, Fig. 522), Pearson (364), Peddie (245), Pergens (278), Pflüger (145, 252, 253, Fig. 374), Pheophilaktowa (313), Phipson (84), Piper (297), Plateau (124, 303), Plato (1), Pliny (5), Pole (135, 223, 235, 236, Fig. 449), Polimanti (259), Porta (9), Porter (289, 304), Porterfield (29), Posada-Armigo (182), Preyer (98, Fig. 523), Purkinje (52), Purtscher (192).

Querenghi (218).

Raehlmann (113, 118, 260, Figs. 383, 385), Rand (378, 389, 395, 412), Rayleigh (350), Reber (237, Fig. 429), Reichert (375), Requier (31), Richardson-Robinson (418), Ritter (283), Rivers (298, Fig. 425), Roberts (170), Rönne (305, Fig. 387), Rose (86, 87, 88, 91), Rozier (36).

Sachs (43), Saenger (371 A), Samelsohn (213), Samojloff (313, 314), Schanz (402), Schelske (89), Scherffer (30, 37, 41), Schiötz (392, 408, Figs. 410, 417, 419, 435, 437, 450, 514, 575, 587), Schirmer (112, Fig. 492), Schmitz (146, Fig. 524), Schoeler (136, Fig. 584), Schuster (219, Fig. 591), Scoresby (75), Scott (35, Fig. 570), Seebeck (61, Figs. 481, 509, 546), Sheppard (393), Shufeldt (173), Siven (327), Slonaker (246), Smith, E. M. (365), Smith, J. A. (220), Snell (225, 240), Snowball (Figs. 416, 418, 442, 452), Sommer (53, Figs. 490, 500), Somya (231), Spurzheim (55, Fig. 482), Steffan (163), Steinheim (183), Stilling (114, Figs. 485–489, 549), Stort (199), Swanzy (174), Szili (193), Szokalski (66).

Torelle (285), Trendelenburg (290), Tucker (356), Turbervile (21).

Uhlenhuth (384), Uhthoff (261, 579, Figs. 381, 394), Usher (357, 364, 403, Figs. 408, 413).

Valentine (368), Vaughan (315), Venturi (39, 42, 44), Vernon (93), Verrey (202), Vierordt (101), da Vinci (7), Vogt (409, 410, 419, Figs. 436, 438, 446, 566, 577, 585).

Waardenburg (422, Figs. 402, 405), Wardrop (48), Warlomont (115), Wartmann (67, 69, Fig. 561), Watson (338), de Wecker (125, Fig. 375), Wehrli (291), Wernicke (385, Fig. 367), Wery (292), Whitaker (306), Wilbrand (371A), Wilson, G. (76, Figs. 455–458, 479, 496, 497, 536, 537, 556, 557), Wilson, J. A. (358), Winch (345), Wölfflin (420, 423, Figs. 597, 601), Woinow (108), Wolfe (137, Figs. 554, 555, 572), Wolffberg (254), Wood (381).

Yamaguchi (339), Yerkes (316).

CHRONOLOGICAL BIBLIOGRAPHY

This Bibliography does not claim to be a complete record of any section of the literature which has been published on colour vision or colour-blindness; all papers known to the writer which are of interest from the point of view of heredity have been included, and an attempt has been made to include other papers of wide scope illustrating the different aspects of the subject, or such papers as have been referred to in the introductory account.

* Indicates that the original publication has not been seen.

1. Plato: *The Dialogues of Plato.* Translated by B. Jowett. Vols. I—IV. Oxford, 1871.

2. Aristotle: *Opera Omnia.* Vol. III. Paris, 1854. [In the section *De Insomniis*, Cap. II, p. 508, we find what is possibly the earliest suggestion of the persistence of sensory impressions and of after-images. Aristotle writes as follows: "And if we look at one colour for a long time, whether white or green, that object, whatever it may be to which we turn our gaze, appears the same colour. And if, after looking at the sun or some other bright object, we shut our eyes, when we turn our eyes aside, in whatever direction we chance to direct our eyes, the object appears, at the end of our line of vision, first in its natural colour, then it changes to bright red, then to dark red, and finally turns to black and disappears."

3. Aristotle: *The History of Animals.* Translated by R. Cresswell. London, 1862.

4. Cleomedes: *Meteora.* Burdigalae, 1605.

5. Plinius, C. S.: *Historia Naturalis.* T. VI. Edited by Gabriel Brotier. Paris, 1779.

6. Galen: *Opera Omnia.* Basileae, 1562. [References have been taken from the section entitled *De Usu Partium Corporis Humani.* Lib. X. Cap. 3 and Cap. 12.]

7. da Vinci, Leonardo: *Trattato della Pittura.* Parigi, 1651.

8. Alhazen: *Opticae Thesaurus.* Translated by F. Risnero. Basileae, 1592. [The author in Liber I, Cap. I, describes the persistence of visual impressions and some of the phenomena of after-images; he however appears to have only observed positive after-images, and concludes:—"Et similiter si

aspexerit corpus coloratum colore caeruleo vel rubeo, vel alio colore forti scintillante, super quod oriebatur lux solis: & moretur in aspiciẽdo ipsum: deinde auferat visum suum ad visibilia alba in loco debilis lucis: inveniet colores illos admixtos cũ illo colore." Probably he was influenced in this by Aristotle's earlier observation.]

9. Porta, J. Baptista: *De Refractione.* Neapolis, 1593.
10. Kepler, J.: *Ad Vitellionem Paralipomena, quibus Astronomiae pars optica traditur.* Francofurti, 1604.
11. Heath, J.: *Two Centuries of Epigrammes.* London, 1610.
12. Dominis, M. A. de: *De radiis visus et lucis in vitris perspectivis et iride.* Venetiis, 1611.
13. Aguilon, F.: *Opticorum Libri sex.* Antverpiae, 1613. [Liber I, Prop. lii gives an account of negative after-images and explains their occurrence.]
14. Descartes, R.: *Œuvres de Descartes.* T. v. Publiées par Victor Cousin. Paris, 1824. [Vol. v, containing *La Dioptrique, Les Météores* and *La Géométrie*, was first published in 1638.]
15. Kircher, A.: *Ars magna lucis et umbrae.* Rome, 1646. [For an interesting early account of the production of accidental colours, see pp. 162—163.]
16. Boyle, R.: *Experiments and Considerations touching Colours.* The works of the Honourable Robert Boyle. Vol. I, pp. 662—788. London, 1772. [The section on Colours was first published in London in 1663.]
17. Grimaldi, F. M.: *Physico-Mathesis de Lumine, Coloribus, et Iride.* Bononiae, 1665. [The author died in 1663 and his work was not published until two years after his death.]
18. Hooke, R.: *Micrographia.* London, 1665. [pp. 47—79 discuss various phenomena of colours and light; the author concludes that the motion of light (i) ought to be exceeding quick; (ii) must be a vibrative motion; (iii) is a very short vibrative motion. "These, I think, are the three principal proprieties of a motion requisite to produce the effect called Light in the object."]
19. Newton, Sir Isaac: New theory about Light and Colours. *Phil. Trans.* Vol. VI, pp. 3075—3087. London, 1672.
20. Newton, Sir Isaac: Answer to Some Considerations upon the Doctrine of Light and Colours. *Phil. Trans.* Vol. VII, pp. 5084—5103. London, 1672.
21. Turbervile, D.: Two letters from the great and experienced oculist Dr Turbervile of Salisbury, to Mr William Musgrave, S.P.S., of Oxon, containing several remarkable cases in Physick, relating chiefly to the eyes. *Phil. Trans.* Vol. XIV, p. 736. London, 1684. ["A maid two or three and twenty years old, came to me from Banbury, who could see very well, but no colour beside Black and White. She had such scintillations by night (with the appearances of Bulls, Bears etc.) as terrified her very much; she could see to read sometimes in the greatest darkness for almost a quarter of an hour."]
22. Fischer, C. F.: *De Coloribus.* Jenae, 1689 (?).
23. Huygens, C.: *Traité de la Lumière.* Leide, 1690.
24. Neovin, O. J. M.: *Caecus de Colore judicans.* Jenae, 1691.
25. de la Hire: *Mémoires de Mathématique et de Physique.* Paris, 1694. [Contains, pp. 233—302, "Un Traité des differens Accidens de la Vûe," giving some account, p. 289, of the after-images seen as a result of looking at the sun.]
26. Newton, Sir Isaac: *Opticks: or a Treatise of the Reflexions, Refractions, Inflexions and Colours of Light.* London, 1704. [This work was completed many years before its publication; the author writes, "To avoid being engaged in Disputes about these Matters, I have hitherto delayed the Printing...."]
27. Jurin, J.: *An Essay upon Distinct and Indistinct Vision. A Compleat System of Opticks.* By R. Smith. Vol. II, pp. 115—171. Cambridge, 1738. [Some phenomena of accidental colours are described, pp. 168—171.]
28. Buffon, G. L. L. de: Dissertation sur les Couleurs Accidentelles. *Histoire de l'Académie Royale des Sciences.* Année 1743. Mémoires, pp. 147—158. Paris, 1746.
29. Porterfield, W.: *A Treatise on the Eye. The Manner and Phenomena of Vision.* Edinburgh, 1759. [These two volumes contain much which is historically of considerable interest; Vol. I, p. 343 gives some discussion of accidental colours. In Vol. II, p. 347 we find: "Thus the Motion which causes Redness in one, may cause the Sensation of green or blue in another, or even some other new Sensation, which no body before has ever felt or dreamed of."]
30. *Scherffer, C.: *De Coloribus accidentalibus.* Wien, 1761.
31. Requier, J. B.: *Vie de Nicolas Claude Peiresc.* Paris, 1770. [An account is given, pp. 295—296, of the observations on accidental colours made by Peiresc in 1634.]

32. De Godard: Premier Mémoire d'Optique, ou Explication d'une Expérience de M. Franklin. *Observations sur la Physique, sur l'Histoire Naturelle et sur les Arts.* T. VII, pp. 509—514. Paris, 1776. [Discusses Franklin's observations on the persistence of visual images.]

33. De Godard: Recherches sur les Couleurs accidentelles. *Observations sur la Physique, sur l'Histoire Naturelle et sur les Arts.* T. VIII, pp. 1—16, 269—278. Paris, 1776. [Discusses Buffon's observations on accidental colours.]

34. Huddart, J.: An account of persons who could not distinguish colours. *Phil. Trans.* Vol. LXVII, Part I, pp. 260—265. London, 1777. See Fig. 401.

35. Scott, J.: An account of a remarkable imperfection of sight. *Phil. Trans.* Vol. LXVIII, Part II, pp. 611—614. London, 1778. See Fig. 570.

36. Rozier, l'Abbé: Sur quelques Personnes qui ne peuvent distinguer les Couleurs. *Observations sur la Physique.* T. XIII, pp. 86—88. Paris, 1779.

37. Scherffer, C.: Dissertation sur les Couleurs Accidentelles. *Observations sur la Physique, sur l'Histoire Naturelle et sur les Arts.* T. XXVI, pp. 175—187, 275—291. Paris, 1785.

38. Darwin, R. Waring: New Experiments on the Ocular Spectra of Light and Colours. *Phil. Trans.* Vol. 76, pp. 313—348. London, 1786.

39. Venturi, G.: *Essai sur les ouvrages Physico-Mathématiques de Léonard de Vinci.* Paris, 1797. [Explains the inverted image in the eye in a Section entitled De la Vision, pp. 23—24.]

40. Dalton, J.: Extraordinary facts relating to the Vision of Colours: with observations. *Memoirs of Literary and Philosophical Society of Manchester.* Vol. V, Part I, pp. 28—45. London, 1798. [This very interesting account of his own colour-blindness, with a discussion of the condition, was read by the author before the Society in October, 1794.]

41. Herschel, W.: Investigation of the powers of the prismatic colours to heat and illuminate objects; with remarks that prove the different refrangibilities of radiant heat. *Phil. Trans.* Vol. 90, pp. 255—284. London, 1800.

42. Venturi, G.: Dei Colori Immaginarii. *Opuscoli scelti sulle Scienze e sulle Arti.* T. XXI, pp. 274—287. Milano, 1801.

43. Sachs, G. T. L.: *Historia naturalis duorum leucaethiopum auctoris ipsius et sororis ejus.* Solisbaci, 1812.

44. Venturi, G.: *Commentarij sopra la Storia e le Teorie dell' Ottica.* Bologna, 1814. [Gives a translation of a manuscript by Theodoricus, dated 1311, containing the earliest known explanation of the rainbow, pp. 150—165.]

45. Nicholl, W.: Account of a case of curious imperfection of vision. *Medico-Chirurgical Transactions.* Vol. VII, pp. 477—481. London, 1816. See Fig. 412.

46. Fraunhofer, J.: Bestimmung des Brechungs- und Farbenzerstreuungs-Vermögens verschiedener Glasarten, in Bezug auf die Vervollkommnung achromatischer Fernröhre. *Denkschriften der königlichen Akademie der Wissenschaften zu München f. die Jahre* 1814 *und* 1815. Bd. V, S. 193—226. München, 1817.

47. Nicholl, W.: Account of a case of defective power to distinguish colours. *Medico-Chirurgical Transactions.* Vol. IX, pp. 359—363. London, 1818. See Fig. 576.

48. Wardrop, J.: *Essays on the Morbid Anatomy of the Human Eye.* Vol. II, Ch. xlvii, pp. 196—201. London, 1818. [Of coloured vision.]

49. Gall, F. J.: *Anatomie et Physiologie du Système Nerveux en général et du Cerveau en particulier.* T. IV. Paris, 1819. [Cases of colour-blindness are referred to on p. 69.] See Fig. 482.

50. Helling, G. L.: *Praktisches Handbuch der Augenkrankheiten.* Berlin, 1821. [Case of colour-blindness is described in Bd. I, S. 1—3.] See Fig. 548.

51. Butter, J.: Remarks on the Insensibility of the Eye to certain Colours. *Edinburgh Philosophical Journal.* Vol. VI, pp. 135—140. Edinburgh, 1822. See Fig. 590.

52. Purkinje, J. E.: *Beobachtungen und Versuche zur Physiologie der Sinne.* Prag und Berlin, 1823—1825.

53. Sommer: Ueber Chromatopseudopsie, oder den, manchen Menschen eigenen Mangel des Farbenunterscheidungsvermögens. *Journal der Chirurgie u. Augen-Heilkunde.* Bd. V, S. 19—43. Berlin, 1823. See Figs. 490, 500.

54. Combe, G.: *System of Phrenology.* Edinburgh, 1825. [Contains an interesting account of the colour-blindness in the early cases shown in Fig. 408. Usher subsequently followed up these cases and worked out an extensive pedigree showing a family history of seven generations. See Bibl. No. 357.]

55. Spurzheim, G.: *Phrenology or the doctrine of the mind and of the relations between its manifestations and the body.* London, 1825. [The author reports, p. 276, that he knows a family all the individuals of which distinguish only black and white.]

56. Harvey, G.: On an anomalous case of Vision with regard to Colours. *Transactions, Royal Society of Edinburgh.* Vol. x, pp. 253—262. Edinburgh, 1826. [Describes colour-blindness in a man aged 60, no other case of defective colour vision was known in his family.]

57. Colquhoun, H.: An account of two cases of insensibility of the eye to certain of the Rays of Colour. *Glasgow Medical Journal.* Vol. ii, pp. 12—21. Glasgow, 1829. [An isolated case of colour-blindness in a male with normal parents and children is very fully described.]

58. King, P. Lord: *The Life of John Locke, with extracts from his Correspondence, Journals, and Commonplace books.* London, 1829.

59. Brewster, D.: *The Life of Sir Isaac Newton.* London, 1831.

60. Heermann, G. *Über die Bildung der Gesichtsvorstellungen aus den Gesichtsempfindungen.* Hannover, 1835. [p. 158, gives an early reference to yellow vision not associated with jaundice.]

61. Seebeck, A.: Ueber den bei manchen Personen vorkommenden Mangel an Farbensinn. *Annalen der Physik und Chemie.* Bd. xlii, S. 177—233. Leipzig, 1837. See Figs. 481, 509, 546.

62. Carron du Villards, C. J. F.: Quelques mots pour servir à l'histoire anatomique et physiologique des yeux albinos. *Encyclograph. d. Sciences Médicales.* T. xxvii. 2e Série. 1838.

63. Chevreul, M. E.: *De la Loi du Contraste Simultané des Couleurs.* Paris, 1839.

64. Cunier, F.: Observations curieuses d'une Achromatopsie héréditaire depuis cinq générations. *Annales d'Oculistique et de Gynécologie.* T. i, pp. 417—420. Charleroi, 1839. See Fig. 431.

65. Hays, I.: Report of Cases treated in the Wills Hospital for the Blind and Lame, during the months of Oct., Nov. and Dec. 1839, with Observations. *American Journal of Medical Sciences.* Vol. xxvi, pp. 277—304. Philadelphia, 1840. [Case I describes temporary colour-blindness in Mary Bishop.]

66. Szokalski, V.: *Ueber die Empfindungen der Farben in physiologischer u. pathologischer Hinsicht.* Giessen, 1842. [Describes cases of Chrupsia, pp. 151—155.]

67. Wartmann, E.: On Daltonism. *Report of British Association at Plymouth,* 1841. Notes and Abstracts of Communications, pp. 40, 41. London, 1842.

68. Earle, Pliny: On the inability to distinguish Colours. *American Journal of Medical Sciences.* New Series. Vol. ix, pp. 346—354. Philadelphia, 1845. See Fig. 499.

69. Wartmann, E.: Memoir on Daltonism. *Scientific Memoirs.* Vol. iv, pp. 156—187. London, 1846. [The original of this translation was published in the *Actes de la Soc. Helvét. des Sciences Naturelles,* 1841, pp. 194 *et seq.*] See Fig. 561. Second Memoir: *Mémoires de la Soc. de Physique et d'Hist. nat. de Genève.* T. xi, pp. 183—231. Geneva, 1848.

70. Cornaz, C. A. E.: *Des abnormités congéniales des yeux et de leurs annexes.* Lausanne, 1848.

71. Hombres-Firmas: Observations d'Achromatopsie. *Comptes rendus de l'Académie des Sciences.* T. xxix, pp. 175—179. Paris, 1849.

72. Cornaz, C. A. E.: Quelques observations d'abnormités congéniales des yeux et de leurs annexes. *Annales d'Oculistique.* T. xxiii, pp. 24—52. Charleroi, 1850. [Colour-blindness in three individuals is described, pp. 42—47.] See Figs. 448, 491.

73. Henry, W. C.: *Memoirs of the Life and Scientific Researches of John Dalton.* London, 1854. [A post-mortem examination of the eyes of Dalton is described on p. 202; nothing abnormal was found in the humours or tunics of the eye, but no microscopic examination is referred to. The brain also was examined and an imperfect or deficient development of the anterior lobes is described.]

74. Mackenzie, W.: *A Practical Treatise on the Diseases of the Eye.* 4th ed. London, 1854. [Describes cases of Chrupsia, pp. 932—934.]

75. Scoresby, W.: An Inquiry into some of the circumstances and principles which regulate the production of Pictures on the Retina of the Human Eye, with their measure of endurance, their Colours and Changes. *Proc. Roy. Soc.,* 1853. Vol. vi, pp. 380—383. London, 1854; also *Proc. Roy. Soc.* 1854. Vol. vii, pp. 117—122. London, 1856.

76. Wilson, G.: *Researches on Colour-blindness.* Edinburgh, 1855. See Figs. 455—458, 479, 496, 497, 536, 537, 556, 557.

77. Bronner, E.: Cases of Colour-blindness. *Medical Times and Gazette.* New Series. Vol. xii, pp. 359—361. London, 1856. See Figs. 495, 531.

78. Aubert, H.: Ueber die Gränzen der Farbenwahrnehmung auf den seitlichen Theilen der Retina. *Archiv f. Ophthalmologie.* Bd. iii, Abth. ii, S. 38—67. Berlin, 1857.

79. Boehm, L.: *Der Nystagmus und dessen Heilung.* Berlin, 1857. [Total colour-blindness in six brothers is described, pp. 141—145.] See Fig. 382.

80. Noël, C. L.: *De la Chromatopseudopsie. Thèse,* pp. 1—58. Paris, 1857. [Reviews the work of former writers on the subject; gives no new hereditary cases.]

81. Clemens, T.: Farbenblindheit während der Schwangerschaft, nebst einigen zeitgemässen Erörterungen über Farbenblindheit und deren Ursache im Allgemeinen. *Archiv f. physiologische Heilkunde.* Bd. II, S. 41—59. Stuttgart, 1858.

82. Desmarres, L. A.: *Traité théorique et pratique des Maladies des Yeux.* T. III, pp. 694—696. Paris, 1858.

83. Hays, I.: Inability to distinguish colours. *American Journal of Medical Sciences.* N. S., Vol. XXXVI, p. 394. Philadelphia, 1858.

84. Phipson, T. L.: Action de la santonine sur la vue. *Comptes Rendus.* T. XLVIII, pp. 593—594. Paris, 1859.

85. Herschel, J. F. W.: Remarks on Colour-blindness. *Proc. Roy. Soc.* Vol. X, pp. 72—84. London, 1860.

86. Rose, E.: Ueber stehende Farbentäuschungen. *Archiv f. Ophthalmologie.* Bd. VII, Abth. II, S. 72—108. Berlin, 1860.

87. Rose, E.: Ueber die Farbenblindheit durch Genuss der Santonsäure. *Archiv f. pathologische Anatomie u. Physiologie.* Bd. XIX, S. 522—536; Bd. XX, S. 245—290. Berlin, 1860, 1861.

88. Rose, E.: Ueber die Hallucinationen im Santonrausch. *Archiv f. pathologische Anatomie u. Physiologie.* Bd. XXVIII, S. 30—82. Berlin, 1863.

89. Schelske, R.: Zur Farbenempfindung. *Archiv f. Ophthalmologie.* Bd. IX, Abth. III, S. 39—62. Berlin, 1863.

90. Benedict, M.: Der Daltonismus bei Sehnervenatrophie. *Archiv f. Ophthalmologie.* Bd. X, Abth. II, S. 185—190. Berlin, 1864.

91. Rose, E.: Die Gesichtstäuschungen im Icterus. *Archiv f. pathologische Anatomie u. Physiologie u. f. klinische Medicin.* Bd. XXX, S. 442—447. Berlin, 1864.

92. Aubert, H.: *Physiologie der Netzhaut.* Breslau, 1865. [Subjective phenomena of vision are described, pp. 332—390.]

93. Vernon, B. J.: Case of Congenital Myopia; with a faulty perception of colours limited to a small portion of one retina of recent origin. *Saint Bartholomew's Hospital Reports.* Vol. II, pp. 93—95. London, 1866.

94. Goubert, E.: *De l'Achromatopsie ou cécité des couleurs.* Paris, 1867. [Gives an interesting review of much of the literature of the subject published before this date.]

95. Burckhardt, F.: Ueber Farbenblindheit. *Verhandlungen der Naturforschenden Gesellschaft in Basel.* Bd. V, S. 558—570. Basel, 1868. See Figs. 427, 532, 534, 535, 579.

96. Galezowski, X.: *Du diagnostic des Maladies des Yeux par la Chromatoscopie rétinienne.* Paris, 1868. [Case of total colour-blindness described, p. 145, in a man of letters who had "very weak eyes," myopia and nystagmus; the author reports that his vision is good and that he can read small print.]

97. Niemetschek, J.: Ueber Farbenblindheit und Farbensehen. *Vierteljahrsschrift f. praktische Heilkunde.* Bd. C, S. 224—238. Prag, 1868. See Fig. 480.

98. Preyer, W.: Ueber anomale Farbenempfindungen und die physiologischen Grundfarben. *Archiv f. die gesammte Physiologie des Menschen u. der Thiere.* Bd. I, S. 299—329. Bonn, 1868. See Fig. 523.

99. Chisholm, J. J.: Colour Blindness, an effect of Neuritis. *Royal London Ophthalmic Hospital Reports.* Vol. VI, pp. 214—215. London, 1869.

100. Leber, T.: Ueber das Vorkommen von Anomalien des Farbensinnes bei Krankheiten des Auges, nebst Bemerkungen über einige Formen von Amblyopie. *Archiv f. Ophthalmologie.* Bd. XV, Abth. III, S. 26—107. Berlin, 1869.

101. Vierordt, C.: Beschreibung einer photometrischen Methode zur Messung und Vergleichung der Stärke des farbigen Lichtes. *Annalen der Physik u. Chemie.* Bd. CXXXVII, S. 200—222. Leipzig, 1869.

102. Irving, J.: Note on Color Blindness. *Indian Medical Gazette.* Vol. V, pp. 77—78. Calcutta, 1870.

103. Brown, D. Dyce: On the use of Santonin in Eye-Disease. *British and Foreign Medico-Chirurgical Review.* Vol. XLVII, pp. 472—476. London, 1871.

104. Donders, F. C.: Einige Mittheilungen verschiedenen Inhaltes. *Klinische Monatsblätter f. Augenheilkunde.* Bd. IX, S. 468—477. Erlangen, 1871. [Case of total colour-blindness described, S. 470—471.]

105. Farquharson, R.: Experiments on Santonin. *British Medical Journal.* Vol. II for 1871, p. 466. London, 1871.

106. Geiger, L.: *Ueber den Farbensinn der Urzeit und seine Entwickelung. Zur Entwickelungsgeschichte der Menschheit.* S. 45—60. Stuttgart, 1871.

107. Leber, T.: Ueber hereditäre und congenital-angelegte Sehnervenleiden. *Archiv f. Ophthalmologie.* Bd. xvii, Abth. ii, S. 249—291. Berlin, 1871.

108. Woinow, M.: Zur Diagnose der Farbenblindheit. *Archiv f. Ophthalmologie.* Bd. xvii, Abth. ii, S. 241—248. Berlin, 1871. [Describes a case of unilateral green-blindness in a female whose left eye had normal colour vision.]

109. Jeaffreson, C. S.: Colour-Blindness in Disease of Brain and Optic Nerves. *Lancet.* Vol. i for 1872, p. 601. London, 1872.

110. Moigno, F.: On Accidental or Subjective Colors. *Report of Smithsonian Institution* for 1866, pp. 211—253. Washington, 1872.

111. Hochecker, T.: Ueber angeborene Farbenblindheit. *Archiv f. Ophthalmologie.* Bd. xix, Abth. iii, S. 1—37. Berlin, 1873. See Figs. 538, 559.

112. Schirmer, R.: Ueber erworbene und angeborene Anomalien des Farbensinnes. *Archiv f. Ophthalmologie.* Bd. xix, Abth. ii, S. 194—235. Berlin, 1873. See Fig. 492.

113. Raehlmann, E.: Beiträge zur Lehre vom Daltonismus und seiner Bedeutung für die Young'sche Farbentheorie. *Archiv f. Ophthalmologie.* Bd. xix, Abth. iii, S. 88—106. Berlin, 1873.

114. Stilling, J.: Beiträge zur Lehre von den Farbenempfindungen, i u. ii. *Ausserordentliches Beilageheft zu den klinischen Monatsblättern für Augenheilkunde.* Bd. xiii. Stuttgart, 1875. See Figs. 485—489, 549.

115. Warlomont, E.: De la chromatopseudopsie. *Annales d'Oculistique.* T. lxxiv, pp. 5—55. Bruxelles, 1875. [The author gives a full discussion of the subject and a bibliography; on p. 33 he reports that two of his sons are blind for violet, each is affected to the same degree.]

116. Dewar, J. and McKendrick, J. G.: On the Physiological Action of Light. *Transactions, Royal Society of Edinburgh.* Vol. xxvii, pp. 141—166. Edinburgh, 1876.

117. Horner: Die Erblichkeit des Daltonismus. Ein Beitrag zum Vererbungsgesetz. *Amtlicher Bericht über die Verwaltung des Medizinalwesens des Kantons Zürich vom Jahr 1876.* S. 208—211. Zürich, 1876. See Figs. 420, 589. [We are much indebted to the Kantonale Direktion des Gesundheitswesens, Zürich, for the loan of this work containing the original account of the pedigree on the basis of which "Horner's Law" was formulated.]

118. Raehlmann, E.: Ueber den Daltonismus und die Young'sche Farbentheorie. *Archiv f. Ophthalmologie.* Bd. xxii, Abth. i, S. 29—64. Berlin, 1876. See Fig. 385.

119. Camerer, W.: Versuche eines Farbenblinden am Spectralapparat. *Klinische Monatsblätter f. Augenheilkunde.* Bd. xv, S. 51—60. Rostock, 1877. See Fig. 506.

120. Andree, R.: Ueber den Farbensinn der Naturvölker. *Zeitschrift f. Ethnologie.* Bd. x, S. 323—334. Berlin, 1878.

121. Magnus, H.: *Die Farbenblindheit, ihr Wesen und ihre Bedeutung.* Breslau, 1878. See Figs. 459—463.

122. Magnus, H.: Beiträge zur Kenntniss der physiologischen Farbenblindheit. *Archiv f. Ophthalmologie.* Bd. xxiv, Abth. iv, S. 171—236. Berlin, 1878. See Figs. 539, 540, 541, 550.

123. Manz, W.: Ueber albinotische Menschenaugen. *Archiv f. Ophthalmologie.* Bd. xxiv, Abth. iv, S. 139—170. Berlin, 1878.

124. Plateau, J.: Bibliographie analytique des principaux Phénomènes subjectifs de la Vision. *Mémoires de l'Académie Royale des Sciences, des Lettres et des Beaux-Arts de Belgique.* T. xlii. (No. i.) Bruxelles, 1878.

125. de Wecker, L. and Landolt, E.: *Traité complet d'Ophtalmologie.* Paris, 1878. [Colour vision is considered, T. i, pp. 539—592; small family history of total colour-blindness is given, p. 566.] See Fig. 375.

126. Aitken, J.: Colour-Blindness. *Nature.* Vol. xx, p. 627. London, 1879. [Describes his method of testing colour vision and its applicability to the investigation of colour-blindness.]

127. Allen, G.: *The Colour Sense.* London, 1879.

128. Becker, O.: Ein Fall von angeborener einseitiger totaler Farbenblindheit. *Archiv f. Ophthalmologie.* Bd. xxv, Abth. ii, S. 205—212. Berlin, 1879. See Fig. 399.

129. Cohn, H.: *Studien über angeborene Farbenblindheit.* Breslau, 1879. See Figs. 422, 464—478, 510, 542, 543.

130. Draper, J. D.: On a new form of Spectrometer, and on the Distribution of the Intensity of Light in the Spectrum. *Philosophical Magazine and Journal of Science.* 5th Ser., Vol. viii, pp. 75—80. London, 1879.

131. Fick, A.: Lehre von der Lichtempfindung. *Hermann's Handbuch der Physiologie der Sinnesorgane.* Bd. III, S. 139—233. Leipzig, 1879.

132. Jeffries, B. Joy: *Color-Blindness. Its Dangers and its Detection.* Boston, 1879. [Cases are described and scanty family histories given, pp. 18, 19, 63.] See Figs. 493, 501, 502, 503, 505, 516—519, 520 (1883 edition), 521 (1883 edition), 563.

133. von Kries, J. and Küster, F.: Ueber angeborene Farbenblindheit. *Archiv f. Physiologie.* Jahr 1879, S. 513—524. Leipzig, 1879. [Is concerned with physiological considerations; no hereditary cases are described.]

134. Macé, J. and Nicati, W.: Recherches sur le Daltonisme. *Comptes rendus des séances de l'Académie des Sciences.* T. LXXXIX, pp. 716—718. Paris, 1879. [Is concerned with the physiology of colour-blindness; does not refer to its hereditary nature.]

135. Pole, W.: Colour-Blindness. *Nature.* Vol. XX, pp. 477—480. London, 1879.

136. *Schoeler, H.: Ueber Roth-blaugrün- und Grün-purpurblindheit. *Jahresbericht über die Wirksamkeit der (früher Ewers'schen) Augen-Klinik.* S. 41—55. Berlin, 1879. See Fig. 584.

137. Wolfe, J. R.: Colour-sight and Colour-blindness. *Medical Times and Gazette.* Vol. I for 1879, pp. 372—375, 419—421. London, 1879. See Figs. 554, 555, 572.

138. Berry, G. A.: Remarks on the Examination and Classification of Cases of Colour-Blindness. *Edinburgh Medical Journal.* Vol. XXV, Part I, pp. 305—322. Edinburgh, 1880.

139. Dor, H.: The Historical Evolution of the Sense of Colour: Refutation of the theories of Gladstone and Magnus. *Edinburgh Medical Journal.* Vol. XXV, Part I, pp. 426—436. Edinburgh, 1880.

140. Fontenay, O. E. de: Oplysninger om den medfödte Farveblindheds Forekomst i Danmark, et Bidrag til Farveblindhedens Statistik. *Nordiskt Medicinskt Arkiv.* Bd. XII, No. 8, S. 1—44; No. 15, S. 1—20. Stockholm, 1880. See Figs. 414, 424, 483, 484, 544, 547.

141. von Hippel, A.: Ein Fall von einseitiger congenitaler Roth-grünblindheit bei normalem Farbensinn des anderen Auges. *Archiv f. Ophthalmologie.* Bd. XXVI, Abth. II, S. 176—186. Berlin, 1880. [The right eye was affected, the left eye normal. See also Bibl. No. 155.]

142. Holmgren, F.: Ueber die subjective Farbenempfindung der Farbenblinden. *Centralblatt f. die medicinischen Wissenschaften.* Bd. XVIII, S. 898—900, 913—916. Berlin, 1880.

143. Magnus, H.: Ein Fall von angeborener totaler Farbenblindheit. *Centralblatt f. praktische Augenheilkunde.* Bd. IV, S. 373—377. Leipzig, 1880. See Fig. 395.

144. Nettleship, E.: On cases of congenital day-blindness with colour-blindness. *St Thomas's Hospital Reports.* Vol. X, pp. 37—48. London, 1880. See Figs. 388, 390, 393, 404.

145. Pflüger, E.: Beobachtungen an Farbenblinden. *Archiv f. Augen- und Ohrenheilkunde.* Bd. IX, S. 381—412. Wiesbaden, 1880. [Four members of the pedigree described by Horner, Bibl. No. 117, are examined and described by this author, pp. 383, 384.]

146. Schmitz, A.: Statistische Mittheilungen über das Vorkommen von Farbenblindheit in Cleve und Umgegend. *Centralblatt f. praktische Augenheilkunde.* Bd. IV, S. 275—278. Leipzig, 1880. See Fig. 524.

147. Bannister, H. M.: On some points in regard to colour-blindness. *Journal of Nervous and Mental Disease.* Vol. VIII, pp. 49—63. New York, 1881. [Concludes that colour-blindness when partial and incomplete is in some instances at least a functional defect of the higher cortical centres concerned in sight and further that it amounts in some cases to merely a retardation of perception of certain colours.]

148. Brailey, W. A.: Report of the Committee on Colour-Blindness. *Transactions, Ophthalmological Society of U.K.* Vol. I, pp. 191—207. London, 1881.

149. Bull, O. B.: Studien über Lichtsinn und Farbensinn. *Archiv f. Ophthalmologie.* Bd. XXVII, Abth. I, S. 54—154. Berlin, 1881.

150. Cohn, H.: Ueber das Verschwinden der Farbenblindheit beim Erwärmen des Auges. *Jahresbericht der Schlesischen Gesellschaft f. vaterländische Cultur.* Bd. LVIII, S. 46—49. Breslau, 1881.

151. "Correspondent": Hereditary Colour-Blindness. *Popular Science Monthly.* Vol. XIX, pp. 423—424. New York, 1881. See Fig. 515.

152. Donders, F. C.: Ueber Farbensysteme. *Archiv f. Ophthalmologie.* Bd. XXVII, Abth. I, S. 155—223. Berlin, 1881.

153. Fontenay, O. E. de: Results of Examinations for Colour-blindness in Denmark. *Archives of Ophthalmology.* Vol. X, pp. 8—19. New York, 1881. [This is an abstract of an article published in the *Nordiskt Medicinskt Arkiv*, Bd. XII, 1880, arranged by Dr B. Joy Jeffries.] See Fig. 424.

154. Frost, Adams: Colour-Blindness. *British Medical Journal.* Vol. I for 1881, p. 645. London, 1881. See Fig. 507.

155. von Hippel, A.: Ueber einseitige Farbenblindheit. *Archiv f. Ophthalmologie.* Bd. xxvii, Abth. iii, S. 47—55. Berlin, 1881. [Further discussion of a case previously described. See Bibl. No. 141.]

156. Holmes, E. L.: A case of puerperal retinitis, blindness; colour-blindness; recovery. *Archives of Ophthalmology.* Vol. x, pp. 421—422. New York, 1881. [The patient was totally colour-blind for three months, after this blue tints began to appear, then yellow, brown, red, and finally green; it was five years before she could distinguish different shades of green.]

157. Holmgren, F.: How do the Colour-blind see the different Colours? *Proc. Roy. Soc.* Vol. xxxi, pp. 302—306. London, 1881.

158. Koehler, S. R.: Color-Blindness. *Popular Science Monthly.* Vol. xix, pp. 91—94. New York, 1881.

159. Landolt, E.: Achromatopsie Totale. *Archives d'Ophtalmologie.* T. I, pp. 114—120. Paris, 1881.

160. Legg, J. Wickham: Report on Haemophilia with a note on the hereditary descent of colour-blindness. *Saint Bartholomew's Hospital Reports.* Vol. xvii, pp. 302—320. London, 1881. See Fig. 582.

161. Little, W. S.: Experience of a red-blind physician with the ophthalmoscope; practical advantage of color-blindness with a case. *Archives of Ophthalmology.* Vol. x, pp. 20—22. New York, 1881.

162. McHardy: Colour-Blindness. *British Medical Journal.* Vol. I for 1881, p. 645. London, 1881. See Fig. 525.

163. Steffan, P.: Beitrag zur Pathologie des Farbensinnes. *Archiv f. Ophthalmologie.* Bd. xxvii, Abth. ii, S. 1—24. Berlin, 1881.

164. *Hermann, G.: *Ein Beitrag zur Casuistik der Farbenblindheit.* Dissertation. Dorpat, 1882.

165. Kesteven, W. H.: Case of Xanthopsis or Perverted Colour Vision. *Medical Times and Gazette.* Vol. I for 1882, p. 131. London, 1882.

166. Kolbe, B.: Ein Fall von angeborener einseitiger Rothgrünschwäche. *Centralblatt f. praktische Augenheilkunde.* Bd. vi, S. 291—296. Leipzig, 1882.

167. von Kries, J.: *Die Gesichtsempfindung und ihre Analyse.* Leipzig, 1882.

168. Macgowan: Colour-Blindness. *Lancet.* Vol. I for 1882, p. 76. [States that colour-blindness is unknown or unrecognised in Japan and Indo-China; the author examined 1000 hospital patients and others among crews of gunboats in the imperial service of China and failed to find colour-blindness. This is not confirmed by other enquiries.]

169. Noyes, H. D.: Two cases of Hemi-achromatopsia. *Archives of Ophthalmology.* Vol. xi, pp. 210—221. New York, 1882.

170. Roberts, C.: Colour-Blindness as a Racial Character. *Lancet.* Vol. I for 1882, p. 124. London, 1882.

171. Engelmann, T. W.: Bacterium photometricum. Ein Beitrag zur vergleichenden Physiologie des Licht- und Farbensinnes. *Archiv f. die gesammte Physiologie.* Bd. xxx, S. 95—124. Bonn, 1883.

172. Fontan: Un Cas de Daltonisme traumatique. *Recueil d'Ophtalmologie.* Série 3, T. v, pp. 705—710. Paris, 1883.

173. Shufeldt, R. W.: A case of Daltonism affecting one eye. *Medical Record.* Vol. xxiii, p. 319. New York, 1883. [The case described was in a male aged 21 years; the right eye was normal, the left eye colour-blind; on being asked to pick out the red shades from a series of coloured worsteds with the right eye covered, he chose a full series of brown shades from dark to a light ochre. No family history given.]

174. Swanzy, H. R.: Case of Hemiachromatopsia. *Transactions, Ophthalmological Society of U. K.* Vol. iii, pp. 185—189. London, 1883.

175. Bickerton, T. H.: Colour-blindness. *British Medical Journal.* Vol. I for 1884, pp. 224, 225. London, 1884. See Fig. 562.

176. Donders, F. C.: Noch einmal die Farbensysteme. *Archiv f. Ophthalmologie.* Bd. xxx, Abth. I, S. 15—90. Berlin, 1884.

177. Donders, F. C.: Farbengleichungen. *Archiv f. Physiologie.* Supplement. S. 518—552. Leipzig, 1884.

178. Eperon: Hémiachromatopsie absolue. *Archives d'Ophtalmologie.* T. iv, pp. 356—370. Paris, 1884.

179. Graber, V.: *Grundlinien zur Erforschung des Helligkeits- und Farbensinnes der Tiere.* Leipzig, 1884.

180. Hilbert, R.: Beiträge zur Kenntniss der Farbenblindheit. *Archiv f. die gesammte Physiologie.* Bd. xxxiii, S. 293—296. Bonn, 1884. [No reference to the hereditary aspect of the subject.]

181. Hilbert, R.: Ueber eine eigenthümliche Ermüdungs-Erscheinung des nervösen Sehapparates und seine Beziehungen zur Erythropie. *Klinische Monatsblätter f. Augenheilkunde.* Bd. xxii, S. 403—409. Stuttgart, 1884.

182. Posada-Armigo, A.: Dyschromatopsie traumatique. *Recueil d'Ophtalmologie.* Série 3, T. vi, pp. 468—469. Paris, 1884.

183. Steinheim, B.: Contribution à l'Étude de l'Érythropsie. *Recueil d'Ophtalmologie.* Série 3, T. vi, pp. 210—212. Paris, 1884.

184. Berger, E.: Ein Fall von Erythropsie. *Centralblatt f. praktische Augenheilkunde.* Bd. ix, S. 140—141. Leipzig, 1885.

185. Dor, H.: Un cas de Chromatotyphlose ou Achromatopsie Complète. *Revue Générale d'Ophtalmologie.* T. iv, pp. 433—436. Paris, 1885. See Fig. 377.

186. Engelmann, T. W.: Ueber Bewegungen der Zapfen und Pigmentzellen der Netzhaut unter dem Einfluss des Lichtes und des Nervensystems. *Archiv f. d. gesammte Physiologie.* Bd. xxxv, S. 498—508. Bonn, 1885.

187. Govi, G.: *L' Ottica di Claudio Tolomeo; Ridotta in Latino sovra la traduzione Araba di un testo Greco imperfetto.* Torino, 1885.

188. Hilbert, R.: Ueber Xanthopie verursacht durch Pikrinsäure. *Centralblatt f. praktische Augenheilkunde.* Bd. ix, S. 70—71. Leipzig, 1885.

189. Hirschberg, J.: Ein Fall von Blausehen. *Centralblatt f. praktische Augenheilkunde.* Bd. ix, S. 141. Leipzig, 1885.

190. Hogg, J.: Colour-blindness in the Mercantile Marine. *British Medical Journal.* Vol. i for 1885, pp. 1151—1152. London, 1885. See Figs. 533, 573.

191. Hogg, J.: Homer Colour-Blind. *Journal of Science.* 3rd Series, Vol. vii, pp. 313—318. London, 1885.

192. Purtscher, O.: Weitere Beiträge zur Frage der Erythropsie. *Centralblatt f. praktische Augenheilkunde.* Bd. ix, S. 48—53, 72—80. Leipzig, 1885.

193. Szili, A.: Ueber Erythropsie. *Centralblatt f. praktische Augenheilkunde.* Bd. ix, S. 44—48. Leipzig, 1885.

194. Abney, W. de W. and Festing, E. R.: Colour Photometry. *Phil. Trans.* for 1886. Vol. 177, pp. 423—456. London, 1887.

195. *Brodhun, E.: *Beiträge zur Farbenlehre.* Dissertation. Berlin, 1887.

196. Dobrowolsky, W.: Ueber die Ursachen der Erythropsie. *Archiv f. Ophthalmologie.* Bd. xxxiii, Abth. ii, S. 213—228. Berlin, 1887.

197. Hering, E.: Ueber den Begriff "Urtheilstäuschung" in der physiologischen Optik und über die Wahrnehmung simultaner und successiver Helligkeitsunterschiede. *Archiv f. d. gesammte Physiologie.* Bd. xli, S. 91—106. Bonn, 1887.

198. Nettleship, E.: On some of the forms of congenital and infantile Amblyopia. *Royal London Ophthalmic Hospital Reports.* Vol. xi, pp. 353—399. London, 1887. See Figs. 369, 370, 372, 373.

199. Stort, A. G. H. van Genderen: Ueber Form- und Orts-veränderungen der Netzhautelemente unter Einfluss von Licht und Dunkel. *Archiv f. Ophthalmologie.* Bd. xxxiii, Abth. iii, S. 229—292. Berlin, 1887.

200. Charpentier, A.: *La Lumière et les Couleurs.* Paris, 1888.

201. Lubbock, J.: *On the Senses, Instincts, and Intelligence of Animals.* London, 1888.

202. Verrey: Hémiachromatopsie droite absolue.—Conservation partielle de la Perception Lumineuse et des Formes.—Ancien Kyste hémorrhagique de la partie inférieure du Lobe Occipital gauche. *Archives d'Ophtalmologie.* T. viii, pp. 289—300. Paris, 1888.

203. Abney, W. de W. and Festing, E. R.: Colour Photometry, Part ii. The measurement of Reflected Colours. *Phil. Trans.* A for 1888. Vol. 179, pp. 547—570. London, 1889.

204. Angelucci, A.: Recherches sur la Fonction Visuelle de la Rétine. *Recueil d'Ophtalmologie.* Sér. 3, T. xi, pp. 1—26, 201—225, 269—279, 332—343, 604—615, 660—676. Paris, 1889.

205. Hering, E.: Ueber die Hypothesen zur Erklärung der peripheren Farbenblindheit. *Archiv f. Ophthalmologie.* Bd. xxxv, Abth. iv, S. 63—83. Leipzig, 1889.

206. Hess, C.: Ueber den Farbensinn bei indirectem Sehen. *Archiv f. Ophthalmologie.* Bd. xxxv, Abth. iv, S. 1—62. Leipzig, 1889.

207. Hillebrand, F.: Ueber die specifische Helligkeit der Farben, Beiträge zur Psychologie der Gesichtsempfindungen. *Sitzungsberichte der kaiserlichen Akademie der Wissenschaften.* Bd. xcviii, Abth. ii *b*, S. 70—120. Wien, 1889.

208. Bulman, G. W.: On the supposed selective action of Bees on Flowers. *Zoologist.* Ser. iii, Vol. xiv, pp. 422—427. London, 1890. [Author concludes that the result of his few experiments is emphatically against the popular theory of the bee's selective action on flowers.]

209. Hering, E.: Zur Diagnostik der Farbenblindheit. *Archiv f. Ophthalmologie.* Bd. xxxvi, Abth. i, S. 217—233. Leipzig, 1890.

210. Hering, E.: Die Untersuchung einseitiger Störungen des Farbensinnes mittels binocularer Farbengleichungen. *Archiv f. Ophthalmologie.* Bd. xxxvi, Abth. iii, S. 1—23. Leipzig, 1890. [The case was pathological and not congenital, in a female who had atrophy of the optic nerve of the right eye only.]

211. Hess, C.: Untersuchung eines Falles von halbseitiger Farbensinnstörung am linken Auge. *Archiv f. Ophthalmologie.* Bd. xxxvi, Abth. iii, S. 24—36. Leipzig, 1890. [The case was not congenital and was in a man aged 31 years.]

212. Kreyssig, F.: Genuine, totale Farbenblindheit. *Mittheilungen aus der ophthalmiatrischen Klinik in Tübingen.* Bd. ii, S. 332—334. Tübingen, 1890.

213. Samelsohn: Hemiachromatopsie. *Berliner klinische Wochenschrift.* Bd. xxvii, S. 331. Berlin, 1890.

214. Abney, W. de W.: On the Examination for Colour of Cases of Tobacco Scotoma and of Abnormal Colour-Blindness. *Proc. Roy. Soc.* Vol. xlix, pp. 491—508. London, 1891.

215. Bickerton, T. H.: Colour-Blindness generally considered. *Nature.* Vol. xliv, pp. 595—597. London, 1891. [No reference to the hereditary nature of the defect.]

216. Hering, E.: Untersuchung eines total Farbenblinden. *Archiv f. d. gesammte Physiologie.* Bd. xlix, S. 563—608. Bonn, 1891. [A case is examined and fully described; some photophobia, no nystagmus, R.V. = L.V. = $\frac{6}{36}$, fundi normal. Father and two sisters had very good colour sense, no relations known to be colour-blind. In this paper Hering demonstrates the identity of the luminosity curves of the totally colour-blind and the dark-adapted normal eye.]

217. Landolt, E.: Un nouveau cas d'Achromatopsie totale. *Archives d'Ophtalmologie.* T. xi, pp. 202—206. Paris, 1891. See Fig. 396.

218. Querenghi, F.: Deux cas d'Achromatopsie totale. *Annales d'Oculistique.* T. cvi, pp. 333—338. Paris, 1891. [Describes two isolated cases associated with amblyopia, nystagmus and photophobia; in the first case, a female, the parents and also paternal grandparents were cousins.]

219. Schuster, A.: Experiments with Lord Rayleigh's Colour Box. *Proc. Roy. Soc.* Vol. xlviii, pp. 140—149. London, 1891. See Fig. 591.

220. Smith, J. Anderson: A case of Santonin poisoning. *British Medical Journal.* Vol. i for 1891, p. 1224. London, 1891.

221. Brodhun, E.: Über die Empfindlichkeit des grünblinden und des normalen Auges gegen Farbenänderung im Spektrum. *Zeitschrift f. Psychologie u. Physiologie der Sinnesorgane.* Bd. iii, S. 89—107. Leipzig, 1892.

222. Hunt, E.: *Color Vision.* Glasgow, 1892.

223. Pole, W.: Some unpublished data on Colour-Blindness. *Philosophical Magazine and Journal of Science.* Vol. xxxiv, 5th Series, pp. 100—114, 439—443. London, 1892.

224. Royal Society. Report of the Committee on Colour-Vision. *Proc. Roy. Soc.* Vol. li, pp. 280—396. London, 1892.

225. Snell, S.: On the importance of the examination of the eyes separately for defects of Colour Vision. *British Medical Journal.* Vol. i for 1892, pp. 222—223. London, 1892. [The author describes a case of green-blindness of the left eye in a little girl aged 11 whose right eye had normal colour vision; family history believed to be negative; a further case of red-blindness in the right eye and incomplete green-blindness in the left eye of a youth aged 21 is described.]

226. Abney, W. de W. and Festing, E. R.: Colour Photometry. *Phil. Trans.* A for 1892. Vol. 183, pp. 531—565. London, 1893.

227. Kirschmann, A.: Beiträge zur Kenntniss der Farbenblindheit. *Philosophische Studien.* Bd. viii, S. 173—230, 407—430. Leipzig, 1893. [This work is of special interest from its detailed account of unilateral anomaly in the colour vision of two brothers; other cases are fully described but no family histories are given.] See Fig. 564.

228. König, A. and Dieterici, C.: Die Grundempfindungen in normalen und anomalen Farbensystemen und ihre Intensitätsverteilung im Spektrum. *Zeitschrift f. Psychologie u. Physiologie der Sinnesorgane.* Bd. IV, S. 241—347. Leipzig, 1893.

229. Hering, E.: Ueber einen Fall von Gelb-blaublindheit. *Archiv f. die gesammte Physiologie.* Bd. LVII, S. 308—332. Bonn, 1894.

230. Panas, P.: *Traité des Maladies des Yeux.* Paris, 1894. [Case of total congenital Colour-blindness in a male, associated with nystagmus and amblyopia, described with few details in T. I, p. 201.]

231. Somya [, R.]: Zwei Fälle von Grünsehen. *Zeitschrift f. Psychologie u. Physiologie der Sinnesorgane.* Bd. VII, pp. 305—307. Leipzig, 1894.

232. Abney, W. de W.: *Colour Vision.* London, 1895.

233. Gates, E.: The Science of Mentation. *The Monist.* Vol. V, pp. 574—597. Chicago, 1895. [Some examination of the colour sense in dogs is described, pp. 583—587.]

234. Hering, E.: Ueber angebliche Blaublindheit der Zapfen-Sehzellen. *Archiv f. die gesammte Physiologie.* Bd. LXI, S. 106—112. Bonn, 1895.

235. Pole, W.: Data on the phenomena of Colour-blindness, chiefly derived from foreign sources. *Proceedings, Royal Society of Edinburgh.* Vol. XX, pp. 103—140. Edinburgh, 1895. See Fig. 449.

236. Pole, W.: On the present state of Knowledge and Opinion in regard to Colour-Blindness. *Transactions, Royal Society of Edinburgh.* Vol. XXXVII, pp. 441—479. Edinburgh, 1895.

237. Reber, W.: Six instances of colour-blind women occurring in two generations of one family. *Medical News.* Vol. LXVI, pp. 95—97. Philadelphia, 1895. See Fig. 429.

238. Cornish, C. J.: *Animals at Work and Play.* London, 1896.

239. Fick, A.: Zur Theorie der Farbenblindheit. *Archiv f. die gesammte Physiologie.* Bd. LXIV, S. 313—320. Bonn, 1896.

240. Snell, S.: Hereditary or Congenital Optic Atrophy and Allied Cases. *British Medical Journal.* Vol. II for 1896, p. 1231. London, 1896.

241. Colburn, J. E.: Congenital Nystagmus. *American Journal of Ophthalmology.* Vol. XIV, pp. 237—247. St Louis, Mo., 1897. See Fig. 384.

242. von Kries, J.: Ueber die dichromatischen Farbensysteme (partielle Farbenblindheit). *Centralblatt f. Physiologie.* Bd. X, S. 148—152. Leipzig, 1897.

243. von Kries, J.: Ueber das Sehen der total farbenblinden Netzhautzone. *Centralblatt f. Physiologie.* Bd. X, S. 745—749. Leipzig, 1897.

244. von Kries, J.: Über die Farbenblindheit der Netzhautperipherie. *Zeitschrift f. Psychologie u. Physiologie der Sinnesorgane.* Bd. XV, S. 247—279. Leipzig, 1897.

245. Peddie, W.: On a Case of Colour-Blindness. *Transactions, Royal Society of Edinburgh.* Vol. XXXVIII, pp. 501—508. Edinburgh, 1897.

246. Slonaker, J. R.: A comparative study of the area of acute vision in vertebrates. *Journal of Morphology.* Vol. XIII, pp. 445—502. Boston, 1897.

247. Abney, W. de W.: The Sensitiveness of the Retina to Light and Colour. *Phil. Trans.*, 1897. Vol. 190, A, pp. 155—195. London, 1898.

248. Fukala, V.: Ein Fall von seltener absoluter Farbenblindheit. *Klinische Monatsblätter f. Augenheilkunde.* Bd. XXXVI, S. 175—176. Stuttgart, 1898. [It is not clear that this case was congenital; the patient had some brain disease after birth, his vision was very bad up to the age of 10 or 11, but improved after this; vision was now 0·1 of the normal in the right, 0·05 in the left; the retinal vessels were narrowed in the region of the papilla; he had known no colours since childhood, slight photophobia was present.]

249. Hess, C. and Hering, E.: Untersuchungen an total Farbenblinden. *Archiv f. die gesammte Physiologie.* Bd. LXXI, S. 105—127. Bonn, 1898. See Fig. 379.

250. Hilbert, R.: Farbensehen als Influenza-Folge. *Klinische Monatsblätter f. Augenheilkunde.* Bd. XXXVI, S. 167—169. Stuttgart, 1898.

251. Patten, W.: A basis for a theory of Color Vision. *American Naturalist.* Vol. XXXII, pp. 833—857. Boston, 1898.

252. Pflüger, E.: Resultate der Untersuchung einer total Farbenblinden. *Klinische Monatsblätter f. Augenheilkunde.* Bd. XXXVI, S. 326—327. Stuttgart, 1898. See Fig. 374.

253. *Pflüger, E.: Demonstration eines Mannes mit vollständiger angeborener Farbenblindheit. *Internationaler Kongress Moskau.* p. 315, 1898. [Case is described by Grunert. See Bibl. No. 281.]

254. Wolffberg, L.: Totale Farbenblindheit; Kurze Bemerkung. *Wochenschrift f. Therapie u. Hygiene des Auges.* Bd. II, No. 15. Breslau, 1898.

255. Bulman, G. W.: Bees and the Origin of Flowers. *Natural Science.* Vol. XIII, pp. 128—130. London, 1899.

256. König, A.: Bemerkungen über angeborene totale Farbenblindheit. *Zeitschrift f. Psychologie u. Physiologie der Sinnesorgane.* Bd. XX, S. 425—434. Leipzig, 1899.

257. von Kries, J.: Ueber die anomalen trichromatischen Farbensysteme. *Zeitschrift f. Psychologie u. Physiologie der Sinnesorgane.* Bd. XIX, S. 63—69. Leipzig, 1899.

258. Mackay, G. and Dunlop, J. C.: The cerebral lesions in a case of complete acquired Colour-Blindness. *Scottish Medical and Surgical Journal.* Vol. V, pp. 503—512. Edinburgh, 1899.

259. Polimanti, O.: Ueber die sogenannte Flimmer-Photometrie. *Zeitschrift f. Psychologie u. Physiologie der Sinnesorgane.* Bd. XIX, S. 263—283. Leipzig, 1899.

260. Raehlmann, E.: Ueber relativen und absoluten Mangel des Farbensinnes. *Zeitschrift f. Augenheilkunde.* Bd. II for 1899, S. 315—340, 403—427. Berlin, 1899. See Fig. 383.

261. Uhthoff, W.: Ein Beitrag zur congenitalen totalen Farbenblindheit. *Zeitschrift f. Psychologie u. Physiologie der Sinnesorgane.* Bd. XX, S. 326—352. Leipzig, 1899.

262. Abney, W. de W.: A Case of Monochromatic Vision. *Proc. Roy. Soc.* Vol. LXVI, pp. 179—180. London, 1900. [Isolated case described in a male aged 25; nystagmus, day-blindness and probably an absolute central scotoma present; V.R. = V.L. = $\frac{6}{60}$. Luminosity curve given and compared with the normal.]

263. Burch, G. J.: On the relation of Artificial Colour-blindness to Successive Contrast. *Proc. Roy. Soc.* Vol. LXVI, pp. 204—216. London, 1900.

264. Burch, G. J.: On the Production of Artificial Colour-blindness by Moonlight. *Proc. Roy. Soc.* Vol. LXVI, pp. 216—219. London, 1900.

265. Greeff, R.: Die mikroskopische Anatomie des Sehnerven und der Netzhaut. *Graefe-Saemisch Handbuch der gesamten Augenheilkunde.* Aufl. 2, Bd. I, Kap. V, pp. 1—212. Leipzig, 1900.

266. Kirschmann, A.: Additional remarks on Colour-blindness. *University of Toronto Studies, Psychological Series.* Vol. I, pp. 97—100. Toronto, 1900. See Fig. 560.

267. Knies, M.: On the Color disturbance produced by Santonin in Normal and Color-Blind Eyes. *Archives of Ophthalmology.* Vol. XXIX, pp. 503—506. New York, 1900.

268. Knies, M.: On a frequent but hitherto unrecognised form of Congenital Violet-Blindness and on Colour Anomalies in general. *Archives of Ophthalmology.* Vol. XXIX, pp. 491—502. New York, 1900.

269. Knies, M.: The Chromoscope: a convenient instrument for studying the Colour Sense of the Macula Lutea and its Anomalies. *Archives of Ophthalmology.* Vol. XXIX, pp. 485—490. New York, 1900.

270. Burch, G. J.: On the Spectroscopic Examination of Colours produced by Simultaneous Contrast. *Proc. Roy. Soc.*, 1900. Vol. LXVII, pp. 226—228. London, 1901. [The author confirms Hering's statement that contrast phenomena originate in the eye rather than in the brain; he further demonstrates that the complementary colour to red does not consist of one simple colour-sensation; also that the colour which has green for its complementary is not itself spectroscopically simple.]

271. Johnson, G. L.: Contributions to the Comparative Anatomy of the Mammalian Eye, chiefly based on Ophthalmoscopic Examination. *Phil. Trans.* B. Vol. 194, pp. 1—82. London, 1901.

272. McDougall, W.: Some new Observations in support of Thomas Young's Theory of Light and Colour Vision. *Mind.* Vol. X, pp. 52—97, 210—245, 347—382. London, 1901.

273. Pearce, F. S.: Hereditary Sub-normal Color-Perception. *Journal of American Medical Association.* Vol. XXXVI, pp. 624—625. Chicago, 1901. See Fig. 522.

274. Hess, C.: Weitere Untersuchungen über totale Farbenblindheit. *Zeitschrift f. Psychologie u. Physiologie der Sinnesorgane.* Bd. XXIX, S. 99—117. Leipzig, 1902.

275. Kinnaman, A. J.: Mental life of two *Macacus rhesus* monkeys in captivity. *American Journal of Psychology.* Vol. XIII, pp. 98—148, 173—218. Worcester, Mass., 1902.

276. Nagel, W. A.: Einige Beobachtungen an einem Falle von totaler Farbenblindheit. *Archiv f. Augenheilkunde.* Bd. XLIV, S. 153—165. Wiesbaden, 1902.

277. Nagel, W. A.: Ueber die Wirkung des Santonins auf den Farbensinn, insbesondere den dichromatischen Farbensinn. *Zeitschrift f. Psychologie u. Physiologie der Sinnesorgane.* Bd. XXVII, S. 267—276. Leipzig, 1902.

278. Pergens, E.: Erworbene Achromatopsie mit voller Sehschärfe. *Klinische Monatsblätter f. Augenheilkunde.* Bd. xlii, S. 46—48. Stuttgart, 1902. [A case of total colour-blindness occurring after typhus; the spectrum was unshortened with maximum brightness in the yellow region; the patient died several years later and microscopic examination showed an entirely normal retina, also the fibres of the stump of the optic nerve were normal. The achromatopsy had remained unchanged up to the time of death.]

279. Uhthoff, W.: Ein weiterer Beitrag zur angeborenen total Farbenblindheit. *Zeitschrift f. Psychologie u. Physiologie der Sinnesorgane.* Bd. xxvii, S. 344—360. Leipzig, 1902. See Figs. 381, 394.

280. Alter, W.: Monochromatopsie und Farbenblindheit. *Neurologisches Centralblatt.* Bd. xxii, S. 290—296. Leipzig, 1903.

281. Grunert, K.: Über angeborene totale Farbenblindheit. *Archiv f. Ophthalmologie.* Bd. lvi, S. 132—195. Leipzig, 1903. See Figs. 376, 380, 391.

282. König, A.: *Gesammelte Abhandlungen zur physiologischen Optik.* Leipzig, 1903.

283. König, A. und Ritter, R.: Ueber den Helligkeitswerth der Spectralfarben bei verschiedener absoluter Intensität. *König's Abhandlungen zur physiologischen Optik.* S. 144—213. Leipzig, 1903.

284. *Bjerrum, J.: Et Tilfaelde af medfödt total Farveblindhed med Bemaerkninger om Stav- og Tapfunktion. *Hospitalstidende.* Bd. xii, pp. 1145—1148. Kjøbenhavn, 1904. [Notes of case taken from *Jahresbericht der Ophthalmologie.* Bd. xxxv, S. 205—207. Tübingen, 1905.] See Fig. 398.

285. Torelle, E.: The Response of the Frog to Light. *American Journal of Physiology.* Vol. ix, pp. 466—488. Boston, 1903.

286. Gotch, F.: The Time-Relations of the Photo-Electric Changes produced in the Eyeball of the Frog by means of Coloured Light. *Journal of Physiology.* Vol. xxxi, pp. 1—29. London, 1904.

287. Groenouw, A.: Erbliche Farbenblindheit. *Graefe-Saemisch Handbuch der gesamten Augenheilkunde.* Bd. xi, Abt. i, S. 479—483. Leipzig, 1904. See Fig. 545.

288. Hesse, R.: Über den feineren Bau der Stäbchen und Zapfen einiger Wirbeltiere. *Zoologische Jahrbücher.* Supplement. Bd. vii, S. 472—518. Jena, 1904.

289. Porter, J. P.: A Preliminary Study of the Psychology of the English Sparrow. *American Journal of Psychology.* Vol. xv, pp. 313—346. Worcester, Mass., 1904. [Colour discrimination considered, pp. 337—339.]

290. Trendelenburg, W.: Quantitative Untersuchungen über die Bleichung des Sehpurpurs in monochromatischem Licht. *Zeitschrift f. Psychologie u. Physiologie der Sinnesorgane.* Bd. xxxvii, S. 1—55. Leipzig, 1904.

291. *Wehrli, E.: Ueber hochgradig herabgesetzten Farbensinn. *Mitteilungen d. Thurgauischen naturforschenden Gesellschaft.* Bd. xv. [Notes of case taken from *Jahresbericht der Ophthalmologie.* Bd. xxxiv, S. 92. Tübingen, 1904.]

292. Wery, J.: Quelques expériences sur l'attraction des Abeilles par les fleurs. *Bulletins de l'Académie Royale de Belgique. Classe des Sciences,* 1904, pp. 1211—1261. Bruxelles, 1904.

293. Hering, E.: Grundzüge der Lehre vom Lichtsinn. *Graefe-Saemisch Handbuch der gesamten Augenheilkunde.* Th. i, Bd. iii, Kap. xii, 1905.

294. Kerry, R.: A case of Acromegaly. *Ophthalmic Review.* Vol. xxiv, pp. 193—199. London, 1905.

295. McDougall, W.: The Sensations excited by a single momentary Stimulation of the Eye. *British Journal of Psychology.* Vol. i, pp. 78—113. Cambridge, 1905.

296. McDougall, W.: The Illusion of the "Fluttering Heart" and the Visual Functions of the Rods of the Retina. *British Journal of Psychology.* Vol. i, pp. 428—434. Cambridge, 1905.

297. Piper, H.: Beobachtungen an einem Fall von totaler Farbenblindheit des Netzhautzentrums im einen und von Violettblindheit des anderen Auges. *Zeitschrift f. Psychologie u. Physiologie der Sinnesorgane.* Bd. xxxviii, S. 155—188. Leipzig, 1905. [A full description of the case is given; family history not referred to.]

298. Rivers, W. H. R.: Observations on the Senses of the Todas. *British Journal of Psychology.* Vol. i, pp. 321—396. Cambridge, 1905. [Colour vision is discussed, pp. 326—339.] See Fig. 425. Pedigree taken from Bateson in *Mendel's Principles of Heredity,* p. 223. Cambridge, 1909.

299. Beare, J. I.: *Greek Theories of Elementary Cognition from Alcmaeon to Aristotle.* Oxford, 1906.

300. Kallius, E.: Sehapparat. *Ergebnisse der Anatomie und Entwicklungsgeschichte.* Bd. xvi, S. 746—793. Wiesbaden, 1906.

301. Nettleship, E.: Note on some varieties of Albinism. *Transactions, Ophthalmological Society of U.K.* Vol. xxvi, pp. 244—250. London, 1906.

302. Nettleship, E.: Cases of colour-blindness in women. *Transactions, Ophthalmological Society of U.K.* Vol. xxvi, pp. 251—257. London, 1906. See Figs. 433, 498, 558, 567, 568.

303. Plateau, F.: Les Fleurs Artificielles et les Insectes. *Mémoires, Académie Royale de Belgique, Classe des Sciences.* Série II, T. I, pp. 1—101. Bruxelles, 1906.

304. Porter, J. P.: Further study of the English Sparrow and other Birds. *American Journal of Psychology.* Vol. XVII, pp. 248—271. Worcester, Mass., 1906. [Colour discrimination considered, pp. 265—266.]

305. Rönne, H.: Fälle von angeborener totaler Farbenblindheit. *Klinische Monatsblätter f. Augenheilkunde, Beilageheft zum Bd. xliv.* S. 193—206. Stuttgart, 1906. See Fig. 387.

306. Whitaker, A.: The Development of the Senses in Bats. *Naturalist.* Vol. for 1906, pp. 145—151. London, 1906.

307. Fritsch, G.: Vergleichende Untersuchungen der Fovea Centralis des Menschen. *Anatomischer Anzeiger.* Bd. XXX, S. 462—4. Jena, 1907.

308. Hess, C.: Ueber Dunkeladaptation und Sehpurpur bei Hühnern und Tauben. *Archiv f. Augenheilkunde.* Bd. LVII, S. 298—316. Wiesbaden, 1907.

309. Hess, C.: Untersuchungen über Lichtsinn und Farbensinn der Tagvögel. *Archiv f. Augenheilkunde.* Bd. LVII, S. 317—327. Wiesbaden, 1907.

310. Nagel, W. A.: Eine Dichromatenfamilie. *Zeitschrift f. Psychologie u. Physiologie der Sinnesorgane.* Bd. XLI, Abt. II, S. 154—156. Leipzig, 1907. See Figs. 447, 551, 552, 571.

311. Nagel, W. A.: Der Farbensinn des Hundes. *Zentralblatt f. Physiologie.* Bd. XXI, S. 205—206. Leipzig, 1907.

312. Parker, F. J.: Chinin-Amaurosis mit Bericht über einen Fall. *Archiv f. Augenheilkunde.* Bd. LVI, S. 193—197. Wiesbaden, 1907.

313. Samojloff, A. und Pheophilaktowa, A.: Über die Farbenwahrnehmung beim Hunde. *Zentralblatt f. Physiologie.* Bd. XXI, S. 133—139. Leipzig, 1907.

314. Samojloff, A.: Ein Fall von ungewöhnlicher Verschiedenheit der Mischungsgleichungen für beide Augen eines Beobachters. *Zeitschrift f. Sinnesphysiologie.* Bd. XLI, S. 367—372. Leipzig, 1907.

315. Vaughan, C. L.: Einige Bemerkungen über die Wirkung von Santonin auf die Farbenempfindungen. *Zeitschrift f. Sinnesphysiologie.* Bd. XLI, S. 399—407. Leipzig, 1907.

316. Yerkes, R. M.: *The Dancing Mouse.* New York, 1907. [An account of experiments to test the Colour Sense of the Dancing Mouse is described, pp. 133—177.]

317. Edridge-Green, F. W.: Colour Vision and its Anomalies. *British Medical Journal.* Vol. II for 1908, pp. 741—744. London, 1908.

318. Guttmann, A.: Untersuchungen über Farbenschwäche. *Zeitschrift f. Sinnesphysiologie.* Bd. XLII, S. 24—64, 250—270; Bd. XLIII, S. 146—162, 199—223, 255—296. Leipzig, 1908, 1909. See Figs. 596, 599.

319. Hilbert, R.: Ueber Störungen des Farbensinnes im Gefolge interner Erkrankungen. *Klinische Monatsblätter f. Augenheilkunde.* Bd. XLVI, S. 256—261. Stuttgart, 1908.

320. Köllner, H.: Erworbene Violettblindheit (Tritanopie) und ihr Verhalten gegenüber spektralen Mischungsgleichungen. (Rayleigh-Gleichung). *Zeitschrift f. Sinnesphysiologie.* Bd. XLII, S. 281—296. Leipzig, 1908.

321. Köllner, H.: Unvollkommene Farbenblindheit bei Sehnerverkrankung. *Zeitschrift f. Sinnesphysiologie.* Bd. XLII, S. 15—23. Leipzig, 1908.

322. McDougall, W.: An Investigation of the Colour Sense of two Infants. *British Journal of Psychology.* Vol. II, pp. 328—352. Cambridge, 1908.

323. May, B.: Ein Fall totaler Farbenblindheit. *Zeitschrift f. Psychologie u. Physiologie der Sinnesorgane.* Bd. XLII, Abt. II, S. 69—82. Leipzig, 1908.

324. Myers, C. S.: Some observations on the Development of the Colour Sense. *British Journal of Psychology.* Vol. II, pp. 353—362. Cambridge, 1908.

325. Nagel, W.: Erwiderung an Herrn Sivén betreffs Santonin-Einwirkung im Auge. *Zeitschrift f. Sinnesphysiologie.* Bd. XLII, S. 297—298. Leipzig, 1908.

326. Nettleship, E.: Three new pedigrees of eye disease. *Transactions, Ophthalmological Society of U. K.* Vol. XXVIII, pp. 220—249. London, 1908. See Fig. 411.

327. Siven, V. O.: Einige Bemerkungen über die Wirkung von Santonin auf die Farbenempfindungen. *Zeitschrift f. Sinnesphysiologie.* Bd. XLII, S. 224—228. Leipzig, 1908.

328. Behr, C.: Zur topischen Diagnose der Hemianopsie. *Archiv f. Ophthalmologie.* Bd. LXX, S. 340—402. Leipzig, 1909.

329. Burd, C. P.: Colour-blindness. *British Medical Journal.* Vol. II for 1909, p. 1717. London, 1909. See Fig. 454.

330. Cole, L. W. and Long, F. M.: Visual Discrimination in Raccoons. *Journal of Comparative Neurology and Psychology.* Vol. xix, pp. 657—683. Philadelphia, Pa., 1909.

331. Edridge-Green, F. W.: *Colour-Blindness and Colour Perception.* London, 1909.

332. von Helmholtz, H.: *Handbuch der physiologischen Optik.* Dritte Auflage. Leipzig, 1909—1911.

333. Hess, C.: Untersuchungen über den Lichtsinn bei Fischen. *Archiv f. Augenheilkunde.* Bd. lxiv, S. 1—38. Wiesbaden, 1909.

334. Hess, C.: Untersuchungen über den Lichtsinn bei wirbellosen Thieren. *Archiv f. Augenheilkunde.* Bd. lxiv, S. 39—61. Wiesbaden, 1909.

335. Hessberg, R.: Ein Beitrag zur angeborenen totalen Farbenblindheit. *Klinische Monatsblätter f. Augenheilkunde.* Bd. xlvii, S. 129—138. Stuttgart, 1909. See Fig. 389.

336. Merzbacher, L.: Gesetzmässigkeiten in der Verbreitung verschiedener hereditär-familiärer Erkrankungen. *Archiv f. Rassen- und Gesellschafts-Biologie.* Bd. vi, S. 172—198. Leipzig, 1909

337. Nettleship, E.: Some Hereditary Diseases of the Eye. *Transactions, Ophthalmological Society of U.K.* Vol. xxix, pp. lvii—cxcviii. London, 1909. [Colour vision is discussed, pp. cxxviii—cxxxi.] See Figs. 368, 371, 372, 392.

338. Watson, J. B.: Some experiments bearing upon Colour Vision in Monkeys. *Journal of Comparative Neurology and Psychology.* Vol. xix, pp. 1—28. Philadelphia, Pa., 1909.

339. Yamaguchi, H.: Ein Fall von Xanthopsie bei Schwangerschaftsnephritis. *Klinische Monatsblätter f. Augenheilkunde.* Bd. xlvii, S. 160—161. Stuttgart, 1909.

340. Galloway, A. R.: The Board of Trade Sight Tests. *British Medical Journal.* Vol. i for 1910, pp. 915, 916. London, 1910. [Describes twelve cases illustrating the unsatisfactory nature of the Holmgren wool test for colour-blindness.] See Fig. 553.

341. Greenwood, M.: *Physiology of the Special Senses.* London, 1910.

342. Hess, C.: Untersuchungen über den Lichtsinn bei Reptilien und Amphibien. *Pflüger's Archiv f. d. gesamte Physiologie.* Bd. cxxxii, S. 255—295. Bonn, 1910.

343. Hess, C.: Über den angeblichen Nachweis von Farbensinn bei Fischen. *Pflüger's Archiv f. d. gesamte Physiologie.* Bd. cxxxiv, S. 1—14. Bonn, 1910.

344. Juler, F. A.: Congenital total Colour-Blindness with Day Blindness. *Ophthalmic Review.* Vol. xxix, pp. 65—71. London, 1910. See Fig. 378.

345. Winch, W. H.: Colour Preferences of School Children. *British Journal of Psychology.* Vol. iii, pp. 42—65. Cambridge, 1910.

346. Abney, W. de W. Colour-Blindness and the Trichromatic Theory of Colour Vision. Part ii. Incomplete Red or Green Blindness. *Proc. Roy. Soc.*, 1910. Vol. lxxxiv, pp. 449—464. London, 1911.

347. Hayes, S. P. The color sensations of the partially color-blind, a criticism of current teaching. *American Journal of Psychology.* Vol. xxii, pp. 369—407. Worcester, Mass., 1911. See Fig. 574.

348. Kümmell, R.: Zur Kenntnis der Geschwülste der Hypophysengegend. *Münchener medizinische Wochenschrift.* Bd. lviii, S. 1293—1298. München, 1911.

349. Lutz, A.: Über einige Stammbäume und die Anwendung der Mendelschen Regeln auf die Ophthalmologie. *Archiv f. Ophthalmologie.* Bd. lxxix, S. 393—427. Leipzig, 1911. See Fig. 426.

350. Rayleigh, Lord: On the Sensibility of the Eye to Variations of Wave-length in the Yellow Region of the Spectrum. *Proc. Roy. Soc.* A, 1910. Vol. lxxxiv, pp. 464—468. London, 1911.

351. Davenport, C. B.: The inheritance of physical and mental traits of man and their practical application to eugenics. *Heredity and Eugenics.* Ch. viii. Chicago, 1912. See Fig. 528.

352. Gertz, H.: Einige Bemerkungen über das zentrale Sehen bei der angeborenen totalen Farbenblindheit und ein Beitrag zur Diagnostik der Zentralskotome. *Archiv f. Augenheilkunde.* Bd. lxx, S. 202—227. Wiesbaden, 1912.

353. Gertz, H.: Ein Fall von angeborener totaler Farbenblindheit. *Archiv f. Augenheilkunde.* Bd. lxx, S. 228—234. Wiesbaden, 1912. See Fig. 397.

354. Hess, C.: *Vergleichende Physiologie des Gesichtssinnes.* Jena, 1912.

355. Nettleship, E.: Some unusual pedigrees of Colour-blindness. *Transactions, Ophthalmological Society of U.K.* Vol. xxxii, pp. 309—336. London, 1912. See Figs. 434, 439, 441, 569.

356. Tucker, A. W.: Observations on the Colour Vision of School Children. *British Journal of Psychology.* Vol. iv, pp. 33—43. Cambridge, 1912.

357. Usher, C. H.: A Pedigree of Colour-blindness. *Transactions, Ophthalmological Society of U.K.* Vol. xxxii, pp. 352—361. London, 1912. See Fig. 408.

358. Wilson, J. A.: Colour-Sensation. *Ophthalmoscope.* Vol. x, p. 142. London, 1912.

359. Cantonnet, A.: Achromatopsie congénitale totale. *Archives d'Ophtalmologie.* T. xxxiii, pp. 289—291. Paris, 1913. [Describes isolated case in a male aged 20 associated with no other congenital anomaly mental or physical; parents not related, family history negative. The condition was associated with nystagmus, photophobia and with diminished visual acuity; fields were normal for white and showed no central scotomata. Case examined twice with interval of six years in which time no change had occurred.]

360. *Elschnig: *Bericht über die neununddreissigste Versammlung der ophthalmologischen Gesellschaft.* S. 8. Heidelberg, 1913.

361. Franz, V.: Sehorgan. *Lehrbuch der vergleichenden mikroskopischen Anatomie der Wirbeltiere.* Herausgegeben von Prof. Dr Albert Oppel. Bd. vii. Jena, 1913.

362. Ichikawa, K.: Ueber den ophthalmoskopischen Befund der Area centralis des albinotischen Auges. *Klinische Monatsblätter f. Augenheilkunde.* Bd. li, S. 9—15. Stuttgart, 1913.

363. Jerchel, W.: Inwieweit wird das Medizinstudium durch "Rot-grünblindheit" beeinflusst? *Zeitschrift f. Psychologie u. Physiologie der Sinnesorgane.* Bd. xlvii, Abt. ii, S. 1—33. Leipzig, 1913. See Fig. 432.

364. Pearson, K., Nettleship, E. N., and Usher, C. H.: *A Monograph on Albinism in Man.* Part ii. London, 1913.

365. Smith, E. M.: Some Observations concerning Colour Vision in Dogs. *British Journal of Psychology.* Vol. v, pp. 119—202. Cambridge, 1913.

366. Gunn, Rugg: Discussion on Nystagmus. *Proc. Royal Society of Medicine, Sect. of Neurology, Ophthalmology and Otology.* Vol. vii, Part ii, p. lxxx. London, 1914.

367. Nettleship, E.: A Pedigree of Colour-blindness including two colour-blind females. *Royal London Ophthalmic Hospital Reports.* Vol. xix, pp. 319—327. London, 1914. See Fig. 409.

368. Valentine, C. W.: The Colour Perception and Colour Preferences of an infant during its fourth and eighth months. *British Journal of Psychology.* Vol. vi, pp. 363—386. Cambridge, 1913—1914.

369. Hegner, C. A.: Ueber angeborene einseitige Störungen des Farbensinns. *Klinische Monatsblätter f. Augenheilkunde.* Bd. liv, S. 81—89. Stuttgart, 1915.

370. Nettleship, E.: Pedigrees of Colour-blindness. *Royal London Ophthalmic Hospital Reports.* Vol. xx, Part i, pp. 93—107. London, 1915. See Figs. 406, 407, 494.

371. Parsons, J. H.: *An Introduction to the Study of Colour Vision.* Cambridge, 1915.

371a. Wilbrand, H. and Saenger, A.: *Die Neurologie des Auges.* Bd. vi. Wiesbaden, 1915.

372. Göthlin, G. F.: Några Resultat av en Släktforskning angående "Fargblindhet." *Psyke.* Meddelande från Institutet för Psykologisk Forskning, No. 7. Uppsala, 1916. See Figs. 511, 512, 526, 527, 593, 598.

373. Houstoun, R. A.: A Theory of Colour Vision. *Proc. Roy. Soc.* A. Vol. xcii, pp. 424—432. London, 1916.

374. Landolt, E.: Le Syndrome "Achromatopsie Totale." *Annales de Médecine.* T. iii, pp. 498—503. Paris, 1916.

375. Reichert, F.: *Ueber einseitige Farbensinn-Anomalien.* Dissertation. Freiburg, 1916.

376. Affolter, A.: Ophthalmoskopische Untersuchungen in rotfreiem Licht. *Archiv f. Ophthalmologie.* Bd. xciv, S. 1—27. Berlin, 1917.

377. *American Encyclopedia and Dictionary of Ophthalmology.* Vol. xi. Chicago, 1917. [Article on History of Ophthalmology.]

378. Ferree, C. E. and Rand, G.: Some areas of Color-Blindness of an unusual type in the Peripheral Retina. *Journal of Experimental Psychology.* Vol. ii, pp. 295—303. Princeton, N.J., 1917.

379. Hess, C.: Der Farbensinn der Vögel und die Lehre von den Schmuckfarben. *Pflüger's Archiv f. d. gesamte Physiologie.* Bd. clxvi, S. 381—426. Bonn, 1917.

380. Houstoun, R. A.: A Theory of Colour Vision. *Science Progress.* Vol. xi, ii, pp. 377—388. London, 1917.

381. Wood, Casey A.: *The Fundus Oculi of Birds, especially as viewed by the Ophthalmoscope.* Chicago, 1917.

382. Hess, C.: Beiträge zur Frage nach einem Farbensinne bei Bienen. *Pflüger's Archiv f. d. gesamte Physiologie.* Bd. CLXX, S. 337—366. Bonn, 1918.

383. Mottram, J. C. and Edridge-Green, F. W.: Some aspects of Animal Colouration from the point of view of Colour Vision. *Science Progress.* Vol. XIII, i, pp. 65—78, 253—264. London, 1918.

384. Uhlenhuth, E.: The influence of Function upon the Structure of the Eye. *Archives of Ophthalmology.* Vol. XLVII, pp. 401—403. New York, 1918.

385. Wernicke, O.: Total Achromatopsia. *Archives of Ophthalmology.* Vol. XLVII, pp. 302—304. New York, 1918. See Fig. 367.

386. von Kries, J.: Über einen Fall von einseitiger angeborener Deuteranomalie (Grünschwäche). *Zeitschrift f. Sinnesphysiologie.* Bd. I, S. 137—152. Leipzig, 1919.

387. Edridge-Green, F. W.: *The Physiology of Vision with special reference to Colour-Blindness.* London, 1920.

388. Edridge-Green, F. W.: The Theory of Vision. *British Journal of Ophthalmology.* Vol. IV, pp. 409—412. London, 1920.

389. Ferree, C. E. and Rand, G.: The absolute limits of Color Sensitivity and the effect of intensity of light on the apparent limits. *Psychological Review.* Vol. XXVII, pp. 1—23. Princeton, N.J., 1920.

390. Hartridge, H.: Vision. *Starling's Principles of Human Physiology.* pp. 486—594. London, 1920.

391. Parsons, J. H.: Dr Edridge-Green's Theories of Vision. *British Journal of Ophthalmology.* Vol. IV, pp. 322—331, 359—367, 403—409. London, 1920.

392. Schiötz, I.: Colour-Blind Females: The Inheritance of Colour-Blindness in Man. *British Journal of Ophthalmology.* Vol. IV, pp. 345—359, 393—403. London, 1920.

393. Sheppard, H.: Foveal adaptation to Color. *American Journal of Psychology.* Vol. XXXI, pp. 34—58. Worcester, Mass., 1920.

394. Döderlein, G.: Über die Vererbung von Farbensinnstörungen. *Archiv f. Augenheilkunde.* Bd. XC, S. 43—66. München, 1921. See Fig. 600.

395. Ferree, C. E. and Rand, G.: The variable Factors which influence the Determination of the Color Fields. *Archives of Ophthalmology.* Vol. L, pp. 357—359. New York, 1921.

396. Hartridge, H.: The avoidance of objects by Bats in their flight. *Journal of Physiology.* Vol. LIV, pp. 54—57. London, 1921.

397. von Hess, C.: Die relative Rotsichtigkeit und Grünsichtigkeit. *Archiv f. Ophthalmologie.* Bd. CV, S. 137—153. Berlin, 1921. See Figs. 565, 592, 594, 595.

398. Honigmann, H.: Untersuchungen über Lichtempfindlichkeit und Adaptierung des Vogelauges. *Pflüger's Archiv f. d. gesamte Physiologie.* Bd. CLXXXIX, S. 1—72. Berlin, 1921.

399. Larsen, H.: Demonstration mikroskopischer Präparate von einem monochromatischen Auge. *Zeitschrift f. Augenheilkunde.* Bd. XLVI, S. 228. Berlin, 1921.

400. Lenz, G.: Zwei Sektionsfälle doppelseitiger zentraler Farbenhemianopsie. *Zeitschrift f. die gesamte Neurologie u. Psychiatrie.* Bd. LXXI, S. 135—186. Berlin, 1921.

401. Parsons, J. H.: The Evolution of visual Perceptions. *Transactions, Ophthalmological Society of U.K.* Vol. XLI, pp. 97—112. London, 1921.

402. Schanz, F.: Das Sehen der Farben. *Zeitschrift f. Augenheilkunde.* Bd. XLVI, S. 311—316. Berlin, 1921.

403. Usher, C. H.: Histological examination of an adult human Albino's eyeball, with a note on mesoblastic pigmentation in Foetal eyes. *Biometrika.* Vol. XIII, pp. 46—56. Cambridge, 1921.

404. Bollack, M. J.: Hémiachromatopsie bitemporale et Scotome maculaire bitemporal par lésion de la région Hypophysaire. *Revue Neurologique.* Bd. XXXVIII, pp. 966—971. Paris, 1922.

405. Bowditch, H.: Red-Green Color-Blindness in three allied Families. *Journal of Heredity.* Vol. XIII, pp. 139—142. Washington, 1922. See Fig. 580.

406. Houstoun, R. A.: An Investigation of the Colour Vision of 527 Students by the Rayleigh Test. *Proc. Roy. Soc.* A. Vol. CII, pp. 353—360. London, 1922.

407. Johnson, G. L.: *Photography in Colour.* London, 1922. [pp. 51, 52 describe gradual loss of colour vision in one eye associated with a form of creeping paralysis; Abney (Bibl. No. 214), who examined the case, reports that the patient had had a slight stroke leading to paralysis which affected her left side and that she had optic atrophy in the colour-blind eye.]

408. Schiötz, I.: Rotgrünblindheit als Erbeigenschaft. *Klinische Monatsblätter f. Augenheilkunde.* Bd. LXVIII, S. 498—526. Stuttgart, 1922. See Figs. 410, 417, 419, 435, 437, 450, 514, 575, 587.

409. Vogt, A. and Klainguti, R.: Weitere Untersuchungen über die Entstehung der Rotgrünblindheit beim Weibe. *Archiv f. Rassen- u. Gesellschafts-Biologie.* Bd. xiv, S. 129—140. München, 1922. See Figs. 436, 438, 446, 566, 577, 585.

410. Vogt, A.: Ueber geschlechtsgebundene Vererbung von Augenleiden. *Schweizerische medizinische Wochenschrift.* Bd. lii, S. 77—83. Basel, 1922. See Figs. 446, 577.

411. Engelking, E.: Über den Nystagmus bei der angeborenen totalen Farbenblindheit. *Archiv f. d. gesamte Physiologie.* Bd. cci, S. 220—234. Berlin, 1923.

412. Ferree, C. E. and Rand, G.: The effect of intensity of stimulus on the size and shape of the color fields and their order of ranking as to breadth. *American Journal of Ophthalmology.* Vol. vi, Ser. 3, pp. 453—460. Chicago, 1923.

413. Klainguti, R.: Farbensinnstörung bei Retinitis pigmentosa und totale Farbenblindheit. *Schweizerische medizinische Wochenschrift.* Bd. liii, S. 910—912. Basel, 1923. See Fig. 588.

414. Kohlrausch, A.: Über den Helligkeitsvergleich verschiedener Farben. *Pflüger's Archiv f. d. gesamte Physiologie.* Bd. cc, S. 210—215. Berlin, 1923.

415. Kohlrausch, A.: Theoretisches und Praktisches zur heterochromen Photometrie. *Archiv f. d. gesamte Physiologie.* Bd. cc, S. 216—220. Berlin, 1923.

416. von Kries, J.: Zur physiologischen Farbenlehre. *Klinische Monatsblätter f. Augenheilkunde.* Bd. lxx, S. 577—629. Stuttgart, 1923.

417. Nabours, R. K.: The Limitations and Promises of Eugenics. *Journal of Heredity.* Vol. xiv, pp. 277—288. Washington, 1923. See Fig. 443.

418. Richardson-Robinson, F.: A case of Color-Blindness to yellow and blue. *American Journal of Psychology.* Vol. xxxiv, pp. 157—184. New York, 1923.

419. Vogt, A.: Ueber Vererbung von Augenleiden. *Schweizerische medizinische Wochenschrift.* Bd. liii, S. 161—165, 188—193. Basel, 1923.

420. Wölfflin, E.: Über das Vererbungsgesetz der anomalen Trichromaten. *Pflüger's Archiv f. d. gesamte Physiologie.* Bd. cci, S. 214—219. Berlin, 1923. See Figs. 597, 601.

421. Göthlin, G. F: Congenital Red-Green Abnormality in Colour Vision, and Congenital Total Colour-Blindness from the point of view of Heredity. *Saertryk af Acta Ophthalmologica.* Kjøbenhavn, 1924. See Figs. 400, 403, 513.

422. Waardenburg, P. J.: Een Geval van volledige Kleurenblindheid. *Nederlandsch Tijdschrift voor Geneeskunde.* Bd. lxviii, S. 1249—1251. Haarlem, 1924. See Figs. 402, 405.

423. Wölfflin, E.: Ueber angeborene totale Farbenblindheit. *Klinische Monatsblätter f. Augenheilkunde.* Bd. lxxii, S. 1—8. Stuttgart, 1924.

424. Oguchi, C.: Zur Anatomie der sog. Oguchischen Krankheit. *Archiv f. Ophthalmologie.* Bd. cxv, S. 234—245. Berlin, 1925.

425. Just, G.: Zur Vererbung der Farbensinnstufen beim Menschen. *Archiv f. Augenheilkunde.* Bd. xcvi, S. 406—418. München, 1925.

DESCRIPTIONS OF PEDIGREE PLATES

Plate XXVII. Fig. 367. *Wernicke's Case.* Total colour-blindness in two brothers of a sibship of seven; the condition was associated with photophobia and with nystagmus; pupils reacted well to light and accommodation; fundi normal; for elder brother R.V. = $\frac{1}{10}$; L.V. = $\frac{2}{10}$; for younger brother R.V. = L.V. = $\frac{1}{10}$; red was mistaken for black; vision was said to improve at dusk. No consanguinity. (See Bibl. No. 385.)

Fig. 368. *Nettleship and Holmes Spicer's Case.* Total colour-blindness associated with day-blindness and nystagmus in three males of a sibship of nine, the second, fifth and sixth born; one brother and four sisters had normal vision; one sister died in infancy. The father of the sibship "probably had the same disease." No consanguinity recorded. (See Bibl. No. 337, p. cxxxi.)

Fig. 369. *Nettleship's Case.* Total colour-blindness associated with day-blindness and moderate amblyopia in two sisters; they saw about $\frac{20}{70}$ with their hypermetropia of about 3 D. corrected; no definite ophthalmoscopic changes; irides grey-blue and hair auburn; their health was good. Their only brother II. 1 saw well and their two sisters II. 4 and 5 were believed to see well, they were however less than seven years of age and were not seen by the author. The parents were first cousins; no similar defects were known in other branches of the family. Consanguinity. (See Bibl. No. 198, Case xxvii.)

Fig. 370. *Nettleship's Case.* Total colour-blindness associated with photophobia and amblyopia in a brother and sister. II. 1, a fairly intelligent labourer from Wales said that he disliked bright light and saw better in winter than in summer, and that his sight had never been better than it was at the time of examination; he was found to have hypermetropia of 3 D. in R. and 4 D. in L.; R.V. = L.V. = $\frac{6}{24}$, he was wearing + 5 D.; fundi were normal excepting a doubtful congestion of the discs; he was aware that

he could not distinguish colours as other people could and it was found that he judged almost entirely by shade, all pale colours being "white" and all dark colours "black"; he was ready to match green with nearly all other colours; blue was the only colour he promptly picked out by name, but even this colour was often confused with several others, including yellow. One of his sisters was reported to have eyes "exactly the same as" II. 1 and to wear the same glasses; three other sisters and two brothers all saw well and without glasses. Enquiries were made concerning other relatives, but no similar defect was known to have occurred in other members of the family. No consanguinity. (See Bibl. No. 198, Case xxviii.)

Fig. 371. *Nettleship's Case.* Colour-blindness was associated with day-blindness and nystagmus in two and probably three members of a sibship of eight. II. 2 was examined and the condition was found to be typical; his elder brother was said to be similarly affected and his youngest sister, II. 8, aged 2 years, was thought to have the same defect; two brothers and three sisters were normal. No consanguinity. (See Bibl. No. 337, p. cxcii.)

Fig. 372. *Nettleship's Case.* Colour-blindness associated with nystagmus and defective vision in two sisters of a sibship of four; one sister and one brother were normal. The parents were first cousins. II. 1 was operated on for cataract of the L. eye "six years ago"; R.V. then and now $= \frac{6}{24}$ badly, with -2 D.; fundi were normal; nystagmus was present; she disliked sunlight and saw better in the dusk; she was bright and observant and was anxious not to appear colour-blind, but she half confused grey with green, mauve with purple and scarlet with dark brown; she almost matched light violet with various yellows; asked to pick out the yellows, she had no idea of them though she managed after much hesitation to pick out fairly well most of the other colours by name. II. 2 was seen and tested and exactly the same conditions were found, though she had a much higher myopia, which in her was 8 D. Consanguinity. (See Bibl. No. 198, Case xxx, No. 337, p. cxcii.)

Fig. 373. *Nettleship's Case.* Colour-blindness associated with photophobia, amblyopia and nystagmus in two brothers. II. 2, aged 16, was found to have R.V. $=$ L.V. $= \frac{2}{60}$; he had hypermetropia of 2 or 3 D., but vision was not improved by correction; he had been in a workhouse since the age of seven on account of his bad sight, but in spite of his difficulties was now one of the teachers in his school; he said that he could "tell colours well," but on examination he was found to have no colour perception at all, for he confused blue with yellow and scarlet with very dark green. His brother, II. 3, aged 14, was in the same workhouse and said to be colour-blind and to see badly. Two brothers and one sister saw well; the parents were unrelated and said to have good sight. No consanguinity. (See Bibl. No. 198, Case xxxi.)

Fig. 374. *Pflüger's Case.* Total colour-blindness associated with diminished visual acuity, photophobia and nystagmus when looking fixedly in three siblings of whom one, II. 1, was an intelligent girl, aged 14, with V. $= \cdot 15$ in each; no abnormality was found in the retina; no central scotoma was present. The spectrum was shortened at the red end and its brightest region was in the green; strabismus was noticed. Consanguinity. (See Bibl. No. 252.)

Fig. 375. *de Wecker's Case.* In a family of ten children, whose parents had normal vision, the three first born had had bad sight since their infancy, but the author was unable to discover the cause and nature of their defect; the three following children, II. 4—6, had normal vision; the three children, II. 7, 8 and 9, were all affected with total congenital colour-blindness; the youngest child, II. 10, saw well. Two of the affected children were examined; II. 7, aged 18, a well-developed intelligent lad, had never been seriously ill; his eyes appeared normal, except for nystagmus, which was of slight range and extremely rapid; his visual acuity was reduced to finger counting at 5 metres; his papillae were pale and surrounded by a narrow ring of pigment atrophy; his colour vision was tested with spectroscope, coloured papers and wools; the range of visible spectrum and point of maximum brightness were as in the normal dark adapted eye. All colours were to him shades of grey, the ends of the spectrum being nearly black. II. 8, aged 17, was similarly described, but in his case there was no atrophic ring surrounding the papillae. No consanguinity recorded. (See Bibl. No. 125.)

Fig. 376. *Grunert's Case.* Total colour-blindness associated with amblyopia, photophobia and nystagmus in a brother and sister. For II. 2, a peasant aged 36, R.V. $=$ L.V. $= \frac{5}{40}$, bilateral central scotomata were demonstrated; he had brown irides and pupils which reacted normally. II. 3, aged 35, was delicate, she suffered from a weak heart and gynaecological troubles and had been unable to work for some years; she had some myopic astigmatism; R.V. $=$ L.V. $= \frac{5}{50} - \frac{5}{36}$; divergent alternating strabismus was present; the papillae were a little pale and the retinal vessels narrower than normal; no scotomata were demonstrated, possibly owing to the marked nystagmus. In each case the visible spectrum had normal limits, the brightest region being in the green. The five eldest siblings died in the first year of life; the youngest, a female, was living and had good eyes. The parents had both had good eyes; the father died with dropsy at the age of 64 years, the mother died, aged 60, following influenza. Consanguinity. (See Bibl. No. 281.)

Fig. 377. *Dor's Case.* Total colour-blindness in two brothers. II. 1, M. G., aged 35, had myopic astigmatism of 2·75 D. in both eyes; R. V. $=$ L. V. $= \frac{10}{50}$ with glasses; fundi were normal; colour vision was tested by a variety of methods and he was found to see only shades of black and white; his spectrum was shortened at the red end where his limit corresponded with the lithium line between C and D, at a wave

length of 607λ; the limit at the violet end was more indefinite and was given at one time as 455λ, at another time as 435λ; the brightest portion of his spectrum was at the beginning of the green region. The parents and three of the siblings of M. G. had normal colour vision, but one brother, II. 5, was also totally colour-blind. No consanguinity recorded. (See Bibl. No. 185.)

Fig. 378. *Juler's Case.* Total colour-blindness in three members of a sibship of seven; three brothers and a sister, aged 13, 12, 10 and 1 year respectively, were healthy and had normal vision. II. 4, Charles H., aged 8, had dark brown irides; pupils were sluggish but dilated slowly in the dark; ophthalmoscopic appearances were normal; R. V. with + 4 D. = $\frac{6}{6}$, L. V. with + 2·5 Sph., Cyl. + 1·5 A. V. = $\frac{6}{6}$; his mother stated that he had always screwed up his eyes in bright light and that the eyes had always been shaky, but that these signs were not now so marked as they had been; nystagmus was intermittent, oblique and the excursions small, it was not started or increased by attempts at fixation nor by increase of illumination; a central scotoma could not be demonstrated; total colour-blindness was shown by examination with wools, and with the spectroscope through which he saw "white in the middle with red on each side." II. 5, Samuel H., aged 5½, and II. 6, Annie H., aged 3 years, were examined and conditions were found similar to those of II. 4; II. 5 saw in the spectroscope "white in the middle and green at each end"; the colour-vision test for II. 6 was not satisfactory. The three affected siblings appeared to be healthy and of average intelligence. Both parents were members of large families, but no relatives were known to be similarly affected. The colour vision of the mother, I. 3, and of one of her sisters was tested and found to be normal. No consanguinity. (See Bibl. No. 344.)

Fig. 379. *Hess and Hering's Case.* Total colour-blindness associated with amblyopia and nystagmus in two sisters; no scotomata could be demonstrated. The cases are described and discussed in considerable detail, but no statement is made concerning the parents or other siblings. No consanguinity recorded. (See Bibl. No. 249.)

Fig. 380. *Grunert's Case IV.* Two healthy consanguineous parents had three sons of whom the eldest, II. 1, who knew colours well, had myopia of 8 or 9 D.; the second, II. 2, was totally colour-blind and had slight photophobia and nystagmus; R.V. = $\frac{5}{6}$, L.V. = $\frac{5}{4}$; central scotomata were present; fundi normal. The spectrum had normal limits and was brightest in the yellow-green region. The youngest brother, II. 3, was red-green blind. Consanguinity. (See Bibl. No. 281.)

Fig. 381. *Uhthoff's Case.* Total colour-blindness in three siblings; the parents were healthy and unrelated and saw well. II. 1, Bertha F., aged 15 (1901), complained of bad sight, her visual acuity being specially reduced in a very bright light; she was healthy and was normally developed in body and mind. She was found to have myopic astigmatism of 3 D. in the right and 4 D. in the left eye; V. = $\frac{1}{4}$ with correction; she had a marked photophobia, concomitant divergent alternating strabismus and nystagmus on fixation; no absolute central scotoma was demonstrated; she was found to be totally colour-blind and could match all the colours of the spectrum by mixing black and white; ophthalmoscopic examination revealed certain slight pathological changes in the region of the fovea, suggestive of pigmentary degeneration. II. 2, aged 8, and II. 3, aged 6, were also examined, and the condition found was similar in all respects to that described for their elder sister; the youngest sibling, II. 4, aged 5, appeared to see well. No consanguinity. (See Bibl. No. 279.)

Fig. 382. *Boehm's Case.* Total colour-blindness in six brothers associated with photophobia, diminution of vision and nystagmus; the photophobia appeared to be severe in degree and all were considerably hampered in their choice of work by their defect; thus one became a chemist but had to change his work, another brother became a merchant but also had to change his work through inability to see the colour of his goods. The mother, I. 1, had very good vision; the father, I. 2, an aged communal teacher, did not appear to have ever had good vision but lens opacities and other degenerative conditions due to his age made it impossible to demonstrate that his bad sight was the source of the defective vision of his six sons. I. 1 and 2 had twelve children of whom four died young and two daughters, II. 2, aged 20, and II. 8, aged 8 years, were normal. The nystagmus in all the six sons was noticed from the first time that they were seen to definitely fix their vision upon an object; they were shown blue, red and yellow coloured papers which to them differed only in brightness. No consanguinity recorded. (See Bibl. No. 79, pp. 141—145.)

Fig. 383. *Raehlmann's Case.* This case is of great theoretical interest as the author describes the only case on record of total colour-blindness known to have normal visual acuity; the case, however, is also peculiar in other respects, and it may well be that the defect giving rise to this anomaly differs fundamentally from that which exists in the other described cases of total colour-blindness. II. 2, Frau Professor R., aged 58, had been totally colour-blind from her youth; she had a normal light sense, normal visual fields, and after correction for astigmatism, normal visual acuity; to her the visible spectrum was lengthened at both ends, which is of course unusual in such cases, and to her the brightest place in the spectrum was near the line E, which to the normal eye is a pure green; the yellow region was to her very dark or even black. Control experiments by assistants gave the same results. Another very significant feature of this case is that this totally colour-blind female had a son, III. 3, a surgeon, who was a dichromate with a shortened red end of his spectrum; he saw two colours only in the spectrum and had an

unusually keen perception for differences in luminosity. II. 2 had two other children who saw colours normally. II. 3 was a painter by profession, many of his pictures had been exhibited and indicated a very good colour sense. II. 4 had normal colour vision, but her son, III. 4, could not distinguish colours. The mother of II. 2 saw colours well, but the father, I. 2, and his sister, I. 1, suffered from a defective colour sense, the exact nature of which had unfortunately not been determined. The case of II. 2 is very fully described by the author. No consanguinity recorded. (See Bibl. No. 260.)

Fig. 384. *Colburn's Case.* Total colour-blindness and nystagmus in a girl, aged 14, and in her brother, aged 12; no errors of refraction; V. = $\frac{2}{4}\frac{0}{0}$ in good light; mother noted unsteady eyes soon after birth; the affected siblings were strong, bright and healthy; no information is given of other members of the family. No consanguinity recorded. (See Bibl. No. 241.)

Fig. 385. *Raehlmann's Case.* Total colour-blindness in two brothers. II. 1, aged 28, had some corneal scarring in front of the left pupil, for right eye V. = $\frac{1}{5}$ and ophthalmoscopical appearances were normal; he and his brother were unable to distinguish any differences in colour, but were very sensitive in their perception of the slightest difference in brightness; coloured pictures appeared to them like steel engravings; the spectrum appeared like a streak of light with the maximum brightness "in the middle," but the visible spectrum was to them shortened at both ends. II. 2 was aged 24; the condition in both brothers had been the same since their youth. For II. 2 vision was reduced to $\frac{1}{3}$ of the normal, when correction for hypermetropia was made. Slight nystagmus is noted in II. 1, but the examination in each case was hurried and no mention is made of scotomata or photophobia. No information is given of other members of the family. No consanguinity recorded. (See Bibl. No. 118, pp. 47—51.)

Fig. 386. *Nettleship's Case.* Total colour-blindness associated with photophobia, defective vision and nystagmus in two sisters of German nationality, in a sibship of four. Their parents were first cousins. Consanguinity. Unpublished.

Fig. 387. *Rönne's Case.* Total colour-blindness in Kristine J. C., aged 12, the youngest of eight siblings of whom seven had normal colour sense; the parents were second cousins. II. 2 had never recognised colours and confused red with black; she had photophobia and nystagmus; R.V. = L.V. = about $\frac{1}{8}$; fields for white were normal; X-rays were invisible to the patient; the red end of the spectrum was shortened and the maximum brightness was in the green region, boundary at the violet end was normal. Consanguinity. (See Bibl. No. 305.)

Fig. 388. *Nettleship's Case.* Total colour-blindness associated with amblyopia and nystagmus in six siblings. II. 9, aged 25, was freckled and very fair with abundant light reddish-brown hair; her teeth were defective in enamel, forehead at root of nose rather flat; hearing and other senses were good; she was intelligent and very excitable; she complained that she could not see so well by day as by artificial light and that she could not tell colours. R.V. = L.V. = $\frac{2\,0}{2\,0\,0}$ by daylight; emmetropia; pupils active; constant slight lateral nystagmus was present; visual fields (finger test) showed no contraction. She said that in the daytime her sight was so bad that she was afraid to cross the road, whilst at night she saw so well that she could do so with ease, and that she could read small print by a light so dull that other people had to put away their books; on dropping eserine into the eyes, her sight became much worse. Of colours she had not the slightest appreciation; she sorted wools according to their brightness, all colours looked to her like shades of black and white and she always dressed in black and white to avoid making absurd mistakes; discs and vessels were seen to be quite healthy, but a whitish haze of doubtful significance was seen about the macula region. No history of fits or other illness in infancy; her sight had always been as it was at the time of examination, and the nystagmus had been noticed at the age of three weeks. II. 12, aged 20, had symptoms identical with those of II. 9; in each case the daylight vision was improved by looking through a yellow glass; red always looked darker than green of the same shade; the spectrum looked to them like a light band of one colour, brightest in the middle and becoming darker at each end. Of the other nine siblings, II. 1, an army surgeon, with fair complexion and reddish hair, had perfect sight; he died of abscess of liver in India. II. 2 died in infancy of teething and water on the brain. II. 3, aged 35, with reddish-brown hair, was reported to suffer from defective sight in exactly the same way as his sisters. II. 4 had perfect sight, but died, aged 16, of "abscess of the leg and consumption." II. 5, aged 31, had perfect sight; he was fair with sandy-brown hair. II. 6 died, aged 16, after a fall; she was colour-blind and amblyopic, exactly like her sisters; she had golden-brown hair. II. 7, aged 27, was reported to be colour-blind like the others; she married and had two children whose sight was perfect. II. 10 died, aged 2 years, of "whooping-cough." II. 11, aged 22, had very bad sight and the defect was reported to be of the same kind as that of his siblings; he had light brown hair. The parents had good sight and no defect of colour vision, but an uncle was reported to be colour-blind and to be unable to distinguish red from green. No consanguinity recorded. (See Bibl. No. 144.)

Fig. 389. *Hessberg's Case.* Three cases of congenital total colour-blindness in a sibship of four. The grandparents, who lived to old age, saw well and were not colour-blind; the parents, II. 2 and 3, were cousins and saw well, the father died of asthma, the mother was living and was not colour-blind; she, II. 3, had three normal children by a second unrelated husband II. 5.

The first child of II. 2 and 3 was normal; III. 2 (Alfred J.), aged 11 (1909), had photophobia, alternating convergent strabismus and rotatory nystagmus; he had a marked reflection from the retinal vessels; at the macula region the reflex differed from that of normal children; he had a small absolute central scotoma; hypermetropia 2 D. in vertical meridian, 4 D. in horizontal meridian; V., in bright daylight, = counting fingers at 4 m.; tests with Holmgren's wools showed typical total colour-blindness; both ends of the spectrum were shortened, the red end especially so; the brightest part of the spectrum was said to be in the green, near the blue. Very similar accounts are given of III. 3 (Ernest J.), aged 10, and of III. 4 (Martha J.), aged 9; both were examined and had photophobia, alternating convergent strabismus, nystagmus, central scotoma and total colour-blindness, in III. 3 V., in bright daylight, = finger counting at 2 m.; III. 4 counts fingers at 3 m. All three children were well-developed, intelligent and normal in all other respects; the photophobia was noticed by the parents soon after birth. Consanguinity. (See Bibl. No. 335.)

Fig. 390. *Nettleship's Case.* Colour-blindness with day-blindness and nystagmus and retinitis pigmentosa in two brothers; a sister said to be similarly affected. IV. 8, aged 23, a tall milkman with black hair, complained that he could not bear bright light and that his eyes became worse every summer; he had irregular nystagmus, saw better in a dull light than in a bright light and believed that his sight had always been exactly in its present state; R.V. = $\frac{20}{200}$ and 14 J. badly, L.V. = $\frac{20}{100}$ and 14 J. badly, not improved by glasses; his visual fields showed great contraction in every direction except over a narrow tract in the downward and outward region; when asked to name coloured wools he called green blue, and named red, yellow and blue correctly, but he confused purple with dark green, yellow with pink and light blue with pink; ophthalmoscopic examination showed retinal arteries decidedly small and optic discs rather pale but not "waxy"; abundant pigment in very characteristic bone corpuscle shapes was present all round the periphery except over a narrow tract at the inner side which was perfectly free; the conditions seen were identical in each eye. IV. 7, aged 25, also a milkman, had much the same symptoms as his brother; irregular nystagmus; sight better in a dull light; R.V. = L.V. = $\frac{20}{200}$ slightly improved by +30 or 36; pupils acted sluggishly; he was aware that he was colour-blind; he confused light green with bright yellow, pale greys, pale blue-green, pale buff, etc., and rose with dark blue, dark brown, orange, pink and yellow; visual fields showed very marked concentric contraction; some pigment was seen in the retinal periphery, especially in the lower regions. IV. 2, aged 34, was said to be affected in the same way as her brothers; she could not see so well in bright light and could not face the light; she had nystagmus but was believed to see colours well; she had two children living whose sight was believed to be very good. These siblings had two brothers and four sisters with normal vision; the defect of sight in IV. 2, 7 and 8 was noticed by their mother when they were very young. The parents were first cousins once removed; the father, II. 4, died of heart disease aged 50; the mother was a nervous melancholic woman. Consanguinity. (See Bibl. No. 144.)

Fig. 391. *Grunert's Case.* Total colour-blindness in a male aged 36; the condition was associated with amblyopia, nystagmus and photophobia; R.V. with correction = $\frac{5}{36} - \frac{5}{30}$; L.V. with correction = $\frac{5}{30}$; bilateral scotomata were present. The spectrum had normal limits but its brightest region was in the green. Of the five siblings of the colour-blind patient IV. 3, one brother had weak sight; the parents were not related; a great-grandfather on his father's side had a brother who was born blind. No consanguinity. (See Bibl. No. 281.)

Fig. 392. *Nettleship and Holmes Spicer's Case.* Total colour-blindness associated with day-blindness and nystagmus in a sister and two brothers whose parents were second cousins. One brother and one sister died in infancy, one brother, aged 3 years, had normal vision; in addition, one child was still-born and the mother had one miscarriage; there was no reason to suspect syphilis. Very careful and detailed notes of the family were taken by Dr W. C. Souter, and no other cases of defective vision were known in a fairly extensive pedigree. Consanguinity. (See Bibl. No. 337, p. cxxxi.)

Fig. 393. *Nettleship's Case.* It is not quite clear from the author's account of this pedigree what is the real relationship of the two affected sibships, III. 1—3 and III. 4—9; he speaks of II. 2 and 4 being first cousins and their children being second cousins, whereas from other considerations it would appear that II. 2 and 4 are sisters, and II. 2 and 5 are first cousins, in which case the sibships of generation III. would be first cousins through their mothers and second cousins through the father, II. 5, who was first cousin to both mothers. III. 4, Philip P., aged 15, was tall and big for his age but decidedly backward in mental development; he had light hair and brown irides; rapid nearly vertical nystagmus of small range was present; pupils acted well; fundi normal but choroid highly pigmented; V. = $\frac{20}{200}$; refraction hypermetropic; saw best in the evening and in a dull light; was totally colour-blind; "I can only tell between white, black, and brown," when asked for brown he picked up scarlet; he confused bright yellow, blue, pink, and full dark green. III. 5, aged 13, was well grown with light brown hair and grey irides; he had a rapid vertical and rotatory nystagmus; V. in daylight = $\frac{20}{200}$; saw better in the dusk; fundi normal; total colour-blindness, he pronounced "Th" as "F". III. 6, a female, and III. 7, a male, had good sight and intellect. III. 8, aged 7, was quite idiotic and appeared to be quite blind; ophthalmoscopic examination

not possible. III. 9, aged $3\frac{1}{2}$, was idiotic and so nearly blind that he could only tell the difference between bright light and darkness; he had constant nystagmus of wide range; pupils usually $3\frac{1}{2}$ mm., but slowly dilate to large size when he sits for some time in the shade; discs dirty yellowish-white; thickening of one side of septum nasi; could walk and talk a little. III. 1, aged 6, had slight nystagmus which was said to be diminishing; refraction hypermetropic; V. = 12 J. held close in daylight, but saw much better in the dusk; in the daytime her mother did not allow her out because she could not see enough to avoid large objects; fundi normal; total colour-blindness; intellect precocious. III. 2, aged about 4, and III. 3, aged about 1 year, had nystagmus and defective vision. The spectrum for III. 4 and 5 was shortened at the red end and was brightest in the green region. The parents of III. 1—3 were unrelated; the parents of III. 4—9 were first cousins. II. 4 reported to the author that one of her first cousins, an only child, who died aged 10, was said to have been blind in the daytime but able to see well at night. Consanguinity. (See Bibl. No. 144.)

Fig. 394. *Uhthoff's Case.* Total colour-blindness in a teacher, aged 41 years at the time of examination. II. 4 complained of bad sight, which was especially noticeable in a very bright light; he wore smoked spectacles on account of his photophobia and had never been able to distinguish colours; he was married and had three living children who appeared to see well and three children who had died young; he had six siblings, five of whom saw well; one sister, II. 2, apparently had bad sight and was affected like her brother, she was "short-sighted" and could not distinguish colours well, she had a child who saw well. On examination of II. 4, it was found that V. with correction of $-1{\cdot}5$ D. and with smoked glasses was only $\frac{1}{10}$th of the normal; small central absolute scotomata were demonstrated in each field; slight nystagmus was present; the patient matched coloured discs of red, orange, yellow, light green, dark green and blue by mixtures of varying proportions of white and black; the author described the ophthalmoscopic appearances in detail and considered that some slight congenital anomaly was present in the course of the retinal vessels and further suggested that the region of the fovea was not quite normal and that changes were present characteristic of "pigment atrophy." No consanguinity. (See Bibl. No. 279.)

Fig. 395. *Magnus's Case.* Total colour-blindness in a female who had two colour-blind brothers in a sibship of eight. III. 3, aged 38, a teacher with good health and showing no signs of hysteria, had been totally colour-blind since her earliest childhood; she had photophobia, saw better in a dim light and had to wear coloured glasses in bright daylight; R.V. = $\frac{1}{8}$, L.V. = $\frac{1}{5}$; refraction myopic, 2·5 D. in each eye; fields were normal; fundi normal; slight nystagmus was present; it was demonstrated that she was entirely colour-blind, differing colours only impressing her as differing in brightness; with bright green wools she placed bright red, yellow, blue and grey, etc.; the spectrum only gave her the sensation of light, the greatest brightness being at the sodium line. III. 1 was dead, but his sister said he had been as completely colour-blind as herself; the author received confirmation of this from Professors who had taught him at Breslau University, but Magnus did not think the evidence of the totality of the colour-blindness was quite conclusive. III. 2 was said to be colour-blind but no particulars are given. Two or more sisters with normal vision had children, none of whom appeared to be colour-blind. The parents were not related; neither they nor their parents were colour-blind. No consanguinity. (See Bibl. No. 143.)

Fig. 396. *Landolt's Case.* Total colour-blindness in a brother and sister. II. 1, M. M., aged 45, had always had bad vision which was scarcely $\frac{1}{10}$ in each; refraction emmetropic; the condition was associated with nystagmus and photophobia; the optic nerves were rather pale, retinal vessels narrowed and there was some contraction of the visual fields for white; intelligence was above the average. The children of the patient had excellent colour vision, but one of her brothers was totally colour-blind. No consanguinity recorded. (See Bibl. No. 217.)

Fig. 397. *Gertz's Case.* Total colour-blindness in a female, Agda P., aged 16; both parents were aged 46 and had good vision and normal colour vision as tested by Holmgren's wools; the parents were unrelated and of their five children, all except II. 3 had normal colour vision and saw well; no eye disease or defect known in any relations except high myopia. II. 3 was hypermetropic, 4 —5 D., with correction R.V. = L.V. = $\frac{5}{30}$; she had photophobia and nystagmus; violet end of spectrum unshortened, red end shortened to the orange region; the brightest part of the spectrum was to her in the green region; absolute central scotomata were demonstrated. The mother attributed the condition to the fact that during her first month of pregnancy with II. 3 she went to a concert given by six blind singers, which made a great impression upon her. No consanguinity. (See Bibl. No. 353.)

Fig. 398. *Bjerrum's Case.* Total colour-blindness in three brothers, one only was examined, he, a fisherman aged 21, had photophobia, amblyopia and nystagmus; refraction was emmetropic. V. = $\frac{1}{9} - \frac{1}{12}$; central scotomata could not be demonstrated; in the foveal region of both eyes a large blood-red patch is noted; the spectrum was shortened to 680 $\mu\mu$ at the red end, visibility at the violet end was normal, the greatest brightness appeared to him at 528 $\mu\mu$ in the green. Two of the patient's three brothers were similarly affected but the family history was otherwise without interest. No consanguinity recorded (See Bibl. No. 284.)

Fig. 399. *Becker's Case.* Total colour-blindness in one eye with normal colour vision in the other eye in a female. At the age of 3 years, II. 1 complained to her mother that the carpet had a different colour

when she lay on her right side from what it had when she lay on her left side in bed; at the age of 12 her grandfather took her up to the author in order that the defect might be investigated; at the age of 17 she was again examined and the case was then reported. Thus Fräulein S., aged 17 (1878 or 9), with blond hair and grey-blue irides, had refraction R. myopia 2·75 D., V. with correction = $\frac{6}{6}$, L. myopia 3 D., V. with correction = $\frac{6}{6}$; fundus normal and field full in each; her colour vision tested with Holmgren's wools, spectroscope and other tests left the author with no doubt that the left eye was colour-blind, the right eye normal, and that the case was one of unilateral total congenital colour-blindness; she could apparently recognise brown and on this account there has been some difference of opinion as to whether the case may be classed as total colour-blindness. The parents had presumably normal colour vision; the maternal uncle, I. 3, was an artist of high repute as a colorist; the maternal uncle, I. 4, was "colour-blind." No consanguinity recorded. (See Bibl. No. 128.)

Plate XXVIII. Fig. 400. *Göthlin's Case.* Total colour-blindness in two sisters; the condition in these cases was typically associated with amblyopia, photophobia, which was troublesome, and nystagmus which was not pronounced and was perhaps not always present; they were intelligent persons. The parents, both about 70 years of age, gave a normal Rayleigh equation when examined with the polarization-anomaloscope and showed no abnormality in their perceptions of red and green; on the other hand, they stated that they received the same impression in the anomaloscope from a blue-green and a pure green light, and the author could not say whether this was due to yellowness of their lenses due to age or to an innate incomplete blue-blindness. Both the colour-blind sisters were married to men who refused examination but were stated to have normal colour-vision; II. 2 had a son, aged 23, who was found to have colour vision normal in all respects; his Rayleigh equation was typically normal and was given without the slightest hesitation; II. 3 had a daughter, aged 9, who also was demonstrated to have normal colour vision. The paternal grandfather of II. 2 and 3 was half-brother with the same father to the maternal great-grandfather. Consanguinity. (See Bibl. No. 421.)

Fig. 401. *Huddart's Case.* This case was described by the author in a letter to the Rev. Joseph Priestley, F.R.S., in 1777, and is the earliest described case of congenital and hereditary colour-blindness. II. 1, a member of the Society of Friends, named Harris, by trade a shoemaker, living at Maryport in Cumberland, had noticed at a very early age that other persons saw something in objects which he could not see; their language seemed to mark qualities with confidence and precision which he could only guess at with hesitation and frequently with error. His first suspicion of this arose when he was about four years of age; he found a child's stocking and observed that people called it a *red* stocking, though he did not understand why they gave it that denomination as he himself thought it completely described by being called a stocking. He observed also that other children could discern cherries on a tree by some pretended difference of colour, though he could only distinguish them from the leaves by their difference of size and shape; and they by means of this difference of colour could see the cherries at a greater distance than he could, though he could see other objects at as great a distance as they. He could never do more than guess the name of any colour, yet he could distinguish white from black or black from any light or bright colour; dove or straw-colour he called white, and different colours he frequently called by the same name though he could see a difference between them when placed together. Harris was a very intelligent man and attended a course of lectures on Natural Philosophy, hoping it would help him to understand the nature of light and colours.

Two of his brothers were similarly affected (Dalton says *three*); Huddart writes that "two other brothers and sisters" were normal; the parents also were normal. One of the affected brothers was master of a trading vessel belonging to Maryport, and the author asked him whether he had ever seen a rainbow; he replied that he had often done so and could see that it was composed of different colours, though he could not tell what they were. The white stripes of a ribbon he called white; three of the four black stripes he called brown, though they were exactly of the same shade with the other which he had properly called black; the light green he called yellow but he was not very positive, he said "I think this is what you call yellow." The middle stripe which had a slight tinge of red he called a sort of blue, but he was most deceived by the orange colour; of this he spoke very confidently. "This is the colour of grass, this is green." The examination with the striped ribbon was made in the daytime and in a good light.

Dalton, 17 years later, sent an acquaintance in Maryport to test the surviving colour-blind member of the Harris family; Dalton states *twice* that the family consisted of six sons and a daughter (and this is confirmed by the records of the Society of Friends), of whom *four* of the sons were colour-blind. As Huddart's statement is obscure and possibly incorrect, we think it probable that II. 7, marked in Fig. 401 with a query, was really colour-blind. (See Bibl. No. 40, pp. 37—39.)

Grunert reports this as a case of total colour-blindness (Bibl. No. 281, p. 144); other judgments differ from this view on the ground that Harris could see as far off as other children, and was therefore not amblyopic; further, there is no mention of photophobia or nystagmus. No consanguinity recorded. (See Bibl. No. 34.)

Fig. 402. *Waardenburg's Case.* Total colour-blindness in a brother and sister. II. 2 was seen at the age of 9 years, when he was suffering from bad vision, and had photophobia and nystagmus; he wore no

spectacles; the patient was found to have R.V. = L.V. = $\frac{2}{30}$, he had slight myopic astigmatism; no central scotomata could be demonstrated; outer boundaries of fields were normal; no colours were recognised, all differed by shades of brightness only; vision was improved in a dull light; the red end of the spectrum was shortened and the brightest region was in the green. On examining the fundus in red free light it was noted that no yellow colour was present in the macula region and the oval macula reflex was absent. The mother was dead, she was cousin to the father; an elder sister was reported to be similarly affected but was not examined or seen by the author. Consanguinity. (See Bibl. No 422.)

Fig. 403. *Göthlin's Case.* Total colour-blindness in five members of a sibship of seven; the affected individuals consisted of four females aged 29, 26, 14 and 11 years respectively, and one male aged 9; in all cases the condition was typical and associated with acuity of vision not exceeding $\frac{1}{5}$, photophobia and nystagmus; when they were shown Holmgren's wools they asserted that they could distinguish no different colours amongst them; in the polarization-anomaloscope they all perceived exact equality between a pure bright red and a very dark blue; there was no psychic abnormality in any of the children. The parents, I. 1 and 2, and two sons, II. 3 and 4, aged 22 and 17, examined with the polarization-anomaloscope, were shown to have normal colour vision with a completely normal Rayleigh equation. The only defect in eyesight known to have occurred in other members of the family was owing to senile cataract in a grandfather who had seen well in his younger days. No consanguinity. (See Bibl. No. 421.)

Fig. 404. *Nettleship's Case.* An isolated case of total colour-blindness associated with amblyopia and nystagmus in a boy aged 16; he was intelligent and fairly grown; teeth perfect; his sight had never been better than at the time of examination, but the nystagmus had formerly been worse than it now was. R.V. = L.V. = $\frac{12}{100}$; refraction, myopia about $\frac{1}{20}$; constant minute lateral nystagmus was present; he always wore dark glasses in the daytime because he saw better in a dull than in a bright light; he was almost totally colour-blind, but said spontaneously that in very bright sunlight he could see red; in the spectrum he could distinguish no colours, only different shades which were "lightest" at the red end; when being tested he usually named red correctly when it was bright or when held very close; other colours were quite indistinguishable. Media were clear; discs rather pale, the right showing a white semi-transparent glistening band of fibrous tissue extending beyond its margin in the form of a capital D and beneath the large vessels, the left showed a slight haze along the large vessels; at the left macular region there was a single small "punched-out" spot of choroidal disease, and in the right a few similar but smaller spots were seen. The mother reported that for several weeks after his birth there was "a sort of red skin" over the eyes which the medical man however did not think important. His four siblings all had normal vision. No consanguinity recorded. (See Bibl. No. 144. Case *iii.*)

Fig. 405. *Weve's Case.* (Taken from Waardenburg.) Total colour-blindness in two girls, aged 10 and 4 years respectively, in a sibship of four. No consanguinity. (See Bibl. No. 422.)

Fig. 406. *Nettleship's Case.* Most of the data concerning this extensive family history was obtained by Nettleship, but certain additions, including information of two colour-blind females, were made by Usher, who first prepared the pedigree for publication. Nothing is known of the colour vision of individuals in the earlier generations, retained in the chart in order to show relationships. The pedigree traces the history of eight colour-blind males and possibly four colour-blind females, cases which have occurred in three different stocks connected by marriage. To consider first the colour-blind females. VI. 25 and 26, the fifth and sixth born in a sibship of seven, were reported by their first cousin once removed, VII. 22, to be colour-blind, but no details were given of their defect; their mother, V. 8, had a sister, V. 7, with two colour-blind sons, VI. 14 and 15; their father, V. 9, was supposed not to be colour-blind; neither of these colour-blind females married. VII. 57 was abroad, she wrote (1913): "My own case (if I have one) must be slight, and distance is certainly a factor, for I feel almost sure that I see red as others do when it is near me, and only suspected colour-blindness when I discovered that other people saw the red apples in the tree at a distance as plainly as I saw the yellow apples at the same distance. In my father's case red was lost when mixed with green, just as I lose the red apples among the green leaves." Usher sent her tests by post which she did imperfectly, but he was apparently of the opinion that they did not demonstrate conclusively that she was colour-blind. Her father, VI. 70, from his daughter's account, was colour-blind to red by daylight, but appeared to see it as others do by lamplight, and always admired a red dress of hers when she wore it in the evening, and said it was a dull dingy colour by daylight; he first discovered his defect when he was reproved for putting a blue line between the black lines in his engineering drawings where a red line is used between the black; he did not use red because "it did not show"; "red was lost when mixed with green." VI. 70 had a sister, VI. 67, whose two sons, VII. 45 and 46, were colour-blind. VI. 91, aged 79 (1914), mother of VII. 57, was not colour-blind; she did tests sent by post; she does not know of any colour-blindness in her family. The maternal grandfather's (V. 39) colour vision was not known; his grand-daughter said that "as there are no stories that would suggest that he was colour-blind, he was probably normal." None of the sons of the nine married daughters of V. 39 and 40 were known to have been colour-blind, but the only one to be tested was VII. 58, brother to VII. 57, who was normal.

VIII. 12, the fourth colour-blind female, was examined by Gotch in 1912, who reported her to be a deuteranope with about 50 per cent. of green deficiency; Nettleship examined her again in 1913 (for details of the test see the original account), her father, VII. 45, also was tested by Nettleship and was colour-blind; her mother, VII. 27, was tested by Nettleship and was normal; her maternal grandfather, VI. 31, "was certainly not colour-blind," according to the report of his daughter who had never heard of colour-blindness on her father's side; his sister, VI. 32, was a great artist and painted animals and birds beautifully; VI. 30, the maternal grandmother, aged 87 (1913), of VIII. 12, the only one left of her family and generation, never heard of anyone in her family having colour-blindness; she was a keen old lady and much interested in the colour-blindness of her granddaughter. VII. 26, male twin with the mother of VIII. 12, died, aged 34, and was believed to have been normal; his brother, VII. 24, married the daughter of a colour-blind man and had a colour-blind son, VIII. 5, but he himself was reported to be very good at colours; VII. 25 had normal colour vision. There is thus no evidence of colour-blindness on the maternal side of the family of the colour-blind female, VIII. 12. VI. 15 could not see a red flag against a green wood; he could sort silks by candle light, as he was never puzzled by the greens and blues; he married his maternal first cousin, VI. 8, and had three sons of whom one, VII. 12, was colour-blind, and one daughter who died in infancy; his brother, VI. 14, was first discovered to be colour-blind when some of his family were in raptures over a *Pyrus japonica* in full bloom, and he said, "Why, its nothing but leaves"; he saw green, red and brown as one colour, blue and pink as another colour. VI. 14 had a colour-blind grandson, VIII. 5, who was declared to be quite colour-blind by the examining doctors when he went up for his medical examination for one of the Services; red, green and brown are one colour to him, and when he was young he one day had a scarlet piece of flannel in one hand and a bright green piece of velvet in the other; "It is so hard to see the difference," he said, holding them close together. There was no knowledge of the colour vision in members of generation V or earlier; thus we do not know whether the maternal grandfather, V. 2, of the colour-blind male, VII. 12, was or was not colour-blind.

VII. 46, born 1861, the paternal uncle of the colour-blind female VIII. 12, was tested by Gotch who wrote that he was a distinct protanope, red-blind; he remarked, however, "I should never say that red was dingy; it's the guard's green flag that looks like a dirty edition of the red one to me." This suggests deuteranopia rather than protanopia. His only living sibling, the father of VIII. 12, was colour-blind and his maternal uncle, VI. 70, the father of the probably colour-blind female, VII. 57, was also colour-blind. VII. 46 married his second cousin, VII. 50, who had a colour-blind brother, VII. 49, and they had one son, VIII. 19, with normal colour vision. VII. 49 was found to be colour-blind at an examination for the Army; he took pink for grey and blue for pink. VI. 29 never showed any signs of colour-blindness, and as he was reported by his niece, VII. 27, to be a very smart young man and particular about his sister's dresses, they would probably have discovered had his colour vision not been normal. IV. 3 lived abroad and was concerned with colours and dyes. Of VI. 67 her son wrote, "My mother must have been normal as she painted a good deal and nobody has remarked anything unusual in her work."

Usher concludes his account of this history as follows: "With reference to the mode of descent of colour-blindness in females, in none of the cases shown in the chart has colour-blindness been found to come through both parents, but as there are not sufficient data it cannot be asserted that the inheritance has come through only one parent. In two instances the fathers of the colour-blind females are colour-blind, whilst in the third instance his colour-vision was not known, though supposed to be normal. On the other hand, in the two cases with colour-blind fathers there is no evidence whatsoever of colour-blindness having occurred in their mothers' stocks, but in the third instance (VI. 25 and 26), where the father's colour vision is not known, the mother belonged to a stock containing colour-blindness. Of the affected males, nothing is known of colour-blindness in the maternal stock of VII. 49. His sister, VII. 50, married a colour-blind man, and their son, VIII. 19, examined when nearly four years of age, appears to have been normal. VIII. 5 inherits colour-blindness according to rule from his maternal colour-blind grandfather, VI. 14. The colour-blind male, VII. 12, should be expected to derive his defect through his mother, VI. 8, but whether his maternal grandfather was colour-blind is not known." Colour-blindness in the mother's family can be traced in the case of VI. 14 and 15 and VII. 45 and 46; there is no knowledge of the origin of the defect in the case of VI. 70. Further details are given in the original account of the history. Consanguinity. (See Bibl. No. 370.)

Fig. 407. *Pliny Earle and Nettleship's Case.* This very extensive pedigree shows the linkage through marriage of three different stocks, each of which carried colour-blindness; the family history in each case has been traced back for many generations earlier than those shown in the figure, but no common origin for the colour-blindness has been found. The pedigree of the family founded by I. 1 and 2 was first published by Pliny Earle in 1845; the family then extended to four generations, with two sibships of generation five, and was probably the most complete pedigree of colour-blindness which had been published at that date; additional data, extending in some cases to generation VIII, was collected by Dr Samuel P. Hayes from *Pliny Earle's Memoirs* (edited by F. B. Sanborn, Boston, 1898), *The Buffum Family in Rhode Island* (by David Buffum, Newport, R.I., 1890), and from letters from members of the family; it is interesting that with so much additional information only two new cases of colour-blindness appear to

have occurred in this family since the original publication of its history. The histories of the families founded by II. 1 and 2, III. 7 and 8, and II. 3 and 4 were worked out by Dr Alexander Forbes, and by Dr B., VI. 32, his mother, V. 23, and his mother-in-law, V. 11. Many members of generations VII and VIII were too young for information to be obtained, and as the members of the pedigree were widely scattered, little testing could be done.

I. 1, 1717—1796, of whom nothing was known with regard to his colour vision, had four colour-blind sons, four normal sons and six normal daughters; all the six daughters had large families of children, none of whom were colour-blind; one of the colour-blind sons, II. 9, was maternal grandfather to Dr Pliny Earle. The third generation of this family was free from the defect, but a large number of cases, possibly seventeen, occurred in generation IV; there is a story of IV. 30 that he described a fowl as "a yellow hen with blue tail," and when teased about it some years later, declared that "if the tail was not blue it was pink." Pliny Earle states that the whole family was characterised by a defective musical ear and that several members were utterly incapable of distinguishing one tune from another.

VI. 48 was tested, to him purple was blue, he had difficulty with reds and saw no green in the spectrum; he saw no figures in numbers 2 to 12 of Stilling's isochromatic plates. A sister of VI. 55 said that he was colour-blind, but his wife said that he was not. No information could be obtained of the colour vision of the father of the two colour-blind females, IV. 59 and 60. Two other females, III. 4 and 5, are marked as colour-blind on the evidence of information obtained from two of their granddaughters; III. 5 confused pink and blue, and V. 11 related an anecdote told by her father, IV. 3, that his mother, III. 5, went to a ball with one pink and one blue shoe, all oblivious of the fact that they did not match. V. 2 stated that both III. 4 and III. 5 were colour-blind, for she remembers frequently catching them darning their scarlet cashmere shawls with green; V. 11, however, was not aware that III. 4 was colour-blind. Two of the three sons of III. 5 were colour-blind, but the third son, IV. 5, was undoubtedly normal, according to his niece, V. 2, who said that his two colour-blind brothers were very much interested in the study of the whole subject. Nothing was known of the colour vision of II. 1 and 2. III. 6 was not colour-blind, nor were any of his people, so far as was known.

VI. 3 confused pink and blue; VI. 7 was red-green blind and could not tell red and green lights apart; Dr Hayes tested V. 16 and 21, also VI. 3, 7 and 48. Consanguinity. (See Bibl. Nos. 68, 370.)

Plate XXIX. Fig. 408. *Usher's Case.* In 1825 George Combe published an account of colour-blindness in James Milne (1778—1863), a brass founder of Edinburgh, III. 49, in his maternal grandfather, I. 5, and in his two brothers, III. 46 and 52; he adds that no trace of the defect was found in his four sisters, III. 50, 54, 56, 57. We read how I. 5 was desirous that his wife should purchase a beautiful green gown; she brought several patterns to him but could never find one which came up to his views of the colour in question; one day he observed a lady passing in the street and pointed out her gown to his wife as being of the colour that he wished her to get; she expressed astonishment and assured him that the colour was a mixed brown which he had all along mistaken for green; this was the first intimation of his deficiency. III. 49 was for $3\frac{1}{2}$ years apprenticed to a draper; he made mistakes about colours which were for a time attributed to inexperience and ignorance of the names of shades; on one occasion he sold a piece of olive corduroy for breeches and the purchaser requested strings to tie them with; III. 49 was proceeding to cut off what he considered to be the best match, when the customer stopped him and requested strings of the same colour as the cloth; the purchaser chose his own string, and on showing patterns of each to his mother afterwards, III. 49 was told that his ribbon was a bright scarlet and the other a grass green; he later resigned from his business and became a brass founder; he knew blues and yellows but could not distinguish browns, greens and reds; blue and pink, when about the same shade and seen in daylight, appeared to him the colour of the sky which he called blue, but in candle light the pink appeared a dirty buff and the blue remained unchanged; the grass appeared to him more like an orange than any other coloured object with which he was acquainted.

Combe further refers to colour-blindness in a "cousin once removed" of James Milne, which appears from a manuscript written by IV. 63 to refer to III. 42, second cousin to III. 49. The maternal grandfather of III. 42 was brother to I. 5, but it is not known whether he also was colour-blind. The only other case of colour-blindness in this generation, III. 15 (1769—1820), was not related to the Milne family; an account of his defect was given by his granddaughter, V. 24, a well-educated lady who had been told by her mother, IV. 21, that he was unable to distinguish between his wife's (III. 17) scarlet cloak and her grey one, and he could not tell a green crumb cloth from a grey one; he married twice; by his first wife, who was related through his mother's side, he had five sons, who were not known to be colour-blind, and one daughter, IV. 21, who transmitted the defect to her two sons, V. 25 and 26, and through her daughters to her grandson, VI. 16; thus V. 26 could not distinguish the red of geraniums, strawberries or cherries, and he made obvious mistakes when comparing and discussing with others the colours of artificial flies for fishing; V. 25 was said to be worse than his brother; V. 24 was examined and found to have normal colour vision; V. 23 had four sons and two daughters of whom one son, VI. 16, was examined and found to be red-green blind, he recognised only blue and yellow in the spectrum; his only child, VII. 8, was too young to test.

V. 26 married V. 59, granddaughter to James Milne, and had three sons, of whom two, VI. 26 and 34, were colour-blind, and five daughters, two of whom transmitted the defect to their sons, and two others had only daughters; VI. 25 was twice examined and found to have normal colour vision, as had his sisters, VI. 23, 27, 29 and 31; VI. 26 was well known to have been colour-blind; VI. 34 was found to be red-green blind and saw only yellow and blue in the spectrum; all the children of members of this sibship who were living and old enough to be tested were examined, and three males, sons of VI. 29 and 31, were demonstrated to be red-green blind, though one of them, VII. 27, who matched dark brown wools with greens and made other mistakes, named red, yellow, green and blue in the spectrum. The mother of VI. 26 and 34 had three brothers, of whom two, V. 66 and 67, were well known to have been colour-blind; the widow of V. 67 said that the ripest strawberries appeared of a vivid green to her husband, that pink was a striking shade of grey to him, and that in choosing carpets, although he could not distinguish the colours, he vetoed an unsuitable or gaudy one; two females of this sibship, V. 60 and 71, were examined and were not colour-blind.

V. 79, a member of another stock, was colour-blind, he married V. 78, whose father was nephew to James Milne, and who writes, "My husband is colour-blind for red and greens and is the only one in his whole relationship who is so"; she further states: "None of my children are colour-blind. Neither I nor any of my brothers or sisters have any difficulty in distinguishing colours. Neither my father nor any of his brothers or sisters were colour-blind. My younger son has one daughter and her sight is normal. My elder son has two daughters with normal sight, and one son who is colour-blind." Thus VII. 49 has a colour-blind *paternal* grandfather, but it seems unlikely that this is the source of his own colour-blindness; his mother, VI. 82, says that she paints and has a keen eye for colour; her sister also paints; among all her relations she has never heard of any colour-blindness, and "as there is a fair amount of artistic talent, it would probably have been noted had there been any such case. My son's colour-blindness is for red and green, and we proved it when he was three years old, as in copying a picture of red toy soldiers on green grass he reversed the order and could not tell it." From a number of marked colours of different shades sent to the author, VII. 49, aged 19, was seen to match blues with pinks and with purple, and to confuse greens with reds. We have no knowledge of the colour vision in the father of V. 73.

III. 46, the colour-blind brother to James Milne, married three times; his only child by the first marriage transmitted the defect to one of her three sons, V. 81, of whom his niece, VI. 93, writes that he was the only one of her mother's family that she ever heard of being colour-blind. The only married daughter by the third wife of III. 46 had four sons, of whom three, V. 88, 90 and 93, were colour-blind; V. 88 writes, "I am partially colour-blind, that is to say, I am at the mercy of other people with respect to some colours, e.g. reds and greens I am likely to confound, blues and violets and pinks I am uncertain about; certain dark reds appear black. My brother William (V. 90) is, I think, quite as bad in above respects as I am. My other brothers and sisters are, or were, I believe normal." V. 90 writes, "I cannot distinguish red, green or brown; they are all lighter or darker shades of the same colour to me; nor can I distinguish light blue, pink and grey, they being another group of the same kind, *viz.* varying shades of the same colour. I can only pick strawberries by their shape, and a dark red rose is Oxford blue to me, a light pink rose is Cambridge blue. Red is not at all an aggressive colour to me, but violet is; a bright rich yellow is about the only colour of which I can be certain." The defect in V. 88 and 90 was subsequently confirmed by Dr S. P. Hayes, who found that V. 93 was also red-green blind.

Only one other member of this pedigree was known, in 1912, to be colour-blind; he, V. 109, the grandson of James Milne, was examined and found to be red-green blind. The author considers that in the earlier generations there may have been other members affected besides those recorded, but in later generations this is less likely because the occurrence of colour-blindness in the stocks was so well known to a large number of living members, and wide-spread inquiries concerning its presence had been made by a number of relatives; none of the members examined by the author were found to have the defect except those already known to the relatives to be colour-blind. Since the publication of this pedigree in 1912 the author has investigated the further history of the family and sends the following additional information. VII. 14 has a daughter, VIII. 1. VII. 16 has two daughters of whom the eldest is aged 3 years (1925). VII. 20 has two daughters and a son of whom the eldest is aged 5 (1925). VI. 70 has a son and daughter of whom the eldest is aged 5 (1925). VI. 74 has a daughter. VI. 76 married a colour-blind medical man, VI. 75; he saw yellow and blue in the spectroscope; with Stilling's Pseudoisochromatic Plates, 13th edition, he read none of the figures on Plates I, II, III, V, and VII to XI, he read half of those on Plates VI and XII and all on Plates IV, XIII, XIV, XV; with Holmgren's wools he matched indefinite colours with the pale green, blue with the rose, and green with the orange; he was useless with Nagel's cards, he called greenish grey the spots on the card that has nothing but red spots. Of the three sons of VI. 75 and 76, the eldest, aged 9, said he saw blue, green, and red in the spectrum; no defect of colour vision was detected when he was tested by Holmgren's wools and Stilling's plates. VII. 45, aged 6, said he saw red, green, blue and purple in the spectrum; no defect of colour vision detected by Holmgren's wools or Stilling's plates; of VII. 46, aged 3 (1925), his mother says that he can recognise colours quite well and can name them; the author could not confirm this as the child was too young to be tested.

Additional information is also given of the descendants of III. 52; the two sons and two daughters of IV. 83 died unmarried; IV. 84 had a daughter who died, probably quite young. IV. 89 has four daughters and two sons, of whom one son is colour-blind and one daughter has transmitted the defect; thus V. 123 has one daughter, VI. 118, who was abroad, and two sons, VI. 119, who was tested and had normal colour vision, and VI. 121, who was abroad but was believed by his brother to have normal colour vision. V. 124 has three sons and three daughters, of whom VI. 123, a medical man, writes that he is colour-blind (red-green), this is also confirmed by his uncle, V. 130; he had one daughter, VII. 60. VI. 124, 125 and 126 were unmarried, VI. 127 was dead, and VI. 128 was unmarried and abroad. V. 126 had a son and daughter, of whom the son, VI. 130, was tested by Stilling's Tafeln. V. 128 had a son, VI. 131, who was tested and had no difficulty with colours. V. 130, aged 64 (1925), a chemist, is markedly colour-blind, and has to take great care in choosing clothes and ties; he cannot rely on his own choosing; in the spectroscope he named yellow and blue; with Stilling's Tafeln he failed to read any figure on Tafeln 1 to 11, he read three on Tafel 12 and all on Tafel 13; with Holmgren's wools he matched pale green with indefinite colours, i.e. straws and buffs; with orange he gave a bright red, with bright green he matched grey, and with red he picked up dark greens; with rose he put blues; with Nagel's cards he was quite useless. V. 131 is abroad. VI. 33 is married with no offspring; she was examined and found to have normal colour vision. VI. 34 is now dead; on one occasion he undertook to select a green rug to replace one of the same colour that was worn out; on returning home he was told that the new rug was not of the right colour; he replied that it was very stupid of the vendor to send the wrong one for he had chosen an exact match; he asked to see the rug, and on seeing it, at once said that it was all right: it was brown. This confusion of green and brown is what occurred when I. 5 wished to buy a new gown for his wife. Consanguinity. (See Bibl. No. 357, with additions.)

Fig. 409. *Nettleship's Case.* This very extensive pedigree was nearly completed at the time of Nettleship's death after which the material was arranged for publication, and a few additions were made by Usher. Thirty cases of colour-blindness are shown in the chart, two of which occur in women. Nothing appears to be known of the colour vision in members of generation I or in their ancestry. Of the children of I. 3 and 4, one son, II. 6, was known "definitely" to have been colour-blind; a daughter, II. 2, had a colour-blind great-grandson, V. 1, but since nothing is known of the colour vision of III. 3 it cannot be said that the defect of V. 1 arose through II. 2. Nothing is known of II. 3 and 4. II. 10 is believed by at least three of his daughters to have had normal colour vision. II. 6 had one son, III. 5, and five daughters, all apparently free from the defect which, however, was transmitted by all the four daughters who married; thus III. 7, whose husband, III. 8, was in the Navy, had one daughter, IV. 8, with no defect, who married her first cousin and had four children, of whom one son, V. 4, was rejected for the Navy on account of colour-blindness; III. 9 married her maternal first cousin and had three colour-blind sons, IV. 10—12, one normal son who married, IV. 8, and five normal daughters, two of whom had children and one of whom had a colour-blind son, V. 12; V. 9 and 11 were captains in the Army; V. 10 was in the Navy. III. 11 had eight children, of whom IV. 21 was a captain in the Navy and not colour-blind; IV. 22 and 23 were reported to be colour-blind; IV. 24 said that he was colour-blind for reds and greens; IV. 26 was tested, he saw "blue and orange with green between" in the spectrum; called reds green and greens red, and made other errors with Edridge-Green's lantern and also made characteristic mistakes with wools; he was myopic; IV. 28, 29 and 30 and the two daughters of IV. 30 were all reported to have normal colour vision. III. 13, the last married daughter of the colour-blind father, II. 6, had two colour-blind sons, IV. 32 and 33, and one presumably normal daughter, IV. 34. IV. 32 and 33 were both tested; each saw "blue and yellow" in the spectrum and made characteristic mistakes with wools and with Edridge-Green's lantern; IV. 33 had myopia of more than 10 D. II. 10, believed to have normal colour vision, married II. 11, in whose family no colour-blindness could be found, there were however few of this family living; they had ten children, of whom two and possibly three of the five sons were colour-blind, and one of the four married daughters transmitted the defect. Thus III. 19, female, had eight sons, five of whom were colour-blind; IV. 45 failed to pass the R.N. medical test owing to colour-blindness; IV. 46, 47 and 48 were reported by their brother to be colour-blind; IV. 49 was abroad, but wrote, "I am very colour-blind, but so also are several of my brothers; all the odd numbers of us were colour-blind"; he had once been tested and was unable to see poppies in a field of corn or geraniums against the grass of a lawn; some pinks he called Cambridge blue. III. 19 further had one married daughter, IV. 51, who transmitted the defect to one of her two sons, V. 22, who painted a brown horse green. III. 25 sketched, but asked to be told which were his red and green paints; he married III. 26, whose father, II. 12, was reported to be colour-blind by one of his sons; the story current in his family tells how, when his wife joined him in the hills in India, she found him clothed in red trousers; he was a clergyman and presumably thought them to be black or grey; three of the family, however, had denied the existence of colour-blindness in the stock. Of the children of III. 25 and 26 two sons had normal colour vision, one of them was in the Navy, the other, IV. 71, was tested by Nettleship, he married IV. 103, a member of another colour-blind stock and had two sons, aged 3 and 2 years respectively; IV. 73, female, was tested by Nettleship and found to be colour-blind, she said she

had always had difficulty between green and grey, she did not make serious errors with Nagel's cards or with wools and she named "purple, blue, green, yellow, orange, red" in the spectrum; she was not very successful with Stilling's Tafeln and "with the lantern she called two reds green and red and made other mistakes"; Dr Watson reported that IV. 73's green sensation was only 0·5 of the normal. IV. 74 died; IV. 75 was examined by Nettleship and found to be normal. IV. 77 was never able to find strawberries and hollyberries easily as her sister, IV. 75, could; she was tested with wools, Nagel's cards and Stilling's Tafeln and described as colour-blind; she was married and had two daughters, V. 43 and 44, aged 1 year and 1 month respectively. III. 27 was in the Navy and reported to be normal. III. 29, a clergyman, was reported by IV. 73 to be colour-blind. III. 30 was dead, and his sisters were doubtful of his colour-blindness; no information concerning III. 31.

Other cases of colour-blindness in this pedigree occur in members of another stock into which IV. 71 married. II. 15 was reported to be badly colour-blind, his son said that whenever there was any discussion about the particular colour of a bonnet or dress, etc., he always said it was pink; his mistakes were regarded as a family joke; none of his twelve children appears to have been colour-blind, but two of his daughters transmitted the defect. IV. 81 painted a good deal and had no difficulty, but when he began painting, aged about 19, he made bad mistakes and once painted green peas red. III. 47 married a colour-blind man, III. 48, and had three sons, of whom IV. 100 could not tell a red coat on grass and was tested by his sister; IV. 102 reported, "I don't know whether I am colour-blind or not, I can tell crude red from crude green, but I think I am colour-blind about browns. III. 49 said that III. 48 was the only case of colour-blindness known to him in his family.

For further information concerning members of this pedigree readers should consult the original account of the family. Consanguinity. (See Bibl. No. 367.)

Fig. 410. *Schiötz's Case* II. Seven males and three females affected with colour-blindness. I. 1 and 2, of whose colour-vision there was no knowledge, had four normal daughters, II. 2, 4, 6 and 8. II. 6 had one normal son, III. 6, who married his first cousin and had normal children and grandchildren, one colour-blind daughter, III. 7, one normal unmarried son, III. 8, and one normal daughter, III. 9, who married her first cousin, III. 10, the colour-blind son of II. 8. III. 9 and 10 had four colour-blind children, two sons, IV. 9 and 11, and two daughters, IV. 10 and 12. IV. 9 had seven normal children; IV. 10 and 11 were unmarried; IV. 12 had four colour-blind sons, V. 7, 9, 11 and 14, and two normal daughters, V. 13 and 16. All the colour-blind sons of IV. 12 were married and had many children, of whom no information is given.

The author could find no case of colour-blindness amongst the descendants of II. 2 and 4. Consanguinity. (See Bibl. No. 408.)

Fig. 411. *Nettleship's Case.* II. 3 (1798—1851) was known to have been colour-blind; his grandson, IV. 4, had been told repeatedly by his parents that his grandfather had been colour-blind, as he was. II. 3 had eleven children, six sons and five daughters, who were all believed to have had normal colour vision; three of the sons died in childhood, three of the sons and four of the daughters were examined. Two sons, III. 3 and 14, married and had large families, many members of which were tested, and all found to have normal colour vision; one daughter, III. 12, was married and also had children whose colour vision was normal; four daughters, III. 2, 8, 10 and 16, had certain of their sons colour-blind and all their daughters with normal colour vision. Thus III. 2 had one colour-blind son, IV. 4, one son, IV. 10, with normal colour vision, and two sons who had died but were believed to have had normal colour vision; she further had two daughters married, of whom one, IV. 3, had one colour-blind son, three normal sons and two normal daughters; and the other, IV. 6, had two colour-blind sons, three normal sons and five normal daughters. III. 8 had three colour-blind sons, three sons with normal colour vision and four normal daughters. III. 10 had four colour-blind sons, two normal sons, and five normal daughters. III. 16 had three colour-blind sons, four normal sons, and five normal daughters.

Many cases in generation V, and also cases in generation VI, were examined and reported on by Dr S. P. Hayes in 1912. Certain cases—V. 30, 31, 33, 39, 40, 50, 51, 52 and VI. 6—were too young to test.

All the thirteen cases examined were said to be good examples of red-green blindness. Edridge-Green's wools and a small pocket spectroscope appear to have been used for the tests. Nothing was known of the condition with regard to colour vision earlier than generation II. No consanguinity recorded. (See Bibl. No. 326, with additions.)

Fig. 412. *Nicholl and Bell's Case.* This interesting history was originally described by Nicholl, in 1816, when III. 1 was aged 11 years; he was said to be a clever and healthy boy with grey irides, a yellow tinge surrounding the pupil; he called no colour green; dark bottle green he called brown; light yellow he called yellow, dark yellow and light brown he confused with red; pale green he called light red, "common green" he called red; light red and pink he described as blue; blue and red he recognised as such; he said that scarlet paper, grass and green baize were the same colour but different shades; in a prism he saw red, yellow and purple. This boy had four sisters with normal colour vision and one brother, III. 9, who was at that time an infant and too young to test; his mother, II. 2, and her sister, II. 1, had

normal colour vision; his maternal grandfather, I. 2, and his great uncle, I. 3, were colour-blind. I. 2 had been in the Navy and on one occasion had purchased a blue uniform, coat and waistcoat, with red breeches to match the blue. I. 3 considered that a cooked lobster was the same colour as a cucumber; he never called blue pink nor red green, but he called pink blue and green red; he had several sons who died young, and one daughter with normal colour vision, who married but had no children. At a later date III. 1 writes, "The great peculiarity of my case is that it has existed in my family, as far as we have been able to trace, for generations, and has always skipped over the female branches, although, as in my own case, it has been transmitted through them. My brother has the same peculiarity of vision. I have long been convinced that I really see but three colours, viz. blue, yellow and white, and the absence of all colour, black. By taking the water colours, gamboge, Prussian blue and Indian ink, I can produce all the colours I see in Nature....The rainbow appears to me to be composed of but two well-defined and distinct bands, stripes or colours, the one shaded from light to dark blue and the other shaded from light to dark yellow." Both brothers, III. 1 and 9, were examined and identified as dichromates.

In 1924 we again got into touch with the family and, largely owing to the very valuable assistance of IV. 15, obtained information of fourteen further cases of colour-blindness in three generations. III. 1 and two of his four sisters died leaving no children; III. 4 had a daughter, IV. 2, and a son, IV. 1, whose vision, according to the statement of his daughter, V. 12, was perfectly normal; III. 6 had a colour-blind son, IV. 4, and a daughter who died leaving no children; III. 9 married twice, having three sons and six daughters by his first wife, one son and one daughter by his second marriage; all these children were believed to have normal colour vision.

IV. 4 had thirteen children, of whom one son writes that his father was the only member of his family known to him to be colour-blind. IV. 8 had six sons and a daughter: V. 3 was said to be colour-blind, V. 6 was said to be slightly colour-blind, V. 7 and 8 were in Canada and nothing was known of their colour vision, V. 2, 4, and 9 were said to have normal colour vision; V. 4, however, was married and had two sons, of whom one was said to be colour-blind, the second was an infant and too young to test. IV. 14 married her first cousin, IV. 1, and had two sons and a daughter, of whom one son, V. 11, was colour-blind; the daughter, V. 12, reports that her son has perfectly normal vision.

IV. 15 had thirteen children; of her six sons, all of whom were examined some years ago by Doyne in Oxford, five were colour-blind, only one of them has children, and he, V. 16, has four sons living in South Africa; of the daughters of IV. 15, all of whom had normal colour vision, V. 21 had a son, VI. 5, who is colour-blind, and two daughters with normal vision. V. 23 had two daughters and a son of whom we have no information; V. 26 married her second cousin once removed and had two sons, of whom one is colour-blind; V. 29 had four sons and three daughters, of whom the two eldest sons are colour-blind, the third son's sight is believed by the mother to be normal and the fourth son is too young to test, the three daughters of V. 29 have normal colour vision; V. 31 had two normal daughters. IV. 18 had good vision, he was not related to IV. 15.

It is unfortunate that we have no knowledge of the family history of IV. 7 and of V. 5, for either these women came themselves of colour-blind stock or we find ourselves with three cases of colour-blindness transmitted by the fathers, each of whom has normal colour vision. We much regret that we have not had the opportunity to examine any of the cases reported in this pedigree, but many of the cases have been scientifically tested. VI. 11 was in the Navy, VI. 12 failed to pass the test for colour vision in the Navy, IV. 1 was a General in the Army, and we feel some assurance that in a family of this culture, the members of which are fully aware of the anomaly, and whose traditions are associated with the Services, it is unlikely that its colour-blindness should not be looked for and its presence or absence determined in most cases. Consanguinity. (See Bibl. No. 45, with additions.)

Plate XXX. Fig. 413. *Usher's Case.* Eight cases of colour-blindness in males. IV. 20, a draper, aged 17, finds difficulty in matching colours; he puts yellows and buffs to match pale green in the Holmgren wool test, blues and pinks to match purple, and dark greens and browns to match red; he has blue irides and reddish hair. His brother, IV. 17, gave buff and straw colours with pale green, blues with purple, and browns and greens with red. Three other brothers, IV. 18, 19, 21, were believed to be normal. A first cousin to this sibship, IV. 10, named only red and blue in a spectroscope; in the wool test he matched buffs and red with pale green, blues with purple, greens with orange, and dark greens and browns with red; his only brother, IV. 9, was abroad, but had been rejected by a railway company on account of defective colour vision; the report says that when tested with coloured wools he matched light green with pink, pale pink and light brown, as well as with light green itself; he was then tested with a skein of pale pink and he selected three different shades of light brown or fawn; with a skein of red he matched red, scarlet, green and blue.

The maternal grandfather to these two affected sibships, II. 10, saw only red and blue in the spectroscope; he matched pale green wools with drabs and yellows, purple with blues, orange with greens, and red with dark greens and browns. Six of the eight children of II. 10 were tested and found to have normal colour vision; also four sons of III. 21, the son of II. 10, were tested and found normal. III. 20, 26 and 27 were unmarried.

II. 5, an elder brother of II. 10, was colour blind, he matched yellows and pink skeins with pale green, blues with purple, and dark brown and green with red. II. 2 and 4, two sisters to II. 5 and 10, were examined and found to be normal; II. 4 had no children; II. 2 married twice, by her first husband, II. 1, who was a draper for two years and made bad mistakes with colours, she had a son, III. 2, with normal colour vision, and five grandchildren, IV. 1–5, who were believed to have normal colour vision: by her second husband II. 2 had three daughters and eight grandchildren, none of whom are known to be colour-blind, but III. 6 and 8, with their families, are in America and there is no definite knowledge of them; IV. 3, 4 and 5 are unmarried in Australia.

I. 4 was known to be colour-blind; his nephew, II. 10, remembers that he could not recognise the colour of a dress. I. 2 had one sibling only, a sister. II. 7 represents two individuals, of whom no particulars were obtained as to age, sex or colour vision. III. 27 and 28 had each eye tested separately with coloured wools. III. 29 and twelve of his relatives were examined, all were found to have normal colour vision. III. 17, III. 24 and IV. 16 were abroad. No consanguinity. Hitherto unpublished.

Fig. 414. *de Fontenay's Case* 63. Colour-blindness in two brothers and in their three maternal uncles; parents and grandparents were normal. III. 2, aged 51, was tested and was found to be red-blind; he had one son who had normal colour vision. No consanguinity. (See Bibl. No. 140.)

Fig. 415. *Nettleship's Case.* Colour-blindness in eight males. IV. 5 was seen by the author in 1896 when, at the age of 17, he had just been rejected for Woolwich on account of colour-blindness; he was found to be markedly colour-blind to wools. I. 1, a colour-blind male, had three sons and six daughters, all reported to have normal colour vision; II. 1 had four sons and grandchildren by three of them, none of whom were known to be colour-blind. II. 3, 4, 5 and 13 died unmarried; the three daughters, II. 6, 8 and 11, had colour-blind sons; thus II. 6 had one colour-blind son and one normal daughter; II. 8 had three colour-blind sons and two normal daughters; II. 11 had two colour-blind sons, one normal son and one normal daughter, III. 16, who was the mother of the patient, IV. 5. The author had only examined the one case in this family and the history as given was described by him in a letter after his visit; thus we do not know whether his brother, IV. 4, and his uncle, III. 17, who were reported as unaffected, had been tested. No consanguinity recorded. Hitherto unpublished.

Fig. 416. *Snowball's Case.* L. family. Two cases of colour-blindness in males, in a pedigree which has been very fully investigated by the author, who made detailed examinations on thirteen members of the stock.

III. 3, Robert L., aged 43, had worked as a boy in the mercantile marine; later he served as a soldier, and in 1914 joined the Navy and worked in the engine room of destroyers for some months; he had never been tested for colour vision, but he apparently could not tell the exact colours of the flashes used for signals at sea though he understood what they were for, he never made a mistake but required someone to tell him the real colour; he stated that he had passed the colour test for the railway in 1914, and that he had learned to distinguish between the different colours; he was rather shy and suspicious and it was difficult to gain his confidence. In the wool test he matched green with pale green, light blues, rose pinks, greys, drabs, and flesh pink; red he matched with reds, browns and a dark olive green with a touch of brown; rose pink he matched with rose pinks, pale greens, light blues, mauves and a dark purplish grey; orange he matched with oranges, brownish oranges and yellow greens. Tests with Stilling's Tafeln and with Nagel's cards confirmed his deficiency; in the spectrum he named blue and yellow. Of his three children, IV. 1, a boy aged 17, passed all the tests correctly; IV. 2, a boy aged 12, passed all the tests correctly with the exception of the spectrum, in which he named only red, green, blue and purple; IV. 3, a girl aged 7, did all the tests correctly, again excepting the spectrum, in which she, like her brother, failed to name yellow. III. 3 had six brothers, he was often teased by his family about his weakness in naming colours and, so far as he could remember, he had never heard of any similar peculiarity in his brothers or his parents, or in their parents. His father, II. 5, aged 69, passed all tests correctly; he believed that his two brothers and three sisters and his parents, I. 1 and 2, had normal colour vision; II. 5 knew nothing about the colour vision in his paternal aunt and uncle, or in his paternal or maternal grandparents; his mother, I. 2, also had one brother and sister, of whom he had no knowledge. II. 7, aged 71, the mother of III. 3, was partially tested and appeared to be normal; she had three brothers, one step-brother and four sisters most of whom were dead, she had never heard that any of them were colour-blind, nor had she ever heard of any defect of colour sense in her parents or grandparents; her father, I. 3, was a farmer, and was known personally to his grandson, III. 9.

III. 5, aged 42, was tested and was found normal with wools, Stilling's Tafeln, Nagel's cards and the spectrum; he had three children, of whom IV. 6, a boy aged 7 years, was tested; IV. 6 found it difficult to understand the tests, but appeared to have a normal colour sense, except in the case of the spectrum, in which he promptly named red, green and blue; IV. 7, aged 3 years, and IV. 8, aged 4 months, were too young to test.

III. 6 was in France and could not be tested, but his two children, IV. 4 and 5, were examined; IV. 4, a girl aged 10 years, did all tests including the spectrum correctly; IV. 5, a boy aged 7, did all other tests correctly, but named only red, green and blue in the spectrum.

II. 14, maternal aunt to III. 3, had three children, of whom III. 14, a son, was colour-blind; pale green wool he matched with greys and pink, pink he matched with blue and mauve, red he matched with browns, and orange he matched with greenish yellow; he failed also to pass Stilling's and Nagel's tests; in the spectroscope he named red, light blue and dark blue. No consanguinity. Hitherto unpublished.

Fig. 417. *Schiötz's Case VI.* Colour-blindness in the male descendants of I. 1 and 2, who had one colour-blind son, II. 3, two normal sons, and three normal daughters, II. 2, 4, and 7, all of whom transmitted the defect to their sons. Thus II. 2 had three colour-blind sons, two normal sons, and three normal daughters; II. 4 had three colour-blind sons, one normal son and four normal daughters; one of these daughters, III. 9, married and had two colour-blind sons and three normal daughters. II. 7 had one colour-blind son, III. 15, and three daughters with normal colour vision. All members of generations III and IV were tested. No consanguinity recorded. (See Bibl. No. 408.)

Fig. 418. *Snowball's Case.* Colour-blindness in a female and in three of her seven sons; three of her sons had normal colour vision. II. 4, Mrs H., aged 54, was examined and found to be colour-blind; pale green wools she matched with pale blues and violet blue, heliotrope, lemonyellow and cream; she rejected very dark greens and called them black; with rose pink she matched yellowish red and browns; full red she matched with rose pink, browns and dark olive green; with orange she placed cream and light brown. When asked to name the test wools she called green "blue," rose pink "red," full red she called "brown" and orange she called "pink." With Stilling's test she failed utterly in groups 1—9 and 12, group 10 she thought easier but made mistakes, thus she read 42 instead of 92, 75 instead of 54, 10 instead of 83; in group 11 she read only 8 in Tafel 1. With Nagel's card test *A* she stated correctly that there was red on cards 1, 2, 3, 7, 8, 10, 15 and 16, but she did not point to the red dots in them, thus she took dots of other colours for red; she saw red only, wrongly, in 5, 6, 7, 8, 9, 12, 14, 16 and made other mistakes. In the spectrum, reading from the red end, she named dark blue, green, black. Thus II. 4 was undoubtedly colour-blind; she required to get others to choose her dresses; she had a right convergent strabismus, which appeared when she was aged 8 years, as the result of a fall on the back of her head; an ophthalmoscopic examination was made under difficulties, but the author was satisfied that there was no atrophy of the optic disc in either eye. Her parents were dead, and so far as she can remember, neither her father nor her mother was colour-blind; she knew nothing of her grandparents; her parents were not related in any way but her mother's brother married her father's sister, she knew nothing of them or their family except that they lived in Liverpool; she had five sisters and three brothers but appeared to know very little about them. II. 4 reported that her husband's father, I. 3, who died aged 69, was colour-blind; he was a master painter and made mistakes in mixing colours, which were found out by his men, when about to put on the paint; so far as was known, I. 3 had no brothers or sisters, and was not related to his wife, I. 4. II. 4 had thirteen children, of whom III. 3, female, aged 33, Mrs M., living in Shrewsbury, had three children, the eldest, aged 5 (1916), she was not examined. III. 5, male, aged 32, was colour-blind; he matched pale yellow, grey and buff with pale green wools; mauve and blue with rose pink; greens, browns and reds with full red, and yellow greens with orange; with Stilling's Tafeln he failed almost entirely; in the spectrum he saw "only a spot." III. 6, Mrs B., in Shrewsbury, was not seen. III. 7, aged 29, living near Warrington, was not seen; she had three boys, the eldest aged 6 years. III. 9, was tested in 1922 by Sir J. H. Parsons, who found him normal with Holmgren's wools, Stilling's test and coloured lights. III. 10, John, died age 18; he was paralysed in both legs from birth, no evidence of his being colour-blind was obtainable from his mother. III. 11, Beatrice, aged 24, was examined fully and found to be normal; in the spectroscope she read, "red, pale yellow, green, blue, heliotrope." III. 12, Horace, aged 22, was colour-blind; he confused light blues with pale green wools, flesh pinks with rose pink, dark browns and dark purple with full red, lemon yellow with orange; he managed Stilling's test well, but made mistakes with Nagel's cards; in the spectrum he named "dark red, green, purple." III. 13, Frank, aged 27 (1922), was examined and classified as normal; he was rather hesitating over the wool test and was not entirely correct in Stilling's tests; Nagel's tests were done without error; in the spectroscope he named "red, orange, light green, sea green, light blue, dark blue." III. 14, Wilfred, aged 19 (1916), was tested with wools, Stilling's Tafeln and Nagel's cards, and classified as normal; in the spectroscope he named "red, yellow, green, blue, purple"; he was tested again later and the classification confirmed. III. 15, Ethel, aged 18, and III. 16, Amy, aged 16, were fully tested and found to be normal; each of them named "red, yellow, green, blue and heliotrope" in the spectrum. III. 17, Percy, aged 12, noticed at school that he could not tell the colours at the painting lesson, another boy had to mix his paints for him; pale green wool he matched with cream and greys, rose pink he matched with blue and pale violet, full red he matched with dark greens and browns, orange he matched with a yellowish green; he also made many mistakes with Stilling's Tafeln and Nagel's cards; in the spectroscope he named "green to the left and blue to the right." III. 17 was said to have had a squint, but it was not apparent at the time of testing. No consanguinity. Hitherto unpublished.

Fig. 419. *Schiötz's Case I.* Nineteen cases of colour-blindness of which four were in females. I. 2 was twice married; by his first wife he had seven children and by his second wife he had eighteen children; colour-blindness occurred in the descendants from both marriages, but there is no definite knowledge that

I. 2 himself was colour-blind. II. 5 married first a daughter by the first marriage, II. 4, and secondly a daughter by the second marriage, II. 6; by his first marriage he had one son with normal colour vision, III. 6, one colour-blind son, III. 7, and two daughters, III. 8 and 10, who were themselves normal, but transmitted the defect; by his second marriage II. 5 had a colour-blind son, III. 13, three normal sons and two normal daughters. Of the sisters of II. 6, one, II. 10, had a colour-blind son, III. 19; and one, II. 7, had three normal children, one daughter of which married her half first cousin, III. 7, who was himself colour-blind, and had ten children, of whom the only son, IV. 12, and four of the nine daughters, IV. 15, 18, 19 and 22, were colour-blind; two of the colour-blind daughters married and each had one son who was colour-blind, V. 14 and 15; one of the normal daughters, IV. 13, married and had four normal daughters. IV. 24, the colour-blind son of III. 8, married IV. 10, herself a member of a colour-blind stock, information as to which has been very kindly sent to us by the author, and had two children, V. 17, a colour-blind son, and V. 18, a normal daughter. V. 18 is herself married and has two sons living in Copenhagen, about whom no information is available. III. 10 had a normal son, IV. 25, a colour-blind son, IV. 26, and a normal daughter, IV. 27, who married her colour-blind half uncle, III. 13, and had three sons, of whom two, V. 20 and 23, were colour-blind, one, V. 21, normal, and one normal daughter, V. 22.

A large number of cases in this pedigree were examined by the author who used Stilling's test, Ishihara's test and Nagel's Anomaloscope; he usually describes the cases as red-green-blindness only, but he tells us that the three cases V. 2, V. 4 and V. 17 were all deuteranopes. Consanguinity. (See Bibl. No. 408, with additions.)

Plate XXXI. Fig. 420. *Horner's Case.* Fourteen cases of colour-blindness in males only in a pedigree of four generations.

I. 1, a colour-blind male, had five normal daughters, of whom II. 2 had four normal daughters, one of whom had two colour-blind sons, IV. 1 and 2; II. 4 had two colour-blind sons, III. 6 and 7, and three normal daughters; II. 6 had three normal daughters and one colour-blind son, III. 13; II. 8 had four normal daughters; II. 10 had three colour-blind sons, one normal son and five normal daughters, of whom III. 18 married and had two colour-blind sons, one normal son and one normal daughter; III. 20 married and had three colour-blind sons and one normal daughter. No further information is given; the author comments on the fact that in each of the seven cases of colour-blindness in generation IV, the defect had skipped two generations in the direct line. No consanguinity recorded. (See Bibl. No. 117.)

Fig. 421. *Nettleship's Case.* Family E. Colour-blindness in a male, III. 2, and in his maternal grandfather, I. 2. III. 2 had two children, a son, IV. 1, of whose colour vision there was no knowledge, and a normal daughter. It is not known whether III. 2 had any siblings. No consanguinity recorded. Hitherto unpublished.

Fig. 422. *Cohn's Case.* Colour-blindness in males only in three generations. III. 2, aged 43, with fair hair and blue grey irides, knew that he had since his youth made mistakes in colours; his parents were normal and unrelated, but his mother's brother and one of her male cousins were colour-blind; he had five siblings of whom four were brothers and all had normal colour vision, but all the sons of his sister, III. 4, were more or less colour-blind and her daughters had normal colour vision. III. 2 had seven children, all of whom were normal. No consanguinity. (See Bibl. No. 129, p. 128.)

Fig. 423. *Nettleship's Case.* Family B. Six colour-blind males in two sibships. Nothing is known of the colour vision of I. 1 and 2; they had ten children, of whom two sons were colour-blind, a daughter, II. 5, and a son, II. 7, were tested and found to have normal colour vison. II. 5 had eight sons, of whom four were colour-blind, and a normal daughter, III. 6; III. 2, 3 and 10 were not suspected of being colour-blind but had not been tested. III. 6 had a normal son and daughter. II. 7 was married and had normal children. No consanguinity recorded. Hitherto unpublished.

Fig. 424. *de Fontenay's Case.* A colour-blind male, I. 1, had five sons and three daughters, all with normal colour vision; three of the sons, II. 2, 5 and 7, were married and had in the three resulting sibships eight sons and three daughters, all unaffected; two of the daughters of I. 1, II. 10 and 12, were married and each had one colour-blind son; II. 10 had also three normal daughters, one of whom had two colour-blind sons and six unaffected children; II. 12 had, in addition to the colour-blind son III. 17, two normal sons and two normal daughters, one of the latter had a colour-blind son, IV. 1. No details of the cases are given. No consanguinity recorded. (See Bibl. No. 424.)

Fig. 425. *Rivers' Case.* Seven cases of colour-blindness in males amongst the Todas of the Nilgiri Hills in Southern India. In every case the condition was a perfectly definite example of red-green blindness, and no evidence could be found of other sensory defects associated with the colour-blindness; the individuals were tested with Holmgren's wools, Nagel's cards, Rothe's coloured papers, and in certain cases with Lovibond's tintometer. In each case the defect was transmitted to the affected male through his unaffected mother, except in the case of II. 3 and 9, the father of whom belongs to the affected stock; we have no knowledge of the mother's stock in this case or whether she was related to the father; the percentage of colour-blindness amongst the Todas is high, and I. 1 may well have also been a member of an affected stock. According to the author's account of the social organisation of the Todas (see *The Todas,*

London, 1906), polyandry would appear to be the rule amongst them and it must be exceedingly difficult, owing to their customs, to determine who is the real father of any individual. The pedigree is taken from Bateson's chart. No consanguinity recorded. (See Bibl. No. 298.)

Fig. 426. *Lutz's Case.* A single case of total colour-blindness in a male, aged 20 years. III. 7 reported that he had been dazzled by bright light since his earliest youth; he was found to have marked bilateral photophobia and nystagmus; R.V. = L.V. = $\frac{6}{36}$; media clear; fundi normal; examined by Holmgren's and Nagel's tests he was found to be totally colour-blind. He was the only affected member of his sibship of eight, one brother, III. 6, died in infancy; no other member of his family had been known to suffer from dazzling. No consanguinity recorded. (See Bibl. No. 349.)

Fig. 427. *Burckhardt's Case.* Nine cases of colour-blindness in males in four generations. II. 2, a male, with normal colour vision, had a colour-blind son, III. 2; it is not stated whether he had other children. III. 2 had three normal daughters, IV. 2, 3 and 5, two of whom had colour-blind sons; IV. 2 had two colour-blind sons, one of whom had a twin brother with normal colour vision. IV. 3 had two colour-blind sons.

II. 3, brother to II. 2, was colour-blind; his daughter, III. 7, with normal colour vision, had three sons, of whom two were colour-blind. The normal son, IV. 10, married his second cousin, a granddaughter of II. 2, whose exact parentage is not stated, and had a colour-blind son, V. 6.

The family was Bernese; no details of the type of colour-blindness in these cases are given. No consanguinity recorded. (See Bibl. No. 95.)

Fig. 428. *Holmgren and Göthlin's Case.* Reference is made to this very interesting family history in a paper by Göthlin, published in 1916 (Bibl. No. 372); he did not there give a full account of the case because the history was incomplete and he hoped, at some future date, to be able to examine certain youths of the sixth generation and to investigate further certain peculiarities in colour vision present in some members of the fourth and fifth generations. He has very kindly sent us what further information is already in his possession. I. 1 was a doctor and an entomologist, living at the end of the eighteenth and beginning of the nineteenth century; his daughter, II. 1, told Holmgren that her father, while investigating insects, would from time to time ask other members of the family whether the colour on the animal was red or green; further, he was accustomed in his medical investigations to ask other members of his family whether his patients were cyanotic or not. Göthlin concludes from these facts that I. 1 was probably red-blind.

II. 1, the daughter of I. 1, had eight children, of whom two sons, III. 2 and 4, were known to be colour-blind, but were not examined; three sons, III. 3, 8 and 10, were examined by Holmgren, and found to be red-blind; two sons, III. 12 and 14, and one daughter, III. 6, were not known to have any defect in their colour sense. No definite case of colour-blindness appears to have occurred in generation IV, though Göthlin refers to certain lesser peculiarities in colour vision which ought to be thoroughly examined; in each of the three cases in which the daughters of the colour-blind members of generation III have married, however, they have had colour-blind sons. Thus IV. 5, daughter of III. 2, has two sons and three daughters, believed to have normal colour sense, and two sons, V. 5 and 6, examined by Göthlin with the polarisation anomaloscope and described as red-blind; IV. 7, also daughter of III. 2, has three normal daughters and two sons, V. 8 and 11, similarly demonstrated to be red-blind; IV. 19, daughter of III. 10, has three normal daughters and two red-blind sons, V. 13 and 15. The only daughter of II. 1 does not appear to have transmitted the defect. No consanguinity recorded. Hitherto not published in detail.

Plate XXXII. Fig. 429. *Reber's Case.* III. 2, Mrs S., a physician's wife, complained, at the age of 50, of asthenopic symptoms; she was found to have slight hypermetropia and, with correction, her vision for form was normal; she said that her colour sense had been defective as long as she could remember, and that *two* of her sisters were similarly affected. Tests made with Oliver's series of wools revealed a complete confusion of dark green, dark red and brown; lighter shades she distinguished better; rose and blue were confused. On being asked for details of her family history she stated that all her sisters, of whom there were *three*, had impaired colour perception, and her only brother also had the defect; her father, both his brothers and his three sisters, were also colour-blind; her mother was believed to have normal colour vision, but III. 2's maternal uncle, II. 1, was extremely colour-blind. III. 2 had no knowledge of the colour vision of her father's parents; her maternal grandparents were not colour-blind, so far as she had been able to learn.

III. 2 had four children, of whom two sons were colour-blind, one son, a twin to one of the colour-blind members, was believed to be free from the defect and one daughter had normal colour vision; the younger of the affected sons was examined and was found to have exactly the same defect as his mother.

The title of this paper refers to *six* colour-blind women, but the description indicates seven. No consanguinity recorded. (See Bibl. No. 237.)

Fig. 430. *Nettleship's Case.* Colour-blindness in two females and seven males in three generations. I. 3, a colour-blind male, had seven children, of whom two daughters, II. 5 and 12, were colour-blind, two sons had normal colour vision and two daughters with normal colour vision, II. 6 and 9, had colour-blind sons. II. 5 had two children, of whom III. 3, a son, was colour-blind, and III. 4, a daughter, was normal. II. 6

had three colour-blind sons, III. 6, 7 and 12, one normal son, III. 5, and four normal daughters; the youngest son, Colonel W., III. 12, either was single or had no children, but other members of the sibship had many children, who were all said to be normal. II. 9 had three sons, of whom two were colour-blind; it was not known whether the third son, III. 15, was colour-blind or normal. There is no statement as to whether II. 12 and 13 were married or single. Some second cousins of Colonel W. on his maternal grandfather's side were reported to be colour-blind. The author did not suppose that the pedigree was complete even for the sibships shown, possibly children who died young are omitted. No consanguinity recorded. Hitherto unpublished.

Fig. 431. *Cunier's Case.* This is an interesting case of hereditary disease affecting all the females of five generations; twelve females were affected and nine males had normal vision except in the case of V. 8, who had high myopia. The author published the case as one of hereditary colour-blindness from the fact that the affected members, of whom he examined several, could not distinguish between dark blue and cerise colour, but from his account there was evidently some other pathological condition present and the colour-blindness may well have been only a secondary symptom. We owe to Mr C. H. Usher the suggestion that the primary defect was in the lens in which there was perhaps a yellow discoloration without enough loss of transparency to cause great defect of sight. No members of the pedigree became blind, though I. 1 lived to be 80 and II. 3 died aged 70 years. No consanguinity recorded. (See Bibl. No. 64.)

Fig. 432. *Jerchel's Case.* I. 1 was colour-blind; he had one son who died childless and five daughters, four of whom transmitted the defect. Thus II. 2 had one colour-blind son, one son and one daughter with normal colour vision; their descendants in the next generation were all normal. II. 4 had one colour-blind son, two normal sons and three normal daughters. II. 6 had five normal children and normal grandchildren. II. 8 had two colour-blind sons, three normal sons, who all had normal offspring, and four normal daughters, one of whom had one colour-blind son and a normal daughter, and one, III. 24, had a normal son and daughter. III. 10 married a colour-blind man and had one colour-blind son, III. 34, two normal sons, one colour-blind daughter, III. 30, and two normal daughters. We are told that the descendants of this sibship had normal colour vision, but we are not told whether the colour-blind female herself had children or not.

The author of this case was one of the colour-blind grandsons of I. 1. No consanguinity recorded. (See Bibl. No. 363.)

Fig. 433. *Nettleship and Paton's Case.* Colour-blindness in two females of the same sibship and possibly also in their mother; two males affected in the next generation. II. 4 had always been reputed amongst her descendants to have been colour-blind, but no facts concerning her defect could be obtained; she married and had a considerable family, of whom two of the daughters, III. 4 and 5, were certainly very colour-blind, they made bad mistakes, and yellow was the only colour III. 4 was sure of. III. 5 died unmarried; III. 4 married and had one child, a son, IV. 2, who was so colour blind that he was unable to distinguish the flowers of a crimson rose from the foliage. IV. 2 married his first cousin and had four children, of whom the third, V. 3, was still-born and V. 4 was an albino; all had normal colour-vision. IV. 3, a colour-blind male, died unmarried, aged 24; his maternal grandmother was sister to the possibly colour-blind II. 4; his two maternal uncles, III. 8 and 9, died unmarried. Consanguinity. (See Bibl. No. 302.)

Fig. 434. *Nettleship's Case.* Colour-blindness in a female; her father and all her four sons being similarly affected. The author was indebted, for this pedigree, to Sir Thomas Barlow and Dr Gabb, but he himself examined the colour-blind female, her husband, and five of her six children.

Nothing is known of the colour vision in members of generations I and II, and there is no proof that the mother of the colour-blind female, IV. 2, was a conductor of the defect; she, III. 2, married her colour-blind first cousin, III. 3, but their relationship was on his father's side and not on his mother's side; we have no knowledge of the source of the colour-blindness in III. 3. II. 1 was a medical practitioner; III. 2 was not colour-blind; III. 3 was known to be very badly colour-blind, he was of Welsh extraction and had other siblings, but no information could be obtained of them or their descendants; III. 2 and 3 had six or more children, most of whom were believed to have been males, and all except the last born, IV. 2, died within a few minutes of birth; nothing was known as to the cause of this high infant mortality. IV. 2 knew that she did not see colours normally, but she did not wish to be examined and only gave information reluctantly; the brief examination with wools left no doubt as to her condition, and she only saw two colours which she named "red or yellow" and "blue" in the spectrum; her husband, IV. 3, was not colour-blind. Of the six children of IV. 2 and 3, V. 1, aged 23 (1908), was in South Africa; his father and sisters all said that he was very badly colour-blind. The sisters V. 2 and 3 were both tested and found to have normal colour vision. V. 4, aged 18, saw two colours only in the spectrum, which he named yellow and blue; he confused the rose of the wool test with blues and mauves and matched full greens with browns. V. 5 and 6 made similar mistakes, though V. 5 had less defect than V. 6.

V. 3 had a deformity of the little finger which was constantly crooked or half-flexed; it could be straightened passively without pain or perceptible resistance, but flexes when released; the condition was more marked in the right than in the left finger; besides the flexion there was also some curving of

the finger, especially of its distal end, towards the ring finger; a similar deformity was present in the mother, IV. 2, and in her father, III. 3; the condition was said to be well-marked in the case of III. 3 and to be very slight in the case of IV. 2. It is not stated whether the condition was congenital or whether it tended to progress. Consanguinity. (See Bibl. No. 355.)

Fig. 435. *Schiötz's Case V.* I. 2, a man with normal colour vision, was twice married; by his first wife he had three sons who were all tested and found to have normal colour vision; by his second wife, I. 3, who was colour-blind, he had four children, II. 4—7, of whom three were colour-blind sons, one, a daughter, with normal colour vision. No consanguinity recorded. (See Bibl. No. 408.)

Fig. 436. *Vogt and Klainguti's Case, P.O.* Red-green-blindness in a brother and sister, in their father and in their maternal first cousin. III. 3, male, aged 22, had normal colour vision; III. 4, male, aged 17, was a dichromate; III. 5, male, aged 12, had normal colour vision; III. 6, female, aged 10, was a dichromate. The father of this sibship, II. 4, aged 49, was also demonstrated to be a dichromate; nothing was known of the colour vision in his parents. The mother, II. 3, aged 42, had normal colour sense, her sister, II. 2, aged 55, with normal colour sense, married to a normal, II. 1, aged 56, had two sons, of whom III. 1 had normal vision and III. 2 was a dichromate. Nothing was known of the colour vision in the parents of II. 2 and 3. All individuals in generations II and III were examined by the authors. No consanguinity recorded. (See Bibl. No. 409.)

Fig. 437. *Schiötz's Case IV.* Colour-blindness in three males and one female in two small sibships. II. 1 and 2 are colour-blind brothers; II. 2 married and had three children, of whom III. 1, a son, and III. 3, a daughter, were colour-blind, III. 2, a daughter, had normal colour vision. All these cases were examined, and the mother of III. 1—3 also was examined. No consanguinity recorded. (See Bibl. No. 408.)

Fig. 438. *Vogt and Klainguti's Case, Ra.* Colour-blindness in two sisters and two brothers in a sibship of eight; their father and a paternal uncle were also colour-blind. III. 1, male, aged 21, III. 3, male, aged 17, III. 5, female, aged 15, and III. 7, female, aged 11, were all fully tested and demonstrated to be dichromates; one brother, III. 2, was not tested and no information is given of his colour vision; two brothers, III. 4, aged 16, and III. 6, aged 13, were tested and described as normal, and one sister, III. 8, aged 8, was also normal. The father, II. 3, aged 43, was demonstrated to have dichromatic vision; the mother, II. 2, aged 41, had normal colour sense. All four grandparents were dead and nothing was known of their colour vision. The mother had one step-sister, II. 1, who was examined and found to be normal; the father had two brothers and a sister, all of whom were examined; thus II. 4, aged 42, and his wife, aged 39, had normal colour vision; II. 7, aged 40, was a dichromate, his wife, aged 39, and his daughter, aged 7, had normal colour vision; II. 8, aged 38, had normal colour vision, her son, III. 10, aged one year, was too young to test. No consanguinity. (See Bibl. No. 409.)

Fig. 439. *Nettleship's Case.* Colour-blindness in two sisters, in all their five sons, and in one of their male first cousins. III. 7 and her husband were dead at the time that their history was investigated, but their children were confident that their mother was more or less colour-blind; she used to do wool-work, but had to have the coloured wools selected for her; she and her husband were not cousins, they had two children, a son and daughter, of whom the latter matched all wools promptly and correctly, without the slightest hesitation, the former, IV. 4, was colour-blind; he matched pale green wool with drab and the pink with certain blues; in the spectrum he thought he saw three colours, "orange, yellow and blue." III. 9, sister to III. 7, was an elderly lady in weak health when tested in 1908; she knew she had always had difficulty with colours, and on trial confused pale green wool with brownish buff and yellow, violet she confused with blue, she considered but rejected brown as a match for bright red; in the spectrum she at first saw "orange, yellow and blue," but after prolonged looking thought there was "green between the yellow and blue"; she never named red in the spectrum; her husband was tested and found to be normal, he and his wife were not cousins. III. 9 and 10 had four sons and a daughter, of whom IV. 6, a schoolmaster, aged about 26 (1908), was colour-blind; he confused pale green with buff, orange with light brownish-green and pale yellowish-greens, violets with blues and almost with rose, and considered, but finally rejected, bright red as a match for greens and browns; he saw only two colours, "orange and blue," in the spectrum and "a sort of dark-green" to the *left* of the "orange." IV. 7, a medical man, aged about 24 (1908), made many characteristic mistakes in matching the wools; IV. 8, also a medical man, was well known by his father and sister to be as colour-blind as his brothers; IV. 9, the only sister, aged about 20 (1908), was tested and found to be normal; IV. 10, aged about 18, confused pale green with buff, orange with bright red and bright green, rose with violet and purple; in the spectrum he saw "reddy yellow and blue." III. 12, maternal first cousin to III. 7 and 8, was examined and found to be definitely colour-blind; his daughter, IV. 17, and two of his six sons were examined and found to be normal.

The parents of III. 7 and 9 were not cousins, their father died when they were children and nothing was known of his colour vision, the mother appears to have come of a stock in which colour-blindness was present, since her sister, II. 9, also had a colour-blind son. Nothing is known of the colour vision in generations I and II. Professor Bateson introduced this family to Nettleship, and Professor Priestley Smith examined many of the members within his reach. No consanguinity recorded. (See Bibl. No. 355.)

Plate XXXIII. Fig. 440. *Nettleship's Case.* This pedigree was prepared by Nettleship and was amongst his incompleted unpublished work at the time of his death; it represents a family, members of which have achieved high academic distinction. We have been enabled through the kindness of VI. 54 to add a little further information to that supplied by Nettleship.

Nettleship expended a great amount of labour in writing letters and endeavouring to get his information concerning the occurrence of colour-blindness as complete as possible, but few cases have been thoroughly and scientifically tested and the history appears to be to a large extent based upon statements supplied by members of the family concerning themselves or their relations whom they knew to be colour-blind or believed to be normal. We have no doubt of the accuracy of the history so far as the colour-blind members are concerned, and in a family of this standard of culture, in which the occurrence of the anomaly is a recognised feature of the family history, the condition is only likely to have escaped notice if it is of slight degree.

With regard to the anomalous trichromates, V. 76, 78 and 79, they and all members of their sibship were fully tested, but we only know definitely of one further case who was tested with regard to this condition and he, VI. 54, made a normal equation. Since this particular anomaly remains unrecognised unless revealed by the test, we can have no assurance that other members of the family would accept the normal equation if tested. It appears to be definite, from Schuster's[1] and Houstoun's[2] investigations, that the condition of anomalous trichromatism does not constitute an extreme variation of normal colour vision, but further research is required before we can say what, if any, relationship it bears to colour-blindness. The red and green mixture which matches the given homogeneous yellow to the eyes of most people was much too red for V. 76, 78 and 79, who suggested that the mixture was to them almost as red as a hunter's coat.

The descendants of II. 1 were believed to be normal. We have communicated with one of the living descendants of II. 3 who had no knowledge of colour-blindness in his ancestors, but we take it from a scientific book written during the life of III. 2, that he could not tell the difference between a red coat and a black one on the hunting field. V. 13 had seven sons of whom "some" were said to be colour-blind. VII. 1 and 2 were fully tested by Nettleship and found to be normal. Two women in this family are known to be colour-blind, VI. 13 and VI. 19; of the former, she is known to have had a colour-blind father, V. 24, and a colour-blind maternal grandfather, IV. 24; she was married and had four children of whom two sons were colour-blind, one son, VII. 5, and one daughter, VII. 8, were said to be not at all colour-blind; the sister of VI. 13 and her only daughter, VII. 9, were said to have normal colour vision. Among the descendants of III. 33 and 34 are distinguished men of science who were interested in the subject of colour-blindness and tested their relations; we have little doubt that all information concerning this branch of the family is accurate and complete.

This is an extremely interesting history showing the typical form of descent in all cases; thus no colour-blind male has a colour-blind son, except in the possible case of III. 14 whose wife also was of colour-blind stock; the descent in every case is through the normal daughter of a colour-blind father, and in the two only cases of affected females the anomaly occurs or probably occurs on both sides of the family. The occurrence of cases of anomalous trichromatism in the history is very interesting, but this defect possibly arises from a different source from that of the colour-blindness in closely related branches of the family, as shown in the pedigree.

We much regret our inability to complete the pedigree; it would be of great interest to hear whether further cases of the defect have occurred amongst the descendants of V. 17, 23, 26, 29, 32, 33, VI. 8 and VI. 23. Consanguinity. Hitherto unpublished.

Fig. 441. *Nettleship's Case.* This fully worked out pedigree, containing seventeen cases of colour-blindness, is of special interest, for three of the cases are in females and one case in a female, V. 28, who has a twin sister with normal colour vision whose bodily features are almost indistinguishable from those of the colour-blind twin.

No information could be obtained of the colour vision in I. 1 and 2. II. 11, aged 84 (1908), wrote that to the best of her recollection her brothers, II. 2 and 4, and her sisters, II. 7 and 9, were, like herself, endowed with perfect vision for colours, but that she well remembered that her niece, III. 7, who was about seven years her own junior, when a young girl mistook "scarlet for white," and she added that the father, II. 8, was very angry when told that the child "did not know one colour from another." II. 11 had seven children of whom III. 29, a female, was examined and found to be normal, and III. 26 reported that he and his three children were normal. II. 2 and 4 had normal descendants of whom III. 4 was examined and confirmed the normality of his father and uncle, and reports were obtained of several other descendants of the brothers. II. 4 is said to have had particularly delicate appreciation of colour. II. 6 died, probably, whilst young. II. 7 had a very large family of whom nine lived to adult life (the mother forgot how many had died in infancy, eight, ten or more); of the living members three were males and six females, one female, III. 7, and two males, III. 10 and 12, were colour-blind. III. 7, aged 77 (1908), knew that she had always been colour-blind; she had been known to mend brown gloves with green thread and frequently made

[1] Bibl. No. 219.

[2] Bibl. No. 406.

other conspicuous mistakes; she was very musical and had repeated premonitory attacks of glaucoma; II. 8, the father of III. 7, was a Jew who came from Germany as a lad; originally a French polisher he became a traveller in jewelry and later a wine merchant; he used to give his daughters dress materials of very good quality but sometimes of "queer colour," but no one could say that he confused colours. III. 7 had three children, a son who died in infancy and two daughters with good colour vision of whom IV. 4 married a man with good colour vision and had five sons, V. 1—5, all of whom were tested and two of whom were colour-blind; IV. 4 and 6 were very musical; IV. 4 suffered from a progressive deafness which began when she was a young girl, with no history of otorrhœa. Of her colour-blind sons V. 1, aged 27, saw only "yellow and blue" in the spectrum, confused light green with buffs and yellows, rose with dark peacock-green and grey with green; V. $= \frac{6}{6}$. V. 5 confused pale green with buff, orange with green, and dark green with brown and red. V. 2—4 were carefully tested and found to be normal. III. 8 and 9 had normal colour vision. III. 10 and 12 were both dead but it was well known to their relations that they had the defect, all their six children were examined and found to be normal but the only married daughter of each of them had a colour-blind son; thus V. 6 saw "yellow and blue" in the spectrum, confused orange with green, pale green with buff, and rose with blues and purples; V. 7, 9, 10 and 12 had normal colour vision; V. 8 and 11 were too young to test; V. 13 confused pale green with yellow and buffs, and orange with various shades of brown.

III. 14 was in South Africa with his three daughters and four sons; none of them was adequately tested but they were closely questioned for Nettleship by III. 17 who visited them and was assured that none of them was colour-blind; V. 14 and 15 were believed to be normal. III. 16, herself normal, married a colour-blind man, III. 32, from another stock and had seven children who lived to adult life, of whom five were examined and found to be normal and two, IV. 27 and 28, were reported to be normal; IV. 27 had three daughters with normal colour vision and one son, V. 18, who was colour-blind. IV. 30 had been examined and was normal, she had four daughters who were all quite young and in Africa. III. 17, herself normal, had a daughter, IV. 36, who was normal, two sons, IV. 37 and 38, who were colour-blind, and a son, IV. 32, who was normal; IV. 37, aged 34 (1907), saw in the spectrum "orange and blue with perhaps green between them," and confused pale green with pale salmon-pink, yellows, buffs and pale grey; scarlet with dark greens and dark browns; and rose he matched with blues and purples. III 19 was normal and had two normal unmarried daughters, IV. 40 and 41. III. 22 had three children, a normal son, IV. 43, who had one daughter, a normal daughter, IV. 45, whose husband and two sons were tested by Nettleship and found to be normal, and a colour-blind son, IV. 44, who saw only "yellow and blue" in the spectrum and made characteristic mistakes in Nagel's test; his wife, IV. 50, a lady of good education and great intelligence, had normal colour vision and believed that both her parents, her brother and his daughter, also her sister and her seven children all had normal colour vision; she heard however from her mother in Canada that although her own husband, III. 31, was not colour-blind his mother, II. 14, was so. If we felt able to rely upon this statement we should have a colour-blind female with a normal son; there is however this much evidence in favour of the existence of colour-blindness in the family of IV. 50, she with her colour-blind husband, IV. 44, had a colour-blind daughter, V. 28, and three sons and two daughters with normal colour vision. V. 26 died young; the other members of this sibship were tested with great care by Nettleship who repeated the tests on the like twins, V. 27 and 28, five times on different occasions with invariably the same result that V. 27 was perfectly normal with regard to colour vision and V. 28 was typically colour-blind. The twins are so much alike that their own mother has sometimes confused them, moreover there was only one placenta for the two births; a very detailed description of their resemblances and in the repeated examinations of their colour vision is given in the original account of the case.

III. 32, the colour-blind member of the stock into which III. 16 married, saw only two colours in the spectrum, "yellow or red, and blue," and confused pale green with pink and drab, etc.; he had no knowledge of his parents and grandparents; one of his two brothers, III. 34, was known by his daughters, IV. 55 and 57, to have been colour-blind, the other brother, III. 35, died abroad and nothing was known of his colour vision. IV. 55 had a colour-blind son, V. 38, three daughters with normal colour vision and one son and daughter who were too young to test. One of the sisters of III. 32 had a colour-blind son, IV. 62. For further information as to this family history see the original account. No consanguinity recorded. (See Bibl. No. 355).

Fig. 442. *Snowball's Case.* Colour-blindness in two brothers, five sisters and one brother with normal colour vision. III. 7 reported that his father, II. 4, died aged 76; he was a reedmaker, the reeds were coloured at the edge with papers differently coloured according to the counts, and he never had any difficulty with colours, so far as George B., who as a boy used to spend a great deal of time with him at his work, knows. Nothing is known of the colour vision of his two brothers, II. 3 and 5, of his half-siblings, II. 1 and 2, or of his parents, I. 2 and 3. but III. 7 never heard his father speak of any relative as being colour-blind. The mother, II. 6, died aged 76; she was an expert in all sorts of needlework and so far as is known had no difficulty with colours; she had one sister, II. 7, who used to take III. 7 out sketching and painting and never showed any difficulty with colours; she had two half brothers and three half sisters by he same father and of these II. 8, who died aged 65, was a master painter and decorator above the average

in his vocation and not likely to be colour blind; II. 9 is an art master and paints pictures; II. 10, aged 70, is an artist and expert in coloured needlework; II. 12 and her two daughters are also painters; II. 13, aged 63, is clever at needlework. The father, I. 5, was a master decorator of very high class, also a collector of paintings and pottery. Of the siblings of III. 7, III. 2 is clever at crewel and coloured needlework; she has a son and two daughters who, as far as she knows, do not suffer from colour-blindness. III. 4 was tested by the recorder with wools, Stilling's Tafeln, Nagel's cards and the spectroscope; she made errors in all tests but corrected herself and at a third trial named all colours in the spectrum; her two children, Frank H., aged 30, and Florence H., aged 21, were also tested and said to be normal.

Harry B., aged 54, III. 5, was colour-blind; tested with wools he matched green with rose pinks, fresh pink and greys; with rose pink he matched mauve, light greens and light blues; with red he matched reddish browns, browns and dark yellowish green; with orange he matched yellowish greens, yellows, brownish yellow and one light scarlet; light green he named grey, rose pink he called grey, red he named correctly, orange was yellow; he made similar characteristic mistakes when tested with Stilling's Tafeln, Nagel's cards and Edridge-Green's beads; in the spectroscope he saw only "two strong colours" which he named yellow and blue. III. 5 first noticed that he was colour-blind as a young man in a cotton mill where he had to sort out yarn according to the different colours; he did this quite wrongly and got into trouble about it; grass and trees, he would say, are of a light brown colour; he cannot appreciate what is meant by green. In his work as surveyor he cannot distinguish on his plans plots marked red from those marked green. His vision was tested and was myopic; R.V. with – 10 D. Sph. – 1·0 Cyl. Ax. 150° = $\frac{6}{6}$; L.V. with – 10 D. Sph. = $\frac{6}{5}$ partly, crescents were present on temporal edge of discs. All the five living children of III. 5 were examined and demonstrated not to be colour-blind; one of them, IV. 7, had two children who were too young to test.

George E. B., schoolmaster, aged 51, III. 7, was tested and found to be normal; he had two daughters and a son who were all tested and classed as normal.

III. 9, Lucy B., aged 49, was tested; she did the wool test correctly and with confidence and named all colours in the spectrum; she was in poor health and there was not time to take her over the Stilling's and Nagel's tests a second time; she found difficulty in these tests, which is not at all infrequent, many patients correcting their errors when invited to repeat them. Her sister Sarah F., aged 47, III. 10, was also classed as normal though she also made mistakes in Stilling's and Nagel's tests on a first reading. III. 11, William B., aged 43, stated that he first noticed some difficulty with colour at the age of about 15 when handling postage stamps, but he cannot remember what were his particular difficulties then; later, at the age of 21, when he began to play snooker he confused green and brown, green and blue, and yellow and pink. On testing him with Edridge-Green's beads those he called red were all green except one pink; with green he placed reds and light and dark browns; with yellow he placed orange, yellowish green and pinkish yellow; blues he placed correctly; in the spectroscope he saw yellow, pale blue, dark blue; he made frequent and characteristic mistakes with wools, with Stilling's and with Nagel's tests. III. 11 had three sons and one daughter aged 8 to 15 years; all were tested and found to have normal colour vision. III. 13 was examined and found to have normal colour vision. No consanguinity. Hitherto unpublished.

Fig. 443. *Nabours's Case.* Fifteen cases of colour-blindness, one female affected, in six generations; only one member of the family has been definitely tested, those known to be affected revealed the defect by mistakes made in ordinary affairs of life, so that possibly there are other members, with some grade of defect, entered as normal in the pedigree. We have in this history two examples of the intermarriage of colour-blind stocks; thus the colour-blind male, III. 23, married a woman whose brother was known to be colour-blind; they have three sons and five daughters of whom only one son, IV. 34, was known to be affected and only one daughter, IV. 27, married; she had three sons and six daughters of whom one son, V. 19, was known to be affected and three of the four married daughters transmitted the defect; one of the daughters, V. 11, married a colour-blind male, V. 7, whose maternal uncle, IV. 6, and maternal grandfather, III. 3, were also colour-blind, they had four children of whom one daughter and one son, VI. 15 and 16, were colour-blind, one son and one daughter, VI. 12 and 14, were believed to be normal. There are a striking number of cases in this pedigree in which a colour-blind father has a colour-blind son, thus I. 7, II. 18, III. 3, III. 23, and V. 7 are all examples of such a sequence; we know that in two of the cases the mother was also a member of a colour-blind stock, in the other cases we have not enough information of the mother's history to assert that she was clear of the defect, but either certain colour-blind males have transmitted the defect to their sons or we have a remarkable coincidence in the pedigree of five colour-blind males married to five female members of colour-blind stocks.

IV. 6 was known to be colour-blind because he was unable to follow the coloured charts used in demonstrating the circulation of the blood; he changed his choice of profession from medicine to law on discovery of his defect. II. 18 revealed his defect when, having ordered a house to be painted, the paint ran out before the job was done, the additional paint furnished was not of the same colour but he said it was, and completed the house in two colours. III. 3 was a calvary officer; he wished to be transferred to the signal corps but was unable to distinguish between the different coloured lights or the flags used. III. 23 patched green wall paper with red, matching the pattern carefully in the different colour; his family laughed

over his mistake, but his brother, III. 21, agreed that the colour match was all right. IV. 34 was unable to tell a coloured picture of a sunset from an uncoloured one, he could only tell if colour were present by occasional brightness effects and was notorious for the combination of colours he wore together in his ties and shirts. V. 7 revealed his defect by his inability to use colour-tests in chemistry. V. 19 also had difficulty over colour tests in chemistry and did not know the colours of his sisters' dresses. VI. 15 was student and assistant in the recorder's department at one time and he remembered that she was unable to distinguish between green, red and blue crayons. We are indebted to the recorder for much additional information, for notification of three further cases of colour-blindness, IV. 6, VI. 26 and VI. 29, also for the personal examination of one case, VI. 16; of this case he writes: "I have simply tried him out twice with differently coloured charts, pictures, pencils, crayons, etc.; the best I can say is that he is badly muddled in respect to blue, green and red; he is pretty well along in college work, and has a good deal of experience in entomological work; as far as I am able to ascertain he is able to distinguish between colours largely by their shade or density, as photographic plates might make distinctions; for example, he marks a brown as green, a lavender as grey, a dark green as brown, a dark blue as purple, a light green as brown, a purple as blue, a tan as green, etc.; he was fairly consistent in these mistakes. However, this subject is better able to distinguish colours than his sister, VI. 15, who appears to be utterly unable to distinguish greens, reds and blues or any of the combinations." No consanguinity recorded. (See Bibl. No. 417, with additional information.)

Fig. 444. *Bell's Case.* Colour-blindness in three brothers; one brother and five sisters have normal colour vision; a maternal first cousin also affected. This history can unfortunately only be regarded as complete with regard to the single sibship IV. 16—24; a considerable amount of trouble has been taken to obtain accurate information about other branches of the family, but certain members discourage all enquiry and appear to resent any suggestion that they or their relations may have other than normal colour vision. The family is artistic and certain members have achieved considerable academic distinction; we are much indebted to IV. 23, a medical woman, who has been the source of our information; she writes of IV. 18: "I believe he always cherishes the conviction that we others are absurd in supposing there is so much difference between red and green; we have to pretend not to notice his defect too much; he is fond of gardening, scarlet geraniums and their green leaves are alike to him and he cannot easily see strawberries." IV. 22 was demonstrated to be colour-blind as a boy when an examination of colour vision was made throughout his school; "he was much vexed about it as he had always known he could not see colours." Of IV. 24 his sister writes: "it was a family joke in my infancy that if he cut his finger he spoke of the black bleed"; all three brothers commonly refer to pink and crimson as blue. They were all known to be colour-blind early in life for their father, III. 10, was a specialist in colour and was especially interested in the condition. IV. 23 is quite definite that she and her four sisters, also one brother, IV. 19, had normal colour vision. IV. 23 and several of her sisters as well as her mother and her maternal grandfather had considerable artistic ability. IV. 8, maternal first-cousin to IV. 23, was rejected by the Navy on account of colour-blindness; of another first cousin, IV. 5, we are told "half my family say of course he was colour-blind; I remember, if my memory can be trusted, that he was caught out by failure to see any difference in colour between a book and the ottoman it was lying on—one being red and the other green"; his immediate family however resented the suggestion that IV. 5 was colour-blind and all mention of it was suppressed before them; his widow also writes that his vision was absolutely normal in every respect, that he had a great appreciation of beautiful shades of colour and saw them just as she or anybody else did.

Of IV. 25 too there appears to be some doubt, and it was not found possible to obtain any information concerning his colour vision; IV. 23 felt that any questions would be resented and her letter on the subject to V. 5, a Naval Commander and known to have normal colour sense, remained unanswered. Thus all the positive information we have is that the two sisters, III. 7 and 9, had colour-blind sons. When we tried to find the source of the defect we had little success though many enquiries were made concerning members of the family in generations I and II and their descendants; IV. 23 was not at all sure that her maternal grandfather, II. 7, had normal colour vision, she had no definite evidence on the point but we were allowed to see some of his beautiful water colour sketches which were in her possession; they were all in very soft colours and similar in this respect to the early paintings of his daughter, III. 9; his granddaughter believed this to be characteristic of the period and it is certainly not possible to say from the paintings that II. 7 had any defect of colour vision, neither is it possible to say that his colour sense was normal; his monochromes were particularly good and rather a speciality with him, which is of interest in this connection but proves nothing. We have been unable to hear of any colour-blindness in the family of II. 8, the mother of III. 7 and 9; only one other member of her sibship married and his grandson, a scientific man, writes "I am not aware of any case of colour-blindness in any member, past or present, of my family, and I think its occurrence in recent times is most unlikely." Consanguinity. Hitherto unpublished.

Plate XXXIV. Fig. 445. *Bell's Case.* Colour-blindness in two Japanese brothers and probably in their grandfather. III. 1 appears to be a typical but rather severe case of red-green blindness, with shortening of the red end of the spectrum and extension of the violet end; we had not the apparatus to

test the limits of his spectrum, but he was tested at school some years ago in his own country, and was then the only one of his class who could not see the A line at the red end, but could see the two H lines at the violet end of the spectrum; tested with Houstoun's apparatus he had average sensibility to blue and always named it correctly, he was usually correct in naming yellow, but always hesitated; red he always called black or green, and green he called red or grey or green but was always uncertain; he sorted beads correctly and appeared to be very sensitive to difference of shade, but he was uncertain of the name of any colour except blue, and light blue he would call pink. The following table shows the result of testing with Edridge-Green's cards in daylight, and in artificial light shaded with orange, yellow, red, green, blue and purple silks.

No. of Card	Daylight	Orange	Yellow	Red	Green, Blue and Purple
1	Reads blue M.	Reads easily	Reads easily	Reads easily	Reads no letter on any card
2	Failed	Reads easily	Reads easily	Reads easily	,, ,, ,,
3	Failed	Reads easily	Failed	Reads easily	,, ,, ,,
4	Red yellow S.	Hesitating	Failed	Failed	,, ,, ,,
6	Reads orange brown G.	Reads easily	Reads easily	Failed	,, ,, ,,
7	Failed	Reads easily	Failed	Reads easily	,, ,, ,,
8	Failed	Reads easily	Failed	Reads easily	,, ,, ,,

The effect of distance on the colour discrimination of III. 1 was tested by Dr Percy Stocks with 10 cm. square coloured cards, placed at distances of 15, 10, and 6 metres respectively; the result is shown in the following table. Clearly, distance does to some extent modify his judgment.

Readings at different distances.

Test Cards	15 metres	10 metres	6 metres
(1) Dark red	Darker than (2)	Thinks it is red	Thinks it is red, much darker than (2)
(2) Dark green	Grey	Greenish grey	Thinks it is green
(3) Light green	Bluish grey	Green	Grey, slightly darker than (4)
(4) Pink	Light blue or pink	Light blue or pink	Red
(5) Blue	Blue	Blue	Blue
(6) Rose	Same as (2)	Might be brown, red or green	Thinks it is red

III. 1 had one brother, III. 2, who was also colour-blind, but the defect in his case was said to be less severe; his sister, III. 3, and her three children were believed to have normal colour vision; his parents were not known to have the defect, but his maternal grandfather was believed to have been colour-blind, on the basis of the fact that he did not know whether he was using red or black ink. No consanguinity. Hitherto unpublished.

Fig. 446. *Vogt's Case.* Colour-blindness, in a female, IV. 2, in her father, III. 3, and in her maternal grandfather, II. 7. IV. 2, aged 11 years (1921), was examined, and described as a dichromate; her only sibling, a boy aged 9 (1921), was also examined and found to have normal colour vision. III. 3 and II. 7 were both tested and found to have a similar defect to that of IV. 2; III. 3, believed his wife, III. 12, to have normal colour vision, but she was apparently not tested; two of her brothers, III. 14 and 15, and both her parents were tested; her mother, II. 8, had normal colour sense. The sister of III. 3, his father, II. 3, his maternal aunt, II. 4, and several other more distant relatives, were tested and found to be normal. IV. 11 was normal, IV. 12 and 13 were too young to test. No consanguinity recorded. (See Bibl. No. 409.)

Fig. 447. *Nagel's Case.* Seven cases of colour-blindness in three generations. A colour-blind man with a normal wife had five children, of whom the eldest, a son, was colour-blind, the second, a daughter, was normal, the third, a daughter, was colour-blind, the fourth, a daughter, was normal and the fifth, II. 5, a colour-blind daughter, married a normal man and had three colour-blind sons, III. 2—4. The eldest of these sons married a normal woman and had two children, a son and daughter, with normal colour vision. The vision in all the affected cases was dichromatic; the recorder personally examined II. 5, III. 3 and III. 4; he had reliable information of the other members. No consanguinity recorded. (See Bibl. No. 310.)

Fig. 448. *Cornaz's Case.* Colour-blindness in a brother and sister, III. 2 and 3; they had three sisters with presumably normal colour vision. III. 2, aged 42, was living in Montpellier; he had reddish hair and greyish blue irides with yellowish pupillary circles; he confused light green, very light brown, rose and light grey, also he confused darker greens with browns, reds and darker greys. He said that one of his sisters, who was not living in Montpellier, was colour-blind, but could give no details of her case; his four children, two sons and two daughters, and their mother, III. 1, all saw colours well and often corrected their father's errors. II. 2, father of III. 2, died when III. 2 was aged 10; he was said to have had good eyes; one of his brothers, II. 3, was myopic, a second brother, II. 4, had strabismus. II. 1 saw colours well. Among the relatives of III. 2 was a high official whose eyes were continually moving (? nystagmus). No statement is made concerning the family of II. 1. Nothing was known of the colour vision of I. 1 and 2. No consanguinity recorded. (See Bibl. No. 72.)

Fig. 449. *Pole's Case.* I. 1 was a native of Jersey; it was not known whether he was colour-blind; he had seven or eight sons, all of whom lived to adult life but died childless, and four daughters, one of whom, II. 8, died unmarried, the other three had colour-blind sons. The eldest daughter, II. 2, had, so far as was known, only one son, III. 2, who was so colour-blind that he nearly got into trouble by writing an official letter in two colours; III. 2 had two sons and two daughters, none of whom was colour-blind, but the younger daughter, IV. 3, had two sons and four daughters, of whom one son, V. 2, was excessively colour-blind. The second daughter, II. 4, had three sons and two or three daughters, of whom two sons, III. 4 and 5, were colour-blind, the defect was slight in the case of III. 4, more severe in III. 5; the descendants of III. 4 for three generations were believed to be free from the defect; III. 5 had sixteen children all believed to have normal colour vision, but five of his daughters transmitted the defect to their sons; thus IV. 16 had one colour-blind son, V. 20, one normal son and one normal daughter; IV. 18 had one colour-blind son, V. 24, two normal sons and several normal daughters; IV. 20 had one child, V. 29, a colour-blind son; IV. 22 had three colour-blind sons, four normal sons and three normal daughters; IV. 24 had one colour-blind son, V. 39, one normal son and two normal daughters; of the three affected brothers, V. 31, 34 and 36, the defect was most severe in V. 31 and the least severe in V. 34, it was first noticed in V. 36 at the age of five years. The unaffected brother, III. 9, of III. 4 and 5 and their sisters had numerous posterity, but no case of colour-blindness was known amongst them. The third daughter, II. 6, of I. 1 had several sons, of whom one was colour-blind; this line of descendants died out.

V. 36 sent the account of his family to the recorder; he wrote again thirteen years later, and reported that the descendants of his colour-blind relations had largely increased, but that he knew of no case of colour-blindness amongst his nephews or nieces, or his first, second and third cousins once removed. The daughter of V. 20 had lately married, but we have no knowledge of her children. No consanguinity recorded. (See Bibl. No. 235.)

Fig. 450. *Schiötz's Case VII.* Colour-blindness in I. 2 and in nine of his male descendants; his three sons and three daughters were, so far as was known, free from the defect, but all his daughters, II. 2, 3 and 6, transmitted the defect; thus II. 2 had one colour-blind son, one normal son, and three normal daughters; II. 3 had three normal sons and five normal daughters, two of whom had colour-blind sons, IV. 4, 5 and 9; II. 6 had three colour-blind sons, III. 14, 17, 18, and five normal daughters, two of whom had colour-blind sons, IV. 11 and 13. Many members of generations III and IV were examined; the reports of the condition in I. 2 left little doubt that he was colour-blind, though he was not tested. No consanguinity recorded. (See Bibl. No. 408.)

Fig. 451. *Bell's Case.* Colour-blindness in two brothers; one brother, a sister and both parents had normal colour sense; one sister was too young to test. III. 5, aged 13, was badly colour-blind; the defect was discovered during the routine test for colour discrimination, made in the Galton Laboratory with Houstoun's apparatus; from this test it would appear that he was capable of misnaming any of the four colours—red, green, blue and yellow—involved, but he was usually correct over blue and yellow and invariably failed over green; tested with Edridge-Green's cards he read correctly Nos. 4, 15, 19, 20; in eleven cases—1, 2, 3, 5, 6, 7, 8, 9, 12, 13, 14—he read the letter but named the colours wrongly, and he failed to name the letter at all in 10, 11, 16, 17, 18 and 21; he would usually call red green and green brown; if red and green came together he would distinguish between them, but would call one or other brown; blue and yellow he always knew. Sorting coloured beads he put pale green with yellow, light blue with light pink, mauve with blue, green with orange and orange with red. The boy knew of his defect and said that he always found difficulty in the painting classes at school. III. 6, aged 12, tested with Edridge-Green's cards read them all correctly and without hesitation. III. 7, aged 8, failed almost entirely with Edridge-Green's cards, he was correct in one case only—Card 15; in four cases, 1, 2, 4 and 6, he named the letter but gave the colours wrongly; sorting beads he confused browns, reds and greens. III. 8, aged 5, read through all the cards promptly and correctly. III. 9, aged 3, was too young to test.

Both parents were tested and found to have a normal colour sense; they had not been aware of the defect in their children and were inclined to question its reality; the father was a policeman and knew of no similar defect in any of his forebears; the mother was not in touch with her brothers and sisters, she knew of no defect in them or their families, but added that if she did know of colour-blindness in any

of them she would not like to speak of it; thus, attempts to follow up the family history met with no encouragement. II. 10 had no knowledge of the colour vision of her father, I. 1, but said that he worked on the line as a young man and later took a small farm. No consanguinity. Hitherto unpublished.

Fig. 452. *Snowball's Case.* A fully worked out pedigree by Dr Thomas Snowball, of Burnley, who examined, with Holmgren's wools, the spectroscope, Stilling's Tafeln and Nagel's cards, a large number of normal members of the family as well as two cases of colour-blindness.

III. 10, aged 47, had always been shortsighted and wore strong myopic glasses; when 12—13 years of age he worked in the warehouse of a coloured goods (cotton) manufacturer in Colne and when, aged 15, he got into the office he found that he was unable to work out a sheet of coloured patterns, he had to ask what colour it was he was dealing with, or he sometimes used the wrong one; this defect hindered his progress so that he gave up his post and took up a newsagency; later he went into a China business, and when a customer pointed to any article and mentioned the colour, III. 10 made a mental note of the colour and tried to associate it with the name used, but he was unable to carry the impression of that colour to another article. Pink, sky-blue and lilac as a class he could tell from blacks, browns and reds, but he could not tell the different shades of the one class or the other. Tested with Holmgren's wools he matched green with greens, stone colour, cream and buffs; with rose pink he matched rose pinks, blues, heliotrope; with red he matched reds and dark browns; he confused yellowish greens with orange. In the spectrum he saw "dark yellow, yellow, blue and dark blue." With Stilling's Tafeln he did not recognise Groups 2, 4, 5 (except the first Tafel), 6 (except the big 5, 9, 2, 6, 1 and 2 in the upper of the last two Tafeln), 7 and 8; he read Group 9 easily. With Nagel's cards, for A he said red or reddish in 1, 2, 5, 6, 10, 11, 14; only red in 6, 14; only green in 3 and 9; only grey in 15. For B in No. 1 he saw red and green; in No. 2 he saw slate and brown; in No. 3 he saw green and red; in No. 4 he saw black and red.

III. 10 reported that his brother, III. 2, who died aged 52, was, from what he could remember, somewhat like himself as regards colours, but not so bad; his sister, III. 3, aged 53, was examined and was not colour-blind; she had one son, IV. 9, aged 20, who was also tested, nothing noteworthy was found, except that in Nagel B. 3 he saw green only; he had one infant daughter, V. 2, aged 8 months. III. 10's second sister, III. 5, aged 51, was examined and was not colour-blind; she had one son, IV. 10, aged 20, who wore strong myopic glasses and who was colour-blind; thus with Holmgren's wools he matched green with greens, mauve, brown, and several stone and light green colours, after much hesitation; with rose pink he matched rose pinks, lilac, light heliotrope and light blue; with full red he matched reds and one brown; with orange he placed yellowish greens. With Stilling's Tafeln IV. 10 read Groups 1 and 9—12 promptly, the other Groups were either not read at all or only after much hesitation and with errors. With Nagel's cards, he sees in A red or reddish in 2, 6, 15 and ?11; red only in 3, 6 and ?12; green only in 5, 13, 14, 1, 9 and grey only in none; in B, 1 he called green, 2 he called brown, 3 was green and brown, and 4 he called red and brown. In the spectrum IV. 10 saw "darker yellow, yellow, blue, darker blue." The third sister, III. 7, of III. 10, aged 50, and her two daughters, IV. 11 and 12, aged 23 and 14 years respectively, tested with wools, Stilling's Tafeln, Nagel's cards and the spectroscope, were found to have normal colour vision.

III. 10 was twice married and had one daughter by each wife; one of these, IV. 13, was tested and found to be normal; in the spectrum she named red, yellow, green, blue, indigo.

II. 4, the mother of III. 10, died aged 74, she was not colour-blind so far as was known; she knew about the colour-blindness of III. 10, but he never heard her remark that she had ever known anyone of her family similarly affected; she was one of a sibship of eleven, one of her sisters, II. 11, was examined, also many of this sister's children and grandchildren.

II. 3, a cornmiller, the father of III. 10, was killed when III. 10 was an infant, but he had never heard his mother remark that his father was colour-blind, nor had he ever heard of colour-blindness in his paternal aunt and uncle.

III. 2, according to the statement of his wife and family, had been a joiner, but he was also in the china business, and made mistakes in the colours of cups without knowing that he had done so; there were only two colours he confused, "celast" (a blue green) and pink; he always got someone to buy his ties for him because he said he couldn't tell the colours; his wife never heard him speak of his parents being colour-blind as far as she can remember. III. 2 had four daughters and two sons, of whom three daughters, IV. 2, 3 and 7, and one son, IV. 6, were tested and were not colour-blind. IV. 2 had one daughter, aged 14 months.

II. 11, aunt to III. 10, was examined, aged 79; she did not know of any case of colour-blindness in her parents, I. 3 and 4, or in her siblings; her answers to the tests were at times incorrect, but she was so feeble that it was impossible to spend a long time over the tests and the results were not satisfactory, and could not be insisted upon; she had eleven children and twenty-eight grandchildren, of whom many were examined. III. 30, aged 43, did the tests with wools, Stilling's Tafeln and Nagel's cards correctly; he named red, green and blue in the spectrum; he had never heard it mentioned that his father was colour-blind; he had four children, aged 17, 7, 5 years and 10 months respectively, who were not examined. III. 32, aged 42, did all the tests correctly and named red, green, blue and purple in the spectrum. III. 33,

aged 38, worked in a coloured goods factory and had no difficulty with colours at his work; he did the tests correctly and named red, green, blue and purple in the spectrum; his two sons, IV. 43 and 44, aged 10 and 8 years respectively, passed the tests correctly, with the exception of IV. 44, who had some difficulty with certain of Stilling's Tafeln; he named red, green, blue and purple in the spectrum. III. 22 died, aged 45; three of his four children were tested and were not colour-blind though there was some hesitancy in certain cases; each named only red, green, blue and purple in the spectrum, though IV. 27 and 30, when asked to look carefully, noted a yellow tinge after red; IV. 27 had one daughter, aged $2\frac{1}{2}$ years. III. 20, and three of her four children, were tested and did the tests correctly, including the spectrum. III. 24, female, aged 49, had suffered for a number of years from a chronic iridocyclitis; she matched purples with red and some pale browns with orange wools; she could not tell any of the figures in any of the Stilling Tables; in the spectrum she named orange, green and blue. Two of her three boys IV. 31—33 were tested, both did the wool, Stilling and Nagel tests correctly and both named only red, green and blue in the spectrum; they were aged 21 and 19 years respectively. III. 26, aged 46, and her two children, a son aged 23 and a daughter aged 12, did all tests correctly. III. 18, female, aged 55 years, did the wool and Nagel tests correctly, made a few errors in Stilling and named red, fawn, green and blue in the spectrum; her son, IV. 20, aged 33, was a coloured cotton manufacturer, he did all tests correctly; he had two daughters, aged 6 and 3 years respectively, who were not examined; IV. 21, daughter of III. 18, had some difficulty with Stilling and Nagel tests and did not name yellow in the spectrum. III. 17, aged about 57, was in New Zealand and not examined. III. 28, aged 44, and her three children, IV. 36—38, aged 16 and 12 respectively (the two girls were twins), all did the wool and Nagel tests correctly, III. 28 and IV. 38 made errors in the Stilling test and omitted yellow in naming the colours of the spectrum. III. 35, aged 34, and two of her four sons, aged 8 and 7 years respectively, were tested; they seemed a little uncertain over some of the wools and over Stilling; all three named only red, green, blue and purple in the spectrum. II. 6, brother to II. 11, was twice married; he had two sons, III. 13 and 14, by the first marriage and one son, III. 15, by the second; III. 15, aged 42, was examined and found normal, his two children, aged 4 and 2 years respectively, were not seen; the two children of III. 13, a male aged 30 years and a female aged 18, were tested and found normal with wool, Stilling and Nagel tests; in the spectrum omitted to name yellow. No consanguinity recorded. Hitherto unpublished.

Plate XXXV. Fig. 453. *Nettleship's Case.* Family A. Three colour-blind males in a sibship of six. II. 2 (William S.), aged 57 (1880), had well-marked congenital colour-blindness; he confused reds with greenish-browns, etc., and said that he could not properly tell railway signals; refraction myopic, about 2 D.; V. $= \frac{6}{9}$ partly with each eye; striae in lenses. II. 2 is the second born of three colour-blind males, he had also three sisters, but the order of birth in the sibship was not noted. II. 1, the elder brother, was very badly colour-blind, II. 3 was said to be only slightly colour-blind. The parents were believed to be normal by II. 2, but he had no definite information. No consanguinity recorded. Hitherto unpublished.

Fig. 454. *Burd's Case.* Three brothers are unable to distinguish red from green at a distance, but have no difficulty in doing so near to; one of them had to leave the merchant service on account of this defect though he had passed the examination in colours; it was only some time afterwards that he accidentally discovered himself to be colour-blind at a distance. The three affected brothers had four sisters with normal colour vision. No consanguinity recorded. (See Bibl. No. 329.)

Fig. 455. *Wilson's Case.* Colour-blindness in II. 1, Mr N., in his brother, II. 2, and in his cousin, II. 4; a sister, II. 3, had normal colour vision. No consanguinity recorded. (See Bibl. No. 76, p. 36.)

Fig. 456. *Wilson's Case.* Colour-blindness in the Rev. Mr E., II. 1; his brother, II. 2, and his two uncles were similarly affected; his sister, II. 3, had normal colour vision. No consanguinity recorded. (See Bibl. No. 76, p. 36.)

Fig. 457. *Wilson's Case.* Mr X. was reported to be colour-blind and to have five brothers all of whom were similarly affected. No consanguinity recorded. (See Bibl. No. 76, p. 71.)

Fig. 458. *Wilson's Case.* Colour-blindness in a father and two of his sons. II. 1, a carver and gilder, appeared to confound all colours; he was a good draughtsman but painted a head with the face muddy green and brought a packet of emerald green which he conceived to be vermilion. II. 2, an artist by profession, knew no difference by gas-light between the variously coloured bottles in a druggist's window and was unable to distinguish the red from the green signal-lamp at a railway station. The father, I. 2, was reported to confound all colours. No consanguinity recorded. (See Bibl. No. 76, p. 34.)

Fig. 459. *Magnus's Case.* A normal female, I. 2, who had colour-blind brothers, I. 3, had also a colour-blind child, II. 1. No information is given of the sex of II. 1 or of the number of the colour-blind brothers or of the parentage of I. 2. Two other similar family histories were known to the author. No consanguinity recorded. (See Bibl. No. 121.)

Fig. 460. *Magnus's Case.* Two sisters with presumably normal colour vision had each a colour-blind son. No further information is given. Another similar family history was known to the author. No consanguinity recorded. (See Bibl. No. 121.)

Fig. 461. *Magnus's Case.* Colour-blindness in four brothers whose only sister had normal colour vision. No information is given of the parents. No consanguinity recorded. (See Bibl. No. 121.)

Fig. 462. *Magnus's Case.* Colour-blindness in a father, I. 1, and his two sons, II. 1 and 2. No further information is given. No consanguinity recorded. (See Bibl. No. 121.)

Fig. 463. *Magnus's Case.* Colour-blindness in a father, I. 1, and in his three sons, II. 1, 2 and 3. No consanguinity recorded. (See Bibl. No. 121.)

Fig. 464. *Cohn's Case.* Colour-blindness in two brothers in a sibship of nine. II. 2, examined aged 19, was classified by the author as red-green blind; he called rose wool light green and saw only yellow and blue in the spectroscope; the spectrum was not shortened. He had brown hair and irides, normal fundi and good vision for form; one elder brother was also colour-blind. Parents were not related; no knowledge of their colour vision. No consanguinity. (See Bibl. No. 129, p. 21.)

Fig. 465. *Cohn's Case.* Colour-blindness in a Jew aged 18 and possibly in his brother also; his three sisters had normal colour vision; II. 1 took blue for rose and saw yellow and blue only in the spectrum, no shortening of spectrum; he had brown hair and irides; good vision for form and normal fundi. No knowledge of the colour vision of the parents. No consanguinity. (See Bibl. No. 129, p. 22.)

Fig. 466. *Cohn's Case.* Colour-blindness in a Jew aged 18 and in his elder brother; two brothers and one sister had normal colour vision. II. 1 took blue for rose and saw only yellow and blue in the spectrum, no shortening of spectrum; he had dark brown hair and irides; good vision for form and normal fundi. The parents, I. 1 and 2, had normal colour vision. No consanguinity. (See Bibl. No. 129, p. 24.)

Fig. 467. *Cohn's Case.* Colour-blindness in a father, I. 1, and in his son, II. 1; the mother and two sons had normal colour vision. II. 1, a Jew aged 15, had black hair and blue grey irides; he took blue and grey for rose and saw only blue and greenish yellow in the spectrum, no shortening of the spectrum. No consanguinity. (See Bibl. No. 129, p. 30.)

Fig. 468. *Cohn's Case.* Colour-blindness in a father, I. 1, and in his son, II. 1; three daughters and one son had normal colour vision. II. 1, aged 10, took green for rose; he saw yellow and blue in the spectrum, no shortening of the spectrum; he had fair hair and blue irides and normal fundi. No consanguinity. (See Bibl. No. 129, p. 36.)

Fig. 469. *Cohn's Case.* Colour-blindness in two brothers; parents and three brothers have normal colour vision. II. 2, aged 14, sometimes took rose for grey-green and green for grey, he had dark hair and brown irides; fundi were normal; refraction was hypermetropic in each; left eye was amblyopic and had convergent strabismus. No consanguinity. (See Bibl. No. 129, p. 66.)

Fig. 470. *Cohn's Case.* Colour-blindness in two brothers and in their maternal uncle; parents with normal colour vision; seven siblings who had died were believed to have had normal colour vision. II. 1, aged 10, had blue-grey irides, light brown hair and normal fundi; he took blue for rose and saw yellow and blue only in the spectrum; his younger brother, II. 2, and his mother's brother, I. 3, were also colour-blind. No consanguinity. (See Bibl. No. 129, p. 71.)

Fig. 471. *Cohn's Case.* Colour-blindness in two brothers in a sibship of four. II. 1, aged 10, a Jew with brown irides and dark brown hair, took blue-green for rose and was uncertain about all colours; his 6-year old brother was also colour-blind. No knowledge of colour vision of parents. No consanguinity. (See Bibl. No. 129, p. 93.)

Fig. 472. *Cohn's Case.* Colour-blindness in two brothers; the parents and two brothers had normal colour vision. II. 1, aged 13, had brown hair and grey irides; fundi normal; he took blue for rose; in the spectroscope he saw green, yellow, dark yellow, later named red, and blue. II. 2, aged 9, was also colour-blind. No consanguinity. (See Bibl. No. 129, p. 99.)

Fig. 473. *Cohn's Case.* Colour-blindness in two brothers whose parents had normal colour vision. II. 1, aged 10, took green wool for rose sometimes; in the spectroscope he saw red, yellow and blue. II. 2, aged 9, sometimes took green for rose, he also saw red, yellow and blue in the spectrum; both brothers had brown hair and normal fundi. II. 1 had blue irides, II. 2 had brown. Parents were known to be related. Consanguinity. (See Bibl. No. 129, pp. 117 and 119.)

Fig. 474. *Cohn's Case.* Colour-blindness in two brothers; the parents, two brothers and two sisters had normal colour vision. II. 1, aged 22, with fair hair and blue irides, took green for rose; he saw yellow and blue in the spectrum; he had myopia with a posterior staphyloma. No consanguinity. (See Bibl. No. 129, p. 133.)

Fig. 475. *Cohn's Case.* Colour-blindness in a father and in three of his sons; six other children had normal colour vision. II. 1, a Jew aged 19, with brownish black hair and brown irides, took blue for rose; fundi normal. No consanguinity. (See Bibl. No. 129, p. 138.)

Fig. 476. *Cohn's Case.* Colour-blindness in II. 1, aged 11, who called grey and blue-violet rose; he had fair hair and blue-grey irides; fundi normal. Parents had normal colour vision but the mother's brother, a Jew, was colour-blind. No consanguinity. (See Bibl. No. 129, p. 154.)

Fig. 477. *Cohn's Case.* Colour-blindness in two brothers; another brother, two sisters and the parents had normal colour vision. II. 1, a Jew, aged 13, took light green for rose and blue-green for orange, yellow he constantly called blue; he had brown hair and irides; fundi normal. II. 2, aged 6, was similarly colour-blind. No consanguinity. (See Bibl. No. 129, p. 158.)

Fig. 478. *Cohn's Case.* Colour-blindness in two brothers of a sibship of six; parents and four siblings had normal colour vision. II. 3, aged 12, took violet for rose and yellow for blue; he had fair hair and light brown irides; fundi normal. The parents were cousins. Consanguinity. (See Bibl. No. 129, p. 162.)

Fig. 479. *Wilson's Case.* Colour-blindness in two brothers and in "several other members" of the family; two brothers had normal colour vision and no female member had the slightest trace of the defect. II. 1, Mr N. of Torquay, reported that he had a distinct perception of the whole spectrum with the exception of the red and green which seemed to him to be a very near repetition of the same colour; the flowers of a fuchsia, the berries of mountain ash and holly were only distinguishable to him by their tone and form; pale green and pink appeared to him to be slightly different shades of the same colour; he confused also crimson and dark green; in a failing light scarlet resembled black; he said that he would on no consideration undertake to distinguish the ordinary signals used on railways and had frequently remarked that this was a very likely source of accidents. II. 2 when a child once picked up a red-hot coal asking what that funny green thing was. II. 1 believed that his defect was an advantage to him when engaged upon crayon drawing. No consanguinity recorded. (See Bibl. No. 76, pp. 28—30.)

Fig. 480. *Niemetschek's Case.* Colour-blindness in two brothers; no knowledge of colour vision in the parents. Dr F., II. 1, said that for him green did not exist and that green he always called red; moreover he did not always distinguish red for he called rose red. Sky-blue and carmine-red he called brownish; his brother, who was dead, was said to have had the same defect. No consanguinity recorded. (See Bibl. No. 97.)

Fig. 481. *Seebeck's Case.* Colour-blindness in two male first cousins whose mothers were sisters. II. 1, aged 18, with blue-grey eyes and light brown hair, had known since childhood that he could not rightly distinguish colours; he confused rose-red and sky-blue; shades of green he called brown, red, orange, or yellow; his parents and his only sibling, a sister, had normal colour vision. His mother's sister had a son, II. 3, who was also colour-blind. No consanguinity recorded. (See Bibl. No. 61, pp. 202—211.)

Fig. 482. *Spurzheim's Case* (Quoted by Gall). Spurzheim saw in Edinburgh three brothers and their first cousin, all of whom were unable to distinguish between green and brown. No further information is given. No consanguinity recorded. (See Bibl. No. 49.)

Fig. 483. *De Fontenay's Case* 182. Colour-blindness in father and child; the type and severity of the affection was similar in each case. No consanguinity recorded. (See Bibl. No. 140.)

Fig. 484. *De Fontenay's Case* 190. Colour-blindness in father and child; the child was aged 13 and had dark brown eyes; both were cases of red-blindness. No consanguinity recorded. (See Bibl. No. 140.)

Fig. 485. *Stilling's Case.* II. 1, an actor, was red-green-blind; he had several brothers similarly affected; no statement is made concerning the parents or normal siblings. No consanguinity recorded. (See Bibl. No. 114, p. 29.)

Fig. 486. *Stilling's Cases I and II.* Colour-blindness in two brothers and in several other members of the family; it is not clear whether these other affected members of the family are of the same sibship as the two brothers or are more distant relatives. II. 2, a tobacco worker, confused red, green and brown; he matched blue and rose threads, light blue and light violet, blue and purple; in the spectroscope he saw yellow and blue. II. 3 could not recognise green, he was better able to distinguish red but was always in doubt as to whether the different shades were other colours; he knew a pure blue and a pure yellow; lilac and orange puzzled him; he put rose threads with lilac and sky blue, blue threads with purple and violet and called them all blue; he saw yellow and blue in the spectroscope. The eldest brother, II. 1, and the father, I. 1, had normal colour vision. No consanguinity recorded. (See Bibl. No. 114.)

Fig. 487. *Stilling's Case X.* Colour-blindness in two brothers. II. 1, a gymnast, confused red, green, brown and blue; a younger brother was also affected. Both parents had normal colour vision. No consanguinity recorded. (See Bibl. No. 114.)

Fig. 488. *Stilling's Cases IV and V.* Colour-blindness in three brothers, two of whom were tested; each saw yellow and blue in the spectrum. II. 1, a doctor, knew nothing of green, but red appeared to him a darker shade of yellow, or again red he would call dark blue. II. 2 found it impossible to distinguish red and green. No information is given of the parents or of normal members of the sibship. No consanguinity recorded. (See. Bibl. No. 114, pp. 19—20.)

Fig. 489. *Stilling's Case VI.* Colour-blindness in two brothers, II. 2 could never distinguish red from blue or green from yellow. His younger brother, II. 3, was similarly affected. The mother appears to have been seen, but no statement is made as to her colour vision; one brother is reported to have had normal colour vision. No consanguinity recorded. (See Bibl. No. 114.)

Fig. 490. *Sommer's Case.* Colour-blindness in two brothers, II. 1 and 2; their five siblings and their parents, I. 1 and 2, also the relatives of I. 1 and 2, had normal colour vision. II. 2, Dr G., was myopic; he could distinguish scarlet, yellow and blue; rose red and its shades seemed to him like blue; orange he confused with red or yellow or green; dark blue he matched with sky-blue and violet; the rainbow seemed to him a mixture of red, yellow, green and blue. The defect in II. 1, elder brother of II. 2, was similar. No consanguinity recorded. (See Bibl. No. 53.)

Fig. 491. *Cornaz's Case.* I. 2 married twice; by her first husband, a Frenchman, she had three children of whom two died and nothing was known of their colour vision; II. 3 was living and was colour-blind; he was aged about 20, with chestnut hair and light greyish-brown irides; he called light and dark orange red, and light and dark red he called red, green or brown; blues and yellows were distinguished. By her second husband, a Swiss, I. 2 had three children of whom one son, II. 5, was colour-blind, his elder brother and his sister distinguished colours well. II. 5, aged about 15, had brown hair and irides; a paternal uncle wished to give him painting lessons but had to give up the project on account of his defective colour sense; he confused red, green and brown, light rose he called light blue. The defect in colour sense was similar but not identical in the two half-brothers, and II. 5 would often laugh at the mistakes made by II. 3. I. 2 and 3 distinguished colours well and there were no known colour-blind members of the mother's family. No consanguinity recorded. (See Bibl. No. 72.)

Fig. 492. *Schirmer's Case.* Colour-blindness in three brothers whose parents and sisters had normal colour vision. II. 1 noticed his defect particularly in the evening and in a dim light; he confused green, brown and red, also violet, blue and purple; on being tested with coloured papers he made no mistakes with blue and yellow; he had light blue irides and good vision for form. II. 2 was tested and made very much the same errors as II. 1. No consanguinity recorded. (See Bibl. No. 112.)

Fig. 493. *Jeffries's Case.* Colour-blindness in three brothers II. 1—3; II. 4 was too young to test; no information is given of the parents. No consanguinity recorded. (See Bibl. No. 132, p. 63.)

Fig. 494. *Nettleship's Case.* This family history was worked out by Nettleship, with the help of Dr Arnold Lyndon, who subsequently added to the facts; Usher prepared the pedigree for publication.

I. 1, who died aged 69 (1871), is believed to have had good colour vision; his wife, from Normandy, died aged 61 (1863); they had two sons and two daughters in addition to several children who died in infancy; of the sons, II. 4, believed to have been normal, died over 60; his children, III. 13 and 14, and grandchild, IV. 5, were reported to be normal. II. 8 died unmarried, aged 25; he was believed to have had normal colour vision. Of the daughters of I. 1 and 2, II. 3 had eight children, of whom III. 1 died in infancy; III. 2, a son, died aged 58, was not colour-blind; III. 3, a daughter, with two daughters, IV. 1 and 2, whose colour vision was not known to be affected; III. 5, unmarried, had been lost sight of; III. 6 was in a lunatic asylum, and nothing was known of her colour vision; III. 7 was undoubtedly colour-blind, according to his own and his cousin's (III. 12) accounts; III. 8 died, her son, aged about 23, had a hare-lip, nothing was known of his colour vision; no statement is made concerning the colour vision of III. 10 and of her son, IV. 4.

II. 6 was married at the age of 17, her husband was a diamond merchant with perfect colour vision; they had two married daughters with colour-blind sons, and three colour-blind sons. III. 15, a daughter with no children; III. 16, a daughter with eight children, IV. 6—13, of whom IV. 6 and 11 died in infancy; IV. 7, tested at the age of 25, had normal colour vision; IV. 8 died aged 2 years; IV. 9, a male twin with IV. 10, was tested by Nettleship and found to be colour-blind; he saw yellow and blue in the spectrum and was tested with wools and Nagel's tests; IV. 10 died aged $2\frac{1}{2}$; IV. 12, in the army, is colour-blind; IV. 13 was tested and found to have normal colour vision. III. 18 was believed to have had normal colour vision, he was in his father's jewel business where he had to sort stones, and he made no mistakes; III. 19 died aged 25; III. 20 died in infancy; III. 21 had seven children, of whom IV. 14, a son, aged 25, was tested by Dr Lyndon, and found to be colour-blind, his siblings IV. 15—20 were all believed to have normal colour vision, but only IV. 15 and 17 were tested, and IV. 19 died, aged $3\frac{1}{2}$ years. III. 23 was examined and found to be colour-blind, he and his sister, III. 21, have no ear for music; III. 24 was abroad and is undoubtedly colour-blind; III. 25 was tested, aged 39, and was markedly colour-blind; he had no ear for music and Dr Lyndon describes a sort of fixity or want of mobility of features in his facial expression; he had two children, a son and daughter, who were too young to test. No consanguinity recorded. (See Bibl. No. 370.)

Fig. 495. *Bronner's Case.* Six cases of colour-blindness in males in a small pedigree of four generations. I. 1, Mr M., a learned German chemist who died aged 50, was colour-blind; he had two daughters, II. 2 and II. 3, whose colour vision was normal.

II. 2 had three sons, of whom the eldest and youngest (a painter) had normal colour vision, III. 2 was colour-blind; he could see yellow, blue and red, but not other colours; green, brown and orange puzzled him very much; further, he had light brown hair with greenish grey eyes and had no great talent for music or drawing.

II. 3 had three sons all of whom were colour-blind; thus III. 5, short-sighted, with red hair and greyish blue eyes, never found strawberries in the wood so readily as other boys, from his inability to distinguish the colour of the berries from that of the leaves; he could see yellow, blue and red, but saw no difference

between brown and green; he arranged some shades of red, dark green and brown wools into one bundle which he believed to be red; he had a son and four daughters, who were believed to be normal. III. 7, keen-sighted, with dark brown hair and eyes, could not distinguish the red colour of strawberries from the green of their leaves; he matched grass green with yellow and bluish green with red or grey; he had four children, of whom one, IV. 3, a boy aged 7 years, appeared to have inherited the defect. III. 8 could only distinguish with certainty the blue of the corn-flower and the yellow of brimstone; blood-red and scarlet he classed with green and brown; he could see no difference between green and brown; in the rainbow and solar spectrum he could see only blue and yellow. The father of III. 5, 7 and 8 had normal colour vision. No consanguinity recorded. (See Bibl. No. 77.)

Plate XXXVI. Fig. 496. *Wilson's Case.* Mr D., II. 2, discovered in boyhood that he was colour-blind; when middle-aged he reported that yellow was the brightest colour, blue nearly as bright, and that he could see distinctly only these two colours in the rainbow; red he could distinguish when bright, but delicate shades he confused with stone colour or grey; green he had no distinct perception of, according to its different shades it appeared to him black, brown, red, yellow, blue or grey. He could not distinguish at any distance the ripe cherries on a tree, or strawberries, from their leaves; the flowers of a scarlet geranium he could not see at a distance by daylight, but by candlelight there appeared to be a marked contrast between them and their leaves.

Mr D. was an educated, highly intelligent person, and he was tested by Wilson with the colour diagrams in Hay's *Nomenclature of Colours*, with coloured papers, powders, vegetable infusions and pieces of glass; the result of these tests was in accord with his own statement of his defect given above. The father of Mr D., I. 1, his two brothers, II. 3 and 4, his sister, II. 5, and his sister's son, III. 2, were also colour-blind; his own children had normal colour vision; no statement is made as to whether he had any normal siblings, or whether his affected sister had any unaffected children. No consanguinity recorded. (See Bibl. No. 76, pp. 14—16.)

Fig. 497. *Wilson's Case.* The Countess of D., II. 2, with brownish-grey irides and excellent vision for near and distant objects, had been conscious of colour-blindness since her early youth; in the rainbow she saw only yellow, and in all objects she pronounced on this colour with most confidence; she saw blue clearly, but some shades of lilac seemed to her blue; red, green, black, brown and lilac she did not venture to name confidently, and greens and drabs were to her the same colour; mountain ash or holly berries were indistinguishable from their foliage; in sorting worsteds, she was liable to mix up all the lightest shades of colours. The father, I. 1, of II. 2, one of her sons, III. 3, and two of her nephews were colour-blind; her daughter had normal colour-sense. No information is given of the siblings of II. 2, nor is it made clear whether the two colour-blind nephews are brothers; further, we have no knowledge of the family of I. 2. No consanguinity recorded. (See Bibl. No. 76, pp. 36, 37.)

Fig. 498. *Nettleship's Case.* Colour-blindness in a female; her father was affected similarly, also two of her eight brothers and her only son, who survived early childhood; one of her nephews also was colour-blind; her four sisters were believed to have normal colour vision; but the eldest of the four sons of her eldest sister was colour-blind. III. 14 was examined by the author and could hardly distinguish between red and green; further information of the history was given by this boy's father, who reported that the mother, II. 16, was unable to distinguish red on a green ground, and that the defect in her two brothers, II. 12 and 14, was much more severe than in her case. Of the six children of II. 16 two sons were still-born, one son, III. 12, died young, III. 15 was a miscarriage, III. 16, a daughter, had normal colour vision, and III. 14 was the colour-blind son. Three normal brothers of II. 16 were married and had normal children; one normal sister, II. 8, had two sons and three daughters, all believed to have normal colour vision. No consanguinity recorded. (See Bibl. No. 302.)

Fig. 499. *Pliny Earle's Case.* Colour-blindness in II. 1; his brother, II. 2, and two nephews, III. 1 and 2, were also affected; it is not clear whether the nephews belong to the same or different sibships, nor whether they are sons of the affected II. 2 or of an unaffected sibling of II. 1 and 2; no information is given of the parents I. 1 and 2.

II. 1 reports that he cannot see red fruit on a tree at any considerable distance so as to distinguish it from the foliage; he has sometimes mistaken light green for drab; he could recognise yellow and blue of moderate depth at a great distance, but at any considerable distance he might not know whether a red was really red or deep green or brown or olive. No consanguinity recorded. (See Bibl. No. 68.)

Fig. 500. *Sommer's Case.* Colour-blindness in two brothers and in their maternal uncle. III. 1 (Sommer himself) took blue for red, green for brown, orange for light brown; green, yellow and violet he confused with shades of red; crimson, purple and lilac he only knew by name and could form no idea of them, as he could of yellow and black; red umbrellas he compared with the blue of the sky and almost daily he made mistakes over green, red and brown clothing; the rainbow appeared to be a mixture of yellow and blue. III. 2, aged 36, called red sealing-wax green, light red he called blue, and he often mixed brown and green. Their maternal uncle, II. 3, was affected in the same way and was very short-sighted. No consanguinity recorded. (See Bibl. No. 53.)

Fig. 501. *Jeffries's Case.* Colour-blindness in three brothers who had two brothers with normal colour vision; none of the children of the affected brothers were colour-blind. No information is given of the parents. No consanguinity recorded. (See Bibl. No. 132, p. 63.)

Fig. 502. *Jeffries's Case.* Colour-blindness in a lad, III. 1; his grandfather, I. 2, and his great-uncle, I. 3, were also affected. Presumably his affected great-uncle was brother to the grandfather, but he is not stated to be. Information is very incomplete; we are not told of any normal relations, nor whether the affected grandfather was on the maternal or paternal side of the family. No consanguinity recorded. (See Bibl. No. 132, p. 63.)

Fig. 503. *Jeffries's Case.* Colour-blindness in two brothers and in their maternal grandfather; their three sisters had normal colour vision. II. 2, whose father was colour-blind, reported that her two boys, III. 1 and 2, "do not observe when a flaming bush of *Pyrus Japonica* is in flower, unless near enough to discern the form of the flower"; one of them, on having his attention called to the flowers, said that he now saw them but that they were not so bright as the leaves. The mother first noticed the defect in her elder boy when he was aged five and was unable to see the columbines in a field which were delighting his sisters; the two boys were quite unable to learn to distinguish light green from yellow brown, and appeared to see no difference between them; crimson they always called blue. No consanguinity recorded. (See Bibl. No. 132, p. 18.)

Fig. 504. *Bell's Case.* Colour-blindness in the only male of a sibship of three and in two of his maternal uncles. III. 3, an engineering student at University College, London, seen aged 20, was found to be colour-blind, he confused red and palish green beads, red and orange, brown and green, pale green and pale yellow; dark green he confused with crimson and purplish red; with Houstoun's test for sensitivity of colour discrimination he detected blue very readily, but was uncertain about all other colours; tested with the first eight of Edridge-Green's cards he failed in some respect in each, he read the letter on cards 1, 2, 4, 6 and 7, but named the colours wrongly, on the other cards he failed to read a letter at all; his two sisters were believed to have normal colour vision. II. 1 was said to be blind with regard to red and green; his defect was discovered when he was quite a small boy by his mistaking orange juice for blood; also he frequently stated that he could not distinguish between the flower and foliage of a dark red rose. II. 2 was believed by the family to be less severely colour-blind than his brother, it was only with regard to pale shades of colours that he made mistakes. The two brothers, II. 5 and 9, and four sisters of this sibship were believed to have normal colour vision. None of this sibship had been tested, but there appears to be no doubt of the defect in the cases II. 1 and 2, and presumably, if there is defect in the colour vision of other members, it is of slight degree. The parents I. 1 and 2 were believed to be normal, and no cases of colour-blindness had been known to occur in the antecedents of I. 2. No consanguinity recorded. Hitherto unpublished.

Fig. 505. *Jeffries's Case.* Colour-blindness in a female, I. 1, and in her daughter's son, III. 1; no further information is given. No consanguinity recorded. (See Bibl. No. 132, p. 63.)

Fig. 506. *Camerer's Case.* A single case of colour-blindness in a male, II. 2, who was myopic; his father, I. 1, one of his sisters, II. 3, and his eldest daughter, III. 1, were hypermetropic and had varying degrees of strabismus; he knew of no defect in colour vision of any of his family. II. 2 confused light yellow-red, green and yellow, the two former being to him only shades of yellow; dark yellow-red, green and yellow he usually called brown; he confused violet and blue; pure red and rose were to him independent colours; myopia in both eyes $= \frac{1}{5}$; visual acuity with correction normal. No consanguinity recorded. (See Bibl. No. 119.)

Fig. 507. *Adams Frost's Case.* A colour-blind male, I. 1, had six colour-blind sons, also one son and three daughters with normal colour vision; one of the daughters had a colour-blind son, III. 1. No information is given of the mother of the six colour-blind sons, nor of her family history. No consanguinity recorded. (See Bibl. No. 154.)

Fig. 508. *Bell's Case.* Colour-blindness in three brothers. Unfortunately it was not possible to examine any of the cases; information concerning them was given by their nephew, III. 10, whose opinion was that the defect was so severe as to leave no doubt as to its reality; he reported that II. 1 was only able to recognise blue and yellow, he had one child, a son, III. 1, too young to test. II. 3, a colour-blind brother to II. 1, had a son and daughter, III. 2 and 3, who were believed to have normal colour vision. II. 5 had very good vision and was in the Marines, his colour sense was normal and he had a normal son. II. 7 was severely colour-blind and was able to recognise certain shades of blue and yellow only; his two daughters were normal. These four brothers had one sister, II. 9, who married and had five children, of whom two were sons, all were said to have normal colour vision; the eldest son, III. 7, was in the Navy and was said to have very sensitive colour vision, and the younger son, III. 10, was examined and his colour sensitivity was again estimated to be above the average on Houstoun's apparatus; he read correctly all the Edridge-Green cards without hesitation. The father, II. 10, and his siblings were said to all have "weak sight," but normal colour vision. I. 1—4 were believed to be normal. Most of the family were abroad, and it was not possible to obtain more detailed information. The nephew, III. 10, was a university science student. No consanguinity. Hitherto unpublished.

Fig. 509. *Seebeck's Case.* Colour-blindness in two brothers, in their father and in their paternal uncle. No statement is made of the mother or of her family history. III. 1, aged 18, had known from early years "that he had inherited the defect of mistaking colours from his father"; blue and lilac he called blue; green or green-blue he called green-grey; rose red he called grey or greenish blue; dark grass green and dark yellowish brown were called brown, and so on. II. 2 was reported by his son to make the same mistakes. I. 1 was believed to have had normal colour vision. II. 3 was said to be very defective in distinguishing colours, especially red and blue. III. 2 could not distinguish red and blue; other members of this sibship had normal colour vision. No consanguinity recorded. (See Bibl. No. 61, p. 180.)

Fig. 510. *Cohn's Case* 30. Colour-blindness in III. 3 and in his maternal great-uncle, I. 3 (paternal uncle to his mother); he had brown hair and irides and was so unmusical that he was unable to sing after anybody the simplest melody; he was a Jew, aged 9, took blue for rose and brown ochre for green; no shortening of the spectrum; fundi normal. The parents and his brothers and sisters were all definitely free from the defect. No consanguinity. (See Bibl. No. 129, p. 52.)

Fig. 511. *Göthlin's Case I.* Colour-blindness in nine males and one female in a small pedigree of three generations. II. 4, a female, was colour-blind, incompletely protanopic in type; her father, I. 3, was a protanope with an unusually severe grade of defect; Göthlin believed II. 4 to be heterozygous and held that when colour-blindness occurs in a high degree in the father the inheritance can manifest itself even in the case of women who are heterozygotes. II. 4 married II. 3, whose father, I. 1, was a protanope; they had three sons all of whom were protanopes; one brother and one sister of II. 4 had normal colour vision, the sister was married and had a daughter with normal colour vision and two sons of whom one, III. 9, was a protanope, the other, III. 10, had normal colour vision. II. 3 had a sister with normal colour vision who married and had three sons all of whom were protanopes, and one daughter, III. 1, with normal colour vision. No consanguinity recorded. (See Bibl. No. 372.)

Fig. 512. *Göthlin's Case VI.* A green-blind man, II. 1, married a woman, II. 2, who herself had certainly normal colour sense, but her brother, II. 3, was incompletely green-blind; four sons were born from this marriage of whom two had normal vision and two on investigation were found to be red-blind. No consanguinity recorded. (See Bibl. No. 372.)

Fig. 513. *Göthlin's Case.* Colour-blindness in both parents and in all their six children; the parents, the three daughters and the two younger sons were typically green-blind; the eldest son was incompletely green-blind. In the polarization-anomaloscope all cases except the eldest son, III. 1, perceived full equality between pure yellow and pure red at intensities of light within the limits distinctive of green-blindness; the eldest son under similar conditions did not find full equality but only close resemblance between the red and yellow, and further, he deciphered an important figure in Stilling's pseudoisochromatic tests which other members of the family failed to decipher. No consanguinity. (See Bibl. No. 421.)

Fig. 514. *Schiötz's Case IX.* III. 5, who had a colour-blind brother, III. 3, married and had four colour-blind sons, IV. 7, 10, 11, 12, three of whom were born at one birth, four normal sons and five normal daughters one of whom, IV. 3, had a colour-blind son, V. 2, and a normal daughter, V. 1. IV. 10 had three children, two sons and a daughter, all with normal colour vision; IV. 12 married a member of a colour-blind family, IV. 13, and had a colour-blind son, V. 7, and a daughter with normal colour vision. IV. 13 had normal colour vision but she had a colour-blind sister, IV. 15, a colour-blind first cousin, IV. 20, a colour-blind father, III. 10, a colour-blind paternal uncle, III. 12, a colour-blind maternal grandfather, II. 4, and a colour-blind maternal great-uncle, II. 6. Thus this pedigree shows the intermarriage of three colour-blind families. No consanguinity recorded. (See Bibl. No. 408.)

Fig. 515. *Anonymous.* Colour-blindness in ten males and two females in five generations. V. 1, a very intelligent boy aged 14, was colour-blind and was heard speaking of a "green or brown mare"; his maternal grandfather, III. 4, was unable to distinguish red, green and brown, and confused blue and pink; yellow he always named correctly; III. 4 was once surprised by hearing someone speak of his father's sleigh as being green on the outside and red on the inside, for it had always appeared to him to be the same on both sides; further, he could see no difference in the colour of maple leaves in the spring and autumn. The account goes on to say that one of the brothers of III. 4, *two* of his first cousins and a nephew in the next generation had the same defect, but it would appear that *four* first cousins were affected, for a great-uncle of IV. 4 is said to have inherited the defect from his father and to have transmitted the defect to his four sons. A female relative is said to have transmitted the defect to two daughters, but we are not told to which generation they belong. It is to be regretted that we have not a more precise account of this history which suggests points of special interest. No consanguinity recorded. (See Bibl. No. 151.)

Plate XXXVII. Fig. 516. *Jeffries's Case.* Colour-blindness in a father, I. 1, and in his son, II. 1; no information is given of the mother's family nor of any siblings of II. 1. No consanguinity recorded. (See Bibl. No. 132, p. 63.)

Fig. 517. *Jeffries's Case.* Colour-blindness in twin brothers, II. 1 and 2; both were red-blind; no information is given of the parents nor of other siblings. No consanguinity recorded. (See Bibl. No. 132, p. 63.)

Fig. 518. *Jeffries's Case.* Colour-blindness in a mother, I. 1, and in her son, II. 1; no further information is given. No consanguinity recorded. (See Bibl. No. 132, p. 63.)

Fig. 519. *Jeffries's Case.* Colour-blindness in two brothers and in their maternal uncle. No further information is given. No consanguinity recorded. (See Bibl. No. 132, p. 63.)

Fig. 520. *Jeffries's Case.* Colour-blindness in five brothers; one brother with normal colour vision; no information is given of the parents. No consanguinity recorded. (See Bibl. No. 132, p. 63.)

Fig. 521. *Jeffries's Case.* Colour-blindness in a father and in his two sons; no further information is given. No consanguinity recorded. (See Bibl. No. 132, p. 63.)

Fig. 522. *Pearce's Case.* Colour-blindness in father and daughter. I. 1, J. W. T., suffered from hypochondriasis and recurrent melancholy, he also had arterio-sclerosis and a chronic cystitis secondary to hypertrophy of the prostate; he had no optical defects but could not distinguish red from green and had lost his position as a seaman through frequently placing red and green lights in false positions; fundus was normal. The patient subsequently became insane and died in an asylum; no organic disease of the brain was demonstrated at the autopsy. I. 1 had four children of whom one had chorea, one daughter was "very nervous," one child had lateral curvature of the spine, and a daughter aged 15 was demonstrated by repeated examinations to have a lowered degree of appreciation of red and green; she was well in other respects. No other cases of sub-normal colour perception were discoverable in the family. No consanguinity recorded. (See Bibl. No. 273.)

Fig. 523. *Preyer's Case.* Colour-blindness in a law student aged 20 and in his maternal uncle. II. 1, fair, blue-eyed and very short-sighted, knew that since childhood red and green had appeared the same to him; he was examined and found to be green-blind. His uncle, I. 3, had on one occasion bought red cloth to make a green hunter's coat. No consanguinity recorded. (See Bibl. No. 98.)

Fig. 524. *Schmitz's Case.* Colour-blindness in one member of a sibship whose sex is not stated; one sister had a supernumerary thumb, another sister had a cleft palate. No information is given of the parents nor are we told whether there were any normal members of the sibship II. 1—3. No consanguinity recorded. (See Bibl. No. 146.)

Fig. 525. *McHardy's Case.* Very marked colour-blindness in four brothers, three of whom were wood engravers; the fourth was a water colour artist of some position who was obliged to have the colours labelled for him. No information is given of the parents or of the existence of normal members of the sibship. No consanguinity recorded. (See Bibl. No. 162.)

Fig. 526. *Göthlin's Case II.* Colour-blindness in three brothers and in their maternal uncle, one brother and a sister had normal colour vision; both parents were normal. The colour-blindness was protanopic in all cases but the defect was less severe in the case of II. 2 than in the other affected members of the pedigree. No consanguinity recorded. (See Bibl. No. 372.)

Fig. 527. *Göthlin's Case IV.* This case is of interest as showing different types of colour-blindness occurring in different members of the same sibship. The parents I. 1 and 2 had normal colour vision; they had four sons and one daughter of whom II. 1, a son, had incomplete deuteranopic defect. II. 2, a son, was a deuteranope; II. 3, a son, was a protanope; II. 4, a daughter, had normal colour vision, and II. 5, a son, was a protanope. No consanguinity recorded. (See Bibl. No. 372.)

Fig. 528. *Davenport's Case.* Colour-blindness affecting males only in a grandfather and six of his seven living grandsons. Thus I. 2 was colour-blind; he had a normal brother and three normal children of whom two were females, II. 2 and 3, and one of unknown sex. II. 2 married and had seven children of whom three were normal daughters, three were colour-blind sons and one was an epileptic son with normal colour vision. II. 3 married and had one child who died in infancy, and three colour-blind sons. No further information given. No consanguinity recorded. (See Bibl. No. 351.)

Fig. 529. *Nettleship's Case.* Family C. Colour-blindness in a male, III. 2, and in his maternal grandfather, I. 4. Information of the defect in I. 4 was certainly correct; III. 2 was seen at about the age of 13. No consanguinity recorded. Hitherto unpublished.

Fig. 530. *Nettleship's Case.* Family D. Three colour-blind males in a sibship of six and a colour-blind male maternal first cousin in a sibship of two; the normal siblings in each case were females. There was no knowledge of the colour vision in the parents II. 1, 2, 3 and 4 or in the grandparents I. 1 and 2. No consanguinity recorded. Hitherto unpublished.

Fig. 531. *Bronner's Case.* A single case of colour-blindness in a French farmer aged 60; the condition was discovered after an operation for cataract performed by Dr Sichel in 1851 when the man admitted that he had never dared to buy any clothes for himself because of his inability to see colours rightly. II. 2 hesitated to specify any colour except yellow and blue; from a bundle of wools he recognised scarlet with difficulty, he took light pink for blue, of dark pink he could not say whether it was green, blue or red, he only knew that it was not yellow, white or black; orange puzzled him entirely; green, brown and red were thoroughly confounded; dark green and blood-red scarcely manifested to him any difference. The condition

was congenital and remained unchanged after the lens had been extracted. The father of II. 2 was also affected with cataract but nothing was known of his colour vision. II. 2 had two children, a son and daughter, who had normal colour vision. No consanguinity recorded. (See Bibl. No. 77.)

Fig. 532. *Burckhardt's Case.* Colour-blindness in a male and in his maternal grandfather. III. 1 was an acquaintance of III. 2 of Fig. 534, and the report is taken from him. No consanguinity recorded. (See Bibl. No. 95.)

Fig. 533. *Hogg's Case.* In a family consisting of four sons and three daughters the eldest and youngest of the sons were colour-blind; the other two sons and the daughters were free from the defect. The maternal grandfather was colour-blind, but neither the mother nor any other member of the family were affected. No consanguinity recorded. (See Bibl. No. 190.)

Fig. 534. *Burckhardt's Case.* Four cases of colour-blindness in males in a small pedigree; the chart is given by the recorder but no details of the family are described and it is by no means certain that all members of the sibships are given. The colour-blindness of III. 2 is described and he is said to have made the same mistakes as IV. 1 in pedigree 579; he divided the spectrum into two parts, yellow and blue, and described a neutral part which might be called either grey or rose-red; the ends of the spectrum were not noticeably shortened. No consanguinity recorded. (See Bibl. No. 95.)

Fig. 535. *Burckhardt's Case.* Colour-blindness in two brothers and in their maternal grandfather; a step-brother had normal colour vision. Only one of the brothers appears to have been tested, he was red-blind, confused Parisian green with cinnabar and called carmine reddish brown. No consanguinity recorded. (See Bibl. No. 95.)

Fig. 536. *Wilson's Case.* Colour-blindness in two brothers and in their maternal grandfather. III. 1, Dr S., aged 23 (1855), reported that he had known of his defect for about ten years and that he discovered it through mistakes when entrusted with commissions for coloured purchases; he had been a successful draughtsman and sketcher from nature, but on using water-colours had even painted trees red; he could clearly discern blue and yellow except in the case of light blue which he might mistake for pink; he was uncertain as to the action of acids on litmus and could not at a little distance distinguish red petals or berries from the leaves of the same plants; he was always puzzled with greens and reds and often confused both colours with brown and some greens with drab. He writes: "none of my family are so affected, and some of them are good colourists, but I understand that my maternal grandfather had some similar deficiency." The recorder however states that he had a colour-blind brother. No consanguinity recorded. (See Bibl. No. 76, pp. 33, 71.)

Fig. 537. *Wilson's Case.* Colour-blindness in two brothers and in one of their grandfathers. III. 1, Mr R., aged 40 (1853), had since his childhood been totally unable to retain certain colours in his mind; he considered that his defect was most marked with regard to compound colours such as green, purple, orange and brown; he also confused pink and pale blue, reds and yellows, blues and greens, reds and greens; but his appreciation of the various shades of colours (or the weight of colour as he described it) was extremely delicate. Mr R. was an engraver and he considered that his defective vision was to him a useful and valuable quality. He had once bought very bright red in mistake for green baize. He reports that one of his brothers was similarly affected and that his grandfather was very deficient in his knowledge of colours; further Mr R. had deep grey eyes and was able to see very minute objects without assistance from glasses. No consanguinity recorded. (See Bibl. No. 76, p. 27.)

Fig. 538. *Hochecker's Case.* II. 3, the recorder of this pedigree, was himself colour-blind and could recognise blue and yellow only in the spectrum. His three maternal uncles, I. 3—5, his cousin, II. 5, and his nephew, III. 1, were also colour-blind. No consanguinity recorded. (See Bibl. No. 111.)

Fig. 539. *Magnus's Case.* Colour-blindness in a grandchild, whose sex is not stated, and in the maternal grandfather. The recorder saw two other similar cases; in each case the parents of the affected child had normal colour vision. No consanguinity recorded. (See Bibl. No. 122.)

Fig. 540. *Magnus's Case.* Colour-blindness in a grandchild (sex not stated) and in one of its grandfathers; the parents had normal colour vision. In this, and in a similar case seen by the recorder, it was not known whether the affected grandfather was on the maternal or on the paternal side. No consanguinity recorded. (See Bibl. No. 122.)

Fig. 541. *Magnus's Case.* Two first cousins, the daughters of sisters I. 2 and 4, had each a colour-blind son, III. 1 and 3. No further information is given. No consanguinity recorded. (See Bibl. No. 122.)

Fig. 542. *Cohn's Case.* A single case of colour-blindness in III. 2, a Jew, aged 14, with brown hair and irides and normal fundi; he took blue for rose and saw yellow and blue only in the spectrum, no shortening of the spectrum; his parents were first cousins; his two grandmothers were sisters; his two siblings had normal colour vision; two half-siblings, children of his father by his first, unrelated, wife had normal colour vision. No other case of colour-blindness was known in the family. Consanguinity. (See Bibl. No. 129, p. 39.)

Fig. 543. *Cohn's Case.* Colour-blindness in a Jew, aged 14, with grey-brown irides and dark brown hair. III. 1 took green for rose; in the spectroscope he saw red, yellow, blue and dark green; fundi normal. His only brother and his parents had normal colour vision; maternal grandmother and paternal grandfather were siblings. Consanguinity. (See Bibl. No. 129, p. 112.)

Fig. 544. *de Fontenay's Case.* Colour-blindness in three brothers, in their paternal uncle, and in the only son of one of them; the parents, I. 3 and 4, had normal colour vision; one sister, II. 5, was also normal. II. 2, aged 34, an engineer with dark brown eyes, was tested and found to be red-blind; II. 3 and 4 were said to be also red-blind. No consanguinity. (See Bibl. No. 140.)

Fig. 545. *Groenouw's Case.* I. 1 and 2 had normal colour vision; they had four children, two sons and two daughters, of whom one son, II. 3, the second born, was red-green blind, his three siblings were normal. The eldest son, II. 2, had four children, of whom the only son, III. 1, died young, he was epileptic, and the eldest daughter, III. 2, was mentally defective; this defect, as well as the epilepsy of III. 1, was inherited from the mother, II. 1; the three daughters of this sibship had normal colour vision, the son died before any information on this point had been obtained. II. 5, the eldest daughter of I. 1 and 2, had three sons who were all red-green blind and one daughter, III. 6, with normal colour vision; the father to this sibship was normal. II. 7 married a normal man, II. 6, and had six children, of whom one son was colour-blind, two sons and three daughters had normal colour vision. No consanguinity recorded. (See Bibl. No. 287.)

Fig. 546. *Seebeck's Case.* Colour-blindness in a male and in his maternal grandfather. III. 1, aged 18, with blue eyes and light brown hair, had good vision for form, but his parents had noticed at an early age that he confused colours; he could only distinguish cherries on the trees by their form, red and green appeared very similar to him; he had no siblings, his parents had normal colour vision, but his grandfather, I. 1, was colour-blind and made mistakes very similar to his. No consanguinity recorded. (See Bibl. No. 61, pp. 189—195.)

Fig. 547. *de Fontenay's Case* 170. Colour-blindness in III. 1, who was tested and found to be red-blind; his siblings and his parents had normal colour vision; his maternal grandfather, I. 1, was red-blind. No consanguinity. (See Bibl. No. 140.)

Fig. 548. *Helling's Case.* Colour-blindness in two brothers and in their maternal grandfather. III. 1, aged 13, living in Berlin, was unable to distinguish several colours from one another; especially red, green and lilac; his brother, III. 2, aged 11, had the same defect to a less severe degree. Their maternal grandfather, I. 2, could distinguish no colour, but in other respects had very good sight to the end of his life; he had been in the drapery trade, and in order to help him with the colours in his sales he had several patterns fastened on the sleeves of his coat which he compared with the goods he wished to sell. No consanguinity recorded. (See Bibl. No. 50.)

Fig. 549. *Stilling's Cases VIII and IX.* Colour-blindness in two brothers and in one of their grandfathers. III. 1, a doctor, said that he could distinguish blue and yellow; in sorting threads he put together blue, violet and rose; purple and violet; red, green and grey; he saw blue and yellow in the spectroscope. III. 2, a younger brother of III. 1, had the same defect. It is not stated whether I. 1 was the maternal or the paternal grandfather. The father had normal colour vision. No consanguinity recorded. (See Bibl. No. 114.)

Fig. 550. *Magnus's Case.* Professor Valentin, of Berne, reported to the recorder that Professor F., I. 1, was colour-blind, but his children were normal; he had five daughters, all of whom married, and whose children were, so far as Professor Valentin could learn, for the most part colour-blind. No consanguinity recorded. (See Bibl. No. 122.)

Plate XXXVIII. Fig. 551. *Nagel's Case.* Colour-blindness in a father and son; the father, I. 1, was red-blind, the son, II. 1, was green-blind. No information is given of normal siblings nor of the maternal grandparents of II. 1. No consanguinity recorded. (See Bibl. No. 310.)

Fig. 552. *Nagel's Case.* Colour-blindness in a father and his son; both were green-blind. No further information is given. No consanguinity recorded. (See Bibl. No. 310.)

Fig. 553. *Galloway's Case.* Colour-blindness in a father and his son; II. 1, a ship's mate who had obtained his ticket two years before, matched pink and blue, also yellows, drabs and greens; he said yellow was green and called a white light green three times, but made no mistakes with red and green. His father, who had been a skipper for 21 years, was found to match pink and blue skeins; blue he called light green and green-blue several times. No further information is given. No consanguinity recorded. (See Bibl. No. 340.)

Fig. 554. *Wolfe's Case.* Colour-blindness in two brothers. II. 1, a solicitor, could name black, blue, white and yellow, but no other colour; in the spectroscope he saw blue only and said that the rest looked to him like a glare of fire through transparent gauze; he could only guess at green. His brother had been in the silk department of a warehouse, but made such blunders in regard to colours that he had to leave

the trade. No information is given of the parents or other siblings. No consanguinity recorded. (See Bibl. No. 137, p. 419.)

Fig. 555. *Wolfe's Case.* Colour-blindness in a male and in his maternal uncle. II. 1, an only son, was a shawl manufacturer; pale green he called dirty white; green, yellow and orange were all to him yellow of varying brightness; he could pick out scarlet, but dark green was to him the same as red; he saw all colours in the spectrum, except green, which appeared to him to be similar to red, but of a lighter shade as if some yellow had been mixed with it; crimson he called green, scarlet he called red, orange he called light red; he considered salmon colour to be light green; he was able to identify orange, yellow and blue. His mother, I. 2, aged 70, had excellent sight; her brother was colour-blind. No consanguinity recorded. (See Bibl. No. 137, p. 419.)

Fig. 556. *Wilson's Case.* Colour-blindness in two brothers. II. 1, a peer and an Admiral in the Navy, reported that his younger brother had once painted a red tree in a landscape without being aware that he had done so; he himself, though fond of drawing, never attempted to colour. The shades of green, brown and red perplexed him the most; bright scarlet was unmistakable, but he once chose a pair of green trousers thinking they were brown; pink and light blue puzzled him much by daylight. No consanguinity recorded. (See Bibl. No. 76, p. 31.)

Fig. 557. *Wilson's Case.* Colour-blindness in two brothers. Dr G. first became fully convinced of his defect from the fact that in a chemistry class he was unable to see any change on the addition of acid to an infusion of red cabbage; his eyes were bluish grey, his vision for form excellent; he could see in the rainbow blue and yellow; he believed that on examining crystals by polarised light he could see just as the normal person yellow and blue, red and green, and on turning the prism he could see them changing, but he could not retain in his eye the red and green, and could not tell them on a piece of cloth the next minute; he repeated later that he had the firm idea and belief in his own mind that he *saw* colours the same as the normal person, but they produced no lasting effect on the eye at all, and he could not recognise them again. When asked to select from a number of pieces of coloured glass those which were green, he placed together green, red, brown, yellow, claret and pink; when asked to state which appeared to him the purest or greenest green he at once selected the claret-coloured glass. Red, he said, in the lips, cheeks, nose, roses (red), gooseberries, inflammations and the like, looked blue to him, and yet on taking up an oil paint to illustrate his conception of the colour of the lips he took up a green. He regarded pinks, lilacs, purples and blues as the same colour, differing only in intensity; browns, russets, maroons, olives, citrones, and "a host of others, are just anything that I can guess at, but I never get further than red, brown or green." On one occasion he bought a purple neckcloth under the impression that it was black; he never before, or since, bought a coloured piece of dress without assistance. His brother was said to be similarly affected, but we have no record that he was tested. No consanguinity recorded. (See Bibl. No. 76, pp. 24—26, 71.)

Fig. 558. *Nettleship's Case.* Colour-blindness in a brother and sister. Miss S., II. 1, aged 22 (1895), was seen by the recorder for slight asthenopic symptoms; her sister, who was with her, said spontaneously that II. 1 was colour-blind; the patient knew of the defect but was very reticent and greatly disliked speaking of it; under pressure she admitted that she had made mistakes in matching colours, especially blues and greens. The recorder found, from the incomplete examination allowed, that she matched Holmgren's pale green (Test 1) with pale blue, picked out as grey some greyish-browns and a light violet in Holmgren's 2*a*, and confused yellowish-green with green in his group 2*b*, all the darker greens of this group were blue to her. One of her brothers had been rejected at his examination for the Engineers for well-marked red-green colour-blindness. No further information could be obtained and nothing is reported of the colour vision in the case of the parents. No consanguinity recorded. (See Bibl. No. 302.)

Fig. 559. *Hochecker's Case.* Colour-blindness in a female, I. 2; also in her brother and in her two sons. No information is given of any normal members of the family. No consanguinity recorded. (See Bibl. No. 111.)

Fig. 560. *Kirschmann's Case.* Colour-blindness in two sisters and in the son of one of them. I. 2 (Mrs A.), milliner in San Francisco, is described by the recorder as a dichromate; her sister was also colour-blind; her brother, I. 4, had normal colour-vision; she had two children, a daughter, II. 1, aged 13, with normal colour vision and a son aged 10, who had a defect in his colour sense similar to that of his mother. No consanguinity recorded. (See Bibl. No. 266.)

Fig. 561. *Wartmann's Case.* I. 1 and 2, with normal sight, had eleven children, of whom some had red hair and were not Daltonians, the others had fair hair and anomalous colour vision; both sexes were represented in the two classes. The eldest son, Louis D., born 1810, remembered the correction which his master, a bookbinder, inflicted on him for having used red paper for some books, the cover of which should have been green; he did not perceive any great difference between the colour of the leaf and that of the ripe fruit of the cherry; he confused the colour of a sea-green paper with that of a scarlet ribbon placed close to it; the flower of the rose seemed to him greenish blue, and he called the ash colour of the quicklime of commerce light green; in the spectrum he saw four colours only—blue, green, yellow and red.

Tests are described with coloured glass, with polarised light and with complementary colours. II. 1 had six brothers, of whom three were colour-blind, and four sisters, one or more of whom also were colour-blind. No consanguinity recorded. (See Bibl. No. 69.)

Fig. 562. *Bickerton's Case.* A colour-blind woman with two colour-blind sons, also one son and one daughter said to have normal colour vision. II. 2, a ship's mate, was refused his master's certificate after $4\frac{1}{2}$ years at sea owing to defective colour sense; he was completely colour-blind, but said that he had never experienced any difficulty in navigating his vessel into crowded ports day and night. An elder brother had been told by the local chairman of the Board of Trade that he was "a little defective in colours"; his father, sister and one brother were said to be normal; his mother, I. 2, was incompletely colour-blind, she failed at Holmgren's first test, but passed the second and third tests. No consanguinity recorded. (See Bibl. No. 175.)

Fig. 563. *Jeffries's Case.* Colour-blindness in two brothers, one of whom was red-blind, the other green-blind. No information is given of the parents or of other siblings. No consanguinity recorded. (See Bibl. No. 132, p. 63.)

Fig. 564. *Kirschmann's Case.* Unilateral anomalous colour vision in two brothers. II. 1, a University professor, was very fully tested by the recorder; he was examined with the spectroscope, matched wools, described coloured objects with each eye separately, was tested with Stilling's Tafeln, with colour mixtures and with spectra of coloured flames, and he undoubtedly had anomalous vision for violet, green and possibly yellow with the right eye only; his left eye was normal. Thus violet, seen with his left eye, he described as red or black as seen with his right eye; yellowish green with his left eye was grey-blue with his right; pure green with his left eye was light blue with his right; orange with his left was reddish with his right eye; and yellow with his left eye was a dull orange with his right; red he described as being identical with the two eyes; the anomaly was believed to have been congenital. His brother, II. 2, also a man of academic culture, an astronomer, had apparently a precisely similar anomaly, affecting, in his case also, the right eye only; he was not seen by the recorder, but carried out tests at his request and sent a very clear account of his own observations. The parents were believed by the two brothers to have a completely normal colour sense. Nothing was known of the colour vision of the grandparents. No information is given of other members of the family. No consanguinity recorded. (See Bibl. No. 227.)

Fig. 565. *Hess's Case.* Green-blindness in a male, I. 1, and in his daughter, II. 1; no information is given of colour vision in the mother's family. No consanguinity recorded. (See Bibl. No. 397.)

Fig. 566. *Vogt and Klainguti's Case* (No. L^a). Colour-blindness in a female and in her father. III. 2, female, aged 12, was demonstrated to be red-green blind; her brother, III. 1, aged 14, had normal colour vision; a younger brother, aged 5, was tested, but the results of the examination were indefinite. Both parents were tested; the father, aged 46, was found to be a dichromate, the mother, aged 42, had normal colour vision. The family were abroad and no relations in the neighbourhood knew of any case of colour-blindness in the mother's family. All the grandparents were dead. No consanguinity recorded. (See Bibl. No. 409.)

Fig. 567. *Nettleship's Case.* A colour-blind female in a sibship of six with a colour-blind father; three of her nephews in a sibship of seven and one further nephew in a sibship of five were also colour-blind. I. 1, a butcher, was very colour-blind; the only colour he knew was the blue of his trade coat. He had five daughters and one son, of whom one daughter, the second born, II. 3, was very blind for colours and often made mistakes in buying fabrics; she died aged 50, unmarried, but the recorder made careful inquiries and had no doubt that she was colour-blind. II. 5 (Mrs P.) had good colour vision for both Holmgren's and Edridge-Green's wools; she had four sons and three daughters, of whom three sons were colour-blind; III. 6, died aged 14, was known to have been colour-blind; III. 7 and 9 were examined and found to be colour-blind; III. 8, 10, 11 and 12 were examined and found to have normal colour vision. It was known that III. 4, one of the five children of II. 2, was colour-blind. No consanguinity recorded. (See Bibl. No. 302.)

Fig. 568. *Nettleship's Case.* Colour-blindness in a female, II. 3, in her two brothers, II. 1 and 2, in her father, I. 6, and in her daughter, III. 1. I. 6 used to be teased by his wife because he called brown green and could not distinguish properly between red and green; he and his wife were not consanguineous; they had three children, of whom II. 1, a clergyman, confused green more or less markedly with violet and blue-green, blue with violet, and orange with pale chrome yellow. II. 2 confused blue with rose, and blue-green and orange with yellow-green. II. 3 confused yellow with green; her daughter confused yellow with green and orange with red. I. 5 appeared to have normal colour vision; she had three sisters and a brother, one of the sisters was examined and found to be normal. No consanguinity. (See Bibl. No. 302.)

Fig. 569. *Nettleship's Case.* Colour-blindness in three sisters and in their only brother; their maternal grandfather and their maternal first cousins were also affected.

III. 4, male, aged 23, was very colour-blind, he confused pale green wools with pale yellows, buffs and browns; rose with violet, blue green and grey; scarlet with full green and brown; he also made mistakes in copying a highly-coloured child's picture; refraction at age of 16 was 0·5 H.As., $V=\frac{6}{9}$. III. 5 and 6 are female twins of whom the younger was colour-blind, the elder normal; they were said to be much alike in most of their physical features, but showed sufficient differences to raise considerable doubt as to whether they were of uniovular or binovular origin; III. 5, aged 21, was of not very good physique, but was very intelligent; she

was tested with wools, Nagel's cards and pocket spectroscope; the recorder concluded that she had no defect; she had nearly black hair and grey irides, with some brown on the inner circle; refraction at age of 18 was R. My. 0·5 D., L. My. 2·25 D.; R.V. = L.V. = $\frac{6}{6}$ with correction. Her twin sister, III. 6, was of rather better physique than III. 5 and, though intelligent, was considered to be much less quick and clever; she was colour-blind and said that her chief difficulty was with the lighter colours; she was tested with wools, Nagel's cards and the spectroscope, and made characteristic mistakes; she confused red and green in Nagel's test, but in the spectroscope said she saw "red, green, and blue," with no mention of yellow; with the yellow test wool she confused several yellowish greens; the full details of her examination are given in the original account. The irides of III. 6 showed a diffuse yellowish-brown pigmentation of the inner zone, the peripheral zone was grey or grey-blue; refraction at age of 15, H. 0·75 D.; visual acuity full in each. III. 7, aged 20 (1912), with fair hair and blue eyes, was tested by Dr Sym and found to have no defect of colour vision; she copied a coloured picture and was tested with wools. III. 8, aged 18, with Holmgren's pale green test skein, placed several containing so little green as to be almost grey, but made no absolutely wrong matches; with scarlet she confused a yellowish-pink, but made no other mistakes; with Edridge-Green's mauve or violet, which she called "blue," she matched a number of pure blues, several grey-blues, and one turquoise; in the painting test she rendered orange-red and yellow with red stippling as pink and pinkish-brown of shades; yellowish-green was copied sometimes as very pale green, sometimes as pale brown; saturated bright yellow she copied as the palest watery yellow; she was supposed by her family to be perfect at colours; she had dark hair and brown irides. III. 9, aged 16, was also supposed by her family to have normal colour vision, but she had much the same defect as III. 8; with Holmgren's pale green she made no conspicuous mistakes; with his pink or rose and also with the scarlet she confused a yellowish-pink (salmon), but made no other mistakes; with Edridge-Green's mauve or violet, called "mauvy-blue," she confused several pure blues. In the painting test she rendered scarlet by rose or dark pink, yellowish-red by pure brown, purplish-brown, and reddish-brown; and from greens containing a sensible mixture of yellow she left out the yellow; she had fair hair and blue eyes.

Of the parents of the sibship III. 4—9, the mother, II. 3, was reported by her husband and by her normal daughter, III. 5, to see colours perfectly well; in copying the coloured picture she rendered reddish-yellow hair by warm brown, which raises some doubt as to her normality; the recorder considered that the mistake may have been due to some accidental cause and hoped to apply more complete tests at a later date, but we can find no further record of her case; she had "auburn" hair and brown irides. The father, II. 4, a professional man, was tested and found normal; he had never heard of colour-blindness in any of his relations; he and his wife were not cousins in any degree; he had light hair and blue eyes. II. 3 had one sibling, a sister, II. 2, who was reported to be normal, but had two sons known to be markedly colour-blind, and one daughter, III. 3, reported to be normal. The maternal grandfather, I. 2, was known to have been very colour-blind. No consanguinity recorded. (See Bibl. No. 355.)

Fig. 570. *Scott's Case.* Colour-blindness in a female; her two sons, her brother, her father and her maternal uncle were also colour-blind; her mother, sister and daughter had normal colour vision. II. 2, the recorder, wrote "now I will inform you what colours I have the least knowledge of; I do not know any green in the world: a pink colour and a pale blue are alike, I do not know one from the other; a full red and a full green the same, I have often thought them a good match; but yellows, light, dark and middle, and all degrees of blue, except those very pale, commonly called sky, I know perfectly well and can discern a deficiency in any of those colours to a particular nicety; a full purple and deep blue sometimes baffle me. I married my daughter to a genteel worthy man a few years ago; the day before the marriage he came to my house dressed in a new suit of fine cloth clothes; I was much displeased that he should come (as I supposed) in black and said he should go back to change his colour; but my daughter said, 'No, no, the colour is very genteel,' and that it was my eyes that deceived me. He was a gentleman of the law, in a fine rich claret-coloured dress which is as much black to my eyes as any black that was ever dyed. She has been married several years; no child living, and my son is unmarried; so how this impediment may descend from me is unknown."

The wife of II. 2, his two children, III. 1 and 2, his sister, II. 3, and his mother, I. 2, all saw colours well; his father, I. 1, his maternal uncle, I. 3, his sister, II. 4, and her two sons, III. 3 and 4, were all colour-blind; his sister's daughter, III. 5, saw colours well. This case is probably the earliest record of a colour-blind female; moreover, she inherited the defect from the stocks of both her parents. No consanguinity recorded. (See Bibl. No. 35.)

Fig. 571. *Nagel's Case.* Colour-blindness of the same type in a male, III. 2, and in his maternal grandfather, I. 1. No further information is given. No consanguinity recorded. (See Bibl. No. 310.)

Fig. 572. *Wolfe's Case.* Colour-blindness in a male, in his grandfather (? maternal) and in his maternal uncle. III. 1, a manufacturing chemist, knew that grass is green, having been told so from infancy. Otherwise he would take it to be yellow, about which colour he never made any mistake; red berries he took to be green, but a shade lighter than the green leaf; he saw blue and orange in the spectroscope and knew that there was something else there, but could venture upon no name for it; crimson was nothing at all to

him, grey was the best term he could give it; scarlet, orange and salmon colour he was not sure about; light and dark green he knew nothing of, but was certain about light blue and indigo; violet and purple were similar to blue and indigo respectively. His maternal uncle, II. 3, and his grandfather (not stated which) were also colour-blind. No consanguinity recorded. (See Bibl. No. 137, p. 419.)

Fig. 573. *Hogg's Case.* In a sibship of five, three males were colour-blind; their two sisters and, indeed, all the females of the family were free from the defect, which was said to have been inherited through the father and grandfather. It is not clear from the recorder's account whether both these antecedents were affected and which grandfather is referred to. No consanguinity recorded. (See Bibl. No. 190.)

Fig. 574. *Hayes's Case.* Uniocular colour-blindness in a female who had a colour-blind maternal grandfather. Miss G. S., III. 1, a senior in Mt Holyoke College, was quite unable to recognise reds with her right eye; the colour vision of her left eye was normal; a very detailed examination of her case with Nagel's cards, Holmgren's worsteds, Stilling's Tafeln and a spectroscope is described; ophthalmoscopic examination showed nothing abnormal in either eye; she had low myopia in the left eye and some weakness of vision in the right eye which no lens seemed to correct. She knew no details of her grandfather's defect and had heard of no other case of colour-blindness in her family. No consanguinity recorded. (See Bibl. No. 347.)

Fig. 575. *Schiötz's Case VIII.* I. 2 was colour-blind, nothing was known of the family of his wife, I. 1; they had two sons and two daughters, of whom one son, II. 1, and one daughter, II. 5, were colour-blind; the other daughter, II. 3, with normal colour vision herself, transmitted the defect to two of her four sons, III. 2 and 4; she also had five normal daughters. The colour-blind female, II. 5, married and had two colour-blind sons, III. 6 and 8, and three normal daughters. No consanguinity recorded. (See Bibl. No. 408.)

Fig. 576. *Nicholl's Case.* A colour-blind female with two colour-blind paternal uncles. II. 5, male, aged 48 (1818), was the youngest of a sibship of ten, living near Mauchline in Ayrshire; his chief difficulty was with green and he said that any attempt to distinguish it from red was merely guess-work; grass appeared to him what other people call red and he could not distinguish the colour of red fruit on trees from that of the leaves; he knew scarlet, light yellow, dark blues and black; dark bottle green he confused with brown, dark yellow with light brown, all shades of light red, pink and purple he called blue; a rainbow appeared to him to be a mixture of different shades of yellow and blue, yellow in the centre and blue towards the edges; he had crimson curtains at the window of his bedroom, which appeared to him red in candle-light, blue in daylight. II. 5 considered that he could see objects at a greater distance and more distinctly in the dark than any one he could recollect having met with. II. 4 died in 1791; he was known to have been colour-blind, but no details of his case are given; colour-blindness had not been heard of in any of the ancestors of this sibship. II. 5 had three sons and two daughters, all believed to have normal colour vision; he had four nephews and four nieces, and he said, "I think the last time I saw my only surviving brother he told me a similar defect had been observed in his youngest daughter, a girl about 12 years of age." No consanguinity recorded. (See Bibl. No. 47.)

Fig. 577. *Vogt's Case.* Colour-blindness in four females and five males of two generations. The special interest of this pedigree centres in the marriage of the colour-blind male, II. 7, to the colour-blind female, II. 8; they had three children, a son and two daughters, all of whom were colour-blind. No further cases of colour-blindness were known in the family of II. 7; his brothers, II. 2, and three of his nephews, III. 2—4, were examined, with an uncertain result; II. 4 was examined and found to be normal. There was no knowledge of the colour vision of I. 3; his wife, I. 4, aged 79, had no defect of colour vision; she had eleven children, of whom two daughters, II. 8 and 16, and two sons, II. 11 and 18, were known to be colour-blind; one daughter, II. 10, transmitted the defect to at least one of her three living sons, III. 12; her eldest son, III. 9, was examined and found to be normal; three daughters, II. 12, 13, and 17, were unmarried and were not known to be colour-blind; one daughter, II. 15, had a son and daughter, of whom the former, III. 18, was examined, with an indefinite result, the latter, III. 19, had normal colour vision. No consanguinity recorded. (See Bibl. No. 410.)

Fig. 578. *Bell's Case.* Colour-blindness in two females and in the father of one of them. III. 12, a medical student, aged 35, said that her defective colour vision was recognised very early in life, from the mistakes she made and the difficulties she found in matching colours, and its occurrence was much discussed in the family; this fact is of importance as indicating that if other cases of colour-blindness had occurred in near relations she would be likely to have heard of them, unless the defect was very slight; tested with Houstoun's microscopic apparatus, III. 12 showed a definitely defective sensation for red and green; she always said when red was presented that it was very dark, and when it was nearly in focus she said it looked rather a warm colour, and therefore she thought it must be red; when green was presented she said it was just a dirty colour; when in focus she suggested that it was red, and when red and green were presented together, she said they were different and could say which was "rather warm" and therefore red; at other times she would say green was like a dirty yellow. Tested with the first ten of Edridge-Green's cards she failed entirely with Nos. 2 and 3, she was successful but very slow and hesitating with

Nos. 1, 4, 5 and 6; in Nos. 7, 8, 9 and 10 she pointed out the different colours, but failed to name the letters until she was shown it, after which she could see it for herself. She has the impression that her colour sensitivity varies on different days, and she thinks that she sees colours better when near than at a distance; she has always noticed that she sees certain colours, red for example, much better by artificial light. III. 12, her brother, III. 13, and her first cousin, III. 8, all suffered from angio-neurotic oedema; also III. 12 and both her grandfathers were left-handed. III. 13 and 14, brother and sister to III. 12, were believed to have normal colour vision; the brother is a medical man, now abroad, and had he anything more than a very slight defect it is unlikely that he would not know of it; the sister is married and has a boy aged $2\frac{1}{2}$ years, who is always attracted by bright colours and is delighted with red balls.

II. 16, father of III. 12, is said to be very badly colour-blind, his daughter considers that his defect is much more severe than her own, but he was not aware of it until he reached adult life; he was one of a large sibship and the various families are out of touch so that very little evidence could be obtained about them; one brother however, II. 9, was a sea-captain, he was murdered in China and nothing is known of his colour vision; he had two sons and a daughter, one son is dead, the other married a Norwegian girl and lives in South America, the daughter, III. 7, now dead, was known to be colour-blind; her condition was discovered by the mistakes she made in every-day life and by her difficulty in matching colours; she was a great needle-woman and III. 12 has always heard that she could match colours perfectly by artificial light. The parents of III. 7 were first cousins. III. 9 thinks that II. 10 was daughter to the brother of I. 1, but is not quite sure of this.

III. 12 has tried to obtain information about her mother's family for us, but they are Colonials living in South Africa and are not interested in the subject of colour-blindness, so that her efforts met with no success; she knew her maternal grandfather personally, and believed him to have had normal colour vision. It is with much regret that we find ourselves obliged to publish this history of two colour-blind females without knowing, in the one case, whether the father had defective colour vision, and in the other case having no knowledge of the condition in the mother's family. Consanguinity. Hitherto unpublished.

Fig. 579. *Burckhardt's Case.* Colour-blindness in four males and possibly in two females in a small pedigree of four generations. I. 1 is classified by the recorder as colour-blind on the basis of a statement by II. 2, to the effect that when he was a small boy his mother had sent him to school in a jacket one half of which was green and the other half brown; her three sons, II. 2, 3 and 4, were undoubtedly colour-blind; there is no statement as to whether she had other sons or daughters.

II. 2 could not distinguish red, green and brown, and the whole spectrum appeared to him to consist of two chief colours which he called orange and blue; the recorder tested him in various ways and reports that he and his two brothers made similar mistakes. It is not stated how many children II. 2 had, but a daughter, III. 2, had a colour-blind son, IV. 1.

IV. 1, a fair boy, aged 10, had shown uncertainty in naming colours since his earliest years; the green leaves of the horse-chestnut trees appeared to him to be of the same colour as the red minster; cockchafers, chocolate and meat extract he called green; grass was to him the same colour as the ground; a fine red-coloured disc was bent so that half was illuminated and half in shade, the illuminated half he called red and the shaded half he called green. Further tests are described, but no statement is made as to whether he had siblings.

III. 4, the daughter of II. 4, had no very marked defect in her sense of colour, but she showed a hesitation in naming certain dark and light colours; a dark brownish-red she named correctly, a dark grey she called black, extract of meat she called green, violet and blue were interchanged; examination with the spectrum and colour disc gave no definite result. No consanguinity recorded. (See Bibl. No. 95.)

Plate XXXIX. Fig. 580. *Bowditch's Case.* Colour-blindness in eighteen males and two females in a pedigree showing intermarriage between members of three colour-blind stocks; the defect is described as "red-green colour-blindness," and we are not told what tests were applied, nor whether the type of defect was like or unlike in members of the three allied families.

IV. 21 was a professor of physiology and wrote the section on the physiology of vision in the *American Text Book of Physiology* (1896); he was himself red-green colour-blind; his two brothers had normal colour vision; two of his three sisters died unmarried, the third sister, IV. 23, had three sons, of whom two, V. 32 and 33, were colour-blind and one, V. 31, had normal colour vision, also one daughter, V. 30, who had a daughter, VI. 26; V. 33 had a daughter, VI. 27. IV. 21 had two sons and five daughters, all with normal colour vision; one of the sons, V. 20, married V. 43, whose maternal uncle, IV. 33, was colour-blind, and had a son and a daughter, the son, VI. 30, over three years of age, was unable to tell the names of colours correctly, but the recorder did not consider that he had been demonstrated to be colour-blind. V. 21 and 22 had no sons; V. 23 had one son who was colour-blind and three daughters; V. 26 had two colour-blind sons, three sons with normal colour vision and one daughter; V. 27, twin sister to V. 26, had two sons, both colour-blind. It would be of interest to have more definite knowledge of the colour vision of VI. 30; if he has the defect it is not quite clear how it arises, unless his grandmother, IV. 36, married a colour-blind man; no statement is made of the colour vision of IV. 37 or of III. 18, but it

is likely that III. 18 had no severe defect, for his wife, III. 17, who had a colour-blind son, IV. 33, appears to have made no note of the defect in her husband; she marked her father, II. 18, as having had normal colour vision.

The origin of the defect in IV. 21 is not quite clear; his mother is likely to have been a carrier, for her only married sister, III. 13, had a colour-blind son, IV. 27, one son with normal colour vision, and her only married daughter, IV. 29, had three sons, of whom two, V. 38 and 39, were colour-blind. III. 12 lived near his nephew, IV. 21, and was believed to have normal colour vision. II. 14, maternal grandfather of IV. 21, was a lawyer, he died in 1848; his daughter, III. 9, referred to the colour-blindness of her son in a number of her letters, but never mentioned the defect as being present in her father; a great-grandson of one of the brothers of II. 14 thinks that he remembers some stories suggesting colour-blindness told about one of his great-grandfather's brothers, but no definite information was obtained; a sister of II. 14 married the son of her mother's sister, and four generations of her descendants have been traced with normal colour vision. II. 15 had a twin sister who was married and appears to have had normal descendants for four generations. The father of II. 15 and 16 was an officer in the Continental Army who, when offered the position of adjutant-general, at first declined it, partially on the ground that his defective eyesight did not allow him to survey distinctly a wide or distant area; he had experienced this defect from early life; he wore spectacles and was dependent upon them.

III. 7, father of IV. 21, had two sisters, III. 5 and 6, who married two colour-blind brothers, III. 3 and 4. III. 4 and 6 had two sons and two daughters with normal colour vision; one of the daughters married and appears to have normal children and grandchildren. III. 3 and 5 had one son and five daughters; two of the three married daughters transmitted the defect; thus IV. 6 had two sons, of whom one was colour-blind; IV. 8 had three sons, all of whom were colour-blind, and three daughters, two of whom, V. 11 and 13, were married; V. 11 had four normal sons; V. 13 had two normal sons. III. 3 and 4 had another brother, III. 2, about whose colour vision no information could be obtained. The mother of the sibship III. 2—4 was colour-blind; she had one sister, II. 3, unmarried, who also was colour-blind, one sister was known to have normal colour vision and nothing was known of the colour vision of two brothers, II. 1 and 2, and three sisters, II. 7—9; all the brothers and sisters of II. 4 appear to have died without issue; no information could be obtained concerning the colour vision of the parents of these colour-blind females, thus we are not in a position to say whether the father was colour-blind or not, nor whether the mother was a carrier, nor can we affirm that all the sons of II. 4 were colour-blind. Consanguinity. (See Bibl. No. 405.)

Fig. 581. *Bell's Case.* Colour-blindness in two distinguished men of science. IV. 5 was first discovered to be colour-blind when, as a little boy, he was sent to look for a stick of scarlet sealing-wax which had been dropped on the lawn and which he failed to find; his daughter, V. 7, writes that he could only see bright blue and yellow, violet or purple he called blue if there was sufficient blue in them, but if red preponderated he became confused and called them brown; stories are told of how he was let down by his tailor who made him a pair of rather bright green trousers with red spots which he thought were two shades of brown, and on another occasion a pair of bright apple green gloves were sold to him instead of pale lavender ones. He could draw very well; his sepia sketches were charming, and he seemed to think they matched what he saw. Two of his daughters were artists and considered that they could not have a more delightful companion than their father in a picture gallery, and that he had an unerring instinct for the "good" in art. He was greatly interested in the subject of colour-blindness and did not know of any other case having occurred in the generations preceding him; his parents were second cousins and there had been many intermarriages between the two families at an earlier date; his mother's family belonged to an old firm of manufacturers of dye-stuffs (dry salters) and if any member of the firm had been colour-blind it would almost certainly have been detected; some of his father's family had also been in partnership in the firm; his mother's brothers, III. 1—4, were good painters in water-colour and one of them was a caricaturist of some repute; his father, III. 7, was a man of scientific tastes and great ability, he was a manufacturing chemist. Thus we have no positive information that there was no colour-blindness in generations I, II and III of this pedigree, but it is improbable that able men carrying on work as manufacturing chemists, or the manufacture of dye-stuffs, could be affected without being aware of the fact.

IV. 5 had one son and four daughters, who believe themselves to have a very good colour-sense; the subject has been much discussed amongst them since their earliest childhood. The two brothers and the sister of IV. 5 were believed to have normal colour vision, but IV. 4 was a sugar manufacturer in Demarara and had been much abroad; IV. 2 had one son, however, who appears to have had some less severe degree of colour-blindness. The widow of V. 1 believed that he was not colour-blind, she writes that he took a great interest in the subject and often asked his students and friends for their judgment of colour; she says that his sight was abnormally clear, that when he sketched his greens were very green and that he hardly ever saw blue in distances unless very great; we are told, however, by a colleague who worked in close connection with him for some years, that he could never see yellow in the spectrum; there is no doubt whatever about the accuracy of this observation, for he was a man of great scientific distinction and the point must have frequently arisen, and been a source of some difficulty in his work. V. 7, first cousin to V. 1,

writes that she had on occasions arguments with V. 1 about yellow, which he said was the same as light brown, also about greens; she considered that he had not acute colour sensibility. It appears to have been established that he was a case of what, under Edridge-Green's classification, is known as trichromic vision.

V. 1 had two children, both believed to have normal colour sense; one of them, VI. 2, has four children, of whom two have been tested; VII. 1, aged 15, and VII. 3, aged 10, were shown to have a good average colour sensitivity by means of Houstoun's apparatus, they did the Edridge-Green card test correctly throughout and both named yellow amongst the colours they saw in a small pocket spectroscope,

Information has been obtained about a number of descendants of II. 4 and of the siblings of III. 7, but no hint of a further anomaly of colour vision has been discovered in the stock. We have no knowledge of the family of IV. 1, the mother of V. 1, and so are unable to suggest what is the probable source of the defect in V. 1. Consanguinity. Hitherto unpublished.

Fig. 582. *Wickham Legg and Bell's Case.* Thirteen cases of colour-blindness in a pedigree extending over eight generations; only two of the cases have been examined, in each the defect was found to be very severe, and they believe that all the affected members of the family had the same difficulties in distinguishing colours; we have no doubt that all the members marked as colour-blind in the pedigree really are so, but we cannot insist that other cases would not be found if further examination could be made. V. 35 writes, "I believe the colour-blindness is chiefly due to not seeing red; at a very short distance I cannot see red at all; coming into a harbour on board ship I can see the green signal lights quite clearly but not the red lights at all till close in; I cannot be sure of light shades of pink and often think they are blue; I am not sure of dark red, dark brown and dark green; light green and yellow seem the same unless adjacent; purple and dark blue seem the same unless adjacent. Though I served in the army 33 years, have twice been round the world and have stayed a good deal on the Continent, I only once was detected as being colour-blind and that was by a girl at a dinner party who asked me who a lady was in a pink dress, to which I replied I did not know; afterwards the lady she referred to turned out to be my wife and she then said 'Why you are colour-blind.' I had many narrow escapes however in colouring official plans and diagrams." V. 35 adds that his two brothers, V. 32 and 40, his third cousin, V. 5, his two first cousins, V. 27 and 28, and his half first-cousin, V. 23, were all affected just as he was; his half first-cousin, V. 20, he knew to be colour-blind, but had no knowledge as to the severity of the defect in his case. III. 11, grandfather to seven affected grandsons, was well known in the family to have been colour-blind; III. 2 was also well known to have been colour-blind, he was once reproved by the War Office for writing a letter in red and black ink.

On testing V. 35 we first tried him with Houstoun's apparatus, but he appeared to recognise no colour with certainty; red he would say was dark, green he said was a dark colour, for blue he said, at the focus itself, that it might be blue, and yellow he said might be yellow or light brown. He volunteered the statement that he saw more difference between colours by lamplight than by daylight, so we tested him with Edridge-Green's cards in daylight and again by artificial light, shaded alternately in orange, yellow, red, blue, green and purple; the result was very striking and is shown in the following table.

No. of card	Daylight	Orange	Yellow and red	Blue and green	Purple
1	Reads blue M	Reads easily			
2	Fails	,, ,,	Can read letters		Finds purple light
3	Fails	,, ,,	in each but with	All colours look	very difficult, can
4	Reads yellow S	,, ,,	hesitation or less	the same: can	see no letters, all
6	Sees when shown	,, ,,	readily than in	read no letters	colours look the
7	Fails	,, ,,	the orange light		same
8	Fails	,, ,,			

So far as can be judged from a small pocket spectroscope, V. 35 does not appear to have shortening of the red end of the spectrum, but this test cannot be relied upon and other considerations would lead one to expect that shortening would be found under adequate methods of testing. I thought it would be of interest to test the effect of distance on the colour discrimination of V. 35, and Dr Percy Stocks arranged a series of coloured cards 10 cm. square for the purpose; the result of this examination is given in the table below.

All we can say of the result of this test is that judgment varied with distance, but there was no assurance of stability in the judgment at any distance. We thought it would further be of interest to see how so severe a case managed to sort different coloured beads, and were astonished to find that this test was carried out almost entirely without error; the subject appeared to be very sensitive to different shades of the same colour, but he did not care to name any of the colours, and when asked to drop them one at a time through holes in labelled sections of a closed box it appeared to be almost entirely done by guessing and was usually wrong.

Test cards	Readings at varying distances			
	15 metres	10 metres	6 metres	2 metres
Dark red	Dark	Dark	Dark ?red	Dark
Dark green	Dark	Might be blue	Might be green or pink	Might be yellow
Light green	Light, ?yellow	Might be pink	Dark, ?red	Might be brown or pink
Pink	Light pink	Pink	Pink	Light pink
Blue	—	Might be brown	Might be pink or blue	Light blue

V. 5, aged about 80 years, kindly consented to carry out a few tests, and it appeared that he also was severely affected: he could see no difference between pale blue and pink beads; he was right in dropping blue beads into the blue section of a closed box and yellow beads into the section labelled yellow, red beads were placed in red, in green and in brown sections; green beads were found in sections labelled red, green and orange; an orange bead was placed in section labelled brown. V. 5 failed to read the following of Edridge-Green's cards—2, 3, 5, 6, 7, 8, 14, 16; he was able to read the letters, but could not usually name the colours on cards 4, 13, 15 and 19; he was then tired and we were unable to trouble him with further tests.

V. 44 was present when her husband was tested and it was quite clear that she was normal and saw all the mistakes which he committed.

Enquiries have been made by the family concerning the colour vision of other members of the stock, and all individuals marked in the pedigree chart as normal are said not to be colour-blind, excepting the following, about whom no information on the subject could be obtained from the very full family records—I. 1 and 2, all of generation II, III. 3, 13 and 14, IV. 12, 13 and 14, V. 7, 25 and 26. One family record states that III. 7 was to some extent colour-blind and III. 8 possibly colour-blind. Another record gives them both as normal; a grandson and a granddaughter of III. 7 both write, saying that they never heard he was colour-blind.

This pedigree was originally published in 1881 by Wickham Legg, writing on Haemophilia, as an illustration of the type of inheritance holding for that disease; with further information we have been able to remove three doubtful cases and to add three further cases of colour-blindness to the history, also to bring the pedigree up to date; the former account gives no details of any cases. Nettleship and Usher took a considerable amount of trouble in their endeavour some years ago to identify the family history given by Wickham Legg, with a view to linking up the pedigree with other histories in their possession, but they had no success: it was quite by chance that we noticed the identity of the two pedigrees whilst preparing the one we had investigated for the press. Consanguinity. (See Bibl. No. 160, with additions.)

Plate XL. Fig. 583. *Bell's Case.* Colour-blindness in three males and one female of three consecutive generations. IV. 7 was discovered to be colour-blind when, as a small boy in Australia, he was out with his father who called his attention to the lovely red flowers of the gum trees; he could see no red flowers, but on getting nearer he saw the shape of the flowers, which appeared to be very much the same colour as the leaves; on approaching nearer again he describes how "the red flowers suddenly flashed out before him," and he could at this distance see their redness and appreciate it quite well. He appears to be frequently conscious of the fact that the colour of an object is changing as he approaches nearer to it, and he believes there is a definite critical distance at which he is able to recognise colours. In order to test this point we showed him a large wall-paper design of pink flowers and red berries, on a background of light and dark green leaves; at a distance of 15 metres he described it as "brown patches on a rather dirty yellow"; at 11 metres he said the background was yellower and the brown was becoming more red; at 9 metres he saw a "brown background with pattern of green leaves"; at 7·5 metres he saw leaves more distinctly of a greenish-yellow colour, with berries which were almost white; at 6 metres the leaves were distinctly green and the berries pink. We further tested him with coloured cards 10 cm. square, placed in a series, their order in the series being altered between each trial; the result of this test is shown in the upper table on p. 263. If then there is for IV. 7 a critical distance within which he can recognise red, that distance is presumably greater than 15 metres for objects 10 cm. square; it would appear, however, that his perception of red at 15 metres resembles his perception of dark green at 13 metres, but differs from his perception of green at 11 metres.

On being tested with Houstoun's microscopic apparatus, IV. 7 always called red black, and green also he called black, but he was sure he would never confuse red and green signal lights because the green was always to him so much brighter than the red. On being tested with regard to reaction times by means of a dotting machine in which he had to notice the difference between red and black dots and react accordingly, he invariably performed the same operation, as he could see no difference between the red and black dots.

Sorting coloured beads he confused green with brown, light green with yellow, pale blue with pink and dark green with black, but he never in this test confused red with green. He said that he always recognised only blue and yellow, and that if the slightest trace of red was mixed with the blue the colour at once disappeared and became a greyish-black.

Metres distant	Coloured cards 10 cm. square					
	Dark red	Red-pink	Pink	Blue	Light green	Dark green
15 (*a*)	Brick red	Redder pink than (*a*)	White	Blue	Pink (*a*)	Brown-red
„ (*b*)	Dark red	Red-pink	„	„	„	Red
13	Red	Pink	White	Blue	Green	Red
11 (*a*)	Red	Pink	White	Blue	Light green	Dark-green
„ (*b*)	„	„	„	„	Green	„
„ (*c*)	„	„	„	„	„	„
7·5	Brick-red	Red	Pink	Blue	Green	Dark-green
6	„	„	„	„	„	„

IV. 7 is a medical man with scientific tastes; he is very interested in the subject of colour vision and has rather closely watched his own defect; he insists on the marked variability in his colour sensitivity from day to day, which appears to him to some extent to be dependent upon the state of his health: on one occasion when looking through his microscope at a slide stained with haematoxylin and eosine, he was much struck by the wonderful display of reds and blues which he saw; he had never seen anything like it in his microscopic work before; he noted that he was at this time feeling particularly vigorous. Testing with Edridge-Green's cards in daylight and in artificial light shaded with different colours, we obtained results which are summarised in the following table.

No. of card	Daylight	Red, orange and yellow	Blue and green	Purple
1	Reads M	All cards read quite promptly without hesitation	Very little of any card read in these lights, but marked sensitivity to difference of shade is shown	Reads M
2	*Reads N			„ N
3	Fails			„ C
4	*Reads S			„ S
6	*Reads G			„ G
7	*Reads N			„ N
8	Fails			„ C

* All read with much hesitation and colours wrongly named.

These results are anomalous only so far as the hesitancy or inability to read letters and inability to name colours in daylight are concerned; the response to the tests so far as reading the letter is concerned is entirely normal under the influence of other coloured lights, and the main interest centres in the facts that red, orange and yellow light definitely provide contrasts between colours which are indistinguishable or closely similar to the colour-blind, and further that though in daylight the subject will confuse red and green and see little distinction between them, these two colours differ so markedly in their effects upon his vision when he is subjected to them individually in a concentrated manner.

IV. 7 has three brothers and one living sister, all of whom have been tested; IV. 4 was tested in Australia where he lives and was found to be normal; IV. 5 was rejected from the Air Service on account of colour-blindness; IV. 6, a medical man, has always believed himself to be normal and has found no difficulty in his medical work with the colours of stains and precipitates or colorimetry, but he did fail to see red tubercle bacilli, when presented to him on a slide for diagnosis in his M D. examination, he noted the organism, and said to the examiner, "if that were red I should say it was tubercle bacillus," the examiner replied that it was bright red; on testing IV. 6, however, with Edridge-Green's cards, he read them all without the slightest hesitation, and laughed at his brother's inability to do so. IV. 8 was tested and found to be normal.

Of the parents of this sibship, the mother, III. 6, was reported to be colour-blind to a less degree than

IV. 7; she was not scientifically tested, but could not see the red flowers on the gum trees and constantly made mistakes about colours, and required help when purchasing coloured objects; she was tested by her husband in this sort of way. Her father was said to have been very badly colour-blind. Her paternal grandfather, I. 1, was an artist and architect, and was believed to have had normal colour vision. Nothing is known of the maternal grandparents of III. 6, and no tests have been made upon her siblings, but none of them are known to be colour-blind. II. 6 is still living, but it has not been found possible to obtain information from her concerning her father or her son. IV. 1 and IV. 9 were tested by IV. 7 and were believed by him to have normal colour vision. No consanguinity. Hitherto unpublished.

Fig. 584. *Schoeler's Case.* Colour-blindness in nine males and two females in three sibships in three consecutive generations. All these colour-blind individuals found difficulty in distinguishing between green and red; a red roof among green foliage could not be distinguished; a pale straw-thatched roof was to them in striking contrast to the green of the trees; pale blue and pink were difficult to distinguish; green and blue they found markedly different by lamp light. I. 2, by her first marriage in 1787, had a son, II. 2, with normal colour vision, who had nine normal children; by her second marriage in 1789, I. 2 had five colour-blind sons, two of whom, II. 4 and 7, married and had children. II. 4 had ten children with normal colour vision; II. 7 had three daughters of whom two were colour-blind. One of these colour-blind daughters, III. 6, married her first cousin, III. 3, and had six children, four sons who were all colour-blind and two daughters with normal colour vision. One of the colour-blind sons, IV. 2, and one daughter, IV. 4, were deaf mutes. Consanguinity. (See Bibl. No. 136.)

Fig. 585. *Vogt and Klainguti's Case, Ob.* Red-green-blindness in a father and daughter. III. 3, female, aged 12, was examined and found to be red-green-blind; her sister had a normal colour sense. Her father, II. 11, also was demonstrated to be colour-blind; he had four brothers, who were not tested, but were not known to be colour-blind; his parents, I. 3 and 4, were dead. The mother, II. 2, two of her sisters, II. 3 and 5, and four of her brothers, II. 1, 8, 9, 10, were all examined and found to be normal; the maternal grandmother, I. 2, was also tested and found to be normal; the maternal grandfather, I. 1, was dead. No consanguinity recorded. (See Bibl. No. 409.)

Fig. 586. *Bell's Case.* Colour-blindness in three brothers; their two sisters have a very keen eye for colour. Both parents are said to have normal colour vision. I. 1 writes that he had never heard of any of his father's or mother's relations suffering from colour-blindness and he believed his wife's brothers to be normal. The colour-blindness in the case of II. 1—3 appears to be not very marked; they confused red and green a good deal, especially in strange objects, but they could soon learn to distinguish them fairly well for practical purposes. No consanguinity. Hitherto unpublished.

Fig. 587. *Schiötz's Case III.* I. 2 was twice married; he had two colour-blind grandsons, III. 2 and 7, by the two daughters of his first wife, and four colour-blind grandsons, III. 13, 15, 17, 18, through two daughters of his second wife.

A colour-blind man of a different stock, III. 9, had two children, a son, IV. 5, and a daughter, IV. 6, with normal colour vision. IV. 5 married IV. 4, a normal descendant of I. 2 by his first wife, who had a colour-blind brother, IV. 2, and was niece to III. 7; they had two sons, V. 1 and 2, of whom V. 2 was colour-blind, and three normal daughters. IV. 6 married a colour-blind man, IV. 7, and had four daughters, of whom two, V. 4 and 7, were colour-blind, V. 5 and 6 had normal colour vision. No consanguinity recorded. (See Bibl. No. 408.)

Fig. 588. *Klainguti's Case.* Colour-blindness associated with Retinitis Pigmentosa in two males and two females of a sibship of seven, the offspring of second cousins.

V. 1, V. 2 and V. 4 were all examined, they had never had any eye disease and had normal colour vision; they were aged 19, 18 and 16 respectively. V. 3, aged 17, had fundi characteristic of Retinitis Pigmentosa; R.V. $= \frac{8}{200}$, L.V. $= \frac{10}{200}$; fields showed concentric contraction; there was no photophobia; a coarse horizontal and rotatory nystagmus was present; markedly lowered adaptation was noted; colour vision was tested with wools and Stilling's Tafeln, red and yellow, green and blue were confused; the same green was described at one time as brown, then as sky blue. Wassermann was negative. V. 5, aged 13, had fundi showing Retinitis Pigmentosa, R.V. = L.V. $= \frac{6}{36}$; fields were contracted; no photophobia was present; slight horizontal nystagmus was noted; dark coloured wools were with hesitation correctly grouped; light rose and yellow were confused; both ends of the spectrum were shortened and the brightest place in the spectrum was said to be in the orange-red region; dark adaptation was lowered. V. 6, aged 11, had Retinitis Pigmentosa, associated with horizontal nystagmus and no photophobia; R.V. = L.V. $= \frac{6}{36}$; coloured wools were with difficulty correctly grouped; red and yellow were confused; errors were made in Stilling's test; both ends of the spectrum were shortened; the brightest region of the spectrum was in the yellow; temporal fields were contracted and dark adaptation lowered. V. 7, aged 8, with Retinitis Pigmentosa, nystagmus and no photophobia, had R.V. = L.V. $= \frac{6}{24}$; wool tests were carried out successfully, but with uncertainty and difficulty; errors were made in Stilling's test; both ends of the spectrum were shortened and the brightest region was at one time placed in the greenish yellow and then in the yellow; adaptation time and visual fields could not be examined. The recorder considered that all four patients had

a severe defect of the colour sense, but the cases are atypical and we cannot be sure that the colour-blindness was congenital, or that the pedigree properly belongs to the group under consideration. We are not told at what age the defective vision was first noticed.

The father, aged 46, the mother, aged 44, and a maternal aunt, IV. 14, aged 35, were all examined and had good vision, no night-blindness and no defect of colour vision. Consanguinity. (See Bibl. No. 413.)

Fig. 589. *Horner's Case.* This pedigree is of some historic interest as being the original history on the basis of which "Horner's Law" for the inheritance of colour-blindness was formulated. The pedigree has been frequently misrepresented in the literature of the subject, and we are glad to have been able to see the rather inaccessible volume in which the history is given and to reproduce the pedigree as it was originally described. Horner states that in order to simplify the pedigree he has omitted from it all unmarried daughters or siblings whose descendants were unknown; thus unfortunately we cannot feel assured that we have full information of the normal members of any sibships of the eight generations, except perhaps those of generation VIII. We have indicated this omission on our representation of the pedigree.

I. 1 was born in 1642; the recorder had no knowledge as to whether he was or was not colour-blind, but his two daughters, II. 2 and II. 4, had each a red-blind son, III. 2 and 4, both of whom were born in 1712. III. 2 had a normal daughter who transmitted the defect to two of her sons, V. 3 and 4; III. 4 had two normal daughters, one of whom married her colour-blind second cousin once removed, V. 4, and each had a colour-blind son, VI. 7 and V. 5. V. 3 had two normal daughters who had three colour-blind sons, VII. 1, 3 and 4. VI. 7 had five normal daughters, who all married, the eldest having two normal sons, one colour-blind son and one normal daughter; the second, VII. 9, had one normal daughter and one colour-blind son; VII. 11 had two colour-blind sons and two normal daughters; VII. 13 had one colour-blind son and three normal daughters, and VII. 15 had one normal daughter. Consanguinity. (See Bibl. No. 117.)

Fig. 590. *Butter and Nettleship's Case.* This case is of some historic interest as giving one of the earliest recorded cases of colour-blindness. Butter, in 1822, describes how IV. 6 at the age of 19, when making an artificial fly for fishing, made the body of the fly green when it should have been orange; his younger brother told him of his mistake but he only believed it when confirmed by others; he could see no difference between the orange and green threads. It was then found that he could not distinguish between red and brown, green and orange, pale blue and pink, violet and purple; his eyes were normally formed and his vision for form very acute in all lights. His maternal grandfather, II. 2, was reported "not to have possessed the faculty of distinguishing colours with accuracy." The father, III. 5, was a medical man; he had five children, of whom IV. 5 died, aged 11, IV. 7 died, aged 22, unmarried, IV. 8 died, aged 29, probably unmarried, IV. 9 had two sons, V. 11 and 12, who died unmarried, and were believed to have had normal colour vision.

In 1910 Nettleship made enquiries as to colour-blindness in the later generations of the pedigree. V. 2, a solicitor, and the eldest son of IV. 6, gave information, and elaborate genealogies of all branches of the stock for many generations were formed; only a few of the details obtained are inserted in the pedigree here given. The evidence was entirely negative; V. 2 enquired for each sibship, but could not hear of any further case of the defect and repeated for each "no trace of colour-blindness." Nettleship was of the opinion that the enquiry was worthless, as the reported absence of cases depends entirely upon statements of various members of the stock who had not heard of further cases in the family, and no examinations were made. The family appears to have taken considerable trouble in their enquiries, and there was no attempt on their part to conceal the defect, so that we feel that it is improbable that any further gross defect has occurred in the descendants of IV. 6.

If it be true that II. 2 was colour-blind, the defect may have been transmitted to his descendants through one of his other children, III. 3, but it was not found practicable to follow up these lines of descent. No consanguinity recorded. (See Bibl. No. 51.)

Note as to Plate XLI

No sibships of Plate XLI in which cases of anomalous trichromatism occur have been included in my provisional statistical considerations, which refer to colour-blindness with gross defect only. This plate embodies all the material I have been able to find which bears on the question of the inheritance of anomalous trichromatism; it is, of course, totally inadequate for the purpose of drawing any definite conclusions, though the few cases presented are certainly of sufficient interest to encourage further investigation.

It will be seen that of the thirty-one cases of anomalous trichromatism represented on the plate twenty-four are males and only seven are females: there is evidently, as in colour-blindness, a great preponderance of males amongst affected individuals. With regard to the seven affected females, four are known to have had a similarly affected father, and two of these four further had mothers who came of colour-blind stock; nothing is known of the parentage of I. 1, Fig. 591, or of III. 9 in Fig. 596; nothing is known of the mother's stock in cases II. 2 and 3 of Fig. 594; III. 10 of Fig. 598 is known to have had a

mother of colour-blind stock, her father had not been tested, so may or may not have been an anomalous trichromate. Of the two affected females with sons, one has three sons of whom two are anomalous trichromates, the other has two sons of whom one is an anomalous trichromate, the other is colour-blind. All these facts are of interest and significance.

We may take it from Houstoun's work that anomalous trichromatism does not constitute an extreme variation of normal colour vision: we are tempted to suggest that the pedigrees of Plate XLI indicate some close relationship in the nature of the defects known as anomalous trichromatism and colour-blindness respectively, and to predict that they will probably be found to present examples of a similar type of inheritance.

Plate XLI. Fig. 591. *Schuster's Case.* Deuteranomalous vision in a female and in two of her three sons; the index given by Lord Rayleigh's apparatus was similar in all three cases; the husband and father, I. 2, had normal vision. No consanguinity recorded. (See Bibl. No. 219.)

Fig. 592. *Hess's Case.* III. 2 had deuteranomalous vision; he had four children, of whom one son and one daughter had normal vision, two sons were green-blind. The grandfather of III. 2 was red-green-blind; it is not stated whether this relation was on the maternal or paternal side. No consanguinity recorded. (See Bibl. No. 397.)

Fig. 593. *Göthlin's Case V.* Four cases of defect in colour vision in two generations. II. 4, a male, was found to be red-blind, and also green-blind, neither defect being of a severe grade; he had two normal brothers, one brother, II. 11, who, according to tradition, was colour-blind and four normal sisters, all of whom were married; thus II. 2 had two normal daughters and a son, III. 2, who was protanomalous, with shortening of the red end of the spectrum; II. 8 had one normal daughter and a son, III. 17, who had the same defect as III. 2; II. 13 had two normal daughters and II. 14 had a son and a daughter, both of whom were normal. No consanguinity recorded. (See Bibl. No. 372.)

Fig. 594. *Hess's Case.* I. 1 had deuteranomalous vision; he had two daughters and one son, of whom the latter, II. 1, was green-blind, his two sisters, II. 2 and 3, had the same type of colour vision as their father; nothing was known of the colour vision in the mother's family. No consanguinity recorded. (See Bibl. No. 397.)

Fig. 595. *Hess's Case.* Protanomalous vision in three brothers. I. 1 and 2 had normal colour vision; they had four sons, of whom three had protanomalous vision. The deviation from the normal equation was greatest in the case of the eldest son. No consanguinity recorded. (See Bibl. No. 397.)

Fig. 596. *Guttmann's Case.* Colour-blindness and weakness of colour sense in different branches of the same family. I. 5 was reported to have been colour-blind; of his daughter's four children, two sons were deuteranopes, one son and a daughter had normal colour vision; four of their first cousins on their father's side were anomalous trichromates. III. 6—9, three brothers and a sister, were all examined and found to be anomalous trichromates; one of them, III. 6, was married and had a normal son and daughter, IV. 1 and 2; his other child, IV. 3, was only one year old and could not be tested. The parents and grandparents of this sibship were dead and there was no knowledge of their colour sense; in their father's family II. 11 and 12 were known to be normal, II. 9 was dead, but his daughter, III. 10, and his granddaughter, IV. 4, had normal colour sense; II. 13 was dead, he was the father of two deuteranopic sons, whose defect, however, probably came to them through their mother. Of the maternal relations of III. 6—9, II. 2 and II. 6 had normal colour vision, II. 4 was dead and had not been examined, but his three children were normal; the three children of II. 2, also two of the four children of II. 6, were normal. No consanguinity recorded. (See Bibl. No. 318, pp. 222—3.)

Fig. 597. *Wölfflin's Case.* Deuteranomalous vision in four brothers; their parents and their three sisters had normal colour vision. The anomaly appears in this case probably to follow the same type of inheritance as colour-blindness does; three of the four affected brothers were married and had between them five sons and four daughters, all with normal colour vision. Two of the normal sisters were married; II. 4 had two normal sons and two normal daughters; II. 6 had one normal son, one normal daughter, and one son, III. 11, with deuteranomalous vision. No consanguinity recorded. (See Bibl. No. 420.)

Fig. 598. *Göthlin's Case.* II. 1 and 3 were colour-blind according to family traditions; II. 3 was married and had two sons and two daughters with normal colour vision; both the daughters transmitted the defect: thus III. 4 had two sons and three daughters with normal colour vision, and two sons who were deuteranopes; III. 6 had one son, IV. 11, who was a deuteranope, one son, IV. 12, who had incomplete deuteranopia, one son, IV. 14, and two daughters, IV. 13 and 15, with normal colour vision. II. 1 and 3 had one sister, II. 5; she and her husband were believed to have had normal colour vision, they had three children, of whom III. 9, a son, was a deuteranope, III. 10, a daughter, had deuteranomalous vision, and III. 12, a daughter, had normal colour vision. III. 9 had two sons with normal colour vision. III. 10 had a son, IV. 18, with deuteranomalous vision, two daughters with normal colour vision and a son, IV. 21, with deuteranopic vision. The recorder suggests from this history that deuteranomalous vision indicates a slight degree of green-blindness. No consanguinity recorded. (See Bibl. No. 372.)

Fig. 599. *Guttmann's Case.* An anomalous trichromate, II. 6, married a normal woman, whose sister, II. 8, brother, II. 10, and sister's son, III. 9, also had normal colour vision; they had a deuteranopic son, III. 7, and a normal daughter, III. 8. The normal sister, II. 4, of II. 6 had two sons, III. 5 and 6, who were both anomalous trichromates; one of these sons was married and had two normal children, IV. 2 and 3. II. 1 and III. 2 were also known to have normal colour vision; no defects of colour vision were known in the family of II. 5. No consanguinity recorded. (See Bibl. No. 318, pp. 222—3.)

Fig. 600. *Döderlein's Case.* This pedigree is of special value on account of the very detailed examination which has been made upon every member of generations III, IV and V, except III. 21 and 28, who were no longer living at the time of the investigation. The recorder is describing his own family who are descendants of his colour-blind great-grandfather, I. 2, and who have married three times into another colour-blind stock, the descendants of which are named Schoen.

I. 2 was not examined, but was classified as "red-green-blind," on the basis of reports from his aged son-in-law, II. 14; by his first wife I. 2 had five sons, who all married and, according to the accounts of their children, they and their wives all had normal colour vision; the children of these five sons and their descendants all had normal colour vision, except III. 17, who is classified after Hess as being "relatively red-sighted." The source of the anomaly in the colour vision of III. 17 cannot be assumed to have any association with the defect in his paternal grandfather, in the absence of any knowledge of the colour vision in the father of II. 10, or in her family; III. 17 married a member of a colour-blind stock, III. 18, who had herself normal colour vision and had three sons, of whom two, IV. 14 and 15, were green-blind, one had normal colour vision, and two daughters, one of whom, IV. 16, had "relatively red-sight."

By his second wife I. 2 had a daughter, who transmitted the defect to all her three sons, III. 24, 26 and 28; she also had two daughters, III. 22 and 23, with normal colour vision, one of whom married the colour-blind son of II. 12, and the other became the second wife of II. 12 himself; III. 22 had two sons and a daughter with normal colour vision; III. 23 had a daughter and four grandchildren, all of whom had normal colour vision. III. 24 and 26 were tested and stated to be "green-blind"; III. 28 was known from the accounts of his relatives to be either red- or green-blind. III. 19 was tested and described as "green-blind"; he had two sons with normal colour vision; III. 21 was known from the accounts of his relatives to be either red- or green-blind. The female, IV. 16, with "relative red-sightedness" had one child, a daughter, with normal colour vision. No consanguinity recorded. (See Bibl. No. 394.)

Fig. 601. *Wölfflin's Case.* Deuteranopic and deuteranomalous vision occurring in members of the same family. I. 1 and 2 had normal colour vision; of their four children, two daughters, II. 2 and 6, had normal colour vision, two sons, II. 3 and 5, had deuteranomalous vision. II. 2 had three children, of whom a son and daughter were normal and one son, III. 3, was a deuteranope. II. 3 had three normal daughters. II. 5 married II. 7, whose father was a deuteranope; they had two daughters and one son, of whom one daughter, III. 8, had deuteranomalous vision. No consanguinity recorded. (See Bibl. No. 420.)

ADDENDUM

Fig. 602. *Clausen's Case.* Since the completion of our plates for the press a further interesting pedigree showing red-green colour-blindness in thirteen males has been published by W. Clausen: the history, extending to five generations, is typical with regard to the mode of descent; no female is affected and eleven of the cases are known to have occurred in the sons of the normal daughters of two affected fathers.

The pedigree occurs in the appropriate section of a paper of wide scope entitled "Die Vererbung in der Augenheilkunde," which includes an extremely valuable bibliography of published cases of inherited anomalies and diseases of the eye. This work should lighten the labours of all subsequent workers on the subject. (See *Zentralblatt f. d. gesamte Ophthalmologie,* Bd. XIII. S. 1—55, 161—218. Berlin, 1925.)

602

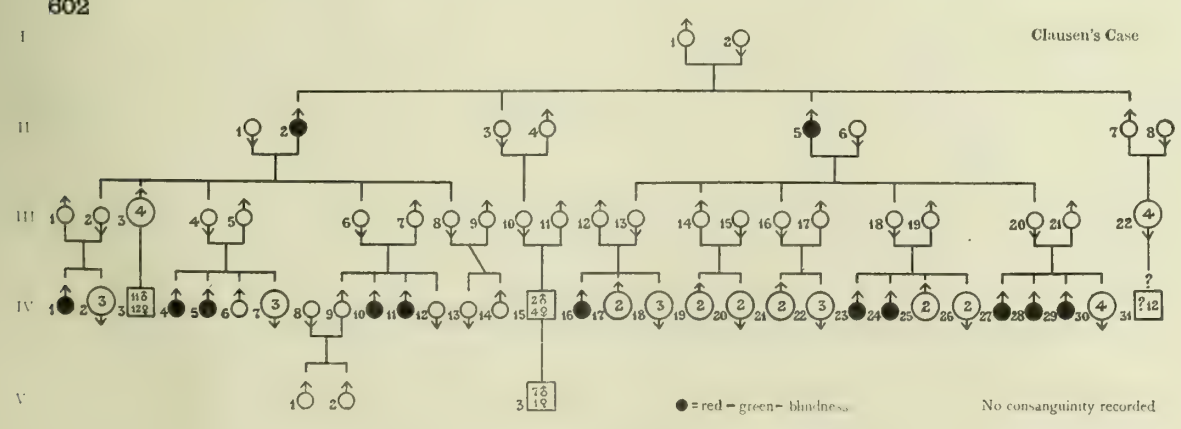

PLATES XXVII–XLI OF PEDIGREES

"BLUE SCLEROTIC PEGGY."

(From a coloured sketch kindly provided by Dr. E. A. Cockayne.)

Adlard & Son, Limited, Impr.

BLUE SCLEROTICS AND FRAGILITY OF BONE

I. INTRODUCTION

(*a*) *History of our Knowledge of Blue Sclerotics.* In the course of an investigation regarding the inheritance of diseases and anomalies of the eye, the subject of blue sclerotics came under consideration, but at an early stage of the enquiry it became apparent that the much more serious disability of bone fragility was so frequently associated with blue sclerotics, that it would be of advantage to combine in the same memoir an examination into the hereditary factor for each condition (*a*) separately, and (*b*) in association. Some of the questions we ask ourselves at the outset are as follows: (i) Are the two associated conditions, as has been suggested, the expression of an inherited failure to develop normally on the part of fibrous structures throughout the body? (ii) Do they represent two separately inherited conditions, the one interfering with the normal development of the sclerotic and the other with the normal development of bone? On this latter hypothesis can we throw any light upon the nature of the link which so frequently tends to produce the two anomalies in the same subject? (iii) Are we to consider a third factor, liability to dislocations and sprains, indicating, as it does, an anomalous development leading to hyperextensibility or hypotonicity of ligaments, as a separately inherited condition? May this anomaly be the result of the general inability of the fibrous tissues of the body to develop normally, or is it merely another manifestation of the underlying source of the defect in bone formation, or of the defect in the development of the sclerotic? A superficial survey of the material presents difficulties to be overcome before the acceptance of any of these hypotheses can be recommended. (iv) Another commonly allied defect is that of deafness due to otosclerosis, and though I am not prepared in this paper to examine the question of the inheritance of otosclerosis as such, I hope that the result of the investigation may lead to suggestions bearing on that subject.

One of the chief difficulties which faces us at the outset lies in the widely differing periods at which the recognition of these conditions as clinical entities or as hereditary defects, or as allied hereditary defects, have taken place: we cannot, for example, assume that the earlier accounts of hereditary bone fragility were not associated with blue sclerotics because no mention is made of the latter anomaly; it may well be that the blue sclerotics were not looked for or that their significance escaped notice though present. Again, we cannot assume that the earlier described accounts of blue sclerotics were unassociated with bone fragility, for until the link was recognised and established as a fact, observers noted the blue sclerotics and sought no information concerning allied defects; this we know well because a number of family histories have been investigated from this aspect of the problem at a date subsequent to that of the original publication.

With regard to bone fragility, it is impossible to believe that this condition, symptomatic or idiopathic, localised or generalised, was not recognised at a very early period; for whatever the form or source of the trouble, the effect is so disabling or even so alarming that it could not escape observation. Although we find no reference bearing on the question in the works of such early writers as Hippocrates or Galen, all we can deduce from this is that these authors personally did not come across a striking case of the sort, which is by no means unlikely. Localised bone fragility resulting from cancer, from syphilis, from tuberculous disease or diseases of the nervous system, or generalised bone fragility resulting from certain forms of poisoning or occurring in old age, etc., are described relatively early; examples of such accounts are those due to Marcellus Donatus in 1588[1], to Fabricius in 1609[2], to Fontanus in 1639[3], etc., but Courtial in 1705[4] writes that all cases in which bone fragility has been noted have occurred in old people or in "gens pituiteux," or in people who have taken mercury. It is not until 1716[5] that we find the first probable reference to a case of bone fragility occurring in an otherwise healthy individual at an early age, indicating an inherent inability to form bone owing to developmental defect, and for some hundred years following this date the condition was not clearly defined but tended to be confused with rickets or with osteomalacia. The first account of a definite case of hereditary idiopathic generalised bone fragility, such as this paper is concerned with, appeared in 1788[6] in a dissertation published at Upsala by Ekman; it is a case of considerable interest, the condition was severe and was traced through three or probably four generations, one member of the family "was small and deformed and waddled like a duck," and the possibility of an associated congenital dislocation of the hip is suggested. Excepting a report of repeated fractures following trifling causes occurring in the three children of normal parents, published by Strack in 1807[7], no further hereditary cases appear to have been described until near the middle of the nineteenth century; since then some thirty more or less scanty histories of bone fragility without mention of blue sclerotics have been published. I may note here that though referring to generalised bone fragility, I am not at the outset convinced that the condition is always generalised, for the tendency of repeated fractures to occur in one limb only or in the lower limbs primarily, or in the upper limbs primarily, is striking in some individual histories, indicating that the grade of fragility may certainly vary in different parts of the same skeleton and may differ markedly in this respect as we pass from case to case; further, the variation in the affection of the skull in different cases offers another example of selection on the part of the underlying pathological processes. True idiopathic bone fragility is very rare, but when it does occur, the disability and resulting deformity may be of so severe a character that it is difficult to understand how a description of such cases occurring in members of a family escaped publication until so late a date; but this indeed is perhaps only another example of the fact, which an investigation into the historical aspect of any hereditary disease presses upon one, that the true significance of multiple cases of disease in the same family

[1] *Bibl.* No. 1. [2] *Bibl.* No. 3. [3] *Bibl.* No. 2. [4] *Bibl.* No. 4.
[5] *Bibl.* No. 5. [6] *Bibl.* No. 6. [7] *Bibl.* No. 9.

has not in the past been grasped, but such cases have been regarded as examples of the inexorable visiting of the sins of the fathers upon the children unto the third and fourth generation, without any enquiry into the nature of the sin referred to, or a recognition that it may consist simply in the giving birth to children to be thus "visited." Even so late as our own times we read of the scorn of so notable a writer as the late George Macdonald upon the suggestion that members of his own family should be protected from intimate contact with the disease to which they were able to offer so slight a resistance as a result of the diathesis bestowed upon them by their father, who was content to leave their fate in the hands of a beneficent deity; he writes: "Fancy telling our boys and girls not to nurse their withering brother for fear they should develop the same fell disease hidden in themselves! She is most kind, however, and does not know better[1]."

When we turn to the question of blue sclerotics all will agree that the appearance of individuals who are subjects of this affection presents so striking a picture that one cannot believe that the condition escaped recognition up to the time of von Ammon[2], who, in 1841, is evidently familiar with its occurrence, has dissected eyes in which blue sclerotics are a feature and makes the observation that the sclerotic in such a case is abnormally thin and implies that the effect seen is due to transparency; my reading, however, has failed to find more than such casual earlier references as those of Henzschel in 1831 (*Zeitschrift f. d. Ophthalmologie,* Bd. I, S. 52—54), who observes in describing a case of hereditary aniridia in a female that her sclerotic was very thin and in many places the choroid could be seen through it, or of Gescheidt, who, in 1832 (*Zeitschrift f. d. Ophthalmologie,* Bd. II, S. 257), refers to the bluish white sclerotics in a case of hereditary microphthalmos; in neither of these cases do we know whether other members of the family also had blue sclerotics, and subsequent investigation reveals that it is not usual to find blue sclerotics in association with cases of hereditary aniridia or microphthalmos. Though von Ammon fully appreciates the fact that the thin transparent sclerotic is characteristic of this membrane in the foetal stage and may persist when there is some interference with the normal development of the eye, he has evidently never noted a case in a healthy individual in which heredity is a marked characteristic and in which other clinical features are strikingly linked with the eye defect in many individuals concerned with the history presented. It is not until more than fifty years after the date of von Ammon's work that we find the first undoubted description of a case belonging to our group in which the condition is hereditary and is associated with brittle bones; in the interval we find a number of references to the condition of which the following from Cornaz[3], in 1848, is an example: "La sclérotique offre parfois aussi une couleur bleuâtre qu'il n'est point rare d'observer lorsque l'œil est resté en arrière dans son développement: cette membrane est alors très-mince et transparente. Cette altération n'est pas rare chez les microphthalmes, et a été observée par d'Ammon dans un cas d'hydrophthalme: on trouve aussi des cas où

[1] Macdonald, G., *George Macdonald and His Wife*, p. 492, London, 1924.
[2] *Bibl.* No. 12.
[3] *Bibl.* No. 15, p. 67.

la sclérotique n'a pas cette abnormité dans toute son étendu, mais tant seulement à une place ou en plusieurs points...."

The first history of hereditary blue sclerotics was not published till as late as 1896 when Spurway[1] described an interesting family in which members of three or probably four generations had suffered from repeated fractures, the four affected members of one sibship having had seventeen fractures between them; at the end of the account the recorder adds, "the only other feature I have noticed common to many members of this family is a curious bluish tinge of the eyeball which in some is very marked." We can judge from a knowledge of other histories that it is safe to assume that all cases in which there was bone fragility in this pedigree had also blue sclerotics, but the converse is far from the truth and we are not able to say that members who had no history of fracture were without blue sclerotics; hence, though we know that this pedigree belongs to the group in which blue sclerotics is a characteristic, we are able to make no statistical use of it. Thus more than a hundred years elapsed between the publication of the first history of bone fragility and the first history of blue sclerotics, and of pedigrees published in this interval it is not possible of any individual case to say to which group it belongs, but an examination of the facts of heredity in the two groups should give some idea as to whether we are dealing with different manifestations of the same defect or with two separately inherited characters.

(*b*) *Bone Fragility.* The particular type of bone fragility which tends to be hereditary and with which this memoir is concerned is commonly known as *osteopsathyrosis idiopathica*, after Lobstein, but descriptions of cases have been frequently given under the titles of osteogenesis imperfecta, periosteal dysplasia, foetal rickets, fragilitas ossium, brittle bones, or even mollities ossium, for the bones of such cases, though frequently described as brittle and liable to fracture, would appear also to be markedly pliable and liable to bend. I do not know whether there is absolute incompatibility between these two attributes—brittle and pliable—but clinical observations on cases of osteogenesis imperfecta certainly suggest the former, and radiographs make it difficult to evade the applicability of the latter term. Lobstein[2] first clearly defined this condition, in 1825, in the following terms taken from the French edition of his work: "Il n'est pas rare de rencontrer sur les cadavres des os légers, cassants et fragiles. Si, sur de tels sujets, l'on presse du doigt l'extrémité des os longs, il pénètre sans effort dans sa substance, en faisant entendre une légère crépitation, et la dépression qu'on a ainsi pratiquée persiste. Il en est de même des os du carpe, du tarse, des corps des vertèbres. Tous ces os peuvent facilement être écrasés: séchés leur substance devient comme vermoulue et facilement pulvérulente. La partie moyenne des os longs, plus résistante, ne s'enfonce pas sous le doigt; mais au moindre effort qu'on fait pour la courber, elle casse comme du verre. L'examen anatomique de ces os montre que leur cavité médullaire s'est extrêmement agrandie aux dépens de la substance compacte; que les parois de cette cavité sont devenues excessivement minces et cassantes; ce qui explique à la fois leur légèreté et leur

[1] *Bibl.* No. 32. [2] *Bibl.* No. 10.

fragilité. Les côtes se brisent surtout avec une singulière facilité. Les os du crâne ne sont pas exempts de cette altération: alors ils sont en même temps amincis par la disparition du diploé; les deux tables qu'il séparait sont confondues en une seule.... Dans cette maladie on n'observe pas de gonflement aux os, si ce n'est dans la partie voisine des articulations. Le périoste n'est ni épaissi, ni abreuvé de sérosité, ni le siège d'aucun travail fluxionnaire; en un mot il n'y a point d'indice d'activité exaltée, point de surcroît de nutrition, c'est plutôt un appauvrissement, une inertie de cette même fonction. Une portion de gélatine serait-elle enlevée par l'effet de l'absorption augmentée?...Mais les observations de Troja prouvent que la fragilité ne dépend ni de la surabondance de phosphate de chaux, ni de la diminution de gélatine. La moelle ne conserve pas non plus sa consistance: au lieu d'être huileuse, elle devient comme une gélatine dissoute; au reste rien ne prouve que la maladie de l'os ait commencé par cette altération de la substance médullaire."

Now we know that the long bones increase in length by the transformation of cartilage into bone at the growing ends of the bone, that they increase in thickness by the deposition of bone from the periosteum, and that the cortex is maintained at a uniform relative thickness by the absorption of bone on the part of the osteoclasts of the marrow within the cavity: one would, of course, expect that there must be some coordinating link between these processes, and that any marked deviation from the normal in one of them would have correlated abnormalities in the other parts of the system, and indeed histological examinations have shown this to be the case[1], for though the most striking defect, which is undoubtedly the immediate source of the fragility, lies in the periosteal failure to lay down compact bony cortical layers, histological examinations do also reveal abnormality in the transformation of cartilage into bone, and as a result the bones are not only too slender and friable, with a thin cortex giving under X-rays a shadow little denser than the surrounding soft parts, but also the long bones are often too short relatively to the size of the trunk.

Thus clinically, persons affected with hereditary bone fragility tend to be short in stature and slender in build; the shape of the head is often too a striking feature as a result of the very anomalous cranial ossification and tends to be characterised by protuberances in various regions. A bi-temporal protuberance, so marked as to turn the ears outward in some cases, is frequently described[2], but protuberances of the occipital region and again of the frontal regions are common features: see Plates A, B, N and O. In extreme cases the cranial ossification is so disorganised that the resulting vault of the skull may consist of a mosaic of small Wormian bones (see Plate E), and we owe to Lawford Knaggs the extremely interesting observation that the bones of the skull normally developed from membrane and presenting cartilage cells at no stage, do in this condition present cells closely resembling or indistinguishable from cartilage cells[3]. Bronson[4], describing an infant aged 6 months, a subject of this affection, who had at birth fractures of the left humerus and of the right tibia and at 6 months a fracture of the right humerus, writes, "he was first seen at the age of 1 month when,

[1] *Bibl.* Nos. 46, 47, 58, 102, 142, etc.
[2] *Bibl.* No. 82 A.
[3] *Bibl.* No. 142, p. 403.
[4] *Bibl.* No. 95.

as now, there was noticeable shortening of the proximal long bones. The shape of the head was entirely normal and symmetrical. Cranial ossification was deficient —a mosaic of bony islands over the occiput and the temporo-parietal region. The temporo-parietal suture lay open the width of one's finger. The sagittal suture was also gaping from the anterior to the posterior fontanelle. The anterior fontanelle measured 3 inches transversely. During the fourth month the temporo-parietal region began to ossify rapidly, and now membrane can be felt only at one spot above the right ear. At the same time the present bilateral bulging above the ears has become noticeable. This bilateral enlargement has increased up to the present, when it is sufficient to turn the ears slightly outward.... Ossification over the occiput has not progressed as rapidly as in the temporo-parietal region, and here, also, there will probably be abnormal protuberance when ossification is completed. The frontal bones showed no defective ossification when I first saw the child, and there is none of the frontal fullness and downward tilted axis of the eye which other cases may show." This case had a negative family history and no blue sclerotics. It appears then that the bossing of the skull may be attributed to delayed ossification in the regions affected, and it is extremely interesting to have this account of the development of the peculiarity under the eye of so close an observer.

In general health and intelligence the subjects of bone fragility do not appear to suffer but tend to maintain in these respects the standards of their normal siblings.

When we come to consider, however, what is the chief clinical manifestation of the condition and indeed constitutes the sole criterion on which the diagnosis is commonly based, namely the liability to fracture from inadequate causes, our difficulties are great, for the defect is evidently a graduated one so that every grade of liability to fracture occurs, and it is by no means clear how we are to decide what is an adequate cause of fracture—which moreover surely varies at different periods of life—and whether a history of repeated fracture alone without a knowledge of the causes may be taken as an indication of the defect. The question of personal equation here is of some significance; one individual is quicker to save himself from becoming the victim of an accident or from falling than is another individual under similar conditions; with regard to sex liabilities, the male may perhaps instinctively incline to more violent exertions and run more risks of accident than does the female, on the other hand, the slighter bone of the female may have less margin of safety before it reaches the boundary with regard to strength beyond which it should be defined as fragile; again, in a condition of fragility dating from infancy much depends upon the care and intelligence of the mother in avoiding fracture where the liability is suspected, and a well-nursed and carefully protected child may escape the diagnosis, who, under less favourable conditions, would reveal the weakness. Moreover, it cannot be asserted that an absence of a history of repeated fracture necessarily denotes freedom from the defect: let us consider from this point of view the description of the case of the man represented by II. 6 in Fig. 673, Plate XLVII. This man at his birth was found to have both arms broken but he was a fine child in other respects, and up to middle age, in spite of deformities and an accident at the age of 26 by which he seems to have injured both thighs, he could walk and work without inconvenience; after the age of 30 a gradual bending of his bones was noted and fractures

began to occur; at 40 his strength failed him, his bones became so brittle that they broke from the slightest blow and he grew so deformed as to be bedridden; his skeleton, now at the Royal College of Surgeons, shows typical signs of osteogenesis imperfecta, the skull shows numerous Wormian bones indicating that the morbid process was evidently present at the period of development, but the man appears then to have recovered and for many years led an active and normal life free from accidents; his two unfortunate children were subject to repeated fractures[1]. Now this history is an unusual one, but had this man died under the age of 30 his condition would have remained undiagnosed, and thus a history of fracture cannot be relied upon as a satisfactory criterion for diagnosis in all cases, though undoubtedly in a severe and active case this side of the picture may be, and generally is, a very striking one.

A basic feature of the defect appears, from histological examinations, to be an inability to form osteoblasts; these are commonly described as few in number and anomalous in structure, that is to say there is a failure on the part of certain primitive cells to differentiate into their normal tissues. Now the work of Strangeways and Fell[2], concerning the growth of the eye in vitro, has demonstrated a normal differentiation of tissues during development under such totally artificial conditions as those in which the organ is deprived of blood supply and cut off from all connection with the central nervous system; surely then one must conclude that something very fundamental is absent from the growing embryo which fails in this way, and it is difficult to understand how in some cases recovery or partial recovery appears to take place. Again, in a defect of such a nature one would expect its manifestations to show throughout the skeleton, yet how are we to classify cases in which there is repeated fracture of one bone only or in which the tendency to fracture appears to be primarily confined to one limb or to the upper or to the lower limbs only? Examples of such cases are IV. 9 of Fig. 692 (Plate XLVII), who had ten fractures of the left leg and three fractures of the right femur between the ages of 4 and 13 years; II. 3 of Fig. 686, aged 17, had had about forty fractures of the legs and in addition only one fracture of the humerus and one of the clavicle; notes of a case sent to me by Mr Fairbank describe a boy, aged $14\frac{1}{2}$, who had had six fractures of his arms or wrists from slight causes and one fractured sternum, but no fractures of his legs; his mother had fractured her humerus or wrist eight times and her legs three times; mother and son had blue sclerotics and the mother was deaf. In some cases the defect evidently shows itself during intra-uterine life, in other and perhaps less rare cases the onset of the disease appears to be after birth or even as late as adult life; again, in other cases there appear to be remissions of the disease or intervals in which no fractures will occur through a period of years and then spontaneous fractures or fractures from the most trifling causes will be reported. Perhaps most commonly the story given in hereditary cases is that the child appeared to be normal at birth, that fractures first occurred when he was learning to walk and that their frequency had tended to diminish after a term of years which differs widely in different cases. Other commonly described features in individual cases are the slightness of pain at the time of fracture and the ready healing, both factors being probably expressions

[1] *Bibl.* No. 18. [2] *Bibl.* No. 145.

of the fact that the injury was produced by slight force and thus the damage to surrounding tissues was reduced to a minimum. Gross deformity appears to arise largely as a result of carelessness; for the readiness of healing, slight pain and frequent recurrence of fracture all tend to encourage the patient or his friends in the practice of treating the injury themselves, whence from their lack of knowledge and experience deformity results.

A mere glance at the thirty-three pedigrees of bone fragility not known to be associated with blue sclerotics, which is all I have been able to collect from the literature, is sufficient to indicate that no statistical statements regarding the factors of heredity can be made on the basis of them; the pedigrees are not only few in number but are for the most part very scanty in extent and are often so incomplete as to give full information of no single sibship. Can we supplement this material by information taken from the pedigrees of blue sclerotics in which bone fragility is so frequently an associated defect?

(*c*) *Association of the Defects.* Let us consider first something of the nature of the two associated defects. In the case of blue sclerotics, the defect appears to be a quantitative one only, resulting in thinness of the sclerotic and thus in its relative transparency, but qualitatively the structure of the sclerotic does not demonstrably deviate from the normal in character. Thus the defect is not one of failure in the differentiation of structure such as appears to be the case in bone fragility, and in the pedigrees in which the two defects are associated, the quantitative defect dominates the position and is present in every case in which there is bone fragility as well as a considerable proportion of further cases in which there is no evidence of qualitative defect. It seems probable, therefore, that these two anomalies are not different manifestations of one defect but are two separately inherited anomalies, linked in such a way that the quantitative defect predisposes to the qualitative one, in other words, the factor leading to the presence of a thin sclerotic predisposes the individual to a faulty bone-producing mechanism. This double anomaly is further suggested by the fact that there is no direct relationship between the severity of the two conditions for very markedly blue sclerotics may be unassociated with other defects, whilst the less blue sclerotics may be associated with a history of repeated fracture from trifling causes; nevertheless it is undoubtedly a fact to be borne in mind that the two anomalies arise in tissues each of which is developed from the same primitive layer of cells.

Now we have to remember that the pedigrees of bone fragility were published as such, and incomplete as they may be, they are on the whole probably more accurate so far as they go with regard to bone fragility than are the pedigrees of blue sclerotics in which the bone defect is generally regarded as an associated factor only, and information may or may not be complete respecting it; also the pedigrees of bone fragility usually contain at least one case showing a severe grade of the defect which has called attention to the history and prompted the enquiry, whereas in the pedigrees of blue sclerotics there may be no single case of severe bone defect and the cases recorded merely indicate a history of fracture which perhaps only became of significance because so relatively large a number of members of the family had suffered from one or several fractures, no single case of which on its own merits would attract attention or

be regarded as a case of true bone fragility; thus we have a selection of material which differs for the two series and which may or may not be the source of differences found regarding them.

All these considerations tend to suggest that the two series of cases should not at present be combined, and I propose to look for further guidance on this point in an examination of the sex incidence and transmission of the defect in the two series. The following tables give comparative figures from which it appears that: (*a*) The sex

Sex Incidence of Bone Fragility

	♂	♀	♁	Percentage of Males in Affected Population
A. Bone Fragility with Blue Sclerotics	108	129	10	$45{\cdot}6 \pm 2{\cdot}2$
B. Bone Fragility	66	30	18	$68{\cdot}8 \pm 3{\cdot}2$

incidence differs markedly in the two series. (*b*) The apparent mode of transmission of the defect differs in the two series. The differing sex incidence is rather puzzling; the excess of males in Group B might be explained by the tendency of females with a slight grade of defect to protect themselves from accident, whilst the nature of their work may in the males be such as to favour the occurrence of accident. It is not easy to see why the same cause should not operate to produce more accidents to the males in Group A; there is however an excess of females in this group with blue sclerotics,

Transmission of Bone Fragility

	Percentages Affected		
	Through Mother	*Through Father*	*Uncertain
A. Bone Fragility with Blue Sclerotics	50·0	45·1	4·9
B. Bone Fragility	16·3	52·2	31·5

* Both parents normal and no indication through which stock the defect has arisen. In Group A, the presence of blue sclerotics frequently shows the source of the defect and thus lowers this percentage.

and it may well be that this affection predisposing the individual to a defect resulting in bone fragility is responsible for an excess of females in the group showing bone fragility. Now if we consider all cases of blue sclerotics we find that of 200 males thus affected, 108 or 54·0 °/₀ are known to have suffered one or more fractures, and of 248 females affected, 129 or 52·0 °/₀ are known to have suffered one or more fractures, that is to say there is no real excess of liability to fracture in the females of Group A, but the excess of liability to fracture shown by the males of Group B is in some way modified by the presence of the factor leading to blue sclerotics.

I can find no evidence that in either group the grade of liability to fracture when it is present is more severe, as evidenced by the number of fractures, in the male than in the female. This point is shown by the following table, which also brings out the fact that Group B on the whole represents a higher grade of defect than does Group A. It is, I think, clear from these facts alone that the conditions in the two series are not homogeneous and information concerning them cannot be combined. With respect to

the widely differing figures regarding the transmission of the defect, I am inclined to look upon these as probably entirely spurious and of no real significance, for in a condition leading in severe cases to deformity and marked disability the female is less likely to marry or to bear children than the male; moreover, in the small Group B in which we find so large an excess of males transmitting the defect, we find also a large excess of males affected; again, in a considerable proportion of the 31·5 °/₀ of

Percentages of Males and Females who have had Fractures

No. of Fractures	*Group A*		*Group B*	
	♂	♀	♂	♀
1—4	55·9	55·3	30·5	28·6
5—7	6·9	9·8	10·2	10·7
More marked Fragility	37·2	35·0	59·3	60·7

cases in which both parents were normal, there was no knowledge of their stock on either side, and it may well be that more complete information would largely add to the percentage of cases in which the mother's stock was responsible; it is contrary to all our experience of hereditary disease to find the mother so little responsible for its transmission. In Group A the more extensive pedigrees and the frequent presence of blue sclerotics in one or other parent, showing the probable source of the bone defect in the offspring, makes the information much more complete and the figures given probably represent something near the true position for this group.

With regard to the proportion of the offspring to be affected when one parent or neither parent is affected, I prefer to make no statement for the pure fragility group, for the numbers in which the sibships are complete and parentage known are too few to be of any value for such a determination; in the group for which a history of fracture is associated with blue sclerotics I find the following figures, suggesting that the father and mother are equally potent in transmitting a liability to fracture and that the affection of one parent does not markedly increase the proportion of the affected in the sibship.

	No. of Sibships	Offspring Affected	Offspring Normal	Percentage Affected
Father affected, mother normal	(27)	61	59	50·8
Mother affected, father normal	(36)	61	65	48·4
One parent affected	(63)	122	124	49·6 ± 2·2
Neither parent affected*	(33)	65	90	41·9 ± 2·7

* In twenty-four cases one parent had blue sclerotics.

One further point is sharply contrasted in the two series, namely the incidence of associated defects which is so marked a feature of Group A, whilst in Group B there is a very noticeable freedom from associated defect. I have already emphasised the fact that the histories of the latter group are scanty and very incomplete, but many of the individual cases are very fully described, and I think there is no doubt that

there is no single characteristically associated defect in this group apart from certain deformities resulting from the disease itself. It is of special interest and significance that in no single case of bone fragility unaccompanied by blue sclerotics are we told of a liability to sprains and in only one case do we read of dislocations; in no single case do we read of deafness; we shall see presently that these factors are frequent occurrences in histories showing blue sclerotics.

(*d*) *Nature of Blue Sclerotics.* "Blue sclerotics" are perhaps a misnomer, for from the date of von Ammon it has been recognised that the blueness does not belong to the sclerotic at all but is due to choroidal pigment seen through a more than usually transparent sclerotic. "Transparent sclerotics," however, may carry with it, the suggestion of qualitative defect, whereas Buchanan's[1] description of post-mortem examinations on two excised eyes subject to this defect demonstrates that in those cases the transparency was due to the thinness of the sclerotic, and that in structure there was a normal distribution of cell and fibre; this bears out, so far as it goes, the earlier naked-eye observation of von Ammon. The histological examination of Bronson's[2] case, however, is said to have revealed a sclerotic of normal thickness, the fibres of which were normal in number and size for a child of that age; this exceedingly careful observer deduces that the "blueness" more probably results from increased translucency than from decreased thickness; she, however, makes no suggestion as to the source of the exceptional translucency in a sclerotic which is of apparently perfectly normal structure, but notes that a quantitative chemical examination of a blue sclerotic should be made and compared with the normal when opportunity occurs; her case remains to puzzle us and we wonder whether it is known what is the normal thickness of the sclerotic for a child aged 11 months, but in the meantime evidence has accumulated in favour of the thinness of the sclerotic in these cases as an explanation of their transparency, in support of which, added to the examinations of von Ammon and Buchanan, we have the experience of ophthalmologists who have operated on such eyes, and further, the direct observation by means of the slit lamp described by several authors. The extreme thinness of the sclerotic in these cases—Buchanan estimates for his first eye examined that the cornea was three-fifths, the sclerotic only one-third the normal thickness—appears to lead to no disabilities of vision or characteristic errors of refraction and to no deviation from the normal of the ocular tension; there are no cases of buphthalmos noted in association with blue sclerotics, and indeed there is no special liability to eye defect or eye disease, or to any ocular anomaly in these people with thin sclerotics; we may, I think, conclude that the thin sclerotic is entirely adequate for the functions which it has to perform—a sufficiently surprising fact: the only disadvantage accruing to people possessed of the anomaly consists in the liability to much more serious defects, apart from the eye, which it carries with it and which may apparently be transmitted with the anomaly to the offspring by an individual who shows no signs of the associated defect himself.

This anomaly is evidently rather rare, for an ophthalmologist attached to a large hospital has come across one case only in the course of a career extending over many

[1] *Bibl.* No. 40. [2] *Bibl.* No. 83.

years; this evidence may appear to be inconclusive, in view of the fact that the condition usually carries with it no defect of vision which would take the individual of necessity to an ophthalmologist; nevertheless this specialist examines the eyes of a large number of patients in the year and would not fail to recognise the anomaly if it presented itself in any case. I have, however, succeeded in collecting seventy-three pedigrees which include 463[1] hereditary cases of the disease, and in consideration of the fact that no history of value as such was published earlier than 1903, this series of pedigrees has accumulated rapidly and is of great interest from the point of view of the inheritance of the condition; it also presents a number of problems arising from the liability of this defect to carry with it a predisposition to other defects of a more serious and disabling character. The grade of the defect, as measured by the depth of colour in the sclerotic, evidently differs widely in different members of the affected population and every variation occurs, from the extreme grade described as "blackish blue" to a mere bluish tinge only, similar to that seen normally in the newborn child; further individual variations are seen in the distribution of the anomaly, which in some cases is described as affecting uniformly the whole sclerotic and in other cases appears to be localised, or to be more marked in a zone surrounding the cornea. The condition is of course congenital and in only one history have I read of any change during life; this was in the children of IV. 29 in Fig. 602; their mother volunteered the statement that her three children were all born with eyes just like hers, but that the two eldest "lost the blue" in the first year of life; the third child, now aged $4\frac{1}{2}$ years, still has blue sclerotics; Bishop Harman, however, who saw the eldest of these children at the age of $2\frac{1}{2}$ years noted that his sclerotics were still blue, but less so than his mother's.

It would seem then either that the sclerotic of these people develops normally up to a definite point at which it remains stationary and further growth is arrested, or on the other hand the sclerotic in these stocks reaches its maturity before it has attained a thickness at which it is opaque; why should we say necessarily that there has been an "arrest" in the process of growth merely because most stocks grow a thicker sclerotic, which has therefore come to be regarded as normal? The thinner sclerotic appears to be, as we have noted, functionally adequate, and so we might argue that there is a superabundance of growth in the normal which is in excess of the needs of the individual and possibly brought about by aesthetic considerations,—an unconscious preference in favour of whiteness of the eyeball leading to its selection and perpetuation by inheritance. We cannot, however, blind our eyes to the very grave associated defects to which some sixty per cent. of these people with thin sclerotics are liable, indicating that in certain tissues developed from the same primitive layer in which more complex structures and further differentiation of structure is demanded, failure is not only quantitative but is also qualitative and the fully-developed tissue is no longer adequate for the needs of the individual; this does definitely point to some deep-seated inherent lack the nature of which is very obscure; moreover the obscurity is not lightened by the fact that other tissues in which there has been a

[1] This covers cases in which sex of affected was not given.

differentiation of structure to carry out specialised and complex functions are developed from this same primitive layer and show no signs of functional inadequacy.

(*e*) *Sex Incidence.* On examination of the pedigrees appended the large number of females with blue sclerotics becomes at once apparent. Now we have become accustomed to regard the male as peculiarly liable to be affected by hereditary disease and the female as being peculiarly potent as a transmitter of hereditary disease or anomaly; such a condition of affairs is seen in its extreme phase in such relatively sex-limited diseases as congenital dichromatism, congenital night-blindness (one type of the affection) and haemophilia, to give these examples only, and there is to our knowledge no single hereditary defect to which the female alone is liable or which is relatively sex-limited to the female; there appears, however, to be a definite excess of females amongst our affected population of individuals with blue sclerotics, the actual figures being 200 males and 248 females in a total of 448 cases; that is to say, 55·4% of the affected population are females, or there is an excess of eleven females in each hundred to be affected. I considered the possibility that this was a spurious result following from the fact that presumably on the whole the normal female sclerotic is thinner than that of the normal male—undoubtedly one would expect all tissues of the female to

Offspring of "Normals," who had affected Siblings

"Normal" Parent	No.	Offspring	
		Affected	Normal
Male	17	3	67
Female	15	3	50
,,	3	1	?*

* There were also normal offspring, but number not stated.

be on the average slighter in bulk than corresponding tissues of the male—and that it seems reasonable therefore to suppose that the female sclerotic would become transparent with a degree of thinning which would not be sufficient to bring about transparency in the male; this being so there may be a number of males in our population who are affected to a degree at which, however, in their case the defect is not conspicuous and escapes detection. I can find no evidence in favour of this supposition from an examination of our material; if it were so one would expect to find occasionally the commonly associated defects—bone fragility or otosclerosis—in males who have been classed as normal with regard to their sclerotics; or again, one would expect such males to have affected offspring; as a matter of fact we find two "normal" males of affected sibships who have each a history of one fracture and four "normal" females who have each experienced one or two fractures; two "normal" males and two "normal" females are deaf[1]. These few facts with the table given above are not adequate to prove anything, but they at any rate fail to provide any reason for supposing that there has been any tendency to sexual selection leading to the classification of the slightly affected males as normal.

It becomes therefore of interest to consider how exceptional a case we are dealing

[1] We must bear in mind, however, that there is always a tendency to make incomplete enquiries regarding the normal members of a stock.

with, with regard to sex incidence, and I have collected facts from pedigrees in the Galton Laboratory, published and unpublished, enabling me to give a value of the sex incidence for eighteen hereditary diseases, though in too many cases, as the probable errors show, the value given is based on too few numbers to be regarded as anything more than an approximation and might become markedly changed on the addition of new material.

Sex Incidence of Hereditary Disease

	♂	♀	Percentage of Males
Hereditary Optic Atrophy	730	135	84·4 ± 0·8
Hereditary Multiple Exostoses	498	211	70·2 ± 1·2
*Hereditary Bone Fragility	66	30	68·8 ± 3·2
*Diabetes Insipidus	72	36	66·7 ± 3·1
*Cleido-Cranial Dysostoses	62	33	65·3 ± 3·3
Angioneurotic Oedema	105	66	61·4 ± 2·5
*Total Colour-Blindness	54	40	57·4 ± 3·4
*Glioma Retinae	57	44	56·4 ± 3·3
Albinism	964	764	55·8 ± 0·8
Retinitis Pigmentosa	454	363	55·6 ± 1·2
[1]Digital defects	214	171	55·6 ± 1·7
*Ateleiosis	67	60	52·8 ± 3·0
Hare Lip and Cleft Palate	92	84	52·3 ± 2·5
[2]Night-Blindness	113	103	52·3 ± 2·3
Congenital Cataract	315	314	50·1 ± 1·3
*Achondroplasia	67	73	47·9 ± 2·8
Blue Sclerotics	200	248	44·6 ± 1·6
*Chronic Trophoedema	32	41	43·8 ± 3·9

* Numbers too small to give anything more than an approximation to the sex incidence.

This table is of interest and does indicate that abnormal thinness of the sclerotic presents an exceptional case with regard to its sex incidence, but the table should not be read too literally or accepted too readily as it stands, for each case requires to be considered in the light of other factors and the true significance of the values given is by no means clear. The sex incidence of a disease is influenced by a great variety of factors differing from one disease to another, and any particular value may have little or no relationship to the inherent relative liability of each sex to show the disease. For example, is the low value of the male sex incidence in Achondroplasia an expression of the fact that the excess, due to the disease, of the already larger size of the male head tends to lead to a selected infant mortality, so that a larger number of achondroplasic females survive birth? or may it further be explained by the fact that the female tends to present herself for treatment owing to obstetric difficulties arising from the large size of head in the foetus and there is thus a selection in the cases which come under observation? Again, are any of these values affected by such factors as concealment of defect on the part of the female in whom it may be regarded as a bar to marriage? Have we any evidence that defect in the female is a bar to marriage and that this factor does not operate for the male? One might readily suppose there would

[1] Includes Lobster Claw and Split Foot Deformity, Polydactylism and Brachydactylism.
[2] Includes only type in which both sexes are liable to affection.

be such a selection, for the defective male may presumably be expected to seek marriage in order to secure that he may have somebody to look after him when disabled, and moreover the woman's instincts may perhaps tend to draw her to the adult who needs physical aid, so that she may marry a disabled man in order to look after him, but when I seek for support of these expectations from an examination of pedigrees of hereditary disease I frequently do not find an excess of affected fathers but do on the contrary more generally find an excess of affected mothers even where there is a preponderance of males in the affected population. It is outside the scope of this paper to seek statistics to prove or disprove these points, but I am able to cite Retinitis Pigmentosa, Albinism, Congenital Night-Blindness (type in which both sexes are affected) and Blue Sclerotics, as examples of conditions in which pedigrees show more affected mothers than affected fathers; in Hereditary Multiple Exostoses, in Congenital Cataract and in Digital defects (including Lobster Claw and Split Foot, Brachydactylism and Polydactylism) there is an excess of affected fathers; the excess of affected fathers is marked in the case of Multiple Exostoses but this may be due to the marked excess of males in the affected population; the excess is less marked in the case of Congenital Cataract and may perhaps be neglected for the case of Digital defects. These examples so far as they go do not necessarily suggest concealment of defect on the part of the female but do perhaps suggest that when the defect is gross and disabling it does to some extent act as a bar to her marriage; indeed in most cases there can be no question of concealment in the affected individual and the material available is insufficient to determine whether there tends to be concealment of possibly latent disease, though it is hard to believe that knowledge concerning the danger of latent hereditary disease is sufficiently widespread to induce concealment in more than a small minority of cases.

(*f*) *Inheritance of Blue Sclerotics.* Blue Sclerotics give an example of a markedly hereditary disease to which, as we have seen, the female is especially liable; she appears also to be slightly more potent than the male as a transmitter of the defect. We know that the female is incomparably more potent as a transmitter of hereditary anomalies in a great variety of conditions, examples of which are Congenital Dichromatism, Congenital Night-Blindness (the sex-limited type of the defect), Haemophilia and Hereditary Optic Atrophy; following such extreme cases as these we find a number of conditions in which the female appears to be more potent as a transmitter but to a less marked degree, and in this group of defects Blue Sclerotics should be placed; only one condition to my knowledge has been demonstrated to exhibit increased potency as a transmitter in the male, this example is given by Hereditary Multiple Exostoses.

The following table gives figures relating to the inheritance of Blue Sclerotics.

	No. of Sibships	Percentage of Sibship affected	Percentage of Males affected	Percentage of Females affected	Percentage of Females in Sibship
Mother affected	91	$62{\cdot}7 \pm 1{\cdot}8$	55·7	68·8	54·1
Father affected	53	$53{\cdot}8 \pm 2{\cdot}2$	52·0	55·3	54·7
*Both parents normal	18	$24{\cdot}8 \pm 2{\cdot}8$	17·5	33·3	45·7

* Not comparable with the values given for the cases of one parent affected as the latter are contributed to by sibships all members of which are normal.

It seems reasonable to regard the proportion of affected amongst the offspring as a measure of the relative potency of each parent as a transmitter of a particular defect, though there is need to be cautious in passing from statistics of one disease to those of another, for there is evidently great variation in the liability of different hereditary anomalies to assume a latent form, and it is necessary to remember that these percentages take no account of defects which may be present in a latent form. There is, however, in the particular case with which we are dealing little evidence of latency as measured by the number of cases in which an apparently normal member of an affected sibship transmits the defect; it is true we have 18 affected sibships in which both parents were believed to be normal, but in few of these cases had one or both parents been examined, and doubtless the number would be decreased with more complete knowledge; of 371 cases in which there is some statement as to parentage no fewer than 344 or 92·7 per cent. are known to have had one or other parent affected. Thus I think we may say that the female has been demonstrated to transmit the defect due to blue sclerotics slightly more readily than does the male, though her excess of influence would appear to lie in a particular tendency to transmit to her daughters; she has apparently no more influence over her sons than has their father.

I would add a table giving some comparative values found to show the relative potency of the male and female as transmitters of hereditary defect, urging again the need for caution in attempting to interpret the facts given in it without much further knowledge of the particular cases; keeping this attitude of mind in view the table is of considerable interest from the number of unsolved problems it suggests.

	Parent affected	No. of Sibships	Percentage of affected offspring	Difference *a*—*b*
Retinitis Pigmentosa	(*a*) Mother	(67)	47·5 ± 1·9	+ 21·9
	(*b*) Father	(45)	25·6 ± 2·1	
Blue Sclerotics	(*a*) Mother	(91)	62·7 ± 1·8	+ 8·9
	(*b*) Father	(53)	53·8 ± 2·2	
Night-Blindness (Both sexes affected)	(*a*) Mother	(52)	43·4 ± 2·4	+ 4·7
	(*b*) Father	(44)	38·7 ± 2·5	
Congenital Cataract	(*a*) Mother	(71)	54·1 ± 1·9	+ 1·8
	(*b*) Father	(83)	52·3 ± 1·7	
Multiple Exostoses	(*a*) Mother	(41)	41·4 ± 2·7	− 11·0
	(*b*) Father	(92)	52·4 ± 1·7	

As in all hereditary diseases, blue sclerotics are found occasionally occurring in an individual in whose stock no other case has been known to occur; the only extensive pedigree I have seen to illustrate this state of affairs is the one we owe to Usher, published here as Fig. 659 on Plate XLVI; the subject of this history is a little girl aged 10 years (1923) who had uniformly slate-blue coloration of the sclerotics of a remarkable character; the family history of the mother of this affected child has been fully worked out, but little is known of the father's ancestry; he however was seen and was normal, moreover he did not know of any similar case of blue sclerotics having occurred in his family and apparently only one of his eight children, by two wives, was thus affected. I have little doubt that this is a case of an isolated occurrence of the defect with no

hereditary basis. I have considered the possibility of attempting a determination of the frequency with which the hereditary factor can be traced in this condition, but have not proceeded with the investigation, for isolated cases of blue sclerotics are not described in medical literature unless a history of extreme bone fragility or some other anomaly is present to add interest to the case, and it is therefore not possible to get any trustworthy estimate of the relative frequency of the occurrence of hereditary and non-hereditary cases.

(*g*) *On Defects found in Association with Blue Sclerotics.* The two defects most commonly noted in association with blue sclerotics, and indeed so frequently accompanying this anomaly as to constitute a syndrome, are (*a*) a liability to fracture which may amount to a true bone fragility, but in many cases expresses itself merely by too many individuals of a family having suffered from one or several fractures; and (*b*) deafness, due to otosclerosis, the symptoms showing most frequently after the age of 20 years. The pedigrees published here provide the following table, indicating the

Liability to Fracture

(*Males*)

	Present	Absent	?	Totals
Deaf	26	10	—	36
Not Deaf	16	12	—	28
?	70	40	19	129
Totals	112	62	19	193

(*Females*)

	Present	Absent	?	Totals
Deaf	45	17	—	62
Not Deaf	21	15	—	36
?	68	51	21	140
Totals	134	83	21	238

frequency of the occurrence of these defects in our affected population. It will be seen that there is a very large proportion of cases in which no knowledge was available concerning deafness; this arises partly from the late date at which the interest of the association was recognised, so that only in recently published pedigrees was enquiry concerning deafness made, and partly from the fact that in all cases where death occurred under 20 years, or which were under this age at the time of the enquiry, the condition had to be regarded as undetermined. A glance at the two sections of the table shows that on the small numbers available there is no significant difference in the proportions of the sexes with blue sclerotics who also suffer from the allied defects, and we may thus combine the two tables which, together with information of a few cases for which the sex is not given, provide the figures below. Thus it will be seen that of individuals with blue sclerotics 252 out of a total of 400 or $63{\cdot}0 \pm 1{\cdot}6$ per cent. suffered

Liability to Fracture

	Present	Absent	?	Totals
Deaf	71	27	—	98
Not Deaf	37	27	—	64
?	144	94	40	278
Totals	252	148	40	440

from one or more fractures; 98 out of a total of 162 or $60{\cdot}5 \pm 2{\cdot}6$ per cent. were deaf; 71 out of 162 or $43{\cdot}8 \pm 2{\cdot}6$ per cent. presented all the three defects; and only 27 out of 162 or $16{\cdot}7 \pm 2{\cdot}0$ per cent. have blue sclerotics unaccompanied by either of the associated defects; it will further be seen that the individual with blue sclerotics and a liability to fracture is more likely to suffer from deafness than the subject who has blue sclerotics with no liability to fracture, or the presence of one allied defect predisposes towards the other.

Examination of the pedigrees will readily convince the student that there is some close link underlying these three conditions, the predominating factor of which leads to blue sclerotics, for the other defects may be said to never occur singly or combined without the scleral anomaly, and an occasional fracture or complaint of deafness in a "normal" member of an affected sibship occurs so rarely as to require no modification of this statement, though we do need to remember that information about normal siblings in all pedigree work is apt to be very scanty and incomplete.

A careful search through the histories of reported cases has revealed evidence of no other definitely associated defect, though the incidence of syndactyly in seven affected members of Fig. 616, Plate XLIII, is interesting and suggestive. Twenty-four affected members of eight pedigrees are reported to have some defect in their teeth; seven affected members of three pedigrees are reported to have had congenital heart disease or some cardiac trouble; thirteen affected members of three pedigrees have suffered from vaso-motor defect, and other more or less isolated defects are noted, but none of these occurrences are sufficiently frequent to be of any real significance. Frequent accounts of scoliosis are merely another manifestation of the bone disease, as also is the frequent description of anomalies in the shape of the skull; we are told of cranial protuberances in various regions in forty-two cases; the occiput is abnormally prominent in twenty-eight cases, the frontal region in twenty-six cases and the temporal or parietal regions in fourteen cases, prominence of different regions frequently occurring in the same individual; these figures only constitute minimum values, for it is evident that cranial anomalies have only received very superficial consideration. The question of liability to sprains and dislocations is interesting, as it would appear in all probability to be another manifestation of the defect in fibrous tissue allied to the scleral anomaly, but information is here again too incomplete for the true significance of the association to be determined; we are told of sprains or dislocations, often said to be frequent, in forty cases, nine of which histories occurred in members who had never had a fracture, thirty-one were associated with a history of fracture, but it is evident that if true bone fragility is present a sprain would almost surely be accompanied by a fracture, and its presence would be masked by the more serious accident and would thus escape observation.

The question of some endocrinal insufficiency as a possible cause of the bone fragility has been considered by a number of authors and a few isolated cases have been described in which an obvious defect of this nature has been observed in association with blue sclerotics and bone fragility, but such cases are varied in character and the defects are manifested by such different clinical signs as adiposity, precocity,

infantilism, maleness in the female, cretinism in near relations, and so on, providing no definite or clear-cut grounds for regarding the association in these cases as in any degree causative; two such cases are described by Meissner[1], who gives references to other investigations on the subject.

(*h*) *Conclusions.* (1) Pedigrees of bone fragility cannot be assumed to contain material homogeneous with that obtained from pedigrees showing a liability to fracture associated with blue sclerotics. The sex incidence in the two series differs markedly; there is a selection of material which differs for the two series, and until the series of pedigrees of bone fragility alone is greatly expanded it is not possible to say to what extent the presence of associated defects which appear to determine the occurrence of bone fragility in the other series modifies the hereditary factors of the disease.

(2) The male sex incidence of bone fragility is high and closely comparable with that obtained by Dr Stocks for hereditary multiple exostoses (*Treasury of Human Inheritance*, Vol. III, Part I). The male sex incidence of a liability to fracture associated with blue sclerotics is relatively low and closely comparable with that given for blue sclerotics alone.

(3) In pedigrees showing associated defects of blue sclerotics, liability to fracture and otosclerosis, the presence of blue sclerotics determines the addition of one or both of the allied defects, which may be said never to occur in hereditary form in these pedigrees without the determining factor which leads to blue sclerotics, yet both conditions do undoubtedly occur independently in a hereditary form, without blue sclerotics, as shown by other pedigrees.

(4) Amongst the adult population of individuals affected with blue sclerotics approximately 60 per cent. of members have an associated liability to fracture, approximately 60 per cent. of members have an associated otosclerosis and 44 per cent. of members suffer from all three defects.

I have to express my great indebtedness to the Medical Research Council, whose grant has rendered the continuance of this work possible, also to Professor Karl Pearson for his help and for many suggestions.

ADDENDA

(i) A paper by J. A. Key ("Brittle Bones and Blue Sclera. Hereditary Hypoplasia of the Mesenchyme," *Archives of Surgery*, Vol. XIII, pp. 523—568. Chicago, 1926) was seen too late to be included in the Pedigree Plates. In it a case of blue sclerotics associated with a severe degree of bone fragility in a girl aged 12 years is very fully described, and some discussion of the hereditary character of the condition is given. All the patient's five siblings had blue sclerotics; two of her brothers and one sister had had multiple fractures. Her father was living and well; his family history was negative. Her mother had blue sclerotics, was deaf and had a history of two fractures. The maternal grandmother and great-grandmother of the patient were known to have

[1] *Bibl.* No. 114.

had blue sclerotics and to have been deaf; there was no knowledge as to whether they had shown any liability to fracture.

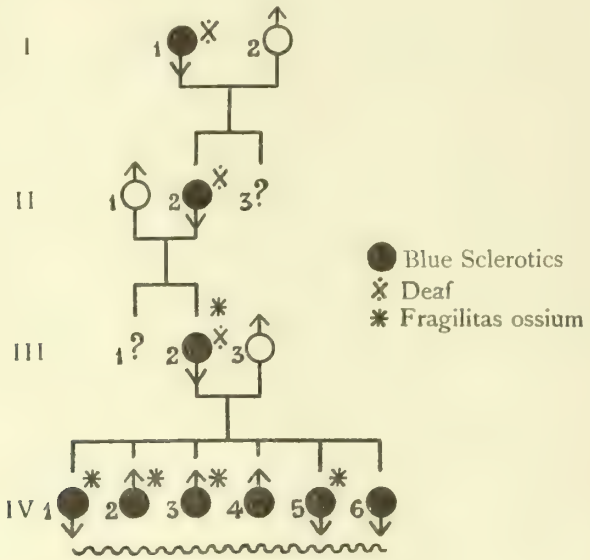

(ii) A reference to a further history also escaped my earlier observation. At a meeting of the Baltimore Medical Society, Dr Sinsky presented four cases of blue sclerotics belonging to a family in which seventeen affected members had occurred in four generations. No details of the cases are given but the history is well worth a more detailed investigation; *both* parents in the first generation are said to have had blue sclerotics, bone fragility and to have been deaf. (*American Journal of Ophthalmology*, Vol. IX, p. 844. Chicago, 1926.)

II. DESCRIPTIONS OF ILLUSTRATIVE PLATES.

Frontispiece. "Blue Sclerotic Peggy." From a coloured sketch of Dr Cockayne's case, represented by IV. 2 in Fig. 622, Plate XLIV. See Descriptions of Pedigree Plates, p. 306.

Plate A. Illustrations of Dr Donald Hunter's case of osteogenesis imperfecta in a boy aged 17, showing blue sclerotics and gross deformity of the whole skeleton. The skull shows typical anomalies. A radiological report states of this case that all the long bones showed shortening and bowing; the shadows of the bones are hardly more dense than those of the surrounding soft tissues; there is very great thinning of the cortex. The boy has never walked and cannot stand without support; his mother thinks he has had thirty or more fractures, the first of which occurred at the age of 3 weeks; the frequency of fractures has decreased since the age of 10 years. There was no history of fractures, blue sclerotics, deafness, nor of a peculiar shape of the head in the grandparents, parents or siblings of this boy who was the ninth born in a sibship of eleven. A full account of the case is given in Dr Hunter's original work. See Bibl. No. 150.

Plate B. Illustrations of a man aged 47 who had blue sclerotics and a history of repeated fractures, the first of which occurred at the age of 2 years; he was only 4 feet $5\frac{1}{2}$ inches in height and is said not to have grown since the age of 10 years; the upper part of his ears are seen to be turned outwards by the bi-temporal enlargement of the skull. Skiagrams of the skull show anomalies typical of the condition. This man had three brothers and four sisters, none of whom had blue sclerotics or exhibited any liability to fracture. See Bibl. No. 148.

Plate C. Fig. (i). Haward's case of fragilitas ossium in a boy aged 10 years; soon after birth he was noticed to have fractures of both humeri and of two ribs; since then he had had twenty-three fractures, mostly from very slight causes; the deformities of his lower limbs rendered him unable to stand or walk.

At the age of 1–2 years curvature of the spine occurred so readily that the child had to wear a spinal jacket, but he had been able to sit up without support since the age of 3–4 years. Improvement in the condition appears to have occurred after the age of 12. There is no mention of the colour of the sclerotics in this case. See Bibl. No. 38.

Plate C. Fig. (ii). Photograph of Dent's case represented by II. 1 in Fig. 696, Plate XLVII. See Descriptions of Pedigree Plates, p. 322.

Plate D. Illustrates the condition in II. 3 and II. 5 of Fig. 686, Plate XLVII. See Descriptions of Pedigree Plates, p. 320.

Plate E. This skeleton of a recently born child suffering from osteogenesis imperfecta was in Vrolik's museum and the original illustration of the case was published by him in Amsterdam in 1849. It provides a beautiful example of the anomalous ossification of the skull in this condition. Vrolik refers to the large number of fractures, recent and healed, of which evidences remain in the ribs and long bones; he comments on the absence of callus with tumour formation at the seat of the fracture. See Bibl. No. 16.

Plate F. This specimen was originally exhibited by C. Himly at a meeting of the Royal Society of Science at Göttingen, on November 25th, 1826. A description of the case may be seen in *Commentationes Societatis Regiae Scientiarum Gottingensis recentiores*, Vol. VI, pp. 61–72, Gottingae, 1828; a more detailed description of the skull is given by E. A. W. Himly in his *Beiträge zur Anatomie und Physiologie*, S. 21–30, Hannover, 1829. Now in the Museum of the Royal College of Surgeons. There has been some question as to diagnosis in this case, but in the absence of beading of the ribs and any enlargement of the epiphyses, and in the presence of multiple fractures of the long bones associated with bending, we have little hesitation in including it amongst our cases. Lawford Knaggs (Bibl. No. 142) observed cartilage cells amongst the bony trabeculae in a specimen of bone examined from the region of the epiphyses, but we venture the opinion that this fact is not incompatible with a diagnosis of osteogenesis imperfecta. The child was illegitimate and was born in a village of Hannover. According to a statement of his parents, his extremities were normal at birth and their extreme fragility and bowing became apparent at about the age of 6 months.

Plate G. Shows the skeleton of the case represented by II. 6 in Fig. 673, Plate XLVII. See Descriptions of Pedigree Plates, p. 321.

Plate H. Fig. (i). Radiograph of lower extremity in II. 1 of Fig. 696, Plate XLVII. See Descriptions of Pedigree Plates, p. 322.

Plate H. Fig. (ii). Photograph of an amputated limb from a case of osteogenesis imperfecta in a boy who had a history of multiple fractures since the age of 6 months and who had been repeatedly under treatment for fractures and attempts to straighten his bent legs; the shape of his femur on one occasion is described as resembling a note of interrogation. At the age of 11 years the boy was bed-ridden and was a pallid obese child; his left lower limb was absolutely flaccid and helpless; there was no muscular power in the thigh. X-rays taken in Wingfield Hospital, Headington, Oxford, showed extreme osteoporosis and thinning of all parts of the skeleton with bending of all the long bones and extreme deformity of both femora. In 1924 the left leg was amputated through the middle third of the femur at the site of the uppermost of three ununited fractures of the femur. The father and a sister of this boy had a history of multiple fractures and bending of the limbs; the father aged 54 was almost stone deaf, was very myopic and was suffering from chronic Bright's disease. The notes of the case do not state whether or no the bone fragility was associated with blue sclerotics.

Plate I. A case of osteogenesis imperfecta in a female child aged 4 hours showing multiple fractures of all the long bones of the skeleton. The midwife reported that during delivery sounds resembling pistol shots occurred which were apparently due to the occurrence of fractures. The child lived for a few weeks only.

Plate J. Multiple fractures and extreme bending in the lower extremity of a boy aged 14 years under the care of Mr Robert Milne at the London Hospital. This case of bone fragility was not associated with blue sclerotics but the skull of the boy showed the bi-temporal enlargement so frequently described in cases of blue sclerotics.

Plate K. Skiagram of the femur of Dr Hunter's case illustrated in Plate A, showing marked curvature. See account in the description of that plate.

Plate L. Skiagram of the right tibia and fibula of Dr Hunter's case shown in Plate A. See description of that plate.

Plate M. Skiagram of the ulna and radius of Dr Hunter's case shown in Plate A. See description of that plate.

Plate N. Skiagram of the skull in norma occipitalis in Mr Milne's patient (see Plate J for description), showing the bi-temporal expansion which may lead to a projection of the ears. Cf. Plate B, upper figures.

Plate O. Skiagram of the skull in Dr Hunter's case (see Plate A for description), showing the occipital protuberance. Cf. Plate E.

III. BIBLIOGRAPHY

1. Marcellus Donatus: *De Medica Historia mirabili Libri sex nunc primum in lucem editi.* Venetiis, 1588. [Lib. v, cap. 1, p. 271 gives a section entitled "Ossium mirae affectiones" in which will be found a description of bone fragility resulting from disease.]
2. Fontanus, N.: *Responsionum & Curationum medicinalium Liber unus.* Amstelodami, 1639. [An early case of bone fragility in old age is referred to on p. 10, "mulier aetate grandaeva eo debilitatis pervenerat, ut vix tactum sustineret, adeo, ut tactu levissimo ipsa membra frangerentur."]
3. Fabricius, W.: *Opera Observationum et Curationum Medica Chirurgicarum.* Francofurti, 1646. [Contains two observations on bone fragility—Centuria ii, Observatio lxviii, dated Nov. 24, 1609, entitled "De admiranda fragilitate ossium," and Centuria v, Observatio lxxxix, dated Feb. 28, 1621, entitled "De mira fragilitate ossium."]
4. Courtial, J. J.: *Nouvelles Observations Anatomiques sur les Os.* Paris, 1705. [pp. 64—72, Obs. ix, "Sur la Fragilité des Os." An attempt is made to explain the source of the defect in the structure of bone which leads to its fragility; it is said that all cases in which the condition has been noted have been in old people or in "gens pituiteux" or in individuals who have taken mercury.]
5. *Amand, P.: *Nouvelles Observations sur la Pratique des Accouchemens.* Paris, 1716.
6. Ekman, O. J.: *Descriptio et casus aliquot osteomalaciae.* Upsaliae, 1788. See Fig. 671.
7. Jacquinelle: Sur plusieurs Fractures survenues successivement au même sujet avec des remarques sur le rachitisme. *Journal de Médecine, Chirurgie, Pharmacie, &c.* T. lxxvii, pp. 267—271. Paris, 1788.
8. Jacquinelle: Récidives de Fractures. *Journal de Médecine, Chirurgie, Pharmacie, &c.* T. lxxxiv, pp. 216—217. Paris, 1790.
9. Strack, C.: Beobachtung von Fragilität der Knochen in der Jugend, ein Beitrag zu der Lehre von den Knochenkrankheiten. *Journal d. practischen Arzneykunde u. Wundarzneykunst.* Bd. xxv, Stück iii, S. 163—166. Berlin, 1807. See Fig. 689.
10. Lobstein, J. F.: *Traité d'Anatomie Pathologique.* Paris, 1833. [T. ii, pp. 204—212 includes a section entitled "De la fragilité des os, ou de l'ostéopsathyrose."]
11. Arnott: Thirty-one Fractures in one and the same Individual. *London Medical Gazette,* Vol. xii, p. 366. London, 1833. See Fig. 680.
12. Ammon, F. A. von: *Klinische Darstellungen der angeborenen Krankheiten und Bildungsfehler des menschlichen Auges.* Berlin, 1841. [p. 73, "Die angebornen Scleroticalkrankheiten sind selten;... wichtig ist eine eigenthümliche weisslich-bläuliche Beschaffenheit dieser Membran, der man nicht selten darin begegnet, wenn die ganze Ausbildung des Auges zurückgeblieben ist; die Sclerotica erscheint in solchen Fällen dünn und fast durchsichtig; ich habe dasselbe auch bei dem angebornen Hydrophthalmus (Tab. xv, Fig. 2) beobachtet."]
13. Gibson, W.: *Institutes and Practice of Surgery.* Philadelphia, 1841. [In Vol. i, pp. 251—252 a description is given of Dr Goddard's case of hereditary osteopsathyrosis.] See Fig. 698.
14. Pauli, F.: *Untersuchungen und Erfahrungen im Gebiete der Chirurgie.* Leipzig, 1844. [A section entitled "Fragilitas ossium haereditaria" will be found on pp. 35—36.] See Fig. 677.
15. Cornaz, C. A. E.: *Des Abnormités congéniales des Yeux et de leurs Annexes.* Lausanne, 1848. [pp. 67—68 give one of the relatively early published accounts of blue sclerotics.]
16. Vrolik, W.: *Tabulae ad illustrandam embryogenesin hominis et mammalium, tam naturalem quam abnormem.* Amstelodami, 1849. [Tab. xci shows an interesting example of a case of osteogenesis imperfecta (so named by this author) in which the vault of the skull is made up of a large number of small Wormian bones; all the bones of the skeleton show signs of fracture. See Plate E.]
17. Hiester, J. P.: Fragilitas Ossium in several members of the same family. *Boston Medical and Surgical Journal.* Vol. xli, pp. 393—394. Boston, 1850. See Fig. 674.
18. Ormerod, E. L.: An Account of a Case of Mollities Ossium. *British Medical Journal.* Vol. ii for 1859, pp. 736—740. London, 1859. See Fig. 673, also Plate G.
19. Gurlt, E.: *Handbuch der Lehre von den Knochenbrüchen.* Berlin, 1862—1865. [In Theil i, S. 147—154 is a section entitled "Die Knochenbrüchigkeit" in which published cases of osteopsathyrosis idiopathica are reviewed.]
20. Jones, J.: Fragilitas Ossium. *British Medical Journal.* Vol. i for 1870, p. 86. London, 1870. See Fig. 701.
21. Agnew, D. H.: *The Principles and Practice of Surgery.* Philadelphia, 1878. [Fragilitas ossium is described, Vol. i, pp. 1037—1038.] See Fig. 694.

22. *Cox, W. S.: An Afflicted Family. (Fractures from slight causes.) *Eclectic Medical Journal.* Vol. XXXIX, p. 458. Cincinnati, 1879. See Fig. 697.

23. Greenish, R. W.: A Case of Hereditary Tendency to Fragilitas Ossium. *British Medical Journal.* Vol. I for 1880, pp. 966—967. London, 1880. See Fig. 675.

24. Pritchard, O.: Hereditary Predisposition to Fractures. *Lancet.* Vol. II for 1883, p. 394. London, 1883. See Fig. 685.

25. Graham, D.: Brittle Bones. *Boston Medical and Surgical Journal.* Vol. CX, pp. 467—468. Boston, 1884. See Fig. 695.

26. Willard, de F.: Fragilitas Ossium. *Medical News.* Vol. LI, p. 734. Philadelphia, 1887. See Fig. 693.

27. Enderlen, E.: Zur Kenntniss der Osteopsathyrosis. *Archiv f. pathologische Anatomie u. Physiologie u. f. klinische Medicin.* Bd. CXXXI, S. 223—233. Berlin, 1893.

28. *Atherton, A. B.: Case of inherited Fragility of Bones: four Fractures of the Olecranon within seven months. *Dominion Medical Monthly.* Vol. II for 1894, pp. 1—3. Toronto, 1894. See Fig. 678.

29. Blanchard, W.: A Case of Fragilitas Ossium. *Transactions, American Orthopedic Association.* Vol. VI, pp. 83—86. Philadelphia, 1894. [A severe case is described in a female who was estimated to have had probably at least 106 fractures; the first occurred at the age of 2 months, their frequency had diminished since the age of 17 years.]

30. Moreau, E.: *Contribution à l'Étude de la Fragilité constitutionnelle des Os (Ostéopsathyrosis de Lobstein).* Thèse. Paris, 1894. See Fig. 688.

31. Schultze, F.: Beitrag zur idiopathischen Osteopsathyrose. *Archiv f. klinische Chirurgie.* Bd. XLVII, S. 327—339. Berlin, 1894.

32. Spurway, J.: Hereditary tendency to Fracture. *British Medical Journal.* Vol. II for 1896, p. 844. London, 1896. See Fig. 639.

33. Dent, C. T.: Case of Fragilitas Ossium. *Transactions, Medical Society of London.* Vol. XX, p. 339. London, 1897. See Fig. 696, also Plates C and H.

34. Griffith, J. P. C.: Idiopathic Osteopsathyrosis (Fragilitas Ossium) in Infancy and Childhood. *American Journal of Medical Sciences.* Vol. CXIII, pp. 426—445. Philadelphia, 1897. See Figs. 678, 697.

35. Hunter, J.: Fragilitas Ossium—Notes on the History of a Family in which it appears to be Hereditary. *British Medical Journal.* Vol. I for 1898, p. 488. London, 1898. See Fig. 679.

36. Eddowes, A.: Dark Sclerotics and Fragilitas Ossium. *British Medical Journal.* Vol. II for 1900, p. 222. London, 1900. See Fig. 652.

37. Schmidt, O.: *Ein Beitrag zur Kenntnis der sogenannten Osteopsathyrosis idiopathica.* Dissertation. Leipzig, 1901. See Figs. 672, 681, 686, also Plate D.

38. Haward, W.: A Case of Fragilitas Ossium. *Transactions, Clinical Society of London.* Vol. XXXV, pp. 38—42. London, 1902. See Plate C.

39. Rebbeling, A.: *Ueber idiopathische Osteopsathyrosis.* Dissertation. Leipzig, 1902. See Fig. 676.

40. Buchanan, L.: Case of Congenital Maldevelopment of the Cornea and Sclerotic. *Transactions, Ophthalmological Society of U.K.* Vol. XXIII, pp. 267—269. London, 1903.

41. Heaton, G.: Two Cases of Fragilitas Ossium. *Midland Medical Journal.* Vol. II, pp. 36—37. Birmingham, 1903. See Fig. 683.

42. Hodgkinson, C. F.: Dark Sclerotics and Fragilitas Ossium. *Transactions, Intercolonial Medical Congress of Australasia for 1903,* pp. 218—219. Tasmania, 1903. See Fig. 648.

43. Broca, A. and Herbinet: De l'Ostéopsathyrosis ou Fragilité osseuse dite essentielle. *Revue de Chirurgie.* T. XXV, pp. 770—786. Paris, 1905. See Fig. 664.

44. Doering, H.: Beitrag zur Lehre von der idiopathischen Osteopsathyrosis. *Deutsche Zeitschrift f. Chirurgie.* Bd. LXXVII, S. 284—301. Leipzig, 1905.

45. Porak, C. and Durante, G.: Les Micromélies congénitales; Achondroplasie vraie et Dystrophie périostale. *Nouvelle Iconographie de la Salpêtrière.* T. XVIII, pp. 481—538. Paris, 1905.

46. Looser, E.: Zur Kenntnis der Osteogenesis imperfecta congenita und tarda (sogenannte idiopathische Osteopsathyrosis). *Mitteilungen aus den Grenzgebieten der Medizin u. Chirurgie.* Bd. XV, S. 161—207. Jena, 1906.

47. Lovett, R. W. and Nichols, E. H.: Osteogenesis imperfecta, with the Report of a Case, with Autopsy and Histological Examination. *British Medical Journal.* Vol. II for 1906, pp. 915—923. London, 1906.

48. Hay, P. J.: A Congenital Anomaly of the Sclera: "Pseudo-Coloboma." *Ophthalmoscope.* Vol. v, pp. 300—303. London, 1907.

49. Poirrier, H. A.: *Contribution à l'Étude de l'Ostéopsathyrose idiopathique* (maladie de Lobstein). Thèse. Paris, 1907.

50. Simmons, C. C.: Osteogenesis imperfecta and idiopathic Fragilitas Ossium. *Annals of Surgery.* Vol. xlvi, pp. 179—189. New York, 1907. [Describes two cases with negative family history; post-mortem appearances of one case described.]

51. Axhausen: Osteogenesis imperfecta oder frühe Osteomalacie als Grundlage der idiopathischen Osteopsathyrosis? *Deutsche Zeitschrift f. Chirurgie.* Bd. xcii, S. 42—69. Leipzig, 1908. See Fig. 691.

52. Lipschütz, A.: Ueber idiopathische Osteopsatyrose. *Berliner klinische Wochenschrift.* Bd. xlv, S. 866—872. Berlin, 1908.

53. Peters, A.: Blaufärbung des Augapfels durch Verdünnung der Sklera als angeborene und erbliche Anomalie. *Klinische Monatsblätter f. Augenheilkunde.* Bd. xlvi, S. 130—133. Stuttgart, 1908. See Fig. 620.

54. Hochsinger, C.: Über Osteopsathyrosis foetalis. *Wiener medizinische Wochenschrift.* Bd. lix, S. 745—754. Wien, 1909.

55. Matsuoka, M.: Ein Beitrag zur Lehre von der idiopathischen Osteopsathyrosis. *Deutsche Zeitschrift f. Chirurgie.* Bd. xcviii, S. 407—414. Leipzig, 1909. See Fig. 690.

56. Harman, N. Bishop: A Pedigree of five generations of "Blue Sclerotics." *Ophthalmoscope.* Vol. viii, pp. 559—561. London, 1910. See Fig. 602.

57. Stephenson, S.: A peculiar appearance of the eyes affecting twenty-one members belonging to four generations of a family. *Ophthalmoscope.* Vol. viii, pp. 330—332. London, 1910. See Fig. 602.

58. Sumita, M.: Beiträge zur Lehre von der Chondrodystrophia foetalis (Kaufmann) und Osteogenesis imperfecta (Vrolik), mit besonderer Berücksichtigung der anatomischen und klinischen Differentialdiagnose. *Deutsche Zeitschrift f. Chirurgie.* Bd. cvii, S. 1—110. Leipzig, 1910.

59. Burrows, H.: Blue Sclerotics and Brittle Bones. *British Medical Journal.* Vol. ii for 1911, p. 16. London, 1911. See Fig. 618.

60. de Cortes, A.: Klinischer und histologischer Beitrag zur Lobsteinschen Osteopsathyrosis. *Zeitschrift f. Orthopädische Chirurgie.* Bd. xxix, S. 402—432. Stuttgart, 1911. See Fig. 692.

61. Hartmann, J.: Zur Frage der Osteopsathyrosis idiopathica. *Deutsche Zeitschrift f. Chirurgie.* Bd. cxi, S. 383—412. Leipzig, 1911. See Fig. 699.

62. Rolleston, J. D.: Inherited Syphilis and Blue Sclerotics. *Ophthalmoscope.* Vol. ix, pp. 321—324. London, 1911. See Fig. 643.

63. Adair-Dighton, C. A.: Four Generations of Blue Sclerotics. *Ophthalmoscope.* Vol. x, pp. 188—189. London, 1912. See Fig. 619.

64. Coues, W. P.: A Case of Fragilitas Ossium. *Pediatrics.* Vol. xxiv, pp. 85—86. New York, 1912.

65. Lewy, J.: Osteopsathyrosis idiopathica. *Deutsche medizinische Wochenschrift.* Bd. xxxviii, S. 1875—1878. Berlin, 1912. See Fig. 684.

66. Adam: Zwei Patienten mit Melanochromie der Sklera und abnormer Knochenbrüchigkeit. *Centralblatt f. praktische Augenheilkunde.* Bd. xxxvii, S. 345. Leipzig, 1913. See Fig. 650.

67. Antonelli: La cornée ovalaire et la sclérotique bleue des hérédo-syphilitiques. *Archives d'Ophthalmologie.* T. xxxiii, pp. 491—503. Paris, 1913.

68. Bamberg, K. and Huldschinsky, K.: Über angeborene Knochenbrüchigkeit. *Jahrbuch f. Kinderheilkunde.* Bd. xxviii, S. 214—266. Berlin, 1913.

69. Behr, C.: Beitrag zur Aetiologie des Keratokonus. *Klinische Monatsblätter f. Augenheilkunde.* Bd. li, S. 281—286. Stuttgart, 1913.

70. Coulon, F. A.: Five Generations of Blue Sclerotics and associated Osteoporosis. *Boston Medical and Surgical Journal.* Vol. clxix, pp. 16—19. Boston, 1913. See Fig. 604.

71. Peters, A.: Blaue Sklera und Knochenbrüchigkeit. *Klinische Monatsblätter f. Augenheilkunde.* Bd. li, S. 594—596. Stuttgart, 1913. See Fig. 620.

72. Zesas, D. G.: Beitrag zur Pathologie der idiopathischen Osteopsathyrose. *Deutsche Zeitschrift f. Chirurgie.* Bd. cxxiii, S. 380—404. Leipzig, 1913.

73. Zurhelle, E.: Osteogenesis imperfecta bei Mutter und Kind. *Zeitschrift f. Geburtshülfe u. Gynäkologie.* Bd. lxxiv, Heft 2 u. 3, S. 942—950. Stuttgart, 1913.

74. Cockayne, E. A.: Hereditary Blue Sclerotics and Brittle Bones. *Ophthalmoscope.* Vol. xii, pp. 271—272. London, 1914. See Fig. 622.

75. Ostheimer, M.: Fragilitas Ossium. *Journal of American Medical Association.* Vol. lxiii, pp. 1996—1999. Chicago, 1914. [Gives the views held by many writers concerning the pathology of the disease and describes a case, with negative family history, of a female aged 3 years who had already had nine fractures, the first occurring at the age of $1\frac{1}{2}$ years and of whom her mother says "she breaks her leg almost every time she tries to stand up"; the condition was associated with deep blue sclerotics.]

76. Tillaye: Ostéopsathyrosis héréditaire familiale. *Revue d'Orthopédie.* T. xv, pp. 113—117. Paris, 1914. See Fig. 682.

77. Wrede, L.: Osteopsathyrosis idiopathica. *Münchener medizinische Wochenschrift.* Bd. lxi, S. 847. München, 1914.

78. Herrman, C.: Blue Sclerotics associated with Brittle Bones. *American Journal of Diseases of Children.* Vol. ix, pp. 205—212. Chicago, 1915.

79. Hofmann, W.: Ueber Blaufärbung der Sklera und abnorme Knochenbrüchigkeit. *Archiv f. klinische Chirurgie.* Bd. cvii, S. 279—285. Berlin, 1915. See Figs. 653, 658.

80. *Salvetti, C.: Osteopsatirosi e Sclerotica blu. *Clinica Chirurgia.* T. xxiii, pp. 298—301. Milano, 1915. [Abstract in *Zentralblatt f. Chirurgie.* Bd. xlii, p. 414. Leipzig, 1915.] See Fig. 657.

81. Stephenson, S.: Blue Sclerotics. *Transactions, Ophthalmological Society of U. K.* Vol. xxxv, pp. 274—276. London, 1915. See Fig. 602.

82. Kienböck, R.: Über infantile Osteopsathyrose. *Fortschritte auf dem Gebiete der Röntgenstrahlen.* Bd. xxiii, S. 122—168. Hamburg, 1915—1916. [Contains a valuable contribution to the subject with abstracts of many published cases in addition to several new cases and a bibliography; two plates of X-rays are included.]

82a. Cameron, H. C.: Osteogenesis Imperfecta. *Proceedings, Royal Society of Medicine.* Vol. ix. *Sect. Disease in Children,* pp. 43—47, 48—50. London, 1916.

83. Bronson, E.: On Fragilitas Ossium and its Association with Blue Sclerotics and Otosclerosis. *Edinburgh Medical Journal.* Vol. xviii, pp. 240—281. Edinburgh, 1917. See Figs. 613, 624.

84. Goldbloom, A.: Fragilitas Ossium, with Report of a Case. *Canadian Medical Association Journal.* Vol. vii (new series), pp. 636—640. Toronto, 1917.

85. Van der Hoeve, J. and Kleijn, A. de: Blauwe Sclera, Broosheid van het Beenstelsel en Gehoorstoornissen. *Nederlandsch Tijdschrift voor Geneeskunde.* Deel liii, pp. 1003—1010. Haarlem, 1917. See Fig. 616.

86. Mixsell, H. R.: Osteogenesis Imperfecta (Osteopsathyrosis, Fragilitas Ossium), with Report of two Cases. *Archives of Pediatrics.* Vol. xxxiv, pp. 756—764. New York, 1917.

87. Rothschild, A.: *Ueber die Vereinigung von blauer Sklera und Knochenbrüchigkeit nebst kasuistischen Mitteilungen.* Dissertation. München, 1917.

88. Whipman, T. R.: Case of Fragilitas Ossium. *Proceedings, Royal Society of Medicine.* Vol. x. *Sect. Disease in Children,* pp. 68—71. London, 1917. [The case is associated with blue sclerotics and has protuberances in the temporal regions of the skull; family history negative.]

89. Coulon, F. A.: Blue Sclerotics; a note upon associated Otosclerosis. *American Journal of Ophthalmology.* Ser. 3, Vol. i, pp. 726—727. Chicago, 1918. See Fig. 604.

90. Van der Hoeve, J. and Kleijn, A. de: Blaue Sclera, Knochenbrüchigkeit und Schwerhörigkeit. *Archiv f. Ophthalmologie.* Bd. xcv, S. 81—93. Berlin, 1918. See Figs. 610, 616.

91. Marconi, A.: Contributo allo Studio della Fragilita ossea associata a Sclerotica azzurra. *Gazzetta degli Ospedali e delle Cliniche.* Tom. xxxix, pp. 367—368. Milano, 1918.

92. Terry, W. I.: Hereditary Osteopsathyrosis. *Transactions, American Surgical Association.* Vol. xxxvi, pp. 317—326. Philadelphia, 1918. See Fig. 627.

93. Voorhoeve, N.: Blue Sclerotics in connexion with other Hereditary or Congenital Abnormalities. *Lancet.* Vol. ii for 1918, pp. 740—741. London, 1918. See Fig. 612.

94. Bolten, G. C.: Beitrag zur Kenntnis der Pathogenese der Fragilitas Ossium Congenita (Osteopsathyrosis infantilis). *Deutsche Zeitschrift f. Nervenheilkunde.* Bd. lxiii, S. 343—359. Leipzig, 1919. See Figs. 630, 660.

95. Bronson, E.: Osteogenesis Imperfecta. *Proceedings, Royal Society of Medicine.* Vol. xii. *Sect. Disease in Children,* pp. 15—17. London, 1919. [Two unrelated cases are described, neither of which is associated with blue sclerotics; Case i has a negative family history.] See Fig. 700.

96. Fraser, J. S.: Otosclerosis with Fragilitas Ossium and Blue Sclerotics, with a Clinical Report of Three Cases. *Proceedings, Royal Society of Medicine.* Vol. xii. *Sect. Otology,* pp. 126—133. London, 1919. [Three cases of otosclerosis from Bronson's pedigree, Fig. 624, are described.]

97. Hass, J.: Zur Kenntnis der Osteopsathyrosis idiopathica. *Medizinische Klinik.* Bd. xv, S. 1112—1115. Wien, 1919. See Fig. 608.

98. Wise, W. D.: Fragilitas Ossium with Blue Sclerotics. *Journal of American Medical Association.* Vol. lxxiii, p. 1696. Chicago, 1919. See Fig. 665.

99. Andrade Maia, J. de: *Contribution à l'Étude de l'Ostéopsathyrose.* Thèse. Paris, 1920.

100. Apert, E. and Cambessédès: Fragilité osseuse familiale avec Sclérotiques bleues. *Bulletins de la Société de Pédiatrie de Paris.* T. xviii, pp. 102—105. Paris, 1920. See Fig. 631.

101. Bauer, K. H.: Über Osteogenesis imperfecta, zugleich ein Beitrag zur Frage einer allgemeinen Erkrankung sämtlicher Stützgewebe. *Deutsche Zeitschrift f. Chirurgie.* Bd. cliv, S. 166—213. Leipzig, 1920.

102. Bauer, K. H.: Über Identität und Wesen der sogenannten Osteopsathyrosis idiopathica und Osteogenesis imperfecta. *Deutsche Zeitschrift f. Chirurgie.* Bd. clx, S. 289—351. Leipzig, 1920. [Contains a valuable discussion of the pathology of the disease with many useful references; the hereditary factor is emphasised and a section is included dealing with the association of the condition with blue sclerotics.]

103. Blegvad, O. and Haxthausen, H.: Blue Sclerotics and brittle Bones, with macular Atrophy of the Skin and Zonular Cataract. *British Medical Journal.* Vol. ii for 1921, pp. 1071—1072. London, 1921. See Fig. 625.

104. Burns, C. W.: Fragilitas Ossium. *Canadian Medical Association Journal.* Vol. xi (new series), pp. 522—523. Toronto, 1921. See Fig. 702.

105. Franke, G.: Ueber Osteogenesis imperfecta. *Zeitschrift f. orthopädische Chirurgie.* Bd. xli, S. 158—179. Stuttgart, 1921.

106. Freytag, G. T.: Ueber blaue Sklera und Knochenbrüchigkeit. *Klinische Monatsblätter f. Augenheilkunde.* Bd. lxvi, S. 507—512. Stuttgart, 1921. See Fig. 637.

107. Rocher, H. L. and Lasserre, C.: Sur un Cas d'Ostéopsathyrose avec Sclérotiques bleutées. *Gazette hebdomadaire des Sciences médicales de Bordeaux.* T. xlii, p. 238. Bordeaux, 1921. See Fig. 655.

108. Vander Veer, E. A. and Dickinson, A. M.: Fragilitas Ossium. *Annals of Surgery.* Vol. lxxiv, pp. 629—632. London and Philadelphia, 1921. See Fig. 661.

109. Alexander, J. B.: Fragilitas Ossium associated with Blue Sclerotics in four Generations. *British Medical Journal.* Vol. i. for 1922, p. 677. London, 1922. See Fig. 614.

110. Glover, D. M.: Osteopsathyrosis: Report of a Case with Roentgenograms of eleven different Fractures in the same Patient. *Archives of Surgery.* Vol. v, pp. 464—484. Chicago, 1922.

111. Gutzeit, R.: Ueber blaue Sklera und Knochenbrüchigkeit. *Klinische Monatsblätter f. Augenheilkunde.* Bd. lxviii, S. 771—774. Stuttgart, 1922.

112. Hansson, H. E.: Om Osteopsathyrosis idiopathica (Osteogenesis imperfecta). *Hygiea.* Bd. lxxxiv, S. 502—508. Stockholm, 1922. See Fig. 615.

113. Mallardi, M.: Un Caso di Osteopsatirosi. *La Pediatria.* T. xxx, pp. 75—80. Napoli, 1922. [The case is associated with blue sclerotics.]

114. Meissner, R.: Über Beziehungen von Osteopsathyrosis idiopathica zum endokrinen System. *Medizinische Klinik.* Bd. xviii, S. 1381—1384. Wien, 1922.

115. Ruttin, E.: Osteopsathyrose und Otosklerose. *Zeitschrift f. Hals-, Nasen- und Ohrenheilkunde.* Bd. iii, S. 263—279. München u. Berlin, 1922. See Figs. 623, 626, 629.

116. Scheel, M.: Demonstration af Moder og Datter med blaa Sclerae og Tendens til Knoglebrud. *Hospitalstidende.* Bd. lxv, S. 1—3. København, 1922. See Fig. 669.

117. Stewart, H.: Fragilitas Ossium associated with Blue Sclerotics. *British Medical Journal.* Vol. ii for 1922, p. 498. London, 1922. See Fig. 609.

118. Aubineau, E.: Le Syndrome des Sclérotiques bleues. *Annales d'Oculistique.* T. clx, pp. 337—342. Paris, 1923. See Fig. 633.

119. Bigler, M.: Über das gleichzeitige Vorkommen von Osteopsathyrose und blauer Verfarbung der Skleren bei Otosklerose. *Zeitschrift f. Hals-, Nasen- und Ohrenheilkunde.* Bd. v, S. 233—239. München u. Berlin, 1923.

120. Blatt, N.: Ein Fall von blauer Sclera, Knochenbruchigkeit und primarem epibulbarem Carcinom von basocellulärem Charakter. *Archiv f. Ophthalmologie.* Bd. cxi, S. 54—59. Berlin, 1923.

121. Bolten, H.: Blauwe Sclerae. *Nederlandsch Tijdschrift voor Geneeskunde.* Deel II for 1923, pp. 1747—1751. Amsterdam, 1923. See Figs. 640, 667.

122. Buchanan, L.: Blue Sclerotics. *Transactions, Ophthalmological Society of U. K.* Vol. XLIII, pp. 352—354. London, 1923. See Fig. 644.

123. Morax, V.: Syndrome des Sclérotiques bleues. *Annales d'Oculistique.* T. CLX, pp. 484—485. Paris, 1923. See Fig. 645.

124. Singer, S.: Ein Beitrag zur Frage der Kombination abnormer Knochenbrüchigkeit und blauer Skleren. *Zeitschrift f. klinische Medizin.* Bd. 97, S. 43—57. Berlin, 1923. See Fig. 656.

125. Straat, H. L.: Blauwe Sclerae, Fragilitas Ossium en Otosklerose. *Nederlandsch Tijdschrift voor Geneeskunde.* Deel LIX, pp. 151—153. Amsterdam, 1923. See Fig. 628.

126. Blencke, A.: Ueber das gemeinsame Vorkommen von Knochenbrüchigkeit mit blauen Skleren und Schwerhörigkeit. *Zeitschrift f. orthopädische Chirurgie.* Bd. XLV, S. 406—415. Stuttgart, 1924. See Fig. 651.

127. *Elewaut, H. M.: Le Syndrome des Sclérotiques bleues. *Bulletin de la Société Belge d'Ophtalmologie,* 1924, pp. 23—25. Bruxelles, 1924. [Notes of this case taken from *Zentralblatt f. d. ges. Ophthalmologie.* Bd. XV, S. 489. Berlin, 1926.] See Fig. 635.

128. Franke, E.: Ueber blaue Sklera und ihren Zusammenhang mit Knochenbrüchigkeit und Otosklerose. *Klinische Monatsblätter f. Augenheilkunde.* Bd. LXXIII, S. 119—126. Stuttgart, 1924. See Figs. 634, 636.

129. Stobie, W.: The Association of Blue Sclerotics with Brittle Bones and Progressive Deafness. *Quarterly Journal of Medicine.* Vol. XVII, pp. 274—287. Oxford, 1924. See Fig. 611.

130. Stulz, E. and Fontaine, R.: Un Cas d'Ostéopsathyrosis idiopathique. *Bulletins et Mémoires de la Société Anatomique de Paris.* T. CXIV, pp. 123—129. Paris, 1924.

131. Takahashi, T.: Beitrag zur Kenntnis der blauen Sclera. *Archiv f. Ophthalmologie.* Bd. CXV, Heft 1, S. 206—214. Berlin, 1924. See Fig. 646.

132. Vallery-Radot, P and Aris, P.: Ostéopsathyrosis héréditaire. *Bulletins de la Société de Pédiatrie de Paris.* T. XXII, pp. 291—293. Paris, 1924. See Fig. 664.

133. Whitchurch Howell, B. and Kinnear, W. L.: Case of Fragilitas Ossium with Blue Sclerotics. *Proceedings, Royal Society of Medicine.* Vol. XVII. *Sect. Disease in Children,* pp. 21—22. London, 1924. See Fig. 654.

134. Wirth, M.: Blaue Skleren und Knochenbrüchigkeit. *Klinische Monatsblätter f. Augenheilkunde.* Bd. LXXIII, S. 251. Stuttgart, 1924. See Fig. 668.

135. Berneaud, G.: Blaue Skleren und Knochenbrüchigkeit. *Klinische Monatsblätter f. Augenheilkunde.* Bd. LXXIV, S. 505—508. Stuttgart, 1925. See Figs. 617, 621, 642.

136. Colden, C.: Blaue Skleren mit eigenartigem ophthalmoskopischem Befund. *Klinische Monatsblätter f. Augenheilkunde.* Bd. LXXIV, S. 360—364. Stuttgart, 1925. See Fig. 647.

137. Dreifuss, W.: Demonstration eines Falles von Osteogenesis imperfecta tarda. *Wiener medizinische Wochenschrift.* Bd. LXXV, S. 2871—2872. Wien, 1925. [No heredity and no blue sclerotics.]

138. Rau, H.: Ein Fall von Osteopsathyrosis idiopathica. *Wiener medizinische Wochenschrift.* Bd. LXXV, S. 1436. Wien, 1925. [The condition was associated with blue sclerotics.]

139. Wiechmann, E. and Paal, H.: Zur Klinik der sogenannten blauen Skleren. *Münchener medizinische Wochenschrift.* Bd. LXXII, S. 213—215. München, 1925. See Fig. 632.

140. Cockayne, E. A.: Case of Brittle Bones and Blue Sclerotics. *Proceedings, Royal Society of Medicine.* Vol. XIX. *Sect. Disease in Children,* p. 45. London, 1926. See Fig. 606.

141. *Kaznelsohn, A.: Ueber das Syndrom der blauen Sklera. *Russ. Ophth. J.* 1926, S. 890. [An abstract of this paper is given in *Klinische Monatsblätter f. Augenheilkunde.* Bd. LXXVIII, S. 117. Stuttgart, 1927.] See Fig. 649.

142. Knaggs, R. Lawford: *The Inflammatory and Toxic Diseases of Bone.* Bristol, 1926. [An account of Osteogenesis imperfecta is given, pp. 375—405.]

143. Kropp: Blaue Sklera und Knochenbrüchigkeit. *Zeitschrift f. Augenheilkunde.* Bd. LIX, S. 323—324. Berlin, 1926. See Fig. 666.

144. Schwarz, F.: Beitrag zur idiopathischen Osteopsathyrose. *Medizinische Klinik.* Bd. XXI, S. 1846—1848. Berlin, 1926. See Figs. 605, 638, 687.

145. Strangeways, T. S. P. and Fell, H. B.: Experimental Studies on the Differentiation of Embryonic Tissues growing *in vivo* and *in vitro.* II. The Development of the isolated early Embryonic Eye of the Fowl when cultivated *in vitro.* *Proc. R. S.* Ser. B., Vol. C, pp. 273—283. London, 1926.

146. Cleminson, F. J.: Otosclerosis associated with Blue Sclerotics and Osteogenesis imperfecta. *Proceedings, Royal Society of Medicine.* Vol. XX. *Sect. Otology,* pp. 471—474. London, 1927.

147. Duggan, J. N. and Nanavati, B. P.: A Family with Blue Sclerotics. *British Journal of Ophthalmology.* Vol. xi, pp. 445—447. London, 1927. See Fig. 662.

148. Shugrue, J. J., Rockwood, R. and Anderson, E. W.: Fragilitas Ossium and Deafness. *Archives of Internal Medicine.* Vol. xxxix, pp. 98—108. Chicago, 1927. See Figs. 641, 670.

149. Terrien, F., Sainton, P. and Veil, P.: Deux Cas de Syndrome de van der Hoeve. (Œil bleu—Fragilité osseuse—Surdité.) *Archives d'Ophtalmologie.* T. xliv, pp. 293—301. Paris, 1927. See Fig. 663.

150. Hunter, D.: A case of Osteogenesis imperfecta. *Lancet.* Vol. i for 1927, pp. 9—12. London, 1927.

DESCRIPTIONS OF PEDIGREE PLATES

Plate XLII. Fig. 602. *Stephenson-Harman-Riddell-Bell Case.* Forty-one cases of blue sclerotics, some of which are associated with bone fragility and deafness, in five generations. This extremely interesting history was first published by Stephenson in 1910 when he examined a number of the descendants of II. 3; later in the same year Bishop Harman, who had come in touch with III. 12, worked out the history of her branch of the family and published a considerably extended pedigree. In 1915 Stephenson described and presented three cases, III. 8, IV. 15 and IV. 16, before the Ophthalmological Society and the account there given of the family was not altogether consistent with the former published accounts; a letter to him brought no satisfaction as he had lost touch with the family and was not able to throw any light upon the discrepancies. A short time ago III. 12 again presented herself at Moorfields and Riddell obtained from her a considerable amount of information regarding her family: he was too busy to pursue the history further, but very kindly handed over to the present author all his notes of the cases and addresses of a number of individuals, who was thus enabled to get in touch with other members of the family and to complete the pedigree in its present form. There are a good many serious differences between the pedigree here presented and that formerly published by Stephenson, particularly respecting the children of III. 6, III. 8 and III. 10 but, as already stated, there were reasons for doubting the accuracy of the earlier pedigree. I have myself seen III. 6, IV. 6 and IV. 24, who have given detailed accounts of each member of their families and moreover the account given by them of the children of III. 8 agrees entirely with that published by Stephenson himself in 1915. Further, valuable additions which Riddell and I have been able to add to the pedigree are almost the whole of Generation V and the investigation of the associated defects which were not referred to in the earlier account. I. 1 died aged 60 years; her grandchild, III. 12, had seen her and remembered that she had blue sclerotics. The four children of I. 1 all had blue sclerotics; II. 2, the only son, died aged 90; he had three children of whom III. 1 was drowned and no knowledge could be obtained of his sclerotics. III. 2, still living and aged over 70, has blue sclerotics and has at least two children of whom no information is available; III. 3 is known to have had blue sclerotics. II. 3 had blue sclerotics; she died aged 80 having had a son and three daughters all of whom had blue sclerotics. Thus, III. 4 had blue sclerotics but was not deaf and had no bone fragility; he was an acrobat on the stage and died as a result of twisting his internal organs whilst "looping" in the air; perhaps his calling in life suggests that he had a hyperextensibility of ligaments which is fairly common in association with blue sclerotics. III. 6, now aged 64 (1927), was seen by Stephenson in 1910 and was also seen by the present writer; her sclerotics are of a deep leaden blue colour and she has a complete arcus senilis surrounding each cornea; she is short and slight, very active still, not at all deaf and has never had any fractures; she devotes herself to nursing in the intervals of looking after her family; she has been twice married. By her first marriage, III. 6 had five children of whom IV. 1, a son, died aged 4 months and his mother had no recollection of the colour of his sclerotics. IV. 2 is said by her mother to have blue sclerotics; she had one fracture of her arm when quite small resulting from slight injury, and is very deaf; she began to notice deafness soon after her marriage at the age of 21 years. IV. 4 has normal eyes, is not deaf and has had no fractures; his five children were also free from any abnormality in these respects. IV. 6, seen by the present author at the age of 40 (1927), has deep blue sclerotics, no arcus senilis or embryontoxon; she became deaf at about the age of 30 but is less deaf than her sister IV. 2; she had some injury to her ankle at birth which has always been weak and sprains very readily. IV. 8 died aged $2\frac{1}{2}$ years following measles: he had white sclerotics and had had no fractures up to the time of his death. By her second husband III. 6 had three sons, of whom IV. 9 was seen by Stephenson at the age of $6\frac{1}{2}$ years when his sclerae presented a curious uniform bluish tinge perhaps best described as "leaden"; the appearance extended to the cornea and beyond the equator of the eyeball as far as could be seen; there was no accentuation in the ciliary zone; he was a lad of dark complexion and a small embryontoxon was present towards the upper margin of each cornea; fundi were well pigmented and the optic discs of oval shape with a congenital crescent at the lower margin of each papilla; he had some trouble at that time with his vision, due to compound hypermetropic astigmatism which was not excessive however in grade; his mother reports that IV. 9 fractured his tibia at about the age of 5 years from a slight cause and that he is rather deaf, but his cousin, IV. 24, says that his limbs are very brittle and deformed; it may be that he has had fractures without realising their

occurrence; he is married but has no children. IV. 10 and 11 have white sclerotics and are unmarried; they have neither of them had fractures nor are they deaf.

III. 8, sister to III. 6, is now (Jan. 1927) in bed encased in plaster with a fractured spine and many fractured ribs as a result of falling downstairs; the family report that "they dare not take off the plaster lest she should fall to pieces"; her nephew, IV. 24, says that she has broken every limb and that her bones still, at the age of 61, break very readily; she is very deaf and has dark blue sclerotics of leaden hue; Stephenson saw her in 1915 when she was 4 feet 10 inches in height at the age of 50; her sister says she has an arcus senilis surrounding the cornea. Of the six children of III. 8, IV. 13 has blue sclerotics and Stephenson tells of a fracture of her leg at the age of 3 years; she is not deaf; at the age of 27 her height measured 4 feet $10\frac{1}{2}$ inches. IV. 15 was described by Stephenson in 1915; she has blue sclerotics and is now deaf, she has had no fractures but has sprained both ankles several times. IV. 16 has blue sclerotics and is not deaf; Stephenson saw her with her mother when she was aged 20, the mother then said that she fell out of bed at the age of 2 years and fractured her thigh; at 4 years she broke her leg by falling whilst running across the kitchen floor, she sprained her ankles several times and her mother "got quite used to picking her up broken." IV. 18 has blue sclerotics but is not deaf and has had no fractures. IV. 19 and 20 have normal sclerotics and are not deaf, but IV. 20 has a history of a broken leg at the age of 3 years.

III. 10, the fourth child of II. 3, died recently from "inflammation of the spine"; she had blue sclerotics, had once had a fractured jaw and had a history of repeated sprains; she was not deaf; she had six children of whom IV. 21 was still-born and IV. 22 died aged a few days; nothing was known of the eyes of these two siblings. IV. 23 has blue sclerotics and is not deaf; she has had no fractures but has suffered from repeated sprains. IV. 24 has deep blue sclerotics and is not deaf; he is short and of slender build; he had a broken leg at the age of 3 years, fractured his left arm at 16 and has broken his nose whilst boxing, but he maintains that he has no bone fragility and that all his fractures occurred from severe injury; he is now employed in motor works and winds up heavy cars without difficulty; he is an intelligent man of energetic habits. IV. 26 was killed in the war and is said to have had normal eyes. IV. 27 has white sclerotics, no history of fractures and no deafness.

II. 5, the third affected child of I. 1, died aged 52; her daughter reports that she had blue sclerotics, was deaf, and had on one occasion broken her ankle; she had a daughter and two sons of whom the sons had normal sclerotics and no history of fracture; III. 14 died aged 42, was married but had no children; III. 15, still living and aged 50, has two living normal children and two sons who had died aged 21 and 14 days respectively and who are said to have had normal sclerotics. III. 12, seen by Bishop Harman in 1910, was then aged 47 and had slaty-blue sclerotics, dark brown hair and brown irides; $V = \frac{6}{9}$; discs were oval and early senile lens opacities were present; seen by Riddell in 1926 she had a well-marked arcus senilis and was not deaf; her right lens was extracted by Hepburn in 1925; she fractured her left femur at the age of about 4 years; slight bossing of the skull is noted but no evidence of rickets; she maintains that she "loses a lot of blood if cut"; periods ceased at 52 years; she has had ten children, six of whom are still alive; the eldest daughter, IV. 29, writes, "I am aware that my eyes are of great interest to nearly every doctor I meet"; she broke her right arm at 9 days and again at 4 years, at a later date her left arm had been fractured, also a collar bone; her mother says that she bruises readily; she herself says that her hearing is very good; she is now (1926) aged 44. IV. 29 was seen by Bishop Harman in 1910 who describes her very deep slaty-blue sclerotics and says the coloration is more intense over the ciliary regions; her hair was then a dull gold and irides dark green; she had then one child, a boy, V. 17, aged $2\frac{1}{2}$ years, whose sclerotics were blue but less markedly so than his mother's. IV. 29 has now (1926) had three children; the boy died in 1920, and of the two girls V. 18 is normal and, V. 19, aged 4 years, has blue sclerotics not quite so pronounced as her mother's. IV. 29 writes that all her children were born with blue sclerotics but that the first two (V. 17, see above) "lost the blue" in the first twelve months; the children hear well and have no broken bones. IV. 30, aged 42 (1926), and his two children have normal sclerotics and have had no fractures. IV. 32 died aged 21 from rheumatic fever; he is said to have had blue sclerotics and to have fractured his left arm twice and his left leg twice. IV. 33, aged 39 (1926), has very blue sclerotics and had had some injury to his right wrist on one occasion which was possibly a fracture; he has one daughter, aged 12, with blue sclerotics who has twice broken her arm. IV. 35 died aged $3\frac{1}{2}$ years from croup; he is said to have had normal sclerotics and to have suffered no fractures. IV. 36 died aged 1 year and 9 months through drinking paraffin; he is said to have had blue sclerotics and to have had no fractures at the time of his death. IV. 37, aged 33 (1926), has blue sclerotics; at the age of 5 years she fractured her left leg and at the age of 10 years she twice fractured her left arm; her two children, aged 8 and 2 years respectively, have each blue sclerotics; V. 23 broke his arm at the age of 7. V. 24 broke her leg at the age of 2 years. IV. 39, seen by Bishop Harman at the age of 14, was considered by him to have sclerotics bluer than is normal though the condition was less pronounced in her than in her affected siblings; Riddell seeing her at the age of 31 says her sclerotics are not now blue, she has no arcus senilis, no deafness and no history of fracture; her one child, V. 25, aged 9 years, has normal sclerotics and no history of fracture. IV. 41 died aged $1\frac{1}{2}$ years from teething; he is said to have had normal sclerotics and no fractures. IV. 42, aged 26 (1926), has normal sclerotics and no history of fracture.

II. 7 had blue sclerotics; she died whilst her two boys were young, from a fall downstairs which fractured her spine; the two boys, III. 17 and 18, were brought up by III. 6, who reports that III. 17 had white sclerotics and that III. 18 had blue sclerotics and was very deformed; the latter is dead, but III. 17 now lives with IV. 24; neither brother was married. IV. 2 has five children of whom V. 1 has white sclerotics and no history of fracture; V. 2, with blue sclerotics, is said to have been born a cripple; her grandmother says "her hips went into her stomach," but from her account it seems likely that she had congenital dislocation of the hips. V. 3 died from measles at the age of $2\frac{1}{2}$; he had blue sclerotics but no fracture up to the time of his death. V. 4, with blue sclerotics, aged 14 (1926), had recently had a fracture of her arm whilst playing at school. V. 5 has white sclerotics and no history of fracture. IV. 6 has three children of whom V. 8, aged 17 (1926), has white sclerotics, is not deaf and has had no fractures; V. 9, aged 15, has blue sclerotics and had one fracture at the age of 3 years from falling up a step. V. 10 has white sclerotics and has had no fracture.

IV. 13 has three children, two girls and a boy, of whom the two girls have blue sclerotics and the boy has normal eyes. V. 13 had fractured legs at the age of 4 years. IV. 15 has one child with blue sclerotics, aged 2 years, who has had a dislocated shoulder. IV. 16 has one child, a boy, with white sclerotics. IV. 24 has one child, a boy aged 10 months who has blue sclerotics.

The affected members of this family show varying grades of defect as judged by the depth of colour of sclerotics and another example is here presented of the fact that severe grade of defect as based on this criterion may be, in individuals, unassociated with either of the commonly allied defects. There is little evidence in this family of true bone fragility, though the number of fractures which have occurred in the family are far in excess of what one would expect in a random sample of the population. There is a considerable amount of deafness occurring amongst affected members, but again the appearance of this defect does not indicate any criterion as to the severity of the associated defects; all we can insist upon is that wherever deafness or a tendency to bone fragility occurs the sclerotics are blue, but the converse does not hold. No consanguinity recorded. Bibl. Nos. 56, 57, 81 and additional information.

Fig. 603. *Riddell's Case.* Blue sclerotics in six males and eight females of four generations. No information was available concerning I. 1 and 2. II. 1 died aged 86; he was married but had no children; he was believed to be normal. II. 3, believed to be normal, died aged 95; he had six sons of whom one, III. 3, was reported to have had blue-grey sclerotics. II. 5 is reported to have had blue sclerotics and to have been slightly deaf; her only daughter, all her five grandchildren and four of her eight great-grandchildren were affected. II. 6 died aged 60 of bronchitis; a photograph of him showed a square prominent forehead and he was reported to have had slightly blue sclerotics; he was not known to have had any fractures. Of the children of II. 3, the eldest, III. 2, believed to be normal, had four normal children aged 22, 20, 13 and 5 years respectively. III. 3 died aged 48 of pneumonia and was unmarried. III. 4 and 6 were normal and married but had no children. III. 5 could not be traced and III. 7 died in infancy; none of this sibship was seen by the recorder.

III. 9, who died aged 47, is reported to have had blue sclerotics and to have been "slightly dull of hearing"; she had five children of whom IV. 5 was seen at age 48, she had blue sclerotics and brown irides with a marked arcus senilis; refraction was hypermetropic with some astigmatism; tension was normal; hearing was normal and teeth were fairly good; she had fractured her right elbow when about 6 years of age as a result of a fall when standing on an empty box; at the age of 16 and again a few years later she had sprained her left ankle and been laid up for a week; her skull showed a slight occipital protuberance. IV. 6 was seen aged 45, she had blue sclerotics and brown irides with marked arcus senilis; eyes were prominent and the patient was slightly deaf; teeth were quite good; there was a history of a fracture of the right patella at the age of 6 when she was knocked over by a dog and some injury to her right knee last January was followed by marked stiffness which still continues, no other joints were stiff; her skull showed very marked occipital protuberance, marked parietal protuberance and less well marked frontal prominence. IV. 7, aged 41, had dark blue sclerotics and brown irides with marked arcus senilis; he had slight exophthalmos and refraction was slightly hypermetropic, vision $\frac{6}{6}$; hearing was normal; there was a history of three fractures, two of which followed a perhaps adequate cause, thus, at the age of 16 he fractured his right elbow from knocking it against a railway carriage; at 34 he fell six feet off some staging and fractured his os calcis; at 41 he fell into a man-hole and fractured his left humerus; the fractures healed and functional result was good; his skull showed frontal and occipital protuberances; this patient had a positive Wassermann and a double aortic murmur with "waterhammer" pulse; thyroid was not prominent.

IV. 9 was seen aged 40; he had grey sclerotics and greyish green irides, arcus senilis was not present; hearing was good; teeth were bad; general development was fairly good and there was no history of fractures or dislocations; he had been under treatment in 1922 for six months for some skin lesion; the patient has since died of carcinoma recti. IV. 10, seen aged 38, had grey sclerotics, irides were green with brownish spots; there was no arcus senilis; visual acuity was $\frac{6}{6}$ and refraction was slight hypermetropia with some astigmatism; fundi were healthy and there was no evidence of arterio-sclerosis; there was no exophthalmos and tension was normal; this patient was slightly deaf, he had very good teeth and had no history of fractures or dislocations; skull was normal, and general development was excellent; height was 5 feet 11 inches.

Thus all members of the sibship IV. 5—7, 9 and 10 were affected and the two members who were married had affected offspring.

IV. 7 had five children of whom one son and two daughters are said to be affected; none of these children is described in detail by the recorder. IV. 10 had three children of whom one, V. 7, was affected. V. 7, aged 12, had blue-grey sclerotics and brown irides; she had no arcus senilis; visual acuity was good, $\frac{6}{6}$, and refraction was slightly hypermetropic; she had no exophthalmos and tension was normal; fundi were normal but darker than those of her twin sister and there was a small quantity of pigment round the borders of the discs; she was not deaf and had good teeth; there was no history of fractures or dislocations; this patient was well developed for her age but was three inches shorter than her twin sister whom she does not resemble. The twin sister, V. 8, was very well developed and was normal; she had slight hypermetropia; fundi were healthy but there was a small amount of pigment around the discs; irides were blue.

II. 6 had one daughter, III. 10, who died aged 55 from pernicious anaemia; she was said to have been dark with brown irides and blue-grey sclerotics, a photograph showed that she had a prominent frontal region; she was frequently taken to be a sister of IV. 6 as they were "so alike," especially about the eyes; she had had no fractures. III. 10 had seven children of whom four died in infancy, three were normal and had normal children. IV. 13 was examined at the age of 44, irides were blue and he had four perfectly healthy children with blue irides and fairish hair; one of these children, V. 9, broke his leg at the age of 9 years when a door swung back on him whilst at school. IV. 15 was seen, aged 41; she had blue-grey irides with normal sclerotics, visual acuity was $\frac{6}{6}$; she was not deaf but had bad teeth which were "soft and broke away"; she had a fracture of her left leg at the age of 8—10 years. Of the three children of IV. 15, the two eldest were healthy and normal; V. 15 had frontal and occipital protuberances and teeth were bad; he was a big healthy boy, aged 6, when seen and had a congenital hernia; he had normal sclerotics and had suffered from no fractures. Photographs of V. 13 and 14 showed that they also had prominent foreheads.

A significant feature of this history is the freedom from associated defects or the slight degree of severity in the symptoms associated with blue sclerotics when they occur; thus, of the fourteen affected members only three were known to have suffered from fractures and in no case does the history justify a diagnosis of fragilitas ossium; again in each of the four cases of associated deafness the defect is described as slight.

Dr Riddell allows us to publish this pedigree but he hopes at a later date to make further clinical observations on the cases. No consanguinity recorded. Hitherto unpublished.

Fig. 604. *Coulon's Case.* Blue sclerotics, the colour varying in intensity, in members of five generations. III. 7, aged 48, had marked blue sclerotics; he had had fractures of a wrist and three ribs, but only after considerable violence; he had slight hypermetropia. III. 4, sister to III. 7, had blue sclerotics and had had one fracture from a trifling cause; she had two children who had blue sclerotics but no history of fractures. II. 3, mother of III. 7, had blue sclerotics, also her sister, II. 2, and the sister's two children, III. 1 and 2, had blue sclerotics with no history of fractures. II. 5, another sister of II. 3, had normal sclerotics as also had her five children. III. 7 married a woman with normal sclerotics and all their five children had blue sclerotics. Thus IV. 4, aged 25, with brown irides had pale blue sclerotics and an embryontoxon at the upper and lower margins of each cornea; a letter from the recorder states that since the publication of his paper IV. 4 has had one female child with normal sclerotics. IV. 6, aged 22, with blue irides had deep blue sclerotics; she had slight hypermetropia and had had one fracture; her child with deep blue sclerotics died of congenital heart disease at the age of 1 week. IV. 7, aged 18, with brown irides had pale blue sclerotics; refraction was moderate hypermetropia; she had an embryontoxon at the upper and lower margin of each cornea; she had a history of one fracture four years previously. IV. 8, aged 14, with brown irides had pale blue sclerotics; embryontoxon at the upper and lower margin of each cornea; no fractures. IV. 9, aged 12, had deep blue sclerotics; well marked embryontoxon at the upper and lower margin of each cornea; she had a history of several fractures from trivial causes. The colour of the sclerotics in this family varied from a light azure blue to a very deep blue, and was uniform over the whole of the visible sclerotic. Writing at a later date the recorder states that III. 4, III. 7, III. 9 and III. 10 all had otosclerosis; the members of this sibship, who had normal-coloured sclerae, also had normal hearing; the deafness in all cases had come on after the age of 30 years; none of the children of III. 7 were yet deaf, but they were all still under the age of 30. Two children had been born since the earlier account of the family had been published, one with blue sclerotics and one who was normal in this respect. No consanguinity recorded. Bibl. Nos. 70, 89.

Fig. 605. *Schwarz's Case II.* II. 2, aged 31, with blue sclerotics, was under treatment for fracture of the left tibia; this was his sixth fracture, all had healed rapidly and well; he had heard badly for three years. Parents were healthy and normal; the patient was married and had a child aged 4 years who had blue sclerotics and had at the age of $1\frac{1}{2}$ years a fractured leg. No consanguinity recorded. Bibl. No. 144.

Fig. 606. *Cockayne's Case.* Blue sclerotics and brittle bones in ten members of three generations. III. 5, aged 11 years, has very blue sclerotics; she walked at the age of 18 months and from her mother's account she "began to fall about when about 2 years of age as if the legs gave way"; for about a year she could just manage to walk until, at the age of 3, she fell and broke her right femur, since when she has

broken her right leg or thigh four times and her left leg twice; the child had been getting stout recently (1926) and was admitted to hospital for investigation; fundi are normal, hearing good, teeth good; skull is normal in shape and the upper limbs of average length, the lower limbs are small and short; she is rather fat, especially in the mammary and pelvic regions; radiogram of skull shows pituitary fossa smaller than normal; all the bones are very slender and rarefied, this is noticeable in the long bones and ribs and especially in the metacarpals; some increase of sugar tolerance is noted and a slight degree of hypopituitarism is diagnosed; she is now unable even to stand up and the recorder was of the opinion that if she were to attempt to walk a fracture would occur.

Of the siblings of III. 5, the eldest brother, III. 1, has had two broken legs and his sclerotics are reported to be less blue than those of III. 5. III 2 has had no fractures and no blue sclerotics; III. 3 has fractured his leg five times, through falling down, the first fracture was before the age of 5 years; he has also broken both arms—otherwise he is in the best of health; his sclerotics are less blue than those of III. 5. III. 4 died aged $2\frac{1}{2}$ years; she had already had one broken leg and one broken thigh through falling when trying to walk; her sclerotics were "rather blue." The mother, II. 1, has normal eyes and no member of her ancestry was, so far as she knew, liable to fracture from slight causes. The father, II. 2, has deep blue sclerotics and has had four fractures in his lower extremities but never in his arms; he had one brother with normal eyes and no history of fracture, and two sisters who both have blue sclerotics and have each had one fracture only; one of these sisters, II. 4, is living in Canada and has children who have normal eyes and are accustomed to much skating and climbing and who have never had a fracture. Thus the liability to fracture in the father's sibship is relatively slight.

I. 4, the mother of II. 2, and her two brothers had blue sclerotics; I. 2 and 3 had each had a broken leg and I. 4 had had several fractures; I. 1, had normal sclerotics and no fractures. No case in this history other than the patient III. 5 appears to suffer severe disability from the liability to fracture and several members of the family have had only one fracture which may easily occur to a normal individual and be of no special significance. There appears to be no tendency to deafness in any member of the family.

We are indebted to the recorder of this case who put us in touch with the family and thus enabled us to expand the pedigree. No consanguinity recorded. Bibl. No. 140.

Fig. 607. *Cockayne's Case.* Blue sclerotics in three members of a sibship of six; the father and paternal grandfather were similarly affected; two sisters aged 20 and 9 years respectively and a brother aged 12 have normal sclerotics. Each of the affected children, aged 18, 16 and 14 years respectively, has had one or more fractures; they are no smaller and no less muscular than their unaffected siblings. The father, II. 2, has an unaffected brother and ten other siblings about whom no information could be obtained. I. 1 had blue sclerotics and had a fractured femur at the age of 60 years. No defect of hearing is associated with the blue sclerotics in this family. No consanguinity recorded. Hitherto unpublished.

Fig. 608. *Hass's Case.* Blue sclerotics in three generations of a family showing a marked history of heart disease, deafness and bone fragility amongst its members. I. 1 was markedly small and feeble; he died aged 56 from heart failure; he had blue sclerotics and was completely deaf at the age of 35. I. 2 was robust and lived to the age of 74. Of their fifteen children, seven died early and seven others had heart disease, three, in addition to heart failure, had blue sclerotics, brittle bones and were deaf, one was deaf without other associated defects; in this generation the deafness came on in middle age.

II. 8, Max. D., aged 52, was very small, had blue sclerotics, was deaf, suffered from heart disease and had some deformity of the left elbow from a spontaneous fracture in childhood, he had also had a fracture of the right humerus; he was said to have otosclerosis combined with some lesion of the internal ear. II. 10, Amalie S., aged 37, was very small and had very slender bones; at the age of 8 years, she had a fracture of the right elbow from a trifling cause and at 31 she had a fracture of the femur without demonstrable trauma; she had heart trouble, also was deaf from otosclerosis; her sclerotics were blue. II. 4, with the four associated defects, had five children of whom two died young and one had blue sclerotics and was deaf. II. 10 had one child with blue sclerotics aged 6; at the age of 2 years he fractured both femurs, later he again fractured a femur and his left leg, the trauma was slight in each case and the injury was accompanied by severe pain. No consanguinity. Bibl. No. 97.

Fig. 609. *Stewart's Case.* Blue sclerotics in eight members of two generations. II. 2 had blue sclerotics and had suffered from partial deafness since childhood; she had had her right femur fractured on two occasions, the first fracture occurred at the age of 2 years and the second two months later; she was the eldest of a sibship of ten, none of whom, except II. 2, has suffered from fractures, but four of the eight sisters have blue sclerotics; there is a suspicion of blue sclerotics in the mother of this sibship, but it could not be verified and the father appears to have been normal; neither of the parents has suffered from fractures.

II. 2 was married twice; by her first husband she had a daughter, L. G., III. 1, with blue sclerotics who at the age of 7 years had been treated in hospital on different occasions for ten complete and two greenstick fractures; the first fracture was at the age of 2 years when the injury concerned her left femur, after this she had six complete and one greenstick fracture of the right femur, two fractures of right humerus, one complete and one greenstick fracture of right tibia. By her second marriage, II. 2 had three

children of whom two have blue sclerotics and one is normal; the eldest of these children, III. 2, had a fracture of his right femur at the age of 2; III. 3 had had no fractures at the date of publication.

II. 5, with blue sclerotics but no history of fracture, had five children of whom one was still-born, one died young, one son and one daughter were normal and one son, III. 6, had blue sclerotics and had had six fractures of his leg bones at the age of 7; his first fracture was of the right tibia and fibula at the age of 2 years, since then he has had two fractures of the right femur, one of the right tibia, one of the left tibia and one greenstick fracture of the right fibula.

II. 8 with blue sclerotics had four normal daughters. We are indebted to the recorder for putting us into communication with Dr Muriel Price who obtained further information about the family for us after the original investigator had left the district. No consanguinity recorded. Bibl. No. 117.

Fig. 610. *Van der Hoeve's Case.* The Y. Family. Blue sclerotics with associated defects in three generations. I. 1 was not examined but was known to have blue sclerotics and to be very deaf; he had had two fractures and was of short stature; his three children all had blue sclerotics and there was no knowledge of further defects in II. 1, who was not seen by the recorder. II. 2, aged 58, was examined; he had had fractures of arm and elbow at an adult age, also on one occasion had a dislocated humerus; his stature was 1·52 m., width of outspread arms 1·62 m.; he had some myopic astigmatism and was so completely deaf that the type of the disease could not be determined; he had a very wide gerontoxon, also kyphoscoliosis. II. 4 was not examined but was known to have had two fractures.

III. 1 and 2, sons of II. 2, both had blue sclerotics and each had had two fractures. III. 1, aged 27, was examined, his stature was 1·85 m., width of outspread arms, 1·84 m., refraction was myopic astigmatism; he had a marked embryontoxon and was deaf, but the type of deafness was not definitely determined—it was said not to be a typical case of otosclerosis. III. 2, aged 25, was small and his refraction was hypermetropic; there was no knowledge of his hearing. No consanguinity recorded. Bibl. No. 90.

Plate XLIII. Fig. 611. *Stobie's Case.* Eighteen cases of blue sclerotics in five generations; five further members of generation II were said to have had "the same sort of eyes" but no definite information of these possibly additional cases could be obtained. The tint of blue in the sclerotics varied in different members from a deep porcelain blue to the just demonstrable blue of the infant which is abnormal in a child or adult; the tint was sometimes a slaty blue, and one case, which was not seen, is described as having nearly black eyes; the intensity of coloration of the sclerotics bore no relation to the severity of other associated symptoms. Two cases of colour-blindness are said to have occurred in the family; we are not told which are the colour-blind members.

Nine members of the family had suffered from fractures and there was no history or suggestion pointing to any deficiency or delay in healing. Certain abnormalities in the skeleton are noted in several individuals, thus, III. 13 and 21 had a considerable degree of kyphosis which commenced at the age of 24; II. 6 was said to have been markedly hump-backed which came on gradually in early adult life; III. 10 had a wedge-shaped head and was insistent that her father had a curious shaped head; IV. 6 was said to have difficulty in getting a hat to fit him and the size of his head was regarded as rather a joke in the family; III. 13 said that she could not get a cap to fit IV. 23, and that her daughter IV. 17 had a very prominent back to her head. The occipital region of IV. 17 was certainly prominent, also the parietal and occipital bones of IV. 23 and frontal eminences of IV. 29 were more than normally evident. A number of cases —III. 11, 13, 21 and IV. 6, 7, 17, 23 and 29—were examined by Dudley Buxton who concluded that on the whole there appeared little reason to believe that they possessed heads which might not be found amongst the normal inhabitants of the neighbourhood; cranial measurements were well above the average but not necessarily abnormal and similar values would certainly occur in any groups which included 200 persons of the general population of the neighbourhood; IV. 17 appeared to be the only definitely abnormal person; the problem, however, is whether the heads were unusual relative to the members of the family without blue sclerotics.

The appearance of the iris in the patients examined is described as a striking feature in that it lacked the normal clearness and presented an almost muddy appearance possibly partly due to an abnormal state of the cornea. The teeth showed deficiencies in many cases, thus in III. 10 the enamel of the lower incisors was worn away, in III. 13 the teeth are described as showing holes and breaking away on biting bread and a similar history of breaking off whilst eating was obtained in III. 21, IV. 6, 17 and 19; in three cases —IV. 29, 34 and V. 1—we are told that the teeth were good.

Deafness is described in eight cases, the onset taking place in adolescence or early adult life when the tendency to fractures diminishes. Sydney Scott examined the hearing of III. 11, 13, 21, IV. 7, 6 and 29; in the first four of these cases deafness was due to otosclerosis and "the similarity of these cases was very striking although the degree of deafness differed considerably"; the tympanic membranes were intact, lustrous and translucent in all and the inner tympanic wall was reflected as a flamingo pink; IV. 29 was doubtful. I. 1 died in old age; he was reported to have been deaf and to have had blue sclerotics; the date of onset of the deafness was unknown and there was no history of fractures. II. 6 died aged 63; he had blue sclerotics and became deaf when a young man; he is said to have had a curiously

shaped head and to have broken nearly every bone in his body. All other affected members of the family known to exist are descendants of II. 6.

III. 10, aged 49, first noticed a defect in her hearing at the age of 13 and was now quite deaf; she had a wedge-shaped head and had a fracture of her leg at the age of 4 years; Sigma test for Syphilis negative; she was inclined to fall about from attacks of giddiness; the enamel of her lower incisors was worn away. III. 11, aged 47, had blue sclerotics, he became deaf before the age of 20 and was now very deaf indeed and probably had advanced otosclerosis; he had had no fractures. III. 13, aged 45, had blue sclerotics and was slightly deaf; she was said to have otosclerosis in the right ear and defect of hearing in the left ear, possibly otosclerosis without fixation of the stapes; she was frequently giddy and had a fracture of the humerus at the age of 9 years; she had embryontoxon; her teeth used to "go into holes and break on pieces of bread." III. 17 died in the war aged 37; his sclerotics were said to be "nearly black"; there was no history of fractures; he became deaf when a young man. III. 21, aged 29, had slaty-blue sclerotics; deafness gradually developed at the age of 14—15, otosclerosis was diagnosed; she had a history of a fractured leg and a dislocated shoulder; thyroid was slightly prominent and hirsuties on the chin were present; at the age of 17 her teeth "began to come into holes in the middle and break right off." III. 23 died aged 4; he had blue sclerotics but had at this age no deafness and no history of fractures.

IV. 6, aged 28, had blue sclerotics; embryontoxon was present; fundi were normal; he had a divergent strabismus; hearing was normal; he had a large head; all his teeth had been extracted as "bits kept breaking off." IV. 7, aged 27, broke her arm at the age of 9 and her leg at the age of 16; embryontoxon was present; she often suffered from giddiness and had been getting deaf for the past two years, otosclerosis was diagnosed, upper and lower incisors were slightly chipped at the edges; Sigma test for Syphilis was negative. IV. 17, aged 23, with blue sclerotics had had seven fractures; she was not deaf and fundi were normal; twelve teeth were missing as the result of breaking off whilst eating. IV. 19, aged 18, with blue sclerotics had had no fractures and her hearing was normal; her teeth were said to "go into holes and break off"; occipital region of skull very prominent. IV. 20, with blue sclerotics, was aged 16; she had a history of a broken leg and was not deaf at present. IV. 23, aged 6, had blue sclerotics; he had four fractures before the age of 4 years and was not deaf; he had slight embryontoxon and some prominence of parietal and occipital bones is noted. IV. 29, aged 10, with blue sclerotics, had had a fracture of her leg; she was always noticeably deaf but the source of this defect was rather obscure and otosclerosis was not diagnosed; her teeth were good; she had slight exophthalmos and prominence of the frontal bones. IV. 34 and 35, also V. 1, were infants with blue sclerotics and had suffered no fractures yet.

There was no evidence of syphilitic taint shown by clinical signs in any members of the family. No consanguinity recorded. Bibl. No. 129.

Fig. 612. *Voorhoeve's Case.* Blue sclerotics in eleven members of three generations. The first members of this family to be examined were II. 6 and his two daughters, III. 21 and 26, and of them we are told that they appeared to be normal and full grown at birth—and that they had good health until about the age of 2—3 years when the first fracture after very slight trauma occurred; this was followed by numerous other fractures, the father had five fractures and his daughters had thirteen and fifteen respectively; with puberty the frequency diminished and from this time bone fractures only occurred sporadically; nearly all healed without leaving any disability, a few healed in bad position or did not sufficiently consolidate. X-rays showed throughout the entire skeleton a very thin cortex which stood out sharply from the surrounding tissues; there was a deficiency of lime salts and a rarefaction of the bone supports with an absence of every rachitical alteration. In certain fractures little or no endosteal but very strong periosteal callus had been formed, and the recorder considered them to be typical cases of *osteopsathyrosis infantilis.* III. 21 and 26 had dark grey-blue sclerotics, their father's sclerotics were concealed by pingueculae; all three patients were of slender build and small size, and had very high palates; they were very intelligent. III. 21 had too small jaws and her lateral incisors were planted inwards; both her little fingers were in radial adduction to the metacarpo-phalangeal joint. Other abnormalities were noted in II. 6 as follows: he had very marked arcus senilis; he had an exophthalmia of the left eye which showed itself when at about 6 years of age, he suffered from "glands in the eyes"; he had maculae corneae with consequent irregular astigmatism, a myopia of 10 D. and a small sickle in the fundus. Further, II. 6 suffered from haemophilia but no details are given of the severity of this condition or the facts upon which the diagnosis was based; if we may accept the diagnosis, it is of interest to find a bleeder who has suffered five fractures and lived to talk about it; at the age of 54 he had severe arterio-sclerosis and we are told that his ears stood out markedly from his head.

The recorder examined a large number of members of this family but he gives no detailed account of other cases: it would appear that the blueness of the sclerotics is less marked in the other cases and is associated in none of the other cases with fragilitas ossium—one further case of fragilitas ossium however occurs in III. 1, who was not known to have had blue sclerotics and who had a congenital deformity of the heart. Haemophilia occurred in II. 11, in IV. 4 and in IV. 6, as well as in II. 6, as noted above; tuberculosis is noted in II. 8, II. 12, II. 13, III. 14, III. 20 and IV. 2, also in II. 6, who had scars of tuberculous fistulae in his neck; severe rachitis is described in III. 8; other congenital abnormalities the

exact nature of which is not indicated were present in II. 9, II. 14, III. 28 and III. 33. The recorder states that Professor Burger examined the ears of two of his patients and found typical labyrinthine deafness. Of other members of the family not introduced into the pedigree the recorder has details of 83 descendants of the parents of I. 1, one of whom was haemophilic, one had epilepsy and seven were tuberculous; of 69 further descendants of the parents of I. 2, one had congenital deformity of the heart, one was "born lame," one was a dwarf, one a hunchback and six were tuberculous; of 33 further descendants of the parents of II. 7, two were hunchbacks, three had tuberculosis of the lymph glands and one severe rachitis.

The recorder makes the interesting suggestion of a possible hereditary defect of the mesenchyme as the underlying source of all the allied defects of this pedigree. No consanguinity. Bibl. No. 93.

Fig. 613. *Bronson's Case.* A very fully worked out pedigree of blue sclerotics associated with fragilitas ossium and deafness. Of the twenty-one affected members, thirteen had a history of fractures, six died in infancy, one was an infant still and one, a healthy boy aged 6 years, had had no fractures; seven of the affected members suffered from deafness.

I. 2, William C., had deep blue sclerotics; he had a history of multiple fractures and sprains and was much crippled; he was short and slender and the shape of his head was "remembered by all who saw him," the frontal and occipital regions were prominent and there was a "soft spot on the top"; he suffered from a moderate degree of deafness. I. 3 was said to have blue sclerotics and a history of fractures; she could not be traced.

In the next generation, II. 2 had eyes and head like those of I. 2 and had a history of multiple fractures; she was very deaf. II. 3 was a large woman with sloping forehead, white sclerotics, normal hearing and no fractures; her seven children and nine grandchildren were all normal. II. 5 died aged 23; she had deep blue sclerotics and had had several fractures but was tall and slender and not crippled; her hearing was normal. II. 6, aged 49, had deep grey-blue sclerotics; she was of medium height, slender and somewhat crippled as a result of multiple fractures; she had also sprained her ankles and dislocated her fingers easily since childhood; the shape of her head was typical of this family with its prominent frontal and occipital regions; she had had increasing deafness since adolescence; she had one child, III. 22, who died in infancy and had deep blue sclerotics. II. 8, with deep blue sclerotics, had lost count of the number of her fractures and sprains which had occurred since early girlhood; she was of medium height and had the characteristic full forehead and prominent occipital region. II. 10 was in Canada but was reported to have white sclerotics and no history of fractures.

Of the children of II. 2, five died in infancy or were still-born and of these one only, III. 1, was known to have had blue sclerotics. III. 5 had blue sclerotics but the coloration was less intense than in some cases; she had had multiple fractures and sprains with a resulting deformity; she was a short woman with full forehead and prominent occipital region and she had had a deafness which was progressive for 20 years. III. 7 was a well built healthy and normal woman. III. 9, aged 35, had blue sclerotics; her forehead and occipital regions were prominent; she had a history of multiple fractures and sprains and had had a progressive deafness since the age of 16 years. III. 20, the only child of II. 5, had the deepest blue sclerotics of any seen; she was a short stout woman and had a history of multiple fractures and dislocations, her hearing was a little defective. Of the children of II. 8, seven were normal and two had the family defect: III. 30, aged 10, had moderate blue coloration of the sclerotics and had already had two fractures of his arm; he was short and thick-set with a full forehead and prominence of the parietal and temporal regions. III. 31, aged 8, had very deep blue sclerotics and had already had multiple fractures; she was fragile and undersized and had the typically shaped head.

Of the children of III. 5, one died in infancy with white sclerotics and the other five had blue sclerotics. Thus, IV. 2 died in infancy without fractures. IV. 3, aged 6 years, with medium blue sclerotics and the typically shaped head, had had no fractures. IV. 4 died in infancy without fractures. IV. 5, aged 3 years, had rather deeper blue sclerotics than his brother, IV. 3, had the same type of head, and had had one fracture of his R. arm. IV. 6 died of pneumonia aged 11 months whilst the family was under observation; he had medium blue sclerotics, a very marked occipital protuberance, and had had no fractures; an eye was excised for examination and it was reported that the sclerotic was of normal thickness. IV. 11, aged 12, the only child of III. 9, had eyes and shape of head very like her mother's; she had a history of multiple sprains and two fractured clavicles. III. 20 had three children of whom IV. 21 had white sclerotics and no history of fractures but could dislocate fingers and toes at will. IV. 22 died in infancy and had deep blue sclerotics. IV. 23, aged 4 months, had blue sclerotics and the family type of head with full frontal region. No consanguinity recorded. Bibl. No. 83.

Fig. 614. *Alexander's Case.* Blue sclerotics associated with brittle bones in four generations. IV. 1, F. F., aged 7 years, was reported to suffer from repeated fractures; the most recent had been one of the lower end of the right tibia; some deformity was present in right leg and right thigh as a result of previous fractures of the tibia and femur, the latter having occurred at birth; the left humerus, tibia and fibula had also been fractured and healed with perfect union and minimal amount of callus. The child was pale and debilitated, the forehead more prominent than usual but no evidence of rickets appeared; he had markedly blue sclerotics; in other respects he was healthy. The mother, III. 2, also had very deep blue

sclerotics but had had no fractures; she had suffered from deafness for many years; her other two children IV. 2 and 3 had blue sclerotics but had had no fractures. III. 3, sister to III. 2, was reported to have had seven fractures during her life and had deep blue sclerotics. II. 2, mother of III. 2, also I. 1, her grandmother, had been the subjects of fragile bones and blue sclerotics.

The recorder endeavoured to get further information and to hear whether there were normal members in any of the sibships affected but was unable to get into touch with the family again. No consanguinity recorded. Bibl. No. 109.

Fig. 615. *Hansson's Case.* Blue sclerotics in five sisters and a brother of a sibship of nine; their mother and the son of one of the affected sisters are also affected. IV. 1, aged 15 when seen, had blue sclerotics and was suffering from a fracture of the shaft of the right femur; it was his thirteenth fracture, the first having occurred at the age of 1½ years; his father and his four paternal aunts were normal, also his paternal grandparents were normal though II. 1 had had a fractured femur when she was over 60 years of age. III. 6, the mother of IV. 1, had markedly blue sclerotics and could definitely remember having had six fractures of which three had occurred before the age of 6 years; she had no fractures between the ages of 14 and 22, at the latter age she slipped and fractured her femur; since that time no further accident had occurred; her hearing was good and teeth were normal; IV. 1 was her only child. Of the siblings of III. 6, one sister, III. 14, had died young, one brother, III. 15, was drowned aged 25; neither of them had had fractures; III. 7, 8, 9, 11 and 12 all had blue sclerotics, III. 9 had two probably normal children, III. 7 fell from a palisade and broke her arm, III. 8 slipped on one occasion and broke a leg, III. 12 slipped on one occasion and broke his leg. Thus the history does not justify a diagnosis of fragilitas ossium in II. 1, or in III. 7, 8 and 12 though they had each suffered from one fracture.

All the four grandparents and the father of the affected sibship were free from the defect but their mother, II. 4, had blue sclerotics and four or five fractures of which the first had occurred at the age of 14. The brother and sister of II. 4 were not affected. No consanguinity recorded. Bibl. No. 112.

Fig. 616. *Van der Hoeve and Kleijn's Case.* Blue sclerotics, brittle bones, deafness and syndactyly in members of two or perhaps three generations. I. 1 was known to have had one fracture as a child and had been very deaf from the age of 14 years to her death at the age of 63; she was of short stature; nothing was known of the colour of her sclerotics. Of the six children of I. 1, four had blue sclerotics and other associated anomalies; II. 1 died aged 46, and was apparently normal; II 2 died aged 47, she had been examined and had blue sclerotics, had had three fractures as a child and had been very deaf since the age of 20 years; she had poor vision but the nature of the trouble is not noted; her two sons aged 15 and 12 respectively were examined and appeared to be normal, they were not deaf, had no syndactyly; had slight hypermetropia, were of stature 1·57 m. and 1·39 m. respectively and the width of their outspread arms was 1·56 m. and 1·32 m. respectively. II. 4, aged 62, was examined; she had blue sclerotics; as a child she had three fractures of her leg, wrist and knee, she had dislocated her foot three times and was bow-legged on each side; her stature was 1·35 m., width of outspread arms 1·42 m.; she had been deaf since before the age of 30; she had incipient cataract and myopia of 3 D.; she had no syndactyly. II. 5, aged 60, was examined; he had blue sclerotics and had had four fractures when young, more recently he had dislocated his foot three times; his stature was 1·44 m. and width with outspread arms 1·48 m.; he was deaf, had slight hypermetropia and syndactyly affecting the second and third toes; he was married and had had one son who was still-born.

II. 7, aged 55, was examined: she had blue sclerotics and had a history of two fractures, one at the age of 6, the other at the age of 16 years; her stature was 1·38 m., width of outspread arms 1·35 m.; she was deaf and had myopia of 3 D.; no information of syndactyly. II. 7 had seven children, III. 5—11, all of whom were examined; III. 5, aged 27, was normal in all respects and had a normal child aged 3; her stature was 1·63 m. and width with outspread arms 1·66 m.; the six siblings of III. 5 all had blue sclerotics, all were deaf and all had syndactyly affecting the second and third right toes; in III. 7 the third and fourth toes of the left side were also joined. III. 6, aged 22, had 18 fractures between the ages of 2 and 16; her stature was 1·33 m. and width of outspread arms 1·50 m.; she had some astigmatism. III. 7, aged 21, had 11 fractures between the ages of 4 and 13 years; she had some hypermetropic astigmatism, her stature was 1·29 m., and width of outspread arms 1·46 m. III. 8, aged 19, had 11 fractures between the ages of 2 and 14 years; she was emmetropic and of stature 1·44 m.; width of outspread arms was 1·48 m. III. 9, aged 16, had one fracture at the age of 9; she had lordosis and scoliosis; her stature was 1·45 m., width of outspread arms 1·43 m.; some myopic astigmatism. III. 10, aged 12, had two fractures at the age of 10 and 11 years respectively; she had mixed astigmatism, stature of 1·27 m. and width of outspread arms 1·24 m. III. 11, aged 11, had had no fractures; he had some hypermetropic astigmatism, stature of 1·39 m. and width of outspread arms 1·35 m.

II. 9, aged 49, had normal sclerotics and had had no fractures but she had cataract; her stature was 1·51 m. and width of outspread arms 1·50 m.; hearing was normal; she had four children who were not examined but were believed to have normal sclerotics and to have had no fractures; one of the four children died at the age of 9 months.

The siblings III. 6—11 were very fully examined and the internal organs, nervous system and sexual organs were found to be normal; the sella turcica of III. 6 was examined under X-rays and was normal; all the affected members were small and delicately built individuals; the deafness in all cases was due to otosclerosis primarily with a secondary labyrinthine disease. A detailed examination of the hearing with the results of a great variety of tests is given in the German version of the history.

X-ray examination showed marked changes in the structure of the bones. No consanguinity. Bibl. Nos. 85, 90.

Fig. 617. *Berneaud's Case I.* Blue sclerotics in seven individuals of four generations with a history of fractures in six members of the family. III. 2, Böttger by name, had dark blue sclerotics and had had seven fractures no details of which are given; he had five children of whom IV. 1, male, had bluish sclerotics and a history of two fractures; IV. 2, female, had white sclerotics and had had one fracture; IV. 3, female, with blue sclerotics had had two fractures; IV. 4, female, had blue sclerotics and a history of three fractures; IV. 5, male, with bluish sclerotics had had no fractures. The mother and grandmother of III. 2 had blue sclerotics; II. 2 had been known to have one fracture but no information is given of fractures in I. 4. III. 2 had a sister with normal eyes who had had no fractures.

No information is given of the nature of the fractures in any case nor of the ease with which they occurred. No consanguinity recorded. Bibl. No. 135.

Plate XLIV. Fig. 618. *Burrows's Case.* Thirteen cases of blue sclerotics in four generations. No details of individual cases are given by the recorder but multiple fractures from slight causes are described as occurring in association with the blue sclerotics in eight cases. No consanguinity recorded. Bibl. No. 59.

Fig. 619. *Adair-Dighton's Case.* Nine cases of blue sclerotics in four generations. II. 2, aged 49, was seen with marked azure blue sclerotics and a gerontoxon; he had slight hypermetropia in both eyes; he had had fractures of both legs as a child and had recently fractured his R. olecranon whilst swimming. II. 3, the only sibling of II. 2, had normal sclerotics. I. 2, the father of II. 2, had blue sclerotics but his two sisters I. 3 and 4, had white sclerotics. II. 2 married a normal wife and six of their eight children had blue sclerotics. III. 2, aged 23, with blue sclerotics had no embryontoxon; she had had fractures of both legs from slight causes and also nerve deafness which was first noticed when her child was aged 3 months; refraction was slight hypermetropia. IV. 1, aged 1 year 9 months, had blue sclerotics; no embryontoxon. III. 3, aged 22, had pale azure blue sclerotics, no embryontoxon; refraction was hypermetropic; she had had one fracture of her right leg. III. 4, aged 19, had pale azure blue sclerotics, no embryontoxon; refraction was hypermetropic; he had had a Colles's fracture of one wrist and a fracture of one arm. III. 5, aged 18, had white sclerotics and no history of fracture. III. 6, with white sclerotics, died at an early age from meningitis. III. 7, aged 14, had pale azure blue sclerotics with no embryontoxon; refraction was hypermetropic; he had been operated on for genu valgum, had fractured his right clavicle once, his right arm twice, and his left arm once. III. 8, aged 13, and III. 9, aged 8, had pale azure blue sclerotics, hypermetropia but no history of fractures. No consanguinity recorded. Bibl. No. 63.

Fig. 620. *Peters's Case.* Blue sclerotics in four generations associated with fragilitas ossium. In three sibships comprising nine individuals only one member is reported as having normal sclerotics. III. 2 and his two sons, IV. 1 and 2, were seen to have deep blue sclerotics and embryontoxon in both eyes; the father said that his four-year-old daughter, IV. 3, had also blue sclerotics. The father's brother, III. 4, wrote that he had the same anomaly and that of his two children, a son, IV. 4, who had recently died, had blue sclerotics whilst his living daughter, IV. 5, was normal; he also reported that his mother and her parents had the same defect. (The recorder considers that probably he only meant one parent.) A surgeon wrote giving information of the father's sister, III. 5, who had the defect and who also had an embryontoxon in each eye, and he reported that her sister, III. 6, was also affected. At a subsequent date the author enquired for a history of fractures and found that there had been multiple fractures in at least three individuals, namely III. 2, IV. 1 and IV. 2. No consanguinity recorded. Bibl. Nos. 53, 71.

Fig. 621. *Berneaud's Case II.* Blue sclerotics in thirteen members of four generations; five of the cases presented only a slight grade of defect; four of the affected members have a history of fractured bones.

I. 2, Gehrke by name, according to the consistent accounts of all members of the family had dark blue sclerotics and had suffered from two fractured bones and many sprains; he was married twice; one of his five children by the first wife had blue sclerotics and had had one fracture; he, II. 2, was married and had one son, III. 1, with blue sclerotics and a history of twelve fractures. As an example of the ease with which fractures occurred in III. 1, the recorder tells of how he broke a bone one day and was taken to hospital where, in spite of all the efforts of the surgeon, the bone healed crookedly; whilst in hospital he was restless at night and broke his arm whilst turning over in bed and when he was finally discharged he made a false step on leaving the hospital and broke another bone.

II. 4—7 had normal sclerotics and had suffered from no fractures, but II. 4, the only one of these four siblings to be married had one of her three children and two of her nine grandchildren with bluish sclerotics; no members of generation III or IV had fractures except III. 1.

By his second marriage I. 2 had three children of whom two, II. 8 and 10, had blue sclerotics; II. 12 and her two sons had normal eyes; II. 8 had no fractures, II. 10 had a history of three broken bones; both the children of II. 8 and the three children of II. 10 had blue sclerotics but the condition was less marked in the case of III. 10 and 12 than in the other cases and none of these children had fractures. No consanguinity recorded. Bibl. No. 135.

Fig. 622. *Cockayne's Case.* Six individuals in four generations with blue sclerotics. IV. 2, aged 1 year 10 months, was brought up for treatment by her mother who thought she was suffering from rickets; she had not yet walked or made any attempt to do so; her sclerotics were of a deep uniform blue colour; hair was fair and teeth normal; X-rays of legs and right arm showed no evidence of old fracture; there was no evidence of rickets and the middle of the shafts of the long bones showed a normal amount of compact bone but they appeared to be more transparent than is normal at this age towards their extremities; the patient was smaller than her sister had been at the same age. III. 2 had blue sclerotics; he broke both legs at the age of 16 and had had many injuries since, including a broken femur and several broken ribs following a fall from his bicycle. III. 3 had blue sclerotics; she had fractured one ankle and sprained the other by slipping off the bottom step of a staircase. III. 2 and 3 were both small and slight, the former only weighing 7 stones 2 lbs. II. 2 had blue sclerotics and was very small, only weighing $7\frac{1}{2}$ stones; he had fractured every bone in his body and many ribs; he had also repeatedly sprained his joints. II. 5 had blue sclerotics, was very small and had sprained both wrists and both ankles. I. 1 was small and had blue sclerotics; he further had a history of numerous sprains and fractures. No consanguinity recorded. Bibl. No. 74.

Fig. 623. *Ruttin's Case.* Blue sclerotics in three males and four females of three generations. No information is given of I. 1 and 2; they had four children of whom II. 1, aged 64, had blue sclerotics and had heard badly since her youth, the informant had no knowledge as to whether she had had any fractures. II. 2, aged 62, had blue sclerotics; he heard well and had had no fractures; he had two children, aged 30—35, who were normal. II. 4, aged 60, had heard badly since her youth, it was not known whether she had blue sclerotics, but her six children are said to have suffered from repeated fractures; these children were aged 20—30, all were said to have normal hearing and the colour of their sclerotics was not known. II. 6, aged 58, had blue sclerotics; he had been deaf since the age of 21 and had once broken his arm; he had two daughters both of whom were affected.

III. 4, aged 32, had blue sclerotics and had been very deaf since the age of 16; the deafness was associated with noises in her ears. III. 6, aged 28, with blue sclerotics had been deaf since the age of 13; she had once broken her foot. III. 6 had two children, a daughter aged 3 and a son aged 2 years, both of whom have blue sclerotics but hear well and have had no fractures. No consanguinity recorded. Bibl. No. 115.

Fig. 624. *Bronson's Case.* Blue sclerotics associated with fragilitas ossium in three generations. I. 2 had blue sclerotics and was considered to be "loose jointed" but he had had no fractures; he did not remember his parents' eyes. II. 2, Thomas W., aged 39, had greyish blue sclerotics, also an embryontoxon; he had had occasional fractures on slight provocation all his life; he had also sprained his ankles many times and had marked hypotonicity of all his joints; his height was 5 ft. $2\frac{1}{2}$ ins.; his skull showed no frontal prominence but the bi-temporal diameter was increased. II. 4, Mrs M., had blue sclerotics with no history of fractures. III. 1, Emily W., aged 10, had the deepest blue sclerotics of the family; she had already had many fractures. III. 2 was normal. III. 3, Myra W., aged 6, had grey-blue sclerotics; she was a short thick-set little girl with hypotonicity of all her joints; she had had no fractures but had sprained each ankle once; her skull showed an increased bi-temporal diameter. III. 4, Winifred W., aged $3\frac{2}{12}$, had grey-blue sclerotics and had already had three fractures. III. 5 died, aged $1\frac{2}{12}$ years, soon after a fracture of one leg; she had blue sclerotics. No consanguinity recorded. Bibl. Nos. 83, 96.

Fig. 625. *Blegvad and Haxthausen's Case.* Ten cases of blue sclerotics in three generations; the condition in this pedigree is associated with brittle bones and deafness in several cases. Only one case, a female aged 23, was examined and it was she, II. 10, who provided the family history. II. 10 had typical blue sclerotics, was dull of hearing and had had several fractures; thus she had broken her right arm twice, her left forearm once, both legs once, right clavicle once and one rib once, each fracture following very slight trauma, the last having occurred at the age of 13. II. 10 now weighed 35 kg.; her stature measured 142 cm. and the distance between finger tips with outstretched arms 152 cm.; her cornea showed distinct arcus juvenilis above and below; R.V. = L.V. = $\frac{6}{9}$; both sclerotics of a rather deep grey-blue colour especially in the area corresponding to the ciliary body which is sharply outlined through the sclerotics; on dilatation of the pupils a zonular cataract was seen in both eyes. The patient was small and slender; she had a kyphoscoliosis with pronounced curvature to the right in the dorsal region and a curvature to the left in the lumbar region; X-rays showed no trace of previous fractures but the bones appeared to be but slightly calcareous and showed defective development. Both tympanic membranes were red and retracted and hearing on both sides was slightly reduced. The lower part of the neck and upper part of

chest were affected with a strange zonular cutaneous disease; spots of an irregular form and of a greyish purple colour varied in size from that of a millet seed to that of a farthing; their surface was below that of the surrounding skin and the veins showed through; the surface of the skin in the affected parts was atrophic, smooth, without scales or crusts, and the hair follicles seemed to be normal; microscopic examination of the affected skin showed no changes in the epidermis but an atrophy of the corium was present which especially attacked the elastic tissues. Further details are given in the original account of the case. It would be of interest to hear whether other affected members of this family were definitely free from zonular cataract and skin affection. No consanguinity recorded. Bibl. No. 103.

Fig. 626. *Ruttin's Case.* Blue sclerotics in six males and four females of three generations. I. 1 had blue sclerotics but his daughter, II. 7, did not know whether he had ever had a fracture; he died aged 56 and since the age of 35 he had been so deaf that he had had to use an ear trumpet; his father was said to be healthy and not deaf, but it was not known whether he had blue sclerotics. I. 1 and 2 had sixteen children of whom nine died between the ages of a few months and 15 years, and of these there was no record; of other members of the sibship, II. 1 had blue sclerotics but no history of fractures; she was very deaf at the age of 35 but did not use an ear trumpet; she died aged 54 from heart failure. II. 3 died aged 53 from heart failure; he had blue sclerotics and had a fracture in his foot whilst dancing; he was deaf and at the age of 22 used an ear trumpet but later could not hear at all. II. 5 had blue sclerotics and once had a fracture following an accident; he used an ear trumpet and suffered from giddiness but not from noises in his ears; his tympanic membrane was thickened and retracted, otosclerosis was diagnosed. II. 6, aged 37, had blue sclerotics, he had had no fractures; hearing was not very good. II. 7, aged 36, had blue sclerotics, was rather dull of hearing and had had a dislocation of the hip, otosclerosis was diagnosed. II. 9 died, aged 29, from heart failure; she had normal sclerotics, had no fractures and was not deaf. II. 10 died, aged 15, from heart failure; her hearing was good but it was not known whether she had blue sclerotics or whether she had ever suffered from fractures.

II. 1 had three children of whom III. 1 died, aged 14 days; III. 2, aged 38, was normal and heard well; III. 3, aged 30, had blue sclerotics, she had no fractures and was not deaf. II. 3 had five children of whom III. 4 died, aged 8 days, from an unknown cause; III. 5 died, aged 6 years, from scarlet fever; III. 6, aged 22, was normal; III. 7, aged 21, heard with difficulty and had blue sclerotics; he had fractured an arm whilst doing gymnastics. III. 8, aged 18, had blue sclerotics; she heard well and had had no fractures. II. 5 and 6 had no children. II. 7 had one son aged $7\frac{1}{2}$ years with blue sclerotics; he had had one fracture; his hearing was good.

The occurrence of heart failure in four members of generation II is of interest and it is unfortunate that we have no knowledge of the cause of death of nine members of this sibship and further have no knowledge of the colour of the sclerotics in these nine members, in II. 10 or in III. 1 and III. 4 and 5 of the next generation. No consanguinity recorded. Bibl. No. 115.

Fig. 627. *Terry's Case.* Blue sclerotics and brittle bones in a female and in her father; her paternal aunts and uncles and her brother and sister were normal and had had no fractures. II. 2, Mrs J., aged 42, was undergoing a hysterectomy for uterine fibroids; she stated that at the age of 8 months she had fractured her tibia and that since this time she had had at least sixty other fractures involving most of the long bones as well as the pelvis and both patellae; she had fractures of the phalanges from merely shaking hands; neither femur had been broken until at the age of 41 when both legs (tibiae and fibulae) and left femur were fractured whilst walking to her door; she said that her legs gave way and she fell to the floor but believed that the bones broke before the fall; three months before this she had had fractures of the left tibia and left patella. II. 2 said that she seldom called in a surgeon but set the bones herself and so had numerous deformities; she had noticed that her fractures united more rapidly than normal, some of them being firm in nine days; she had little pain or tenderness and the amount of callus was very small. Marked prominence of the frontal bones is noted and marked blueness of sclerotics; there was almost complete deafness of left ear; there was no bending of bones; X-rays showed a markedly thin cortex; Wassermann was negative.

I. 3 died, aged 51; he had had blue sclerotics and a history of many fractures. No consanguinity recorded. Bibl. No. 92.

Fig. 628. *Straat's Case.* Six cases of blue sclerotics in three generations. I. 1, female, aged 67, had blue sclerotics; she became deaf at the age of 24; her family had never heard that she had broken any bones; her husband was normal. I. 1 had three daughters and one son; two of the daughters, II. 2 and 6, were normal and had normal children; II. 3, aged 37, had markedly blue sclerotics; she had become deaf between her tenth and fourteenth year, this condition had slowly progressed until now she was absolutely deaf; she had a history of one fracture; her visual acuity appeared to be weak and she had a bilateral arcus senilis; she had blue irides, "donkerblond" hair, stature 158 cm. II. 5, male, aged 35, unmarried, had blue sclerotics; he was very deaf at the age of 30 and in his youth had broken one arm many times; his visual acuity was weak; hair fair, irides brown, stature 168 cm. The deafness in II. 3 and II. 5 was due to otosclerosis. II. 3 had five children of whom three were affected and two girls, III. 4 and 6, were normal. III. 2, male,

aged 10, had light blue sclerotics and had once broken an arm; he was not deaf; he had blue irides, fair hair and a stature of 140 cm. III. 3, female, aged 8, had markedly blue sclerotics, had twice broken a bone and had frequently sprained her foot; she was not deaf; had brown irides and fair hair, stature 127 cm. III. 5, male, aged 4, had slate blue sclerotics and twice had broken his arm; he had blue irides, fair hair and stature of 104 cm. The children of this generation were too young to be assured that otosclerosis would not develop. Radiological examination of III. 5 showed no abnormality in the skeleton. II. 4 was normal. No consanguinity recorded. Bibl. No. 125.

Fig. 629. *Ruttin's Case.* Blue sclerotics and brittle bones in a male and in three of his four children. I. 1 and 2 were healthy but I. 2 died, aged 40, after childbirth; they had nine children of whom three daughters and four sons were living and healthy, one son died from "paralysis" and one son, M. Sch., had blue sclerotics and had a history of repeated fractures which had resulted in a shortening of the right leg. M. Sch., II. 1, was aged 52; at the age of 42 he noticed that he saw badly with his left eye and heard badly on the right side; two years later he had an operation for cataract; during the last four years he had suffered from buzzing in his head and ears and his hearing had become much worse on both sides, lately he had had repeated attacks of giddiness; the tympanic membrane was thickened and retracted; Wassermann test was negative. II. 1 was married and had four children of whom three had blue sclerotics and had repeated fractures. No consanguinity recorded. Bibl. No. 115.

Fig. 630. *Bolten's Case.* I. 1 was very nervous and alcoholic; he had three sons, all nervous but healthy and able to work, and three daughters who were all more definitely psychopathic; thus, II. 4 suffered from manio-depressive psychoses and sometimes had to be looked after in an institution; II. 5 was very nervous; II. 6 also had slight maniacal symptoms and showed signs of sympathetic hypotonia such as frequent attacks of angioneurotic oedema of the lip and nose, migraine, vaso-motor affections of the fingers and toes and nose bleeding; she also had flat foot. Of the seven children of II. 6, all had flat foot and symptoms of vaso-motor defect; they had always cold cyanotic fingers and toes and suffered from frost bite in winter; further, all were liable to attacks of urticaria. III. 1, aged 18, and III. 2, aged 11, had very fragile skeletons and markedly blue sclerotics; the other five children had up to now not shown that they had brittle bones but several of the younger members have slightly blue coloured sclerotics. No consanguinity recorded. Bibl. No. 94.

Fig. 631. *Apert and Cambessédès's Case.* Three cases of blue sclerotics and bone fragility in a sibship of five. The parents, I. 1 and 2, were Polish Jews and the mother said that there were no cases of blue sclerotics or brittle bones in her family or in her husband's family to her knowledge; the father had a heart affection of rheumatic origin. II. 2, aged 11, was a well-developed intelligent child; she had blackish blue sclerotics, the depth of coloration varying with the distance from the cornea and the sclerotic appeared to be soft in the most intensely coloured zones; she had had seven fractures of the left lower limb in each case following slight trauma; the fractures occurred at the ages of 5, 7, 9, 10 and 11 years; she had no deformity of the trunk but the skull was enlarged in the temporal and occipital regions; she had good general health and was not deaf. II. 1, aged $12\frac{1}{2}$, had blue sclerotics less deeply coloured than those of II. 2; he had had one fracture of the lower extremity following a fall and was suffering from a tubercular affection of the right lachrymal sac and from chronic bilateral cervical adenitis. II. 3, aged 8, and II. 4, aged 5, had normal sclerotics and no history of fracture. II. 5, aged 4, had sclerotics almost as deeply coloured as those of her sister II. 2, and had moreover spots of black pigment on the sclerotics; at the age of 2 years, when learning to walk, she fell and fractured her right clavicle. No consanguinity recorded. Bibl. No. 100.

Fig. 632. *Wiechmann and Paal's Case.* Blue sclerotics in three sisters of a sibship of five and in their father; two brothers had died, one of them at about the age of 42. I. 1 died from apoplexy; he was very small and had blue sclerotics but there was no history of fracture and he was not deaf. I. 2 was healthy and lived to the age of about 73. II. 1 was seen at the age of 55; she was a very slender woman with slight muscular development and slender bones; she had some scoliosis; her sclerotics were a deep blue colour, most marked in a zone about 7 mm. wide surrounding the cornea; irides were grey-brown with a few grey nodules at the pupillary margin suggestive of trouble of a tuberculous nature; she had formerly had a threatened attack of glaucoma with dimming of the right cornea, ocular tension raised to 35 mm. Hg, and vision reduced to $\frac{1}{10}$; the condition was relieved in two days through treatment by means of pilocarpine and eserine and had not recurred but there was now present a deep excavation of the disc; tension was now 26 mm. Hg. (Schiötz) for the right eye, 27 mm. Hg. for the left; R.V. with $-1{\cdot}5=\frac{5}{10}$, L.V. with $-1{\cdot}5=\frac{5}{7}$. II. 1 had good hearing up to the age of 10 years, after this it slowly diminished and now conversation was not possible; the tympanum of both sides was thickened and retracted. At the age of 42, II. 1 had a fracture of the femur from a slight cause; she was weakly and nervous and during the last two years had noticed a diminution of vision. The two affected sisters of II. 1 were not seen. No consanguinity recorded. Bibl. No. 139.

Fig. 633. *Aubineau's Case.* II. 5, Felix G., had always blue sclerotics but showed no other ocular anomaly, his fundi were normal and vision excellent; on commencing to walk at the age of 17 months he had a slight fall on a stair and fractured his femur; consolidation was difficult and the surgeon had to

operate; between 1913 and 1922 he had ten fractures of the lower limbs either following slight trauma or even spontaneously; his hearing was normal and viscera appeared to be normal; Wassermann test was negative. II. 5 had two elder brothers who were normal and two siblings had died young of meningitis.

Of the parents, the father was living and alcoholic, the mother had died aged 28 of phthisis. A sister of the mother, I. 3, had blue sclerotics and between the ages of 6 and 12 years had had five fractures from trivial causes. No consanguinity recorded. Bibl. No. 118.

Fig. 634. *Franke's Case II.* Blue sclerotics in a father and in four of his five children; the defect in the father, I. 1, was of medium severity and he had only once suffered from fracture, when at the age of 10 years he injured his skull after severe trauma; his father and grandfather were reported to have had normal sclerotics but there was some doubt about a great-grandfather.

II. 1, aged 10, had had eleven fractures of arms and legs without adequate cause; each injury had healed normally with only a slight amount of callus, the old fractures were scarcely visible by X-ray. Her brother, aged 9, was normal; three other brothers had died aged 9 months, 3 years, and 5 weeks respectively; they all had blue sclerotics but no fractures had occurred at the time of their death.

I. 1 and II. 1 both had a slight imperfection in hearing but there was no otosclerosis; calcium content of blood was raised in both. No consanguinity recorded. Bibl. No. 128.

Fig. 635. *Elewaut's Case.* Blue sclerotics in a soldier seen at the age of 23; the coloration was marked over the whole of the visible sclerotic; his father and paternal uncle were reported to have also had blue sclerotics; in other respects the eyes were normal; Wassermann test was negative. At the age of 4 years the patient had a fracture of the femur which only healed after two years in plaster; later he had repeated dislocation of the shoulder joints; at the age of 17 he had a fracture of the elbow from a slight cause. X-ray appearances suggested deficiency of calcium in the bones. No consanguinity recorded. Bibl. No. 127.

Fig. 636. *Franke's Case.* Blue sclerotics in two sisters with bone fragility in one of them; of the three brothers of the sibship the eldest was not seen, the second had blue eyes and white sclerotics, the third with brown eyes had also white sclerotics; of the parents, the mother with blue eyes and the father with brown eyes were both normal. No other cases of blue sclerotics or of bone fragility or of deafness had been known to occur in the family except in the case of the mother of I. 1, who late in life had twice within a short interval of time fractured her femur apparently without adequate cause.

I. 1 was a missionary in British India, and the mother, who was with him there, became ill with malaria in the first month of her pregnancy with II. 1; she did not improve on being sent to the mountains and so was sent to Germany, where II. 1 was born.

II. 1, aged 14, was small and delicate and mentally rather backward; her sclerotics are described as uniformly blue-grey from the corneal margin to the ocular equator, but she presented no other anomaly; vision = $\frac{6}{6}$ with − 2 D., tension of the eye was normal, hearing was normal and there was no haemophilia; at the age of 12 years she fractured her left femur from simply slipping on a stone; at the age of 13 she fractured her left humerus as she fell with outspread arms, and two months later she fractured the same humerus in a different place as she slipped and fell on her elbow.

The younger sister, II. 2, had blue sclerotics, more marked in degree of coloration than II. 1; she was of stronger bodily development and had no history of fractures. It should be noted that the elder sister had no fracture before the age of 12 and that we are not told the age of the younger sister. No consanguinity recorded. Bibl. No. 128.

Plate XLV. Fig. 637. *Freytag's Case.* Blue sclerotics associated with brittle bones in four generations. Only two cases were examined. V. 1, aged 20, A. W., had deep grey-blue sclerotics; in childhood he had three fractures; he had astigmatism of 1·5 D.; R. V. = L. V. = $\frac{6}{5}$; tension was 16 mm. Hg. (Schiötz) in both eyes; patient was very slender and delicately built with a markedly dolichocephalic skull; internal organs were normal, the spleen just palpable; teeth were normal. Examination of blood showed haemoglobin 84°/₀, red corpuscles 4,800,000, white cells 5—6000 with polynuclear neutrophiles 50°/₀, lymphocytes 40°/₀, mononuclears and transitionals 7°/₀, eosinophiles 2°/₀, mast cells 1°/₀; thus there was a relative lymphocytosis; no haemophilia; Wassermann test negative. X-rays showed the bones to be more slender than is normal but of a normal structure and normal calcium content; there was a marked extensibility of the capsules of the joints particularly of the interphalangeal joints and of the thumb; hearing was normal. The mother, IV. 2, had deep grey-blue sclerotics, vision was normal, ocular tension (Schiötz) was 17 mm. Hg. in left, 16 mm. in right; she was of small slender build with extensible ligaments as in her son; at the age of 12 she had a dislocation of the left patella and she had a fracture in 1919; normal hearing. Other cases as shown in the pedigree appear to be based upon reports but were not personally examined by the recorder. No consanguinity recorded. Bibl. No. 106.

Fig. 638. *Schwarz's Case.* Blue sclerotics in five males and five females of four generations. IV. 9, female, aged 23, was pushed in jest by a youth at a dance and fell to the ground, breaking her leg; she had deep blue sclerotics; at the age of 8 she had been knocked down by a cyclist and fractured her right femur; the injury healed rapidly and well; her first menstrual period was at the age of 19, since when it had recurred

every two months; she had markedly projecting frontal and occipital regions of the skull with ears turned outwards; hearing was good; vision was good and fundi normal; she had kyphoscoliosis; X-rays showed that the cortex of the long bones was markedly thin. IV. 9 had a twin brother who died soon after birth. IV. 7 and 8 had also blue sclerotics and the same form of skull with outstanding ears as their sister; they had very good teeth; IV. 8 had as a child within six months broken both femora; each time the injury healed quickly and well; IV. 7 had no fractures; he was married and had a child aged 6 months who was healthy and robust but had blue sclerotics. IV. 11 had normal sclerotics and no peculiarity in shape of skull. III. 2, 4 and 5 all had blue sclerotics and all had had one fracture; all had marked frontal and occipital projection of the skull with outstanding ears; III. 2 jumped from a chair as a child and fractured his femur; III. 4 fell as a child from a low tree and fractured his femur; III. 5 fell on the floor as a child and fractured her leg. The pedigree is given by the recorder as we have reproduced it but information is not given of other members of the family. Bone fragility in members of this family is evidently very slight if it is present at all. No consanguinity recorded. Bibl. No. 144.

Fig. 639. *Spurway's Case.* This pedigree illustrates the first published account of a history of fragility in bone associated with blue sclerotics: the recorder gives some account of the occurrence of fractures in individual cases but only makes a general statement with regard to the sclerotics; thus he writes, "the only other feature I have noticed common to many members of this family is a curious bluish tinge of the eyeball, which in some is very marked." So that we do not know that each case of fragility in bone had also blue sclerotics, though this would appear to be probable from an examination of other family histories in which the association occurs.

Of I. 2 and his brother I. 4 we are merely told that they both sustained fractures of ribs. I. 2 had two sons by different wives, of whom II. 3 had a fracture of his forearm and broke one femur twice; II. 2, T. C., aged 65 (1896), had repeated fractures before the age of 16 years; he fractured the right femur at $2\frac{1}{2}$ years, both forearms (radius and ulna) at the age of 5, both bones of the right leg at 7 and between this and the age of 16 he broke both bones of each leg twice; his left eye was gouged out by a cow some years ago but he was at 65 hale and hearty except for a slight twisting of one arm.

Of the three children of II. 2, two were affected; III. 1 fractured her leg when very young and died aged 5 years. III. 3 never suffered from fractures and had normal children in this respect. III. 4, J. C., had a history of repeated fractures; he had fractured both humeri, both forearms (radius and ulna), also both legs (tibia and fibula) and had once dislocated his elbow; of his six children only two escaped the defect, the other four having had seventeen fractures between them.

IV. 2, M. C., aged 16 (1896), had had a compound fracture of the right forearm, the radius and ulna were each broken in two places; twice she had fractured both bones of the left forearm, and the left humerus on another occasion was fractured in two places. IV. 3, H. C., aged 15 (1896), had had fractures of both femora, also a greenstick fracture of the humerus and a fracture of one of the phalanges of the third toe. IV. 4, aged 12, had only one fracture of the clavicle. IV. 5, E. C., aged 4, had had fractures of the right humerus, of both clavicles, of both forearms (radius and ulna in each case) and three greenstick fractures of the humerus and each femur; she was now under treatment for fracture of the left humerus. These four siblings also had "bruises and sprains without number"; the bones united promptly without trouble or deformity; in every case union was rapid and in the last case of E. C. the bone was quite firm on the fourth day; no bone had broken twice in the same place.

In other respects the family has been fairly healthy and shows no signs of other constitutional ailments. No consanguinity recorded. Bibl. No. 32.

Fig. 640. *Bolten's Case.* Family A. Blue sclerotics in seventeen members of four generations. II. 4, who herself had blue sclerotics, had eleven children, five sons and six daughters, who all had blue sclerotics, the anomaly being more marked in some cases than in others; these children were all very nervous; the eldest was aged 20 years and the youngest 6 months; one daughter was married and had two daughters aged 2 years and 8 months respectively; these two children also had blue sclerotics and the youngest was suffering from some eruption. II. 4 had two brothers who according to her statement had blue sclerotics; the recorder was unable to see them; she also had four mentally defective brothers and sisters. I. 1, the mother of II. 4, had blue sclerotics and came of a stock carrying a liability to mental defect. II. 5, husband to II. 4, was normal. There was no evidence of an associated bone fragility in any of the affected members; only one fracture had been known to occur in the family and that case was the result of a severe injury to one of the sons of I. 1; there was no history of associated haemophilia or congenital heart disease. III. 1, aged 18, had during the last year become deaf on the left side and a diagnosis of otosclerosis was made; his sclerotics were less blue than those of his siblings. III. 12, aged 7, was liable to fits which were diagnosed as hysterical though in the attacks she bit her tongue and had incontinence of urine. The anomaly was more marked in the females than in the males and its intensity was in no way related to colour of eyes or hair. There was some evidence of vasomotor and trophic disability in the affected members; they flushed and turned white readily, the skin of the hands was shiny and the teeth were irregular in shape and size. II. 4 was very nervous. No consanguinity recorded. Bibl. No. 121.

Fig. 641. *Shugrue, Rockwood and Anderson's Case.* Blue sclerotics in thirteen cases of four generations. II. 2 had blue sclerotics and had had two fractures but was not deaf; his two brothers were normal and one of them had seven normal children. The mother, I. 1, of this sibship had blue sclerotics and was not deaf but had had one fracture. II. 2 had eleven children of whom one son and two daughters had blue sclerotics, brittle bones and were deaf; one son had blue sclerotics but no associated defects; two children with blue sclerotics died in infancy and five children were normal. Three affected members of this sibship were married and had affected offspring as shown in the chart. No consanguinity recorded. Bibl. No. 148.

Fig. 642. *Berneaud's Case III.* I. 1, Frau Henriette T., had deep blue sclerotics and became deaf early in life; she had had four fractures all from trifling causes; thus she broke a femur in church whilst getting up from a kneeling position; she had three children all with blue sclerotics; II. 2 lost her teeth as a young girl and no secondary dentition came to fill their places; II. 3 had a history of three fractures; II. 4 had had three fractures—she broke a bone in her left hand whilst picking a plum from a tree. II. 2, the only married member of this sibship, had four children of whom III. 1 had spina bifida and died shortly after birth; III. 2 was normal; he had served for four years in the war and had had no fractures; III. 3 with white sclerotics had had two fractures at the age of 23; at the age of 24 she had lost two milk teeth which had not been replaced. III. 4 had had six fractures all from trivial causes; his sclerotics were only slightly bluish coloured; he had, at the age of 23, five milk teeth, seven milk teeth had fallen out in the last two years without others taking their place. No consanguinity recorded. Bibl. No. 135.

Fig. 643. *Rolleston's Case.* III. 1, aged 5 months, was admitted to hospital for nasal diphtheria, he was also suffering from congenital syphilis; both his sclerotics showed a uniform pale blue coloration which was thought to be more obvious on some days than on others; he had grey irides and an embryontoxon at the margin of each cornea. The mother, II. 2, aged 27 and of fair complexion, had sclerotics of a somewhat deeper blue more nearly approaching a leaden hue; arcus senilis was present in each eye. The mother's sister, II. 5, aged 16, had blue sclerotics and also her mother, I. 1; her two brothers, aged 37 and 22 years respectively, were not affected. When III. 1 was aged 3 weeks he had lost all power in his left arm but recovered in a month without specific treatment; whilst he was in hospital he again fractured his left arm and the author concludes that these fractures were more likely to be due to fragilitas ossium than to his specific disease, although there was no history of fractures in other members of the family. Three years later the recorder stated that this child had had two additional fractures. No consanguinity recorded. Bibl. No. 62.

Fig. 644. *Buchanan's Case.* This case is very incomplete as a family history, but great interest is attached to it from the fact that one of the affected members of the family, a boy aged $3\frac{1}{2}$ years, injured his eye which subsequently had to be excised and a histological examination was made: we are told that the eyeball was extraordinarily thin; that Bowman's membrane was absent and that there was a normal distribution of cell and fibre in the cornea but less of both than usual. Other authorities who have examined the sections are of the opinion that there is a distinct layer of Bowman's membrane present but that it is thinner than normal. The recorder states that the child's maternal grandfather, his uncle, his mother, his brother and his cousin are all affected in greater or less degree with blue sclerotics: several members of the family were seen and blueness of the sclerotics was a characteristic in all. The recorder kindly endeavoured to obtain more information for us with regard to the history but the family were uncommunicative; we have no knowledge as to whether the members had ever suffered from fractures or were deaf. No consanguinity recorded. Bibl. No. 122.

Fig. 645. *Morax's Case.* Blue sclerotics in three siblings and in their father. II. 3 had had numerous fractures of bones of the upper and lower extremities during adolescence; his eight siblings were normal. III. 1 had had a fracture a short time ago (1923) and had scoliosis. The grandparents, I. 1—4, were said to be normal. No consanguinity recorded. Bibl. No. 123.

Fig. 646. *Takahashi's Case.* Blue sclerotics in a father and in four of his seven children. I. 2 died aged 70; he was of short stature and in his youth had frequently suffered from fractures; he was not deaf and had normal white sclerotics. II. 2, aged 52, was short and had sclerotics of a definite grey-blue colour but not very markedly so; he had apparently shown evidence of slight bone fragility but was not deaf. III. 2, aged 20, complained of increasing visual disturbance; he had on three occasions, at the ages of 7, 11 and 14 years respectively, suffered from fractures following slight injury; he was short and ill nourished and his bony and muscular systems were slenderly developed; he was slightly deaf, probably otosclerosis; he had grey-blue sclerotics; refraction was myopic, 2·5 D. in right, 3 D. in left; R. V. = finger counting at 4 m., L. V. = finger counting at 3·5 m.; tension was 17 mm. Hg. in each and no exophthalmus was present; teeth and nails were badly developed; blood pressure 95 mm. Hg. III. 4, aged 13, was badly nourished, had a poor muscular development and slender bones; his teeth and nails were defective; sclerotics were grey-blue but less markedly so than in the case of III. 2; he had had no fracture; slight deafness was present; ocular tension was normal. III. 6, aged 11, was small and badly developed; teeth and nails were defective; blue sclerotics and deafness are noted; ocular tension was normal. III. 7, aged 7, had very

markedly blue sclerotics; she was not deaf and had had no fractures; ocular tension was normal. III. 1, aged 23, and III. 3, aged 18, were free from the anomaly. III. 5 died aged 3 years from an unknown cause; her parents say she had not blue sclerotics. No consanguinity recorded. Bibl. No. 131.

Fig. 647. *Colden's Case.* Blue sclerotics and brittle bones in a deaf female who had also widespread disease of the choroid and pigmentary degeneration of the retina; a nephew also had blue sclerotics; the parents were normal but two sisters of the mother were very deaf and saw very badly; the recorder was unable to obtain any information concerning the colour of the sclerotics in these two maternal aunts; four sisters and a brother of the patient, II. 7, had good vision and hearing, though one of the sisters had a son with blue sclerotics and a choroidal affection similar to that of his aunt.

II. 7 at the age of 12 years had had nine different fractures of arm, leg or collar-bone; two years ago she had fractured her finger; all the fractures had healed well and quickly; since the age of 20 she had noticed a gradually increasing deafness and diminution of vision; at first she only noticed a disability in the dark, but soon in the day also her orientation and ability to read became worse and worse. The patient was seen aged 28 (1921), when she is described as a small, slenderly built woman of considerable intelligence; she had kyphoscoliosis; irides were dark brown; sclerotics were markedly blue; pupils reacted normally and eye movements were normal; refraction was myopic; R.V. = finger counting at 1·5 m., L.V. = finger counting at 2 m. with some improvement if correction for myopic astigmatism were made; the visual fields showed peripheral contraction and also central scotomata; ophthalmoscopic examination showed an advanced choroiditis disseminata with central and peripheral cicatrised patches and pigmentary deposits; there was also a severe grade of sclerosis of the choroidal vessels. Bilateral complete deafness was present at this time, tests were made and the condition was said to be probably otosclerosis. Three years later II. 7 was again examined; internal organs were said to be normal; blood calcium was estimated at 9·6 mg. per 100 c.c.; the occurrence of spontaneous petechiae is noted; Wassermann test was negative.

The sclerotics of III. 1, aged $3\frac{1}{2}$ years, were not so markedly blue as those of his aunt and he had not yet had any fractures, but an examination of his fundus revealed the presence in him also of pigmentary deposits in the periphery and atrophic patches in the choroid; the condition was entirely free from signs of inflammation. No consanguinity recorded. Bibl. No. 136.

Fig. 648. *Hodgkinson's Case.* Blue sclerotics and fragility of bone in a father and in six of his eleven children. I. 2, aged 55 (1903), had dark sclerotics; he had had both legs broken below the knee from slight falls on three occasions, also a fracture involving one elbow joint; all fractures occurred before the age of 20 years. II. 1 had normal sclerotics and no fractures, sex not given. II. 2, Mrs B., had dark sclerotics; she had had six fractures at the ages of $1\frac{1}{2}$, 7, 8, 11, 14, and 20 years respectively, considerable deformity had been produced by the inaccurate apposition of fragments. II. 3, G. H., had dark sclerotics; he was known to have had one leg broken twice between the ages of 6 and 7 years, the other leg at the age of 19; at 22 years he broke one forearm, also a humerus; he was a jockey and had had other injuries the details of which were not known to his sister. II. 4, Alfred H., had normal sclerotics and no fractures. II. 5, Ada H., had dark sclerotics; she had had two fractures from slight injury at the ages of 4 and 7 years respectively. II. 6, 7, and 10 had normal sclerotics and no fractures. II. 8, Alice H., had dark sclerotics; she had had five fractures; at the ages of 6 months, 3 years, two at 4 years, and one at 14 years respectively. II. 9, William H., had dark sclerotics and had broken his right leg at 4 years. II. 11, John H., had dark sclerotics and had broken his leg twice. The mother of this sibship had normal sclerotics and had had no fractures. No consanguinity recorded. Bibl. No. 42.

Fig. 649. *Kaznelsohn's Case.* Blue sclerotics in five males of a sibship of eight; the father was similarly affected; the mother and three brothers had normal sclera and no history of fractures or of deafness. The father and two brothers suffered from bone fragility; II. 1 had had four fractures and one dislocation; two brothers were deaf; in II. 1 deafness was said to be due to otosclerosis. No consanguinity recorded. Bibl. No. 141.

Fig. 650. *Adam's Case.* Blue sclerotics and brittle bones in two brothers; no information is given of their parents but other members of the family are said to be normal. II. 1, aged 31, had twice broken a finger, once a foot and once an arm, a brother who also had blue sclerotics had had ten fractures. No consanguinity recorded. Bibl. No. 66.

Fig. 651. *Blencke's Case.* Blue sclerotics and brittle bones in a mother and her two children; the mother was deaf; her sister's daughter also had blue sclerotics and was deaf but did not suffer from bone fragility.

II. 1 and 2 had deep blue sclerotics and bones which were so brittle that the slightest cause led to fracture; they were now (1924) aged 7 and 3 years respectively and II. 1 had had three fractures of her leg; II. 2 had broken his collar-bone once, his femur twice and his legs six times; the fractures were followed by only slight formation of periosteal callus but consolidation was complete and a new fracture hardly ever occurred at the site of a previous one; pain was not slight in these cases; the children were small for their age and slender but in other respects were healthy. I. 2 had deep blue sclerotics and was deaf; in her

youth she had had eight fractures from slight causes, the first of which occurred at the age of 11 months and the last of which was at the age of 16 years; she had a dorsal scoliosis; she and her two children had good teeth.

II. 1 had had an operation for wry neck with good result. I. 2 said that on injury she was liable to severe bleeding and that on extraction of a tooth in her youth bleeding had been so severe that she had to be taken to hospital. No consanguinity recorded. Bibl. No. 126.

Fig. 652. *Eddowes's Case.* Blue sclerotics and brittle bones in father and daughter. II. 1 was noticed to have very dark sclerotics and reported that she had broken bones several times, on one occasion from merely falling on her bed; she said that her father also had eyes like hers and had had several fractures; he had lately broken an arm whilst putting on his coat. No consanguinity recorded. Bibl. No. 36.

Fig. 653. *Hofmann's Case.* Blue sclerotics in a mother and her son, her daughters were normal. II. 1, R. R., a tailor by trade, had deep blue sclerotics; he was under treatment for a fracture of the patella, and had earlier had a fracture of the left femur. No information is given of the number of his siblings, nor of the occurrence of fractures in the mother, nor of the hearing of I. 1 or II. 1. No consanguinity recorded. Bibl. No. 79.

Fig. 654. *Howell and Kinnear's Case.* Blue sclerotics and brittle bones in mother and daughter; no other members of the family were affected. I. 1 had had fractures of collar-bone, wrist, humerus, radius and ulna; she had had four fractures of the right arm, the first fracture at 1—2 years of age and the last fracture at 13½ years; blood examination showed 20 mgr. of calcium in 100 c.c. of blood. I. 2 was alive and well; these parents had one child with blue sclerotics who had had fractures as follows—at the age of one year in January 1921 fracture of radius and ulna (left), in July 1921 fracture of radius and ulna (left), in August 1922 fracture of tibia (right), in November 1922 fracture of radius and ulna (left), in July 1923 fracture of radius (right), and in August 1923 fracture of radius and ulna (left). She had been treated by splinting. Union took place in the normal time and alignment was good until the last fracture, when osteoclasis of both bones of the forearm was performed; X-ray before the correction of malunion showed excessive amount of external callus, X-ray after correction showed good alignment. She was given virol and calcium.

On November 5, 1923, height was 2 ft. 11 ins.; weight, 1 stone 13 lbs. 11 ozs.; the prominence of the occiput was rather more marked than usual, sutures were closed, there were no formation of nodes in the skull and no craniotabes. Fundi were normal. Teeth were very carious and worn; no anaemia; internal organs normal; urine showed no abnormal constituents; Wassermann test negative; 12 mgr. of calcium in 100 c.c. of blood was noted. No consanguinity recorded. Bibl. No. 133.

Fig. 655. *Rocher and Lasserre's Case.* II. 3, aged 13 months, had had an obstetrical fracture of each femur, she now had a fracture of the femur resulting from slight trauma; her sclerotics were "bleutées"; II. 2, aged 4 years, had had three fractures; the mother, I. 1, had had infantile paralysis and had had four fractures of diaphyses "au moment de la croissance." No consanguinity recorded. Bibl. No. 107.

Fig. 656. *Singer's Case.* Blue sclerotics in a female whose father and twin sister were also said to be affected. II. 1 was seen, aged 18; her mother said that after her birth she had noticed a softness of the skull; the fontanelles were wide open and the whole skull showed definite pulsation; the rest of the skeleton was not abnormally soft; in the first days of life the mother had been struck by her markedly blue sclerotics; growth was slow, the first tooth did not erupt until the age of 18 months and the child did not walk until the age of 2¼ years; a history of numerous fractures is given, the first two of which occurred at the age of 2 years, two more occurred at the age of 5, at 6 years the patient had a dislocation of the acromial end of the right clavicle and the last fracture was at the age of 14 years; the fractures were characterised by little pain and by their very rapid healing. The patient when seen was very small and slender and had a marked scoliosis in the lumbar region; her limbs were crooked; her sclerotics were markedly blue and there was some exophthalmos; hearing was normal. A number of measurements were taken and stature is given as 144 cm. X-ray photographs were taken and the report states that the whole skeleton showed a diffuse atrophy; the skull showed a marked occipital protuberance. No consanguinity recorded. Bibl. No. 124.

Fig. 657. *Salvetti's Case.* Blue sclerotics and brittle bones in a six years old child whose sister was similarly affected; the father had in childhood many fractures which had healed rapidly and without marked formation of callus. We have been unable to see the original account of this case and the abstract gives no further information and does not unfortunately state the colour of the sclerotics in the father. No consanguinity recorded. Bibl. No. 80.

Fig. 658. *Hofmann's Case.* Blue sclerotics and brittle bones in two brothers. II. 1, F. R., aged 31, a blacksmith, had blue-grey sclerotics; at the age of one year he had had a fracture of the right elbow and had had several fractures since; he had one brother with blue sclerotics who had fractured his left femur seven times and the right femur three times. No information is given of the parents or of the hearing of the brothers. No consanguinity recorded. Bibl. No. 79.

Plate XLVI. Fig. 659. *Usher's Case.* An isolated case of blue sclerotics in a very extensive pedigree of five generations. IV. 29, N. C., aged 10, who was adopted as a child, has dark brown hair, and complexion neither fair nor dark, stated to be an average scholar and to have had no illness, is quite robust, was breast fed in infancy; weight 54½ lbs., height 49 ins.; teeth well formed, no decay; large swelling on left frontal bone dating from birth and a small swelling on right frontal bone; a skiagram shows much thickening of the bone at this region; sella well formed; though there is no history of fractured bones a skiagram indicates that there has been a fracture of the shaft of the right femur. Eyes show a remarkable uniform slate-blue coloration of sclerotics; irides greenish and with a closer texture than usual, crypts and fibres are inconspicuous; fundus normal, no Fuchs' coloboma; cornea clear, no embryontoxon; pupils equal and contract to light; refraction, hypermetropic astigmatism; after atropine R.V. with + 4 D. in the meridian and + 5 D. in the opposite meridian = $\frac{6}{9}$, L.V. with + 5·5 D. in one meridian and + 7 D. in the opposite meridian = $\frac{6}{12}$. When seen again, three years later, there was no change in the blue colour of the sclerotics which seems to have been present at birth; it was noticed by her adoptive mother within a few weeks of birth.

III. 17, the mother, died eight months after the birth of IV. 29 and she, from her daughter's (IV. 30) account, was well aware of the curious blue-coloured eyes of IV. 29; the white of her own eyes was not replaced by blue. III. 17 married twice, by her first marriage with III. 18 she had two daughters, IV. 30 and IV. 32; IV. 30 had three sons V. 10—12; IV. 32 died in infancy. By her second marriage with III. 16, and it was also his second marriage, III. 17 had five children, IV. 26—29, of whom IV. 26, in the army, was abroad, IV. 28 died. III. 17 was an illegitimate child of II. 3 and II. 4, she had two full twin sisters, III. 22 and 23, also illegitimate, and a half-sister III. 26, also illegitimate, by the same mother, but a different father, namely II. 5. II. 4 married II. 6 and had three sons, III. 28—30. III. 16 married four times; by his first wife, III. 15, he had three children, IV. 23—25, of whom IV. 24 is alive and the other two died in infancy; his second wife III. 17 and family have already been mentioned; by his third wife, III. 19, he had no issue and only recently he married his fourth wife, III. 20. III. 26 married twice; by III. 25 she had three children, IV. 42—44, and by III. 27 a daughter, IV. 45. III. 22 died; by III. 21 she had four or five children who died in infancy and three sons, IV. 34—36. III. 23 had several children who died in infancy, two sons, IV. 37 and 38, who are dead, and a daughter, IV. 41. Of the family of II. 2 four are dead, namely III. 4, III. 8, III. 12 and III. 14; III. 4 married twice and had one child, IV. 2, by the first marriage, no issue from the second marriage. IV. 9 and 10 were twins, IV. 20 was epileptic, IV. 11 was killed in the war, IV. 13 and IV. 19 died, IV. 16 and IV. 21 and 22 are abroad, V. 4 and V. 5—9 are young children.

None of the relatives of IV. 29 seen by Usher showed any indication of blue sclerotics, and none of those spoken to had seen anyone with this condition; there was no good evidence of the presence of brittle bones in any member of the pedigree. No consanguinity. Hitherto unpublished.

Fig. 660. *Bolten's Case.* A single case of blue sclerotics and brittle bones in a pedigree presenting no fewer than eleven cases of cretinism. IV. 1, aged 3 years, had markedly blue sclerotics, but in other respects appeared to be normal at birth and robust; she was now of slender build and had a very fragile skeleton; she had fractured her left femur once, her left tibia twice and her right tibia once from slight accidents; she suffered from cold hands and feet and her teeth were not good; her hair was very thin and her nails showed trophic disturbances. III. 2, the mother of IV. 1, was rather nervous and her mother, II. 2, was more nervous, but otherwise there were no neuroses or psychoses to be found in this side of the family. III. 3, the father of IV. 1, aged 25, was healthy and not nervous, but he suffered from hyperacidity, had flat feet, teeth were bad, he complained of cold feet, and had a marked falling out of his hair; he belonged to a family of cretins, for all his six brothers and one of his four sisters were cretins; one normal sister, III. 13, had two cretinous sons. II. 6, the father of III. 3, aged 54, was normal and well developed, but he had a brother who was cretinous. I. 4 was normal, but her brother had a child who was a cretin. The patient, IV. 1, showed no signs of cretinism. No consanguinity recorded. Bibl. No. 94.

Fig. 661. *Van der Veer and Dickinson's Case.* Blue sclerotics in a brother and sister, the parents and five siblings were free from the defect. III. 5, aged 11, had slightly blue sclerotics and had had fourteen fractures, all were of the femora and mostly of the right femur; there was considerable bowing of these bones; the patient had talked at 1½ years of age and had walked at 3 years; the first fracture was at the age of 6 weeks when the child was being dressed by a relative who, on turning him over, heard a snap and the child cried; great care was taken from this time so that the second fracture did not occur until 1½ years later, but after this they became very frequent; he was now no taller than his sister aged 6 years; his teeth were poor and translucent and his gums were somewhat spongy; there were no signs of rickets, but the patient was pigeon breasted. The father was pigeon breasted, but well, also the mother, and all grandparents were free from the defect; four sisters, aged 16, 14, 11 and 6 and one brother, aged 9, were unaffected; one sister, aged 13, had blue sclerotics and bad teeth, but no fractures. No consanguinity recorded. Bibl. No. 108.

Fig. 662. *Duggan and Nanavati's Case.* Blue sclerotics in ten females and six males of three generations. I. 1 had blue sclerotics; her son, II. 2, was slightly affected, his three sons, III. 1—3, had normal eyes; the three daughters of I. 1 and all their children, III. 4—14, had blue sclerotics; no bone fragility, deafness, or congenital syphilis was associated with the anomaly in this family and all cases seen were free from errors of refraction, except one case, which was myopic. One member of the pedigree (?III. 12), a Mahomedan boy, aged 11, came to the Bombay Hospital to have his vision tested as his sight was poor; he had deep blue sclerotics, the greatest depth of colour being in a zone 1 cm. wide surrounding the limbus; he had a moderate degree of myopia; fundi were normal, irides brown. A female (?III. 13), aged 10, was seen with deep blue sclerotics and brown irides; a second female (?III. 14), aged 9, had pale blue sclerotics with scattered patches of a deeper tint, irides brown. II. 7 had a zone of deep blue sclerotic 0·5 to 1 cm. in width surrounding the limbus, the remaining sclerotic being light blue; she had dark brown irides; vision was good and fundi were normal. II. 8 had normal eyes. No consanguinity. Bibl. No. 147.

Fig. 663. *Terrien, Sainton and Veil's Case.* Blue sclerotics in six members of four generations. IV. 1, Cécile R., aged 12½ years, had a fracture of the left radius resulting from slight trauma; she was short in stature and her skull was prominent in the frontal regions; some slight kyphosis and genu valgum on the left side are noted; nails were not brittle, teeth were normal; all tendon reflexes were exaggerated; muscular development was good; some articular laxity was present; X-ray showed increased transparency of bones with thinning of the periosteum; R.V. = L.V. = 1; refraction emmetropic; eye movements, fundi and visual fields were normal; she had porcelain-blue sclerotics and ocular tension was perhaps slightly diminished; she was deaf. The mother, III. 2, aged 35, had some prominence in the frontal regions; she had slight genu valgum on the right side and slight kyphosis; nails were normal and teeth good; all tendon reflexes were exaggerated; X-ray showed a normal sella, the bones showed increased transparency and thinness of cortex, also signs were present of a fracture of the left tibia; R.V. = L.V. = 1; fundi were normal; sclerotics were of a marked porcelain-blue colour, ocular tension slightly raised; she was very deaf and had been so since the age of 25; she had a history of several fractures.

The maternal grandmother of III. 2 had blue sclerotics, but was not deaf and had no fractures; the mother, II. 1, had markedly blue sclerotics and was blind from glaucoma in both eyes; both eyes also showed cataract; she had no history of fracture and was not deaf. III. 2 had three brothers and two sisters, of whom one brother and one sister had blue sclerotics; the affected sister, III. 3, was deaf but had never had a fracture; the brother, III. 5, with blue sclerotics, had had three fractures without adequate cause. No consanguinity recorded. Bibl. No. 149.

Fig. 664. *Vallery-Radot and Aris's Case.* Blue sclerotics and brittle bones in two and probably three generations. III. 1, P. T., aged 2 years, had very blue sclerotics, and had had two fractures from slight causes at the ages of 21 and 22 months respectively, the left forearm and the right clavicle being the injured bones; the child was born at term, had been breast fed for 9 months and was in excellent general health; at 10 months he had seven teeth; he had a small ectopic left testicle. His mother, II. 1, aged 25, had normal sclerotics and no history of fractures; she had no miscarriages; the father, II. 2, was described by Broca and Herbinet in 1905 (Bibl. No. 43); he had been born at term, was breast fed for 3 months, cut his first tooth at 4 months and walked at 12 months; the child is said to have been well and precocious, and to have shown no trace of rickets; at 8 months he had a greenstick fracture of the right forearm which healed readily; at 2 years he fractured his right femur and 15 days later the left femur; further fractures occurred at 3½ years, at 4½ years and at 8 years, all from slight causes; we are also told that he had several sprains; at 28 years II. 2 was said to be in bad health; he was pale and emaciated and had had some lung trouble; his sclerotics were very blue.

I. 2 had paludism from living in the colonies; he had had three fractures which occurred simultaneously in some serious accident; he ultimately died from tubercular disease. I. 1 appears to have shown signs of rickets in infancy and to have had two fractures from slight causes at the age of 6 and 7 years respectively; she had a difficult pregnancy with ankylosis of the trunk before the birth of II. 2, but recovered, and later had a normal pregnancy; we are not told whether she had blue sclerotics and her history with regard to fragilitas ossium is rather obscured by the early signs of rickets. No consanguinity recorded. Bibl. Nos. 43, 132.

Fig. 665. *Wise's Case.* Charles W., aged 5, was seen with a fracture of his tibia from a slight cause; he was well nourished and fairly well developed, showing no sign of scurvy or rickets; his sclerotics were azure blue. The patient had two brothers with blue sclerotics and no history of fracture, also one sister with blue sclerotics and a history of a fractured forearm from what was probably not a trivial cause. The mother of this family had had five fractures from trivial causes and had blue sclerotics; her father, with the same defect in his eyes, had had fractures of a clavicle and a humerus after rather severe falls. The patient's leg united in the usual time without difficulty. No consanguinity recorded. Bibl. No. 98.

Fig. 666. *Kropp's Case.* Blue sclerotics in a mother and in two of her three daughters. I. 1, aged 59, had blue sclerotics; ten years ago she had had a fracture of her leg and within the last year had fractured her femur; she was completely deaf from otosclerosis, symptoms of which had first been noticed at about the

age of 30 years. II. 1, aged 27, had markedly blue sclerotics, over a zone about 5 to 6 mm. wide surrounding the cornea the posterior parts of the sclerotics were normal in colour; she had had eleven fractures and three dislocations and had shown signs of otosclerosis for about six years; she had some myopic astigmatism; bilateral embryontoxon was noted. II. 2, aged 22, had blue sclerotics which were less deep in colour than those of her sister; embryontoxon was present; she had had no fractures; two years ago she had had otitis media with perforation of the drum and since then had had bilateral difficulty in hearing; otosclerosis has now been diagnosed; she had a miscarriage two years ago and since this had had a daughter born with normal coloured sclerotics. II. 4, with white sclerotics, died aged 21 from pulmonary tuberculosis. No consanguinity recorded. Bibl. No. 143.

Fig. 667. *Bolton's Case.* Family B. Three cases of blue sclerotics in mother, daughter, and granddaughter. I. 2 had blue sclerotics; her sister, I. 3, and her nephew, II. 4, had fits but nothing was known of the nature of these fits. II. 2 had blue sclerotics; she was a slender female aged 28 and appeared to be anaemic; she had suffered from epileptic fits, in which she bit her tongue and had urinary incontinence, since the birth of her daughter four years ago; her teeth were carious and irregular; she suffered from cold hands with "dead" fingers. III. 1, aged 4 years, had blue sclerotics but was quite healthy in other respects. No fragilitas ossium was associated with the blue sclerotics of this family. No consanguinity recorded. Bibl. No. 121.

Fig. 668. *Wirth's Case.* Blue sclerotics in a father and two sons, possibly also in the grandfather and a daughter. I. 2 had had two fractures and was deaf, nothing further is reported of him. II. 2 had blue sclerotics and had a history of numerous fractures; he had embryontoxon and was demonstrated by means of the slit-lamp to have an abnormally thin cornea; he suffered from otosclerosis and was deaf; he had very prominent occipital bones.

III. 1, aged 16, had blue sclerotics and had suffered from numerous fractures; he was not deaf but had embryontoxon, also an abnormally thin cornea. III. 2, aged 9, had blue sclerotics but was not deaf and had had no fractures; he had embryontoxon, an abnormally thin cornea, very prominent frontal bones and the ligaments of the joints of his hands and fingers were abnormally lax. III. 3 died aged 2 years, she had had a fracture of the arm in her first year of life. No consanguinity recorded. Bibl. No. 134.

Fig. 669. *Scheel's Case.* Blue sclerotics and brittle bones in a mother and in her illegitimate daughter; the mother was seen aged 34 and unmarried; she was quite definite that all her seven siblings and her father and mother were free from the anomaly. II. 2 had blue-grey sclerotics; her eyes were normal in other respects, tension was normal, there was no embryontoxon; she had had five fractures from slight causes, the first occurring at the age of one year, the third and fourth at the age of 12; she was deaf and the condition was said to be typical of otosclerosis. III. 1, aged 5 years, also had blue sclerotics; she had had two fractures of which the first occurred at the age of $1\frac{1}{2}$ years; her hearing was not yet affected. No consanguinity recorded. Bibl. No 116.

Fig. 670. *Shugrue, Rockwood and Anderson's Case.* Blue sclerotics in four males and three females of three generations; in four cases there was an associated bone fragility and in three cases an associated deafness. III. 2 had deep blue sclerotics and had a syphilitic infection; at the age of 15 he fractured his elbow by bumping it against a barn door, he later fractured the other elbow by knocking it against his saddle whilst riding; two of his ribs had been fractured by a kick from a horse; a rock falling on to his leg fractured his ankle; he had fractured his collar-bone by falling from a wagon; on one occasion he had sprained his ankle; X-ray showed a lateral curvature with rotation of the lumbar spine; there were areas showing myositis ossificans in the muscles of the right thigh, also ununited fractures of both elbows. The mother, II. 3, reports that five of her nine children had blue sclerotics, III. 2 had a broken leg, III. 7 had had both arms and one leg broken, III. 8 and 9 were deaf. The father of this sibship had blue sclerotics, was deaf, and in his youth had a fracture of his leg which failed to unite and the leg was finally amputated. The paternal grandfather, I. 2, was said to have had blue sclerotics.

Only one member of this family appears to have been examined by the recorder. No consanguinity recorded. Bibl. No. 148.

Plate XLVII Fig. 671. *Ekman's Case.* This case is of historical interest as being the earliest published account of a history of hereditary fragility of bone; we are told that the family lived in Sweden and that through three generations dwarf growth associated with a peculiar delicacy and fragility of bone had led to gross deformity in its members. I. 1 is said to have had such distorted limbs that he was unable to walk; he had four children of whom the eldest, born 1702, was well in childhood but at the time of puberty lost all power in his arms and legs and was unable to work; he lived to the age of 73 and obtained a living by begging. II. 2, born 1703, was small and deformed and waddled like a duck. Nothing was known of the daughter II. 3. II. 4 was a dwarf with considerable deformity of arms and legs; he married a healthy woman and had a son III. 2, born 1726, who had experienced fractures from the slightest cause since earliest infancy; his limbs were considerably bent and he was unable to walk; he married however and had two children.

IV. 1, born 1760, was noted when scarcely a month old to have the bones of his arms and legs so soft that they bent or broke from the slightest cause, indeed he suffered from fractures three or four times in almost every year of his childhood. IV. 2, born 1765, had a fracture at the age of 8 days which occurred without the action of any discoverable cause; throughout childhood she suffered from fractures which followed the slightest causes. These two last cases are described by Ekman in considerable detail. No consanguinity recorded. Bibl. No. 6. We are indebted to the librarian of the University Library at Upsala for kindly lending us a copy of the paper from which these notes are taken.

Fig. 672. *Schmidt's Case.* Fragilitas ossium in a male and in two of his sons; three sons and two daughters were free from the defect.

II. 2, A. R., aged 69, had healthy parents and ten healthy siblings and in the whole family there had occurred no case of hereditary bone disease; he appeared to be healthy and robust at birth and his development was good during the first year of life; at the age of 2 years he slipped in the sitting-room and fractured his left femur in the middle of the shaft; he wore a splint for five weeks and the result was good, so that he could walk and run as before; at the end of this year he fell down a stair and again broke his left femur near the neck, and this time he had much pain and displacement of the fragments which resulted in a traumatic coxa vara with shortening of 3 cm.; walking was hampered after this and the disability and deformity increased during the following year; at the age of 6 he fell down and fractured his skull and there remains a depression of 5 mm., but it healed rapidly without serious symptoms; at 7 years he fell from a little stool and fractured his right humerus; the same year he broke his right collar-bone; after an interval of three years he fractured his right femur near the neck; at 13 years he fell on his hands and fractured both forearms near the wrist. He continued to have occasional fractures until the age of 19 years by which time he was only able to move with a crutch or stick and was unable to work; since this time he has had no further fractures; he is small and deformed but otherwise is in the best of health. II. 2 married and had seven children.

III. 2 was born without any difficulty but the midwife noticed in his first bath that he did not move his right leg and a fracture of the femur was found; the next day he was found to have a fracture of the left humerus; it was not known whether these fractures, which healed readily, were intrauterine or had occurred during birth or afterwards; at the age of one year, when he was making good progress in his attempts to walk, deformity in his legs was noticed and from this time he had almost every year repeated fractures so that at the age of 15 he had had six fractures of the right femur, five of the left, two fractures of the right humerus and two of the left; all fractures were treated by a surgeon and healed for the most part without gross deformity, but from the age of 6 years the patient was unable to walk without a crutch or stick; he continued to have fractures until the age of 18 when he became much improved after being bedridden for three years; he attributed the improvement to a vegetarian diet. III. 2 married and had two robust children free from any abnormality of the bones. III. 3 was also affected with the disease in a less severe degree; some curvature of the spine was noticed in the first year of his life and at the end of this year he fell from a little stool and fractured his left femur; he walked at the age of $1\frac{1}{2}$ years; he was nine years from this time without any fracture and then at the age of 10 he fractured his left femur through a fall on the cellar stairs and at 12 years again he fractured his left collar-bone; he married and had four sons and one daughter all of whom were healthy and free from the defect. The remaining five children of II. 2 and 3 were healthy; all were married and had healthy unaffected children. No consanguinity recorded. Bibl. No. 37.

Fig. 673. *Ormerod's Case.* I. 1 was a shoemaker with a stature of 5 ft. 10 ins.; he was a man of dissolute habits and died aged 55 from diabetes. I. 2, a hard-working industrious woman, died aged 93. Of their children, II. 1 and 3 died young; II. 2 died from flooding in child-bed; II. 4 died aged 36 from haemoptysis; II. 5 was drowned; after the birth of II. 6 the mother had some miscarriages and bore some children who died after a few days; none of the sibship who lived had the same affection as II. 6.

II. 6 was born with both arms broken and this was attributed to the father having kicked the mother during pregnancy, he was a fine child in other respects and up to middle age, in spite of deformities and an accident at the age of 26 by which he seems to have injured both thighs, he could walk and work without inconvenience; he married at the age of 30 and after this a gradual bending of his bones and sudden fractures occurred; at 40 he lost all his strength and his bones became so brittle that they broke from the slightest blow, on one occasion he had seven fractures at the same time; at 30 his stature was 5 ft. 3—4 ins., at death at the age of 68 his length in bed measured $39\frac{1}{2}$ ins.; his fractures were characterised by little pain and ready healing and there was no pain in the bones before fracture. The patient had a mind of considerable power but lived a profligate life and had a hasty and violent temper; he kept a low lodging-house, also an establishment for cockfighting. Of his four children, two survived for a few hours only; III. 3 died from small-pox at the age of 16, he had frequent fractures and was described in the neighbourhood as a "thorough-paced precocious little blackguard," but by his mother as a "singularly lively and sharp-witted child." III. 4 was also constantly breaking her bones and bore a similar character; she enlivened the company at public-houses by singing or jesting and grew up as deformed as her father;

she married and became pregnant several times but aborted early, until one occasion when this failed to occur Caesarean section was performed and she died; her twin children both died. The skeleton of II. 6 is now mounted at the Royal College of Surgeons (see Plate G), and the condition is established as one of osteopsathyrosis idiopathica. No consanguinity recorded. Bibl. No. 18.

Fig. 674. *Hester's Case.* A history of multiple fractures in four members of a sibship of six and in their maternal grandfather. III. 3 was seen aged 16 when she was suffering from a fracture of the right femur at the middle of the shaft which occurred after running upstairs and making a sudden turn at a bend; recovery was rapid and perfect; this was her third fracture, the other two had occurred in her left femur and in one of her legs respectively; the patient was of short stature though well developed; she had sandy hair and a florid complexion; menstruation was normal. III. 2 had had eight fractures of the lower extremities; she was married and had a child aged 5 –6 years who was apparently normal; III. 4 and 5 had had seven and three fractures of the lower extremities respectively; III. 6 represents two siblings who were normal. The parents were normal though the mother, said to have been healthy, had died of "fever." The maternal grandfather, I. 2, had had four or five fractures of his limbs and a number of fractures were said to have occurred in the family of one of his sisters. No consanguinity recorded. Bibl. No. 17.

Fig. 675. *Greenish's Case.* Fragility of bone in seven males and in one female of three generations; two other males had fractures from probably adequate causes. I. 1 is said to have been a cripple as a result of deformity produced by frequent fractures; he died from cancer and we are not told at what age his fractures occurred so have no means of judging whether his fractures may have been the result of secondary deposits in the bones; he had five children of whom II. 2 once fractured his thigh, II. 3 had two fractures, II. 5, 6 and 7 and their children never suffered from fractures; we are not told at what ages the fractures occurred in II. 2 and 3 nor are we given any information concerning the nature or severity of the accidents which led to them.

II. 2 had five children of whom III. 1 was seen aged 18 with an ununited fracture of the left femur; at the age of 12 he broke his right femur and some years later the fracture was repeated, in both accidents union occurred in the normal time; he had broken each forearm three times; when very young he broke his left femur which united and remained so until the age of 15 when it again broke and did not unite for a year; six months ago it was again broken and was still ununited; the boy had had no serious illnesses but was rather stout and flabby, he was pale and mentally very dull. Of the four siblings of III. 1 only one had suffered from fractures and he, III. 2, had an arm and a leg fractured at the same time in some severe machinery accident.

Of the children of II. 3, four sons and a daughter of a sibship of nine had repeated fractures from slight causes. Thus III. 6, R. G., aged 17, had a fracture of the left femur and was under treatment; at the age of 7 years he had broken his left femur; at 11 years and again at 14 he fractured his forearm. III. 7 had had four fractures; III. 8 had had four fractures and III. 9 had had eight fractures; one affected sister had had three fractures; four sisters, of whom only one was living, had had no fractures; we are not in these cases told the cause of death or the ages at which it occurred. Thus the history is rather incomplete and leaves one in doubt about the diagnosis of several cases. No consanguinity recorded. Bibl. No. 23.

Fig. 676. *Rebbeling's Case.* Fragilitas ossium in three males and one female of a sibship; the mother also was probably affected; four living sisters were free from the defect and four siblings had died aged a few months without having had any fractures; the grandparents, the father, and the siblings of both parents had so far as was known never suffered from fractures.

III. 9, Willy K., aged 9 years, had been noticed the day after his birth to have a fracture of the femur; the birth had been easy and had not required artificial aid; later he had fractures from the slightest cause, from pushing with his arms or legs against the table, from slipping or even from clumsy movements; he had had about 25 fractures and suffered severe pain though consolidation was rapid; he had had no other illnesses but was an ill-developed child for his age; his skeleton showed no signs of rickets; the legs were markedly bent and deformed; movements of the joints were free; the child was unable to walk, he was normal mentally but rather melancholy. III. 3, aged 18, was about the size of a healthy ten years old child; he had had about 30 fractures, the first of which dated from the first month of life, and he had never been able to walk; the last fracture had occurred a year ago and the one before this three years previously; there was much deformity of the legs and some limitation in the movements of the elbow joints. III. 4, aged 17, was similarly deformed and had also had about 30 fractures; he had a previous history of osteomyelitis; neither he nor III. 3 showed any signs of rickets; his first fracture occurred at the age of one year at a time when he was able to walk; he had had a fracture in this year (aged 17) and two fractures in the previous year, but for two years before this he had remained free. III. 2, aged 20 years, had had about ten fractures; she was small but was much better developed than her affected brothers; her first fracture was at the age of 2 years and the last was at 14 years.

The mother of the affected sibship, II. 3, had one fracture of the right arm in her youth and had many times dislocated her shoulder; a year ago she fell and fractured her right femur; it is rather doubtful whether the mother should be regarded from this history as an affected member and responsible for the defect in her children. No consanguinity recorded. Bibl. No. 39.

Fig. 677. *Pauli's Case.* A history of repeated fractures from inadequate causes in all the five members of a sibship; the father and grandfather were similarly affected; in other respects the family was healthy; no fractures occurred before the age of 8 years. Of the sibship III. 1—5 three members had had two fractures, one had had three and one had had five fractures. No consanguinity recorded. Bibl. No. 14.

Fig. 678. *Atherton's Case.* (Taken from Griffith.) A boy aged 13 years had on four occasions in seven months fractured his olecranon, twice on each side; there was a tendency in the family to fracture from slight causes; the patient's grandfather had had three or four fractures, and his grandmother (?paternal) had had very frequent fractures. The father, II. 2, had had at least six fractures and the patient's uncles (?paternal) had broken their bones. The patient had two sisters both of whom escaped the affection. No consanguinity recorded. Bibl. Nos. 28, 34.

Fig. 679. *Hunter's Case.* Fragility of bone in four members of a sibship of seven and in their father. II. 1 at the age of 9 years fell about seven feet and fractured his right femur; three years later he fell whilst sliding and fractured his right femur, two years later he fell at football and fractured his left femur and again two years later he was knocked down at football and fractured his right femur. II. 2 fell whilst playing eight years ago (1898) and broke her left femur. II. 3 "fell a few feet" and broke her right femur; she and her brother were in hospital at the same time and were dismissed together with their fractures completely united; on the way home she rested her back against a door which gave way and she fell, fracturing this time her left femur. II. 4 had a fracture of his right femur whilst playing; about two months later, on being lifted out of bed and placed on the floor, his foot caught the leg of a table and he broke his femur again at the same point. The remaining three members of this sibship, aged 15, 6 and 2 years respectively, had never had fractures and with the exception of the youngest appeared to be in good health.

The father of the sibship, now aged 50 (1898), had always had good health but had had four fractures of the right femur and three of the left; the first occurred at the age of 6 months and the last at the age of 41 years; he was about 4 feet 10 inches in height with marked disproportion between the lengths of body and limbs; there was some deformity with considerable shortening of both legs. A grandfather still living said that none of his relations had suffered from this defect. No consanguinity recorded. Bibl. No. 35.

Fig. 680. *Arnott's Case.* Fragility of bone in two sisters; two brothers and a sister, also the parents of the sibship and their families, were free from the defect. II. 1, E. M., aged 14, was under treatment for a fracture of her right femur following a fall; this was her thirty-first fracture, the bones affected were: right femur seven times, left femur six, right leg nine times, left leg once, right arm four times, left arm three and left forearm once; the first fracture was at the age of 3 years, and she had broken a bone by merely catching hold of a chair and sometimes in turning round suddenly; the bones united so readily that the mother had treated many fractures herself; there was some resulting deformity. There was said to be nothing peculiar in the appearance of E. M.; she had dark hair and eyelashes and bluish-grey irides. A sister aged 6 had had already nine fractures, the first of which occurred at 8 months. No consanguinity recorded. Bibl. No. 11.

Fig. 681. *Schmidt's Case VII.* I. 1 died from suicide; I. 2 was living and healthy; they had five children of whom two were still-born and two died in the first year of life, all were said by a physician to have the same abnormality in the development of their bones as in the case of II. 5, who was healthy when born, but after three months he suffered from repeated attacks of diarrhoea and vomiting and at 6 months broke his left forearm; from this time onwards he had repeated fractures from slight causes; he was now (1901) aged 5 years and his mother reported that his many fractures had healed rapidly and that the pain had been slight; the fractures had been treated carefully and the resulting deformity was slight. No consanguinity recorded. Bibl. No. 37.

Fig. 682. *Tillaye's Case.* I. 1, aged 75, had a fracture of the right radius at the age of 73. II. 1, aged 45, had fractures of the right femur at 2 months and at the age of 42 years. II. 2, aged 43, had a fracture of the right femur at 29 years. II. 3, aged 42, had a fracture of the left tibia at 20 years. II. 4, aged 42, fractured her left femur at 6 months and at the age of $2\frac{1}{2}$ years. II. 5, aged 36, fractured his left femur at 8 days, his right femur at $3\frac{1}{2}$ years, his left femur again at 6 years and his left clavicle at 8 years. II. 6, aged 34, at this age fell down and fractured the neck of her femur. II. 7, aged 32, fractured her right femur at one month, her left clavicle at 6 weeks, her left femur at 3 months and right femur at 13 years. The fractures in this family are all said to have occurred from insignificant causes but from the account given the only two cases suggestive of true bone fragility are those of II. 5 and 7. The case should be omitted from any statistical considerations. No consanguinity recorded. Bibl. No. 76.

Fig. 683. *Heaton's Case.* II. 4, aged 11 months, had a fracture of the left femur; whilst under treatment he had spontaneous fractures of the right femur and left humerus. The mother reported that after nursing the child she put him down quickly and heard a "crack"; since then he had been unable to move his leg. Of three other siblings the elder two, of whom one is a male, were healthy, but a sister had had a number of fractures occurring apparently spontaneously. No consanguinity recorded. Bibl. No. 41.

Fig. 684. *Lewy's Case.* I. 1 and 2 were two healthy parents; they had six children of whom the two eldest and the youngest were completely healthy and had never suffered from fractures; II. 3 and 4, aged 13 and 10 years respectively, each broke a femur twice whilst learning to walk but had no further fractures;

II. 5, Clara H., aged 5½ years, appeared from the description given by her parents to have had intrauterine fractures of the femur; her birth was normal but both femora were swollen and apparently broken; since then she had had nine fractures of the lower extremities, the tibiae were greatly curved and marked deformity was noted; the upper extremities had not been broken. No consanguinity recorded. Bibl. No. 65.

Fig. 685. *Pritchard's Case.* Fragilitas ossium in six members of two generations. II. 2, a well-developed boy, born on July 14, had two days later fractures of the left humerus and femur; there was no history of violence or accident; on July 17 the mother was moving the child in bed when his right arm caught in the bedclothes and she felt the bone snap; the right femur was fractured on August 4; there were no symptoms of rickets. The first child of the sibship, aged 2, was in good health and robust. The family history of the mother was good; the father was one of a sibship of eight, two of whom suffered from fractures in infancy; the only brother who was married was the father of four children the first of whom had a fracture of the arm, the third a fracture of the femur and the fourth a fracture of all four limbs which occurred spontaneously at or soon after birth. We are not told whether the father of this sibship was an affected or an unaffected brother of I. 2. No consanguinity recorded. Bibl. No. 24.

Fig. 686. *Schmidt's Cases IV and V.* Two cases of fragilitas ossium in a sibship of twelve; seven males and two females of the sibship died with convulsions at the ages of 14 days, 4 weeks, 2 months or up to 3 years; one sister, aged 14, was healthy and well developed; the parents were healthy and no inheritable disease or nerve disease had been known to occur in the family. II. 3 was normal at birth and developed well during the first month, after which time frequent convulsions and diarrhoea occurred, nevertheless he walked at the normal time; at the age of 1½ years he had the first fracture of his right leg and from this time he had repeated fractures at longer or shorter intervals from trifling causes so that at the age of 17 years he had broken his legs about forty times, the humerus once and the right collar-bone once; the pain of the fractures was usually slight and consolidation usually occurred in a short time, but the resulting deformity was so great that the patient had been unable to walk for some years; he was intelligent and in other respects his development appeared to be normal; the deformity was so gross that a double amputation was performed but the patient was still, at the age of 18, breaking his arms and other bones from very slight causes. The amputated bones were said to have an extremely thin cortex with very wide-meshed spongiosa. Photographs are given showing the youth before and after amputation, also his brother, II. 5, with and without bandages. (See Plate D.) II. 5 was normal at birth but his development during infancy was impeded by many attacks of diarrhoea and convulsions; at 2 years of age he broke his right collar-bone, three months later his right femur and shortly after this he fractured his right tibia by treading on a stone; he continued to have repeated fractures of his upper and lower limbs until now (1901), at the age of 8 years, he was unable to stand without bandages; he had a very marked deformity of both femora in the upper third, also a severe lordosis; his head was large, fontanelles were closed, teeth were healthy. No consanguinity recorded. Bibl. No. 37.

Fig. 687. *Schwarz's Case III.* Two parents who were healthy and had had no fractures had five children of whom II. 1, aged 20, had had eight fractures in the last eight years, all following slight trauma. II. 2 had had five fractures following slight trauma. All the injuries had healed quickly and well. Two brothers and a sister were healthy; no members of the family had blue sclerotics. No consanguinity recorded. Bibl. No. 144.

Fig. 688. *Moreau's Case.* Fragility of bone in two sisters; their only other sibling, a brother, was still-born. I. 2 died aged 59; he was not alcoholic, but 5 years before his death he became suddenly melancholic and ideas of persecution haunted him from this time; ultimately he had to be taken to an asylum where he became paralysed and died; by his first wife he had three normal and healthy children; by his second wife he had three children, of whom II. 2 was still-born. II. 3, aged 12, had had no serious illness; she was breast fed in infancy; at the age of 5 she fractured her left leg for the first time; she was pushed on a small bank at school by one of her friends and fell; she was six weeks in hospital and her left leg remained shorter than the other; at the age of 6 a new fracture in the same place followed a similar history and she was five weeks in hospital; at 6½ years she slipped and fell in the street and had a third fracture at the same place; at 7 years of age she slipped and fell and broke her left arm; she recovered its use in three weeks with no resulting deformity; at 8 years she had her fifth fracture in the region of the knee and was a month in hospital; at 9 years of age she fell whilst running to school, was in hospital again for six weeks and the fractured leg grew very deformed; at the age of 10 her seventh fracture occurred in the right leg and this time consolidation was very difficult and necessitated five months' treatment. II. 3 was said to be in good health, and excepting the deformities in her leg her state left nothing to be desired. II. 4, aged 9 years, had been born at term and was breast fed in infancy; she had apparently some acute illness at this time; at the age of 5 years she fractured her right leg and commenced to walk on it after a month; at 5½ years she slipped on her way to school and fractured her left leg; she was six weeks in hospital; at 6 years she slipped in the street and had a fracture in the region of her shoulder which healed in 25 days; in the same year she slipped again and fractured her left leg in the same place as before;

five weeks' treatment was required; at 7 years she broke her arm and while she was still in hospital she broke both legs; later this year she had her eighth fracture which occurred in her leg whilst bathing; at the age of 9 years she broke both legs.

Both sisters walked at the usual age, they showed no symptoms of rickets and there was no curvature of the bones before they were fractured; teeth were normal; skulls were normal and there were no signs of syphilis. Their mother, I. 3, by a former husband who died from phthisis, had two children aged 18 and 15 years respectively who were healthy and had no fractures. The recorder suggests that the mental defect in the father may be of some etiological significance in the light of the fact that fragility of bone does occur in association with certain diseases of the central nervous system. Further news of the two affected sisters was published in 1905 (Bibl. No. 43). They were now aged 23 and 21 years respectively; during the interval the elder sister had had one fracture, at the age of 16, the younger sister had had two fractures at the ages of 11 and 13 years respectively. No consanguinity recorded. Bibl. No. 30.

Fig. 689. *Strack's Case.* Three brothers, the only children of their parents, had eight fractures of arms or legs between the ages of $1\frac{1}{2}$ and 6 to 7 years; all the fractures followed trifling causes and helaed rapidly in four or five weeks; the parents were not affected. No consanguinity recorded. Bibl. No. 9.

Fig. 690. *Matsuoka's Case.* Fragilitas ossium in two sisters; parents were unaffected. II. 2, a Japanese girl, aged 6 years, was weakly at birth; she first learnt to walk at the age of 4 and in this year she fell to the ground and suffered her first fracture of the right femur which healed in a month; shortly after she fractured the left femur; at the ages of 5 and 6 years she had six fractures of the femur; each time she complained of pain; consolidation occurred in about three weeks and the fractures followed very slight causes; X-ray revealed that the child had had 18 fractures and no long bone had remained unbroken except the left radius. The bones were slender, skull rather large, thorax deformed, spine curved and pelvis deformed; the long bones were curved. The mother said that her first child also was affected. No consanguinity recorded. Bibl. No. 55.

Fig. 691. *Axhausen's Case.* I. 2 had in her childhood had four fractures from slight causes; her sister had in her childhood also broken her limbs four times without severe injury and the resulting deformity had become so great that she could only walk with crutches. II. 1 in his early youth had had fractured bones from the slightest causes, he had had at least twenty fractures and his deformity was so great that he was in a helpless state at the time of his death at the age of 21 years; his sister, II. 2, was also affected. No consanguinity recorded. Bibl. No. 51.

Fig. 692. *de Cortes' Case.* A tendency to fracture from slight causes in six males and one female of four generations. I. 1 was known to have had three fractures; no information is given of the age at which they occurred or of the accidents which led to them. II. 2 had five fractures, all of the lower extremities and towards the age of 40 years; his sister, II. 3, fractured the upper part of her femur at the age of about 30 years. III. 2 had a fracture of the forearm when he was of adult age; the recorder was of the opinion that the origin, symptoms and course of the accident all indicated that the case was osteopsathyrotic in character. IV. 2, aged 30, IV. 3, aged 28 and IV. 7, aged 17, were healthy and had had no fractures. IV. 4 had, between the ages of 17 and 24 years, five fractures following trifling causes, two were of the right femur, one of the left femur and one of the shoulder blade; he was now aged 27 and had had no fractures for three years; he showed some signs of rickets. IV. 5 began to show signs of paralysis at the age of 6 years, progress of the disease was so rapid that after 4 or 5 years he was completely paralysed; at the age of 22 he had two fractures following from slight causes; now aged 25 his sphincters were incompetent, extremities were atrophic, flabby and almost without sensation and the patient is described as a case of progressive muscular dystrophy. IV. 6 died young, the cause was unknown; he had not in childhood shown any signs of osteopsathyrosis.

IV. 9 cut his first teeth at 6 or 7 months of age, he walked at $2\frac{1}{2}$ years; at the age of 4 years he fell and fractured his left leg, healing was rapid; the same fracture was repeated in this year and again at the ages of 5, 6, twice at the age of 8, twice at the age of 10, at 11 years and again at 13 years; the right femur was fractured at the age of 11 years, at 11—12 years and at the age of 12 years; all resulted from trifling causes; the skull of this boy was markedly bossed, his lower jaw was large and projecting, epiphyses were slightly thickened, the long bones were flattened and deformed and there was marked flattening with bending of the left tibia.

The late onset of the tendency to fracture and the signs of rickets in other members of this family make the classification of the case rather doubtful. No consanguinity recorded. Bibl. No. 60.

Fig. 693. *Willard's Case.* Seven or possibly eleven cases of fragilitas ossium in three generations. II. 2 was a small spare man who had had three fractures of the rib and clavicle all from direct and decided violence; we are given no details of these accidents nor the age at which they occurred, and II. 2 should probably not be classed as a case of fragilitas ossium; his wife was large and corpulent and extremely hysterical; there is no history of a tendency to fracture in the ancestry of either of them and there were no signs of syphilis; their children were all puny, some of them almost dwarfs, and they had notched teeth, but they rarely suffered from serious illness; only one of the ten escaped fractures.

III. 1, aged 18, was 4 feet in height; at the age of one year she fell down one step and fractured the upper third of her left femur; at $2\frac{1}{2}$ years she tripped on the carpet and fractured the same bone in the same place; at 3 years she slipped on the oilcloth and again repeated the experience; at 4 years, jumping from a low stool, she again fractured her left femur in the upper third; at 7 years she slipped on the ice and repeated the fracture; at $7\frac{1}{2}$ years she turned suddenly and the callus snapped; at 9 years she fell down two steps and the same fracture recurred; at 12 years she tripped on a carpet and fractured the right femur in the upper third; on one occasion she fell downstairs and fractured the left clavicle without any other injury; no fractures had now occurred for six years but she walked with difficulty owing to deformity from the repeated fractures. III. 3 had fractured the right femur in the upper third on three occasions, at the age of 4 years she turned suddenly and screamed before she fell, at 7 years she tripped on the carpet and at 16 years the accident followed a fall on the ice; further, she fractured her left clavicle at 6 years in falling from a chair, and falling backwards on the floor at the age of 12 she again fractured her left clavicle. III. 4 fractured her right femur in the upper third on three occasions, the first time was at 8 weeks of age, the second time was at 15 months when she slipped on orange peel and the third time was at 22 months when she fell down one step; further, she dislocated her shoulder at 5 years; at the age of 15 she was burned over nearly a third of the surface of her body but survived. III. 5 had had four fractures; at the age of 2 years he fell about 8 inches and fractured the upper third of his right femur; at 8 years he was knocked down in the street and the same fracture was repeated; twice at the age of 3 years he fell from the top of a sewing machine and fractured, the first time his right clavicle and the second time a right rib. III. 6 had the left clavicle fractured at birth though it was an easy labour; the same bone was broken at 13 months when she fell from a stool. III. 7 had the right clavicle fractured at the age of one week. III. 8 had the left clavicle fractured at birth during an easy labour. III. 9 fell from a bed at the age of 3 weeks and fractured the left clavicle. III. 10 fell downstairs at 7 years of age and fractured a rib. Only one child of this sibship had had no fracture; she was the strongest and most robustly built of the family and had two normal children.

One child of an affected female had the femur fractured whilst being turned in bed at the age of 4 weeks; at 9 months the fracture was repeated from some trifling cause. This history is unusual in several respects and it appears to us doubtful whether the cases described belong to the condition with which we are dealing; certainly III. 10, who fell downstairs and fractured a rib only, cannot be described as a case of fragilitas ossium, and the repeated fractures at the same place in III. 1, 3, 4, 5 and 6 all suggest a perhaps local weakness with inability to bring about a normal repair rather than a generalised fragility of bone; we are told that in the case of the femur the new line of fracture was nearly always through the old callus. The case is interesting but should probably be excluded from any statistical investigation. No consanguinity recorded. Bibl. No. 26.

Fig. 694. *Agnew's Case.* This case is very imperfectly reported but the account states that a child aged 5 years was under treatment "for a fracture of the tibia and fibula, caused in the usual gambols of play, whose father and grandmother had each been the subject of several similar injuries." No consanguinity recorded. Bibl. No. 21.

Fig. 695. *Graham's Case.* III. 1, aged about 33; had had 18 fractures, the first occurring at the age of $1\frac{1}{2}$ years and the last at 18 years; fourteen of the fractures occurred before the age of 9 years and he (or she) had now had a period of 14 or 15 years without an accident; the right arm had been broken nine times, the left arm twice, the left leg three times, the right leg twice and each collar-bone once; the father, II. 3, is said to have broken his bones fourteen times; a cousin of II. 3 is said to have had twenty-one fractures and to have suffered in this way after he was quite an old man. A paternal uncle of II. 3 was also a "bone-breaker." This history is very incomplete and unsatisfactory in that all information is derived from a letter written by III. 1. No consanguinity recorded. Bibl. No. 25.

Fig. 696. *Dent's Case.* II. 1, a male, aged 29 (1897), is a case of very gross deformity resulting from fragilitas ossium; he was apparently normal and healthy at birth and at the age of 4 months had his first fracture of the right femur whilst being nursed; he had never been able to walk and had fractured his tibia 18 times, his right femur once, left femur twice, left arm four times and left clavicle twice; the bones of his right arm had never been broken; he had scoliosis. The parents were both healthy; his sister and a cousin had scoliosis; a cousin had a cleft palate and another cousin suffered from the same condition as II. 1. The patient was intelligent but had become deaf during the last three years. No information is given of his sclerotics. No consanguinity recorded. Bibl. No. 33. See Plates C and H.

Fig. 697. *Cox's Case.* (Taken from Griffith.) A girl aged 18 years had never been able to walk presumably on account of early fractures; her lower extremities were greatly deformed and she had had seven fractures of which five were of the femur. The brother, II. 2, aged 13, had never been able to walk but it is not stated whether he had a history of repeated fractures; the father and several of his brothers had bones which were easily broken. No consanguinity recorded. Bibl. Nos. 22, 34.

Fig. 698. *Goddard's Case.* On September 27th, 1832, Martin S., II. 1, aged 3 years, fell from a step six inches high and fractured his femur; his mother stated that he had twice before fractured this bone

from very trifling causes; at the age of 4 years Martin fell from his chair and fractured both bones of the forearm; in the same year he fractured his left ulna as a result of a slight accident, and falling down two stairs he broke the humerus, radius and tibia of the right side; by the time he was aged 13 he had had fourteen fractures. The mother, I. 3, had had one fracture of the right femur and five fractures of the left and her brother at the age of 13 had suffered from two fractures of one femur, nine of the other and also two fractures of the arm; further he had had a dislocated hip; some deformity was the result of all these accidents. These affected members are said to have been of very short stature and to have had small bones. No consanguinity recorded. Bibl. No. 13.

Fig. 699. *Hartmann's Case.* Fragilitas ossium in two siblings; the parents and six other siblings were free from the defect. II. 1, Marie B., aged 21 (1911), fell whilst walking at the age of 1½ years and broke her femur; the other femur was broken almost before the first fracture was healed; she further had a fracture of her left leg at 5 years and twice again broke her leg before the age of 8; after this she had a period of ten years free from fractures, but again at 18 she fell suddenly whilst walking in the street and fractured her right femur; at 21 years she broke her left femur; she was well nourished but had a dwarfed stature; her first tooth had been cut at the normal time, her first menstrual period was at the age of 19, since when it had recurred every four weeks. II. 2, Franz B., aged 19 (1911), had always been healthy and it was not until the age of 17 years that he had his first fracture undoubtedly due to fragility of bone, though he had had one fracture of the left forearm at the age of 11; since this time he had had repeated fractures from slight causes and had broken his right femur four times, his left femur six times; he was still having fractures at 19. No consanguinity recorded. Bibl. No. 61.

Fig. 700. *Bronson's Case.* Osteogenesis imperfecta not associated with blue sclerotics in a female aged 3 years 10 months and in her father; a brother aged 8 had had no fractures; the grandfather (? paternal) was reported to be quite normal. No history of blue sclerotics or otosclerosis could be obtained. The patient had a broken clavicle and right humerus at birth and the mother says she has had fifteen fractures in all; most of these have been untreated with the result of extreme deformity of the long bones; there is considerable hypotonia of the joints; the head shows bilateral and frontal enlargement but no occipital prominence. The father, I. 1, had thirty fractures of which the first was in infancy, he was unable to get about except in a wheeled chair; he had recently died aged 29 years from influenza. No consanguinity recorded. Bibl. No. 95.

Fig. 701. *Jones's Case.* A male mulatto, aged 24, had suffered about fifty fractures since the age of 3 years; his legs and thighs were much deformed and the fractures were characterised by very little pain and rapid repair; his health in other respects was good. A female first cousin of the patient was stated to have suffered in the same way. No consanguinity recorded. Bibl. No. 20.

Fig. 702. *Burns's Case.* Fragilitas ossium in five males of a sibship in which two brothers and four sisters were free from the defect; the father and his sister's three sons were also affected. II. 6, J. W., aged 35 (1921), was second born in a sibship of eleven; he had been brought up on a farm until the age of 14 and had never taken an active part in athletics; he was now unable to get about owing to an ununited fracture of the right femur of 19 years standing; his mentality was good and he had always been healthy and free from the ordinary diseases of childhood; at the age of 10 II. 6 "fell off a building" and fractured his right humerus; the arm was in a sling for three weeks and he was able to use it well in six weeks; five years later he fell off a toboggan and fractured the left femur at junction of upper and middle third, four months later he was able to do manual labour and had no disability other than a slight stiffness of the knee; one year later, at the age of 16, he fell whilst skating and fractured the right femur in the upper third, this fracture is still ununited in spite of operative and other surgical treatment; at the age of 34 he fractured the surgical neck of the right humerus and experienced considerable loss of function. Concerning the fractures of his brothers the patient said, "I can't tell you off-hand how many, but all of them are worse off than I am."

II. 5 had fractured both femora two or three times, also his right arm; he had been an invalid for 12 years as a result of ununited fractures of both femora; his fractures commenced at the age of 8—10 years. II. 7 fractured his left femur twelve years ago (1909) and it was still ununited, a bone graft was done several years ago without result; in 1901, when he was probably aged about 13, he fractured his right arm which united; he now gets about on crutches. II. 8 has never had any fractures. II. 9, a robust fellow, worked on a telephone repair gang and had several falls but never a fracture. II. 10 had had at least five or six fractures all of which had united except the last fracture of the femur 5 years ago which had not firmly united (probably fibrous union), and the patient was very lame but got about with the support of a leg splint. II. 11, aged 21 (1921), had had at least eight fractures, both femora had fractures which failed to unite and he got about in a wheel chair. The brothers of this sibship who are married had sons who were all too young yet to expect trouble, but the normal sisters who are married had sons who had had fractures.

The father of this sibship, aged now 60 years, has had three fractures; 18 years ago he fractured his right femur and all endeavours to induce union failed; the thigh was eventually amputated; previous to this he

had had fractures of the tibia and fibula which had united; he was well except for the disabitity from fracture he had three sisters who had never suffered from fracture, one of them has three sons all of whom have a tendency to fracture; another sister has a family of girls none of whom has ever had broken bones. Flesh wounds in the affected members heal normally. The mother, I. 7, aged 60, was alive and well; she had once had a fracture as the result of falling on a galvanised pail; she had had no miscarriages. The patient's Wassermann test was negative and the only brother who had had venereal disease was one of the two who had never suffered from fractures. A rather unusual feature of this history is the relatively late age at which fractures started to occur and their frequent failure to unite. No consanguinity recorded. Bibl. No. 104.

Fig. 703. *Fairbank's Case*[1]. Blue sclerotics in all the four children of a man who was himself affected and whose father also had blue sclerotics. III. 3 and 4, twins aged 7 years, were both under Mr Fairbank's care, to whom we are indebted for notes concerning them. III. 3 broke her leg at the age of 2 years and again at the age of 4; she had "twisted her knee" on several occasions and broke one arm three years ago; fractures were said to occur from slight falls; she had bilateral knock knee, also marked hyperextension of the knees due to backward bending of the tibiae in the upper third; slight dorsi-lumbar curve is noted; the left forearm was bowed as a result of fracture; central permanent upper incisors were definitely translucent but much more calcified than the lower incisors; fronto-parietal and temporal regions were prominent and sclerotics blue; operation was performed for correction of deformity and the bone was said to be quite soft. III. 4 had broken her right leg nine times and the tibia was bent as a result; the last fracture had

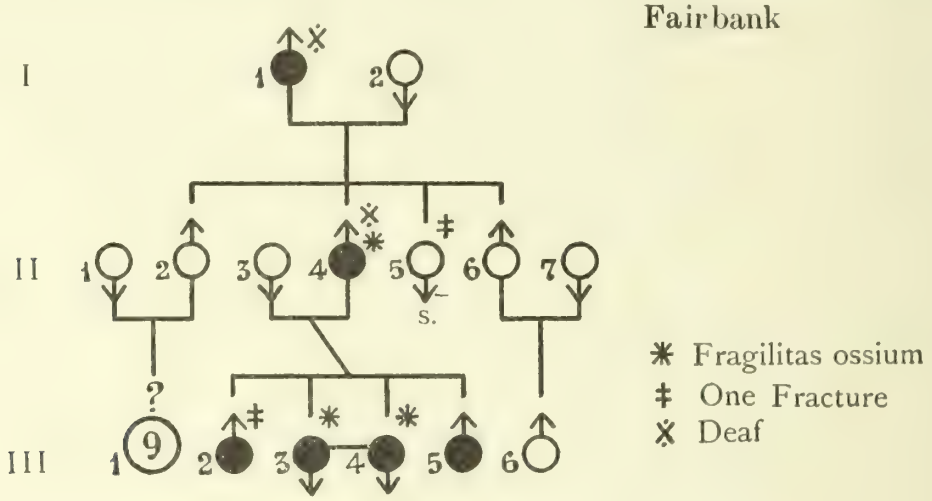

Fig. 703.

occurred a year ago; she was poorly in health and suffered from headaches; the right femur was bowed anteriorly and outwards below the great trochanter; the right tibia was bowed forwards and outwards; the spine showed a left dorsal and right lumbar curve; teeth were markedly grey and transparent especially the lower incisors; operation on the right tibia was performed and the bone was said to be soft and porous; sclerotics were blue. The two brothers of the twins, aged 9 years and 18 months respectively, are not affected with osteogenesis imperfecta and appear to be healthy but III. 2 is said by his father to have very blue sclerotics and III. 5 to have slightly blue sclerotics. III. 2 had a history of a fractured arm which was caused by a grown person falling on him at about the age of 6 years but no further accidents had occurred.

II. 4 has very blue sclerotics and has a history of numerous fractures the first of which occurred when he was about 5 or 6 years of age, both femora were then broken; after this he broke them again several times until he was aged about 13; apparently no further accident occurred until he was aged about 30 when he had a "heavy fall" from his cycle and broke his left ankle; ten years later, in January 1927, he slipped on some stairs and fractured his left tibia which has not yet (December 1927) healed satisfactorily; he says that this tibia has always had a pronounced forward curvature; hearing was good until 12 months ago and he now complains of slight deafness in his right ear. II. 2, a sergeant-major in the army, has white sclerotics and is healthy; he has nine normal and healthy children. II. 5 has normal sclerotics; she had on one occasion a fractured wrist which occurred in a street accident. II. 6 and his son are healthy and have white sclerotics. I. 1 is said to have had blue sclerotics and to have been very deaf; he died when II. 4 was young. No consanguinity recorded. Hitherto unpublished.

[1] Notes of this case were received after the Pedigree Plates had gone to the lithographer.

Showing blue sclerotics.

Showing deformities.

W. T. S.

OSTEOGENESIS IMPERFECTA, DR. DONALD HUNTER'S CASE.

(By kind permission of Dr. Hunter and the Proprietors of 'The Lancet.')

Adlard & Son, Limited, Impr.

ue, Rockwood and Anderson's Case. Repeated fractures, blue sclerotics, occipital protuberance, and temporal enlargements. By kind permission of the Proprietors of the *Archives of Internal Medicine.* (See Bibl. No. 148.)

Fig. i.

Haward's Case of *Fragilitas ossium.* By kind permission of the Royal Society of Medicine. (See Bibl. No. 38.)

Fig. ii.

Dent's Case of *Fragilitas ossium.* By kind permission of the Medical Society of London. (See II. 1 in Fig. 696.)

Subject 1. Subject 2.

Osteogenesis imperfecta. Oskar Schmidt's Case of two brothers. Left, elder brother before and after amputation. Right, younger brother without and with bandages. (See Fig. 686, II. 3 and II. 5.)

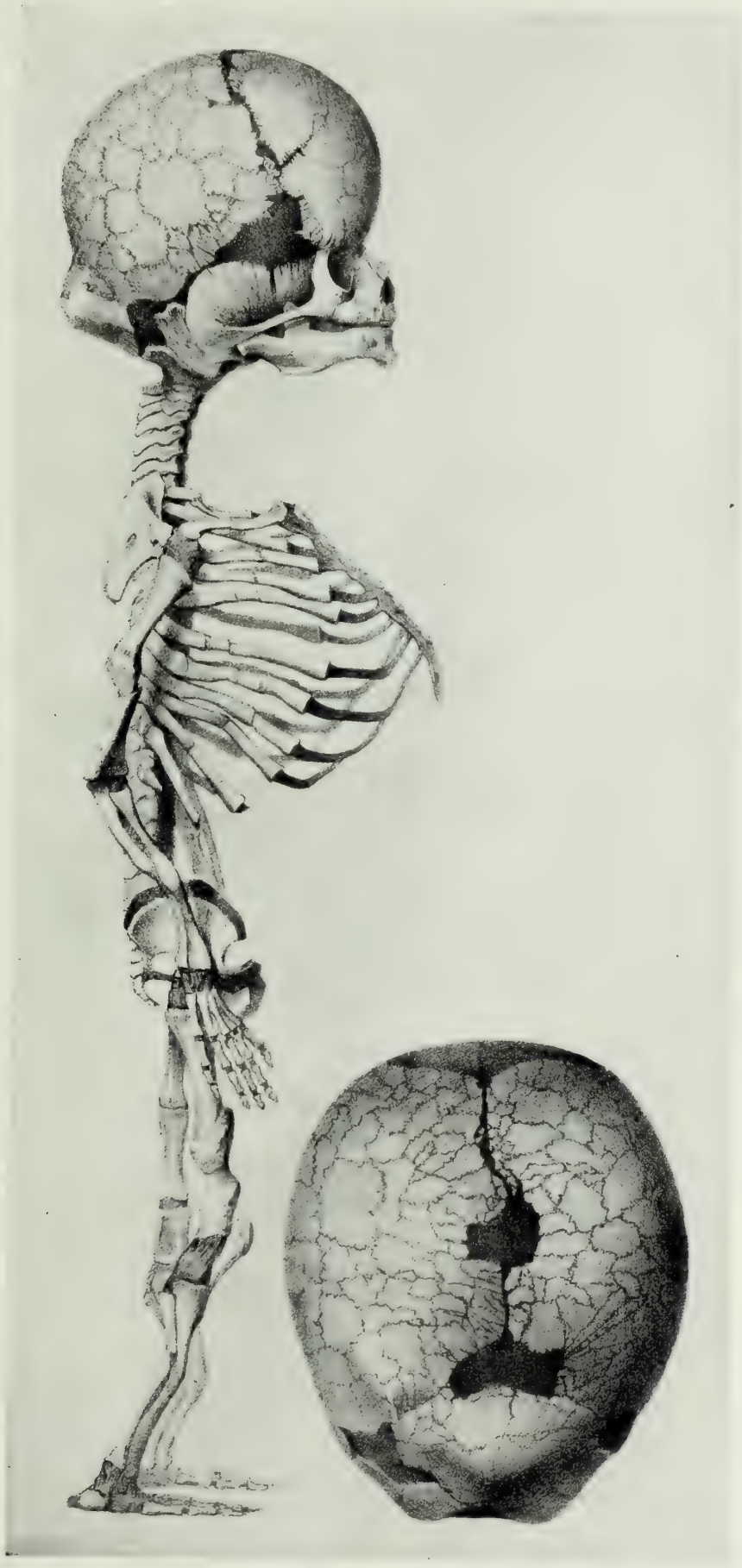

Osteogenesis imperfecta. Multiple fractures and anomalous ossification of the Skull. After Vrolik. (See Bibl. No. 16.)

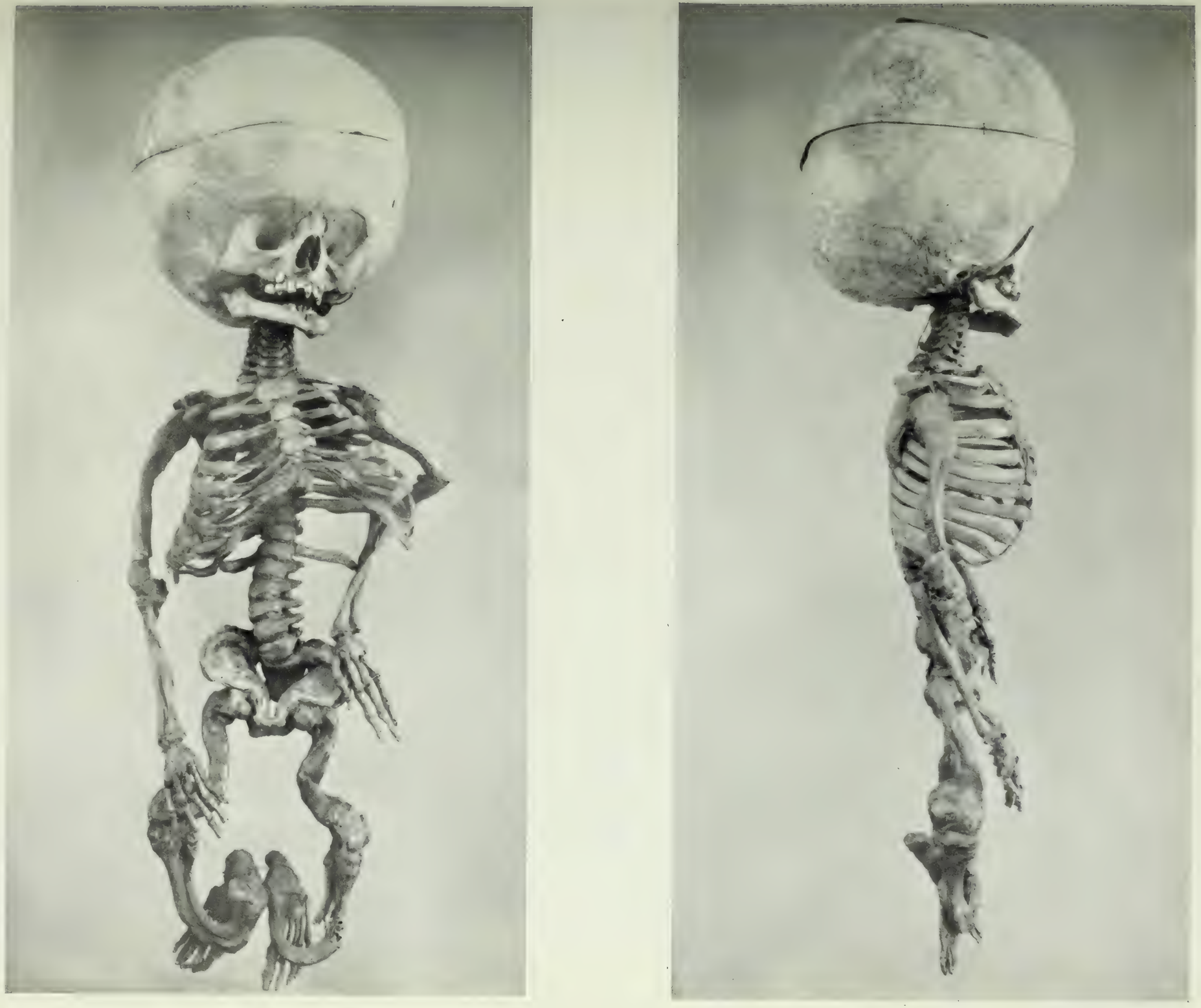

Skeleton of a Hydrocephalic Boy, who died aged 12, showing *Osteogenesis imperfecta.* In the Museum of the Royal College of Surgeons. By kind permission of Sir Arthur Keith.

Osteogenesis imperfecta. Ormerod's Case, from the skeleton in the Museum of the Royal College of Surgeons. By kind permission of Sir Arthur Keith.

Fragilitas ossium. Skiagram of lower limb in Dent's Case (see Plate C). By kind permission of the Medical Society of London.

Amputated and sectional limb of a Boy with *Osteogenesis imperfecta*, from the original in the Museum of the London Hospital. By kind permission of Dr Donald Hunter.

Osteogenesis imperfecta. Skiagram of a new-born female child. By kind permission of Dr Donald Hunter.

Fragilitas ossium. Skiagram of lower extremity of a Boy aged 14 years, showing multiple fractures and external bending.
By kind permission of Mr Robert Milne.

Osteogenesis imperfecta. Skiagram of Femur, showing marked curvature, in a Youth of 17 years. Dr Donald Hunter's Case. By kind permission of Dr Hunter and the Proprietors of the *Lancet.*

Osteogenesis imperfecta. Skiagram showing curvatures of right Tibia and Fibula in a Youth of 17. Dr Donald Hunter's Case.
By kind permission of Dr Hunter and the Proprietors of the *Lancet.*

steogenesis imperfecta. Skiagram of Ulna and Radius, showing curvatures, in a Youth of 17 years. Dr Donald Hunter's Case.
By kind permission of Dr Hunter and the Proprietors of the *Lancet.*

'eogenesis imperfecta. Skiagram of the Skull, in Norma occipitalis, of a Boy aged 14 (see Plate J). By kind permission of Mr Robert Milne.

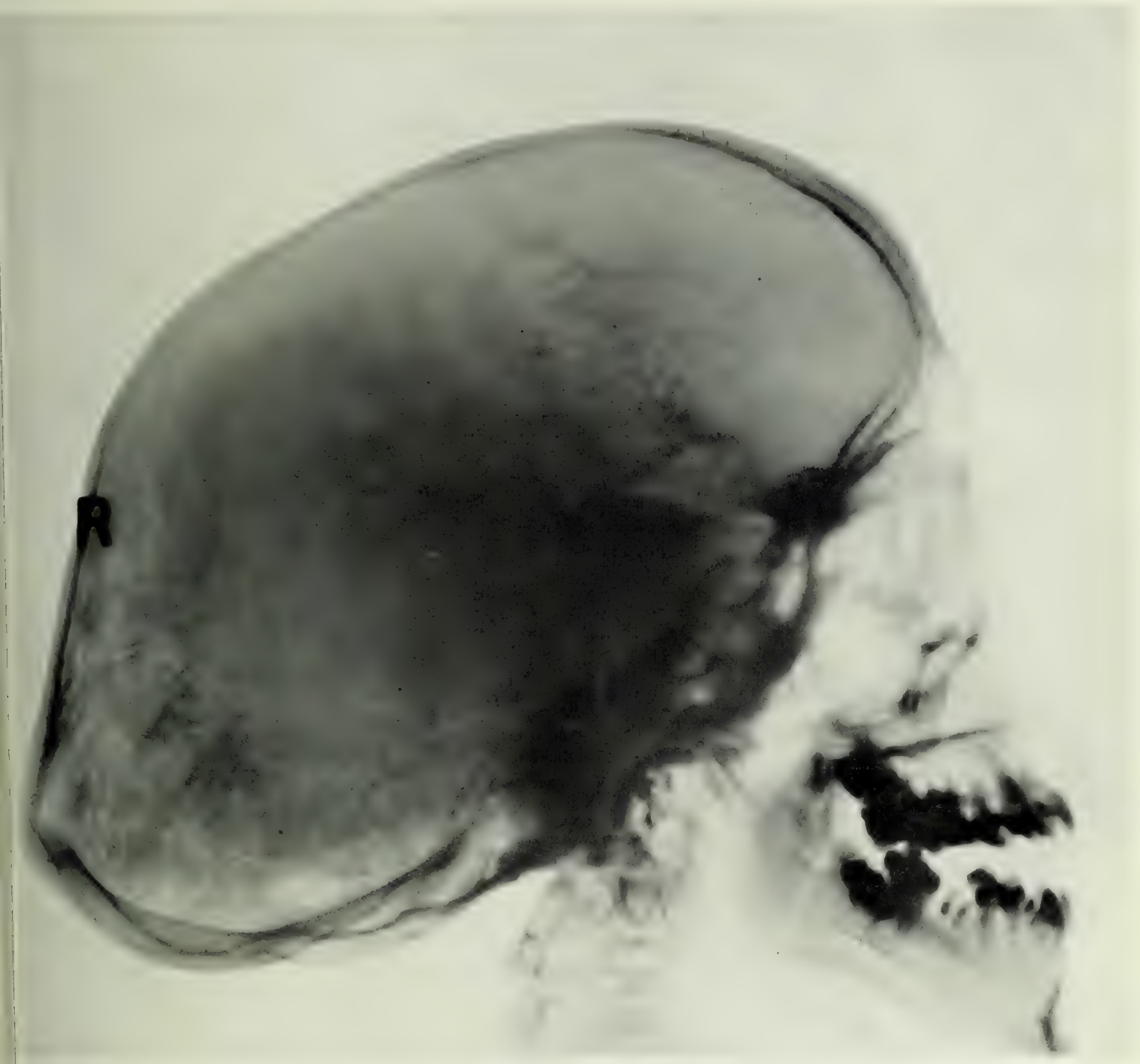

teogenesis imperfecta. Skiagram of Skull, Norma lateralis, showing occipital protuberance in a Youth of 17 years. Dr Donald Hunter's Case. By kind permission of Dr Hunter and the Proprietors of the *Lancet.*

RETINITIS PIGMENTOSA

1. B. Nettleship

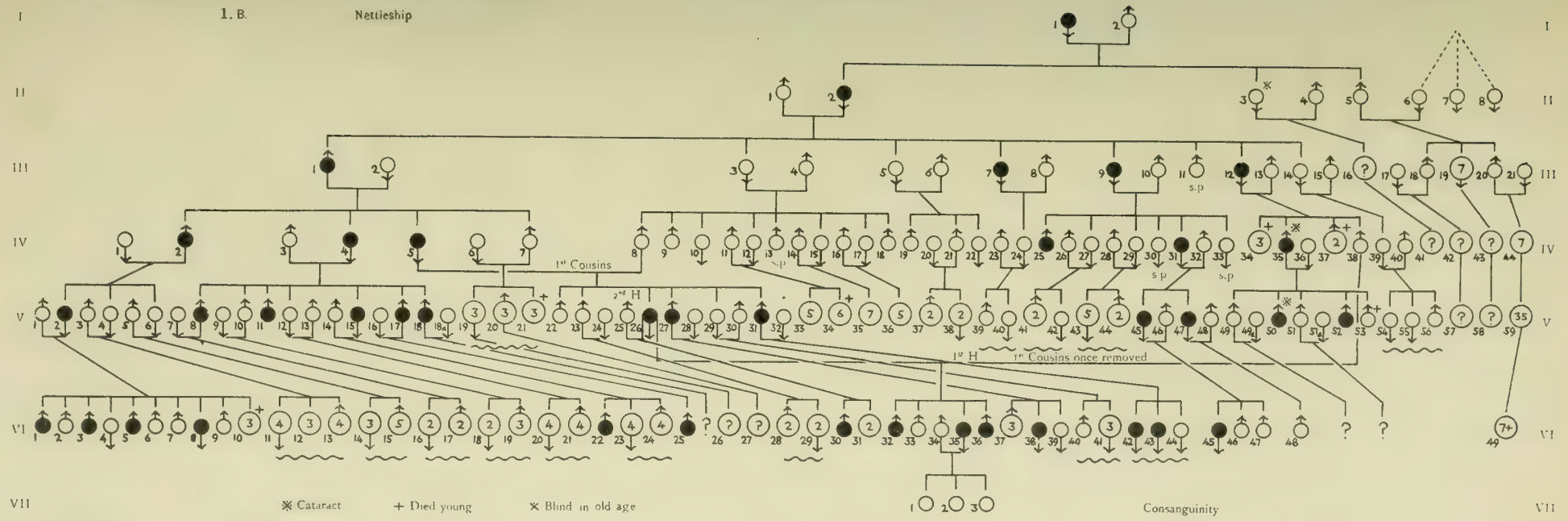

2 Webster

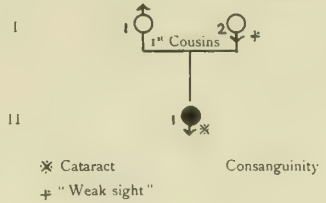

3 Snell

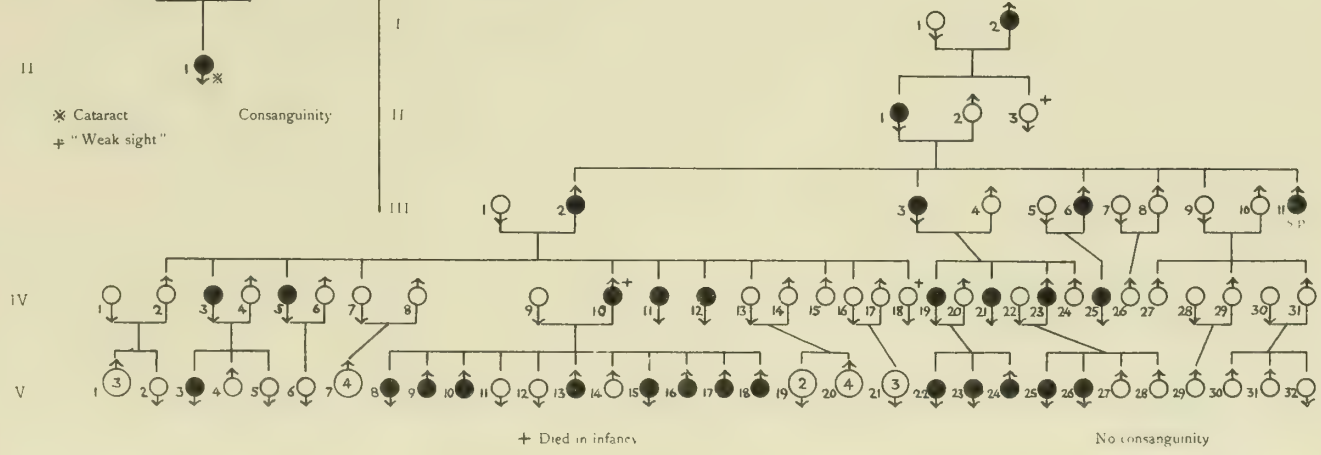

4 Schneider

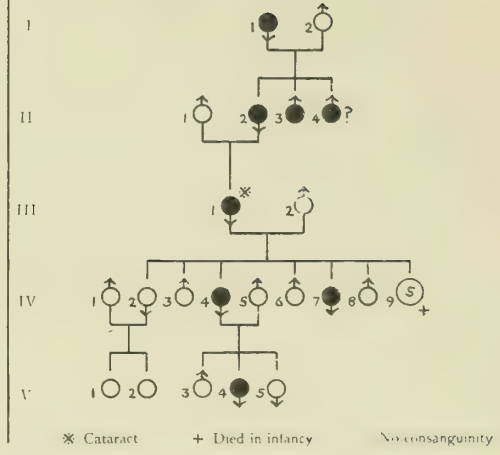

Issued by the Francis Galton Laboratory for National Eugenics.

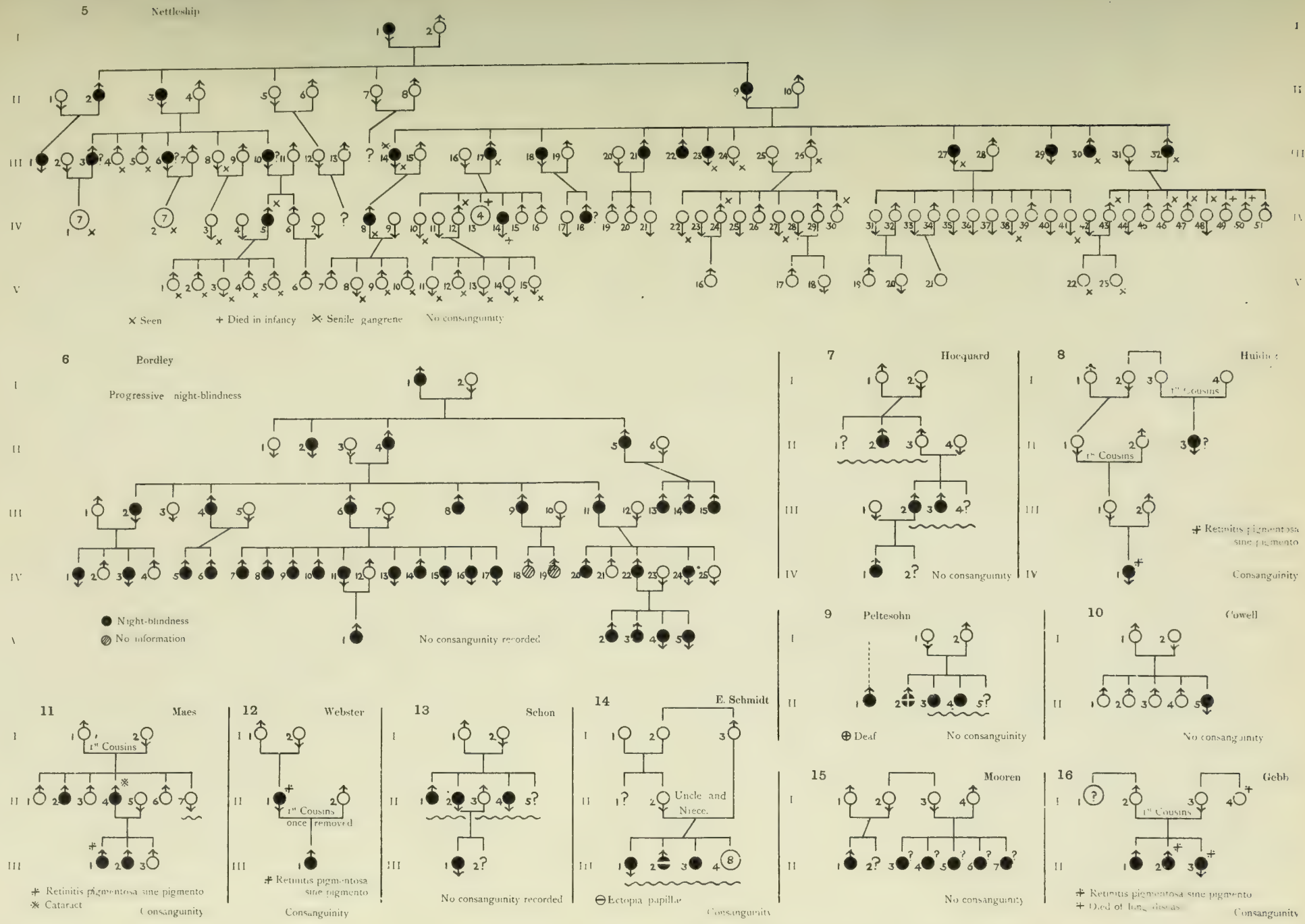

Issued by the Francis Galton Laboratory for National Eugenics.

17 Nettleship

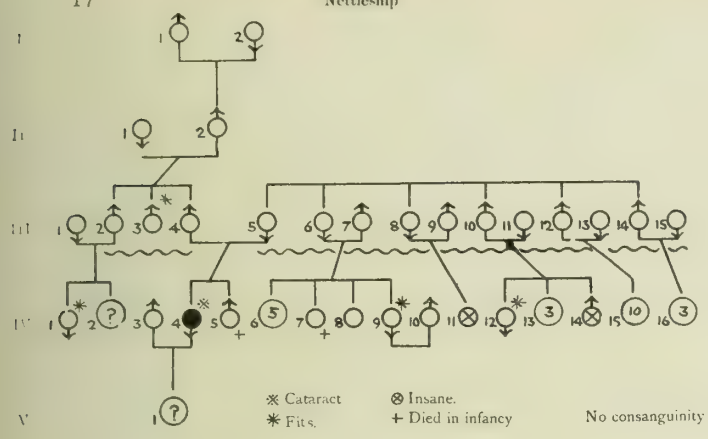

18 Lawford

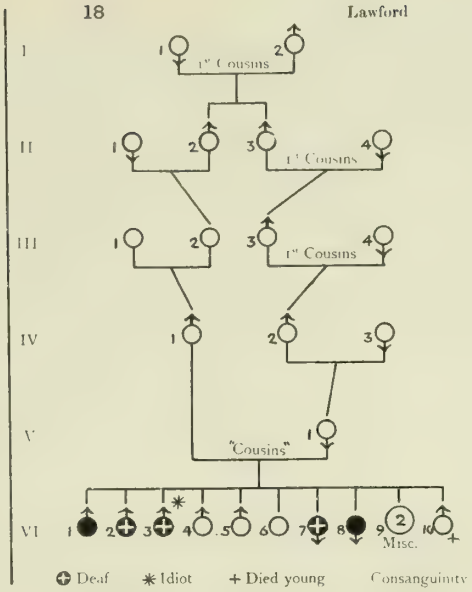

19 Nettleship

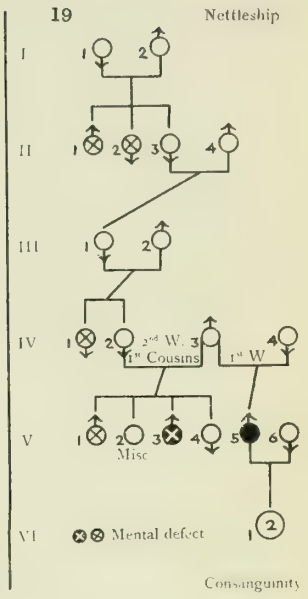

20 Nettleship

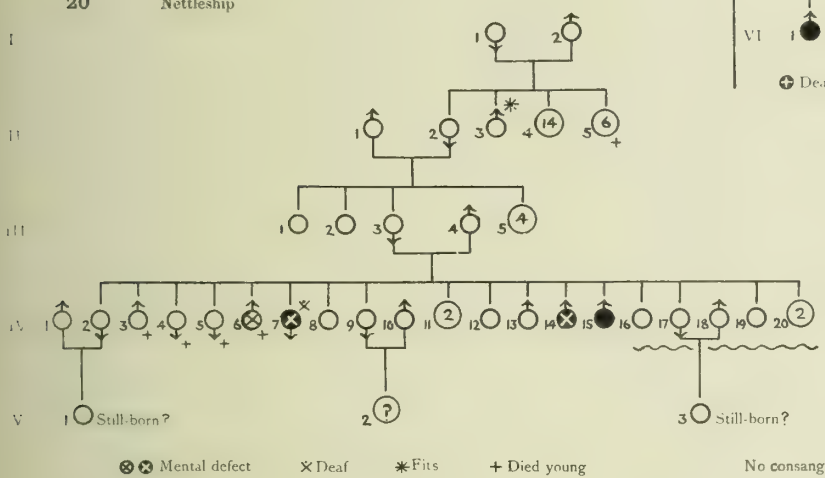

21 Nettleship

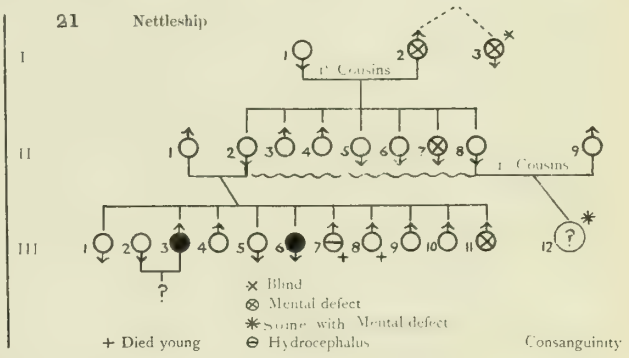

22 Nettleship

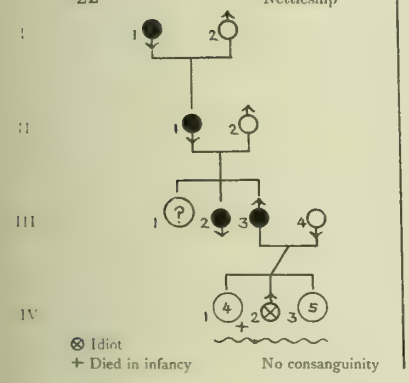

23 Lawford

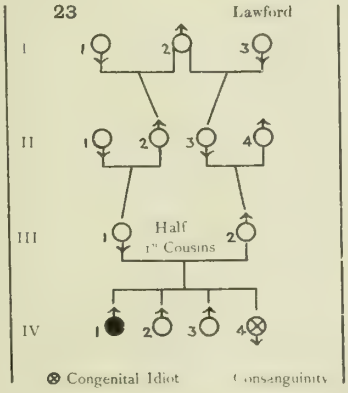

24 Herrlinger

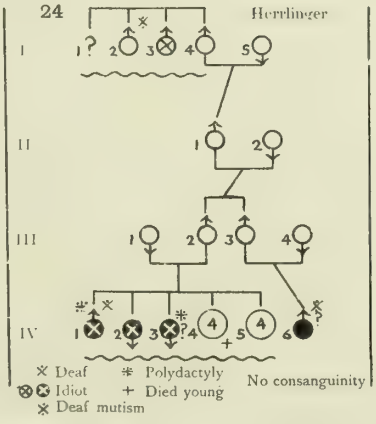

25 Herrlinger

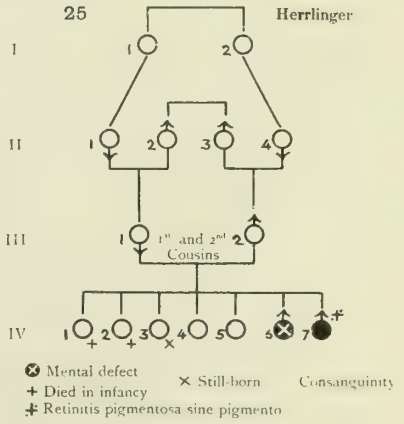

26 Webster

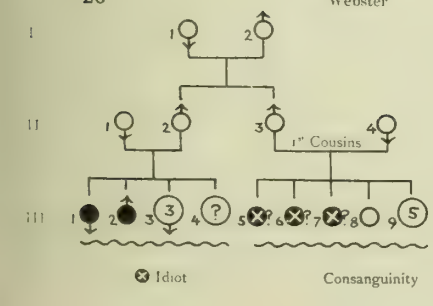

27 Nettleship

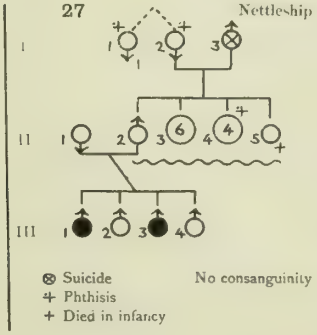

28 Herrlinger

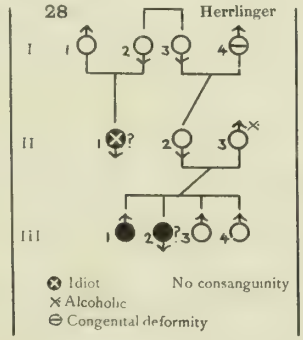

29 Harlan

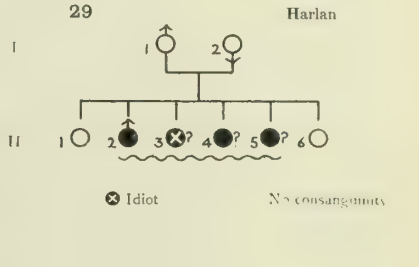

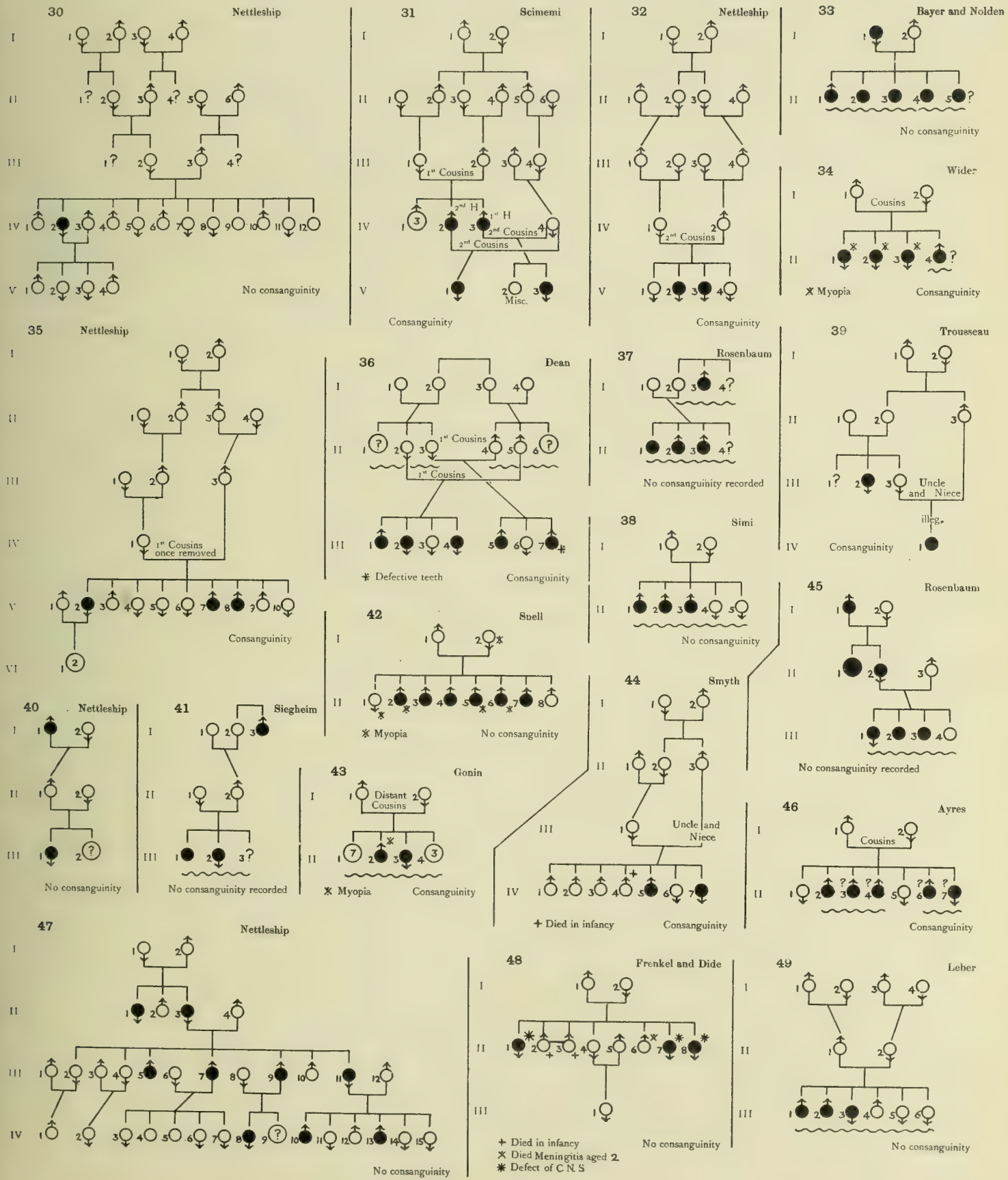
30
Nettleship
No consanguinity
31
Scimemi
1st Cousins
2nd H
1st H
2nd Cousins
2nd Cousins
Misc.
Consanguinity
32
Nettleship
2nd Cousins
Consanguinity
33
Bayer and Nolden
No consanguinity
34
Wider
Cousins
Myopia
Consanguinity
35
Nettleship
1st Cousins once removed
Consanguinity
36
Dean
1st Cousins
1st Cousins
Defective teeth
Consanguinity
37
Rosenbaum
No consanguinity recorded
38
Simi
No consanguinity
39
Trousseau
Uncle and Niece
illeg.
Consanguinity
40
Nettleship
No consanguinity
41
Siegheim
No consanguinity recorded
42
Snell
Myopia
No consanguinity
43
Gonin
Distant Cousins
Myopia
Consanguinity
44
Smyth
Uncle and Niece
Died in infancy
Consanguinity
45
Rosenbaum
No consanguinity recorded
46
Ayres
Cousins
Consanguinity
47
Nettleship
No consanguinity
48
Frenkel and Dide
Died in infancy
Died Meningitis aged 2
Defect of C N S
No consanguinity
49
Leber
No consanguinity

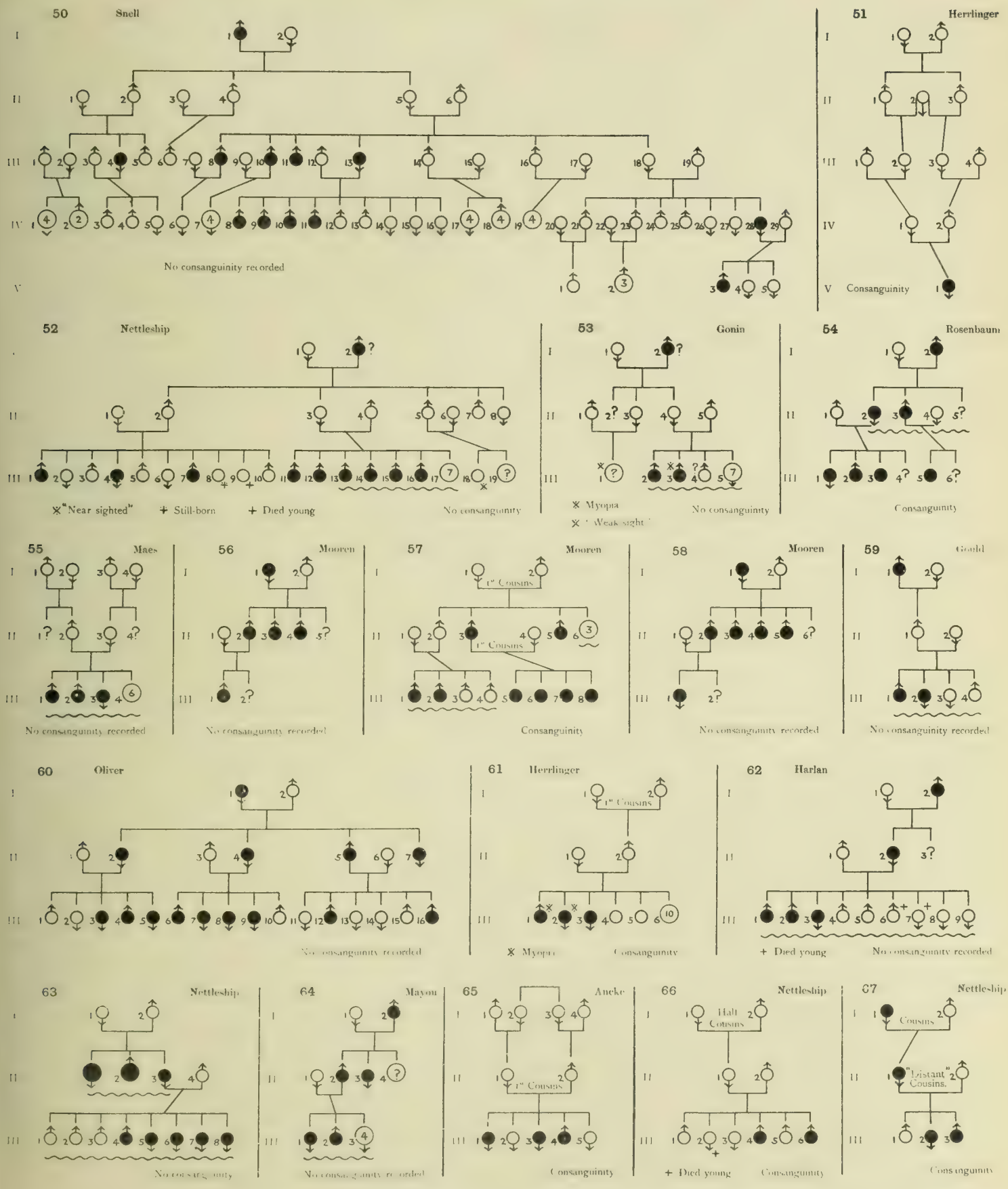

Issued by the Francis Galton Laboratory for National Eugenics.

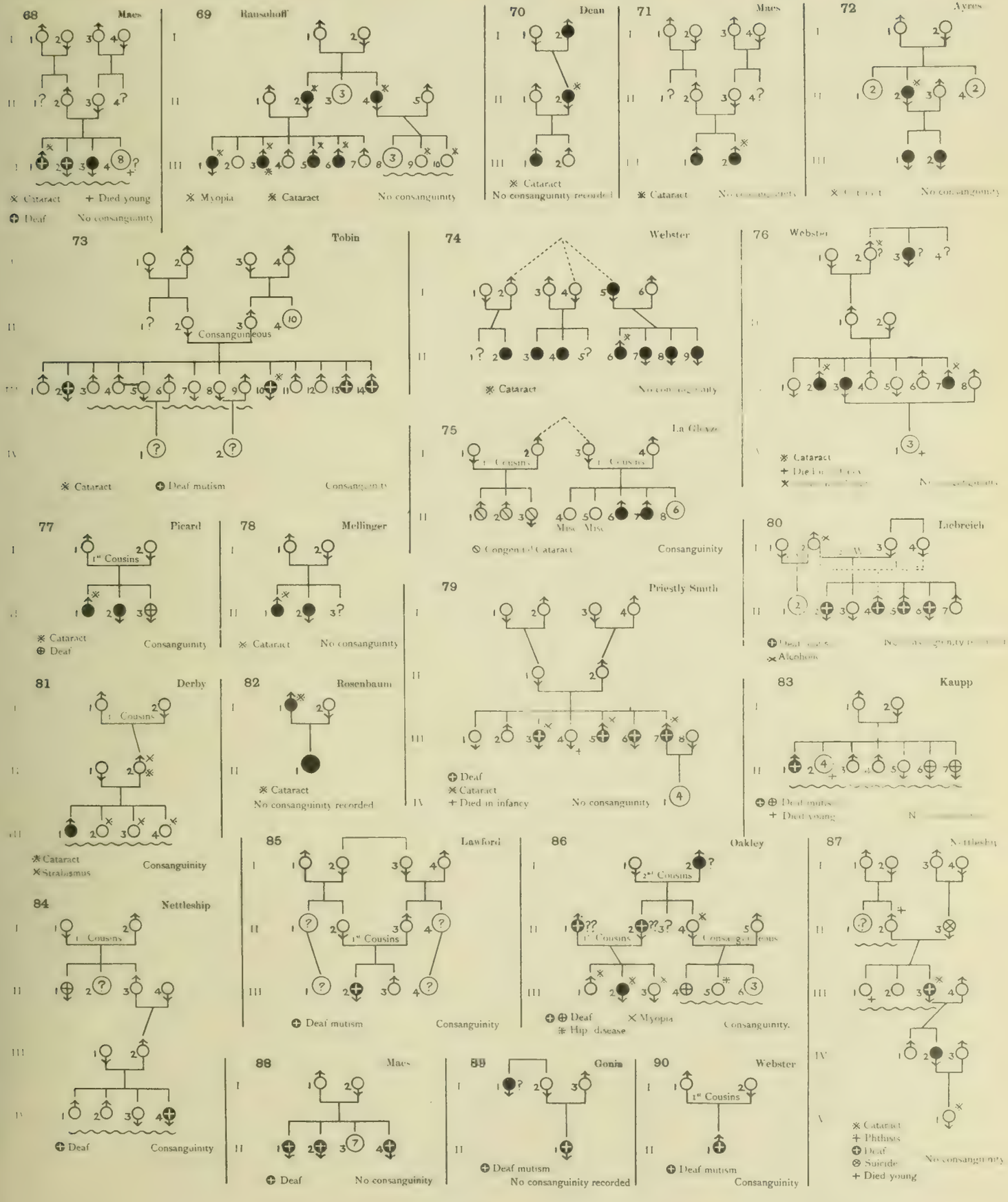
68 Maes
✱ Cataract + Died young
Deaf No consanguinity
69 Ransohoff
✱ Myopia ✱ Cataract No consanguinity
70 Dean
✱ Cataract
No consanguinity recorded
71 Maes
✱ Cataract
72 Ayres
73 Tobin
Consanguineous
✱ Cataract Deaf mutism
74 Webster
✱ Cataract
75 La Gleyze
Congenital Cataract Consanguinity
76 Webster
✱ Cataract
77 Picard
1st Cousins
✱ Cataract
Deaf
Consanguinity
78 Mellinger
✱ Cataract No consanguinity
79 Priestly Smith
Deaf
✱ Cataract
+ Died in infancy
No consanguinity
80 Liebreich
Alcoholism
81 Derby
1st Cousins
✱ Cataract
✱ Strabismus
Consanguinity
82 Rosenbaum
✱ Cataract
No consanguinity recorded
83 Kaupp
+ Died young
84 Nettleship
1st Cousins
Deaf Consanguinity
85 Lawford
1st Cousins
Deaf mutism Consanguinity
86 Oakley
2nd Cousins
1st Cousins
Consanguineous
Deaf ✱ Myopia
✱ Hip disease
Consanguinity.
87 Nettleship
✱ Cataract
+ Phthisis
Deaf
⊗ Suicide
+ Died young
No consanguinity
88 Maes
Deaf No consanguinity
89 Gonin
Deaf mutism
No consanguinity recorded
90 Webster
1st Cousins
Deaf mutism
Consanguinity

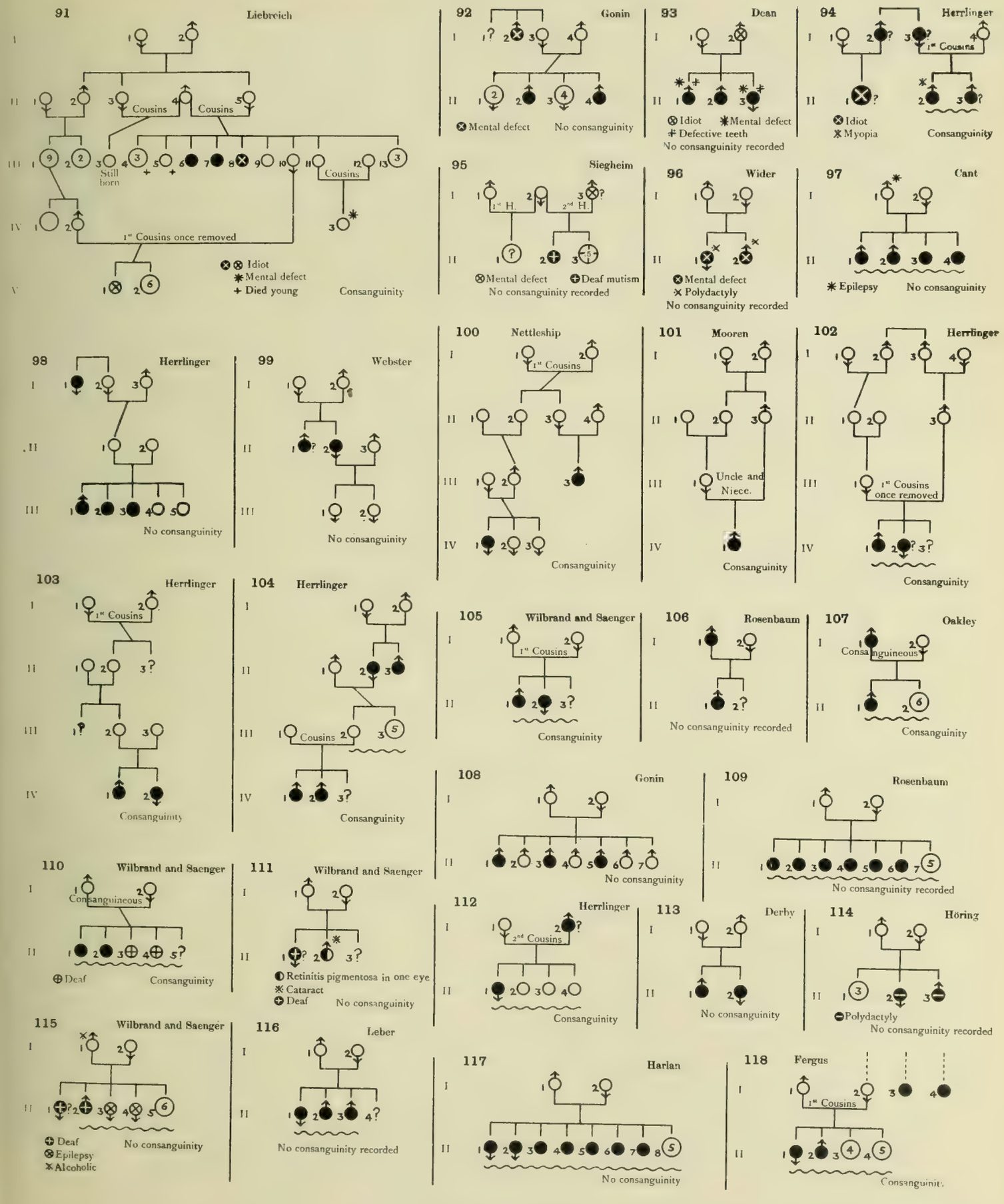
91 Liebreich
Cousins
Cousins
Still born
Cousins
1st Cousins once removed
Idiot
Mental defect
Died young
Consanguinity
92 Gonin
Mental defect
No consanguinity
93 Dean
Idiot
Mental defect
Defective teeth
No consanguinity recorded
94 Herrlinger
1st Cousins
Idiot
Myopia
Consanguinity
95 Siegheim
1st H.
2nd H.
Mental defect
Deaf mutism
No consanguinity recorded
96 Wider
Mental defect
Polydactyly
No consanguinity recorded
97 Cant
Epilepsy
No consanguinity
98 Herrlinger
No consanguinity
99 Webster
No consanguinity
100 Nettleship
1st Cousins
Consanguinity
101 Mooren
Uncle and Niece.
Consanguinity
102 Herrlinger
1st Cousins once removed
Consanguinity
103 Herrlinger
1st Cousins
Consanguinity
104 Herrlinger
Cousins
Consanguinity
105 Wilbrand and Saenger
1st Cousins
Consanguinity
106 Rosenbaum
No consanguinity recorded
107 Oakley
Consanguineous
Consanguinity
108 Gonin
No consanguinity
109 Rosenbaum
No consanguinity recorded
110 Wilbrand and Saenger
Consanguineous
Deaf
Consanguinity
111 Wilbrand and Saenger
Retinitis pigmentosa in one eye
Cataract
Deaf
No consanguinity
112 Herrlinger
2nd Cousins
Consanguinity
113 Derby
No consanguinity
114 Höring
Polydactyly
No consanguinity recorded
115 Wilbrand and Saenger
Deaf
Epilepsy
Alcoholic
No consanguinity
116 Leber
No consanguinity recorded
117 Harlan
No consanguinity
118 Fergus
1st Cousins
Consanguinity

119 Usher and Smith

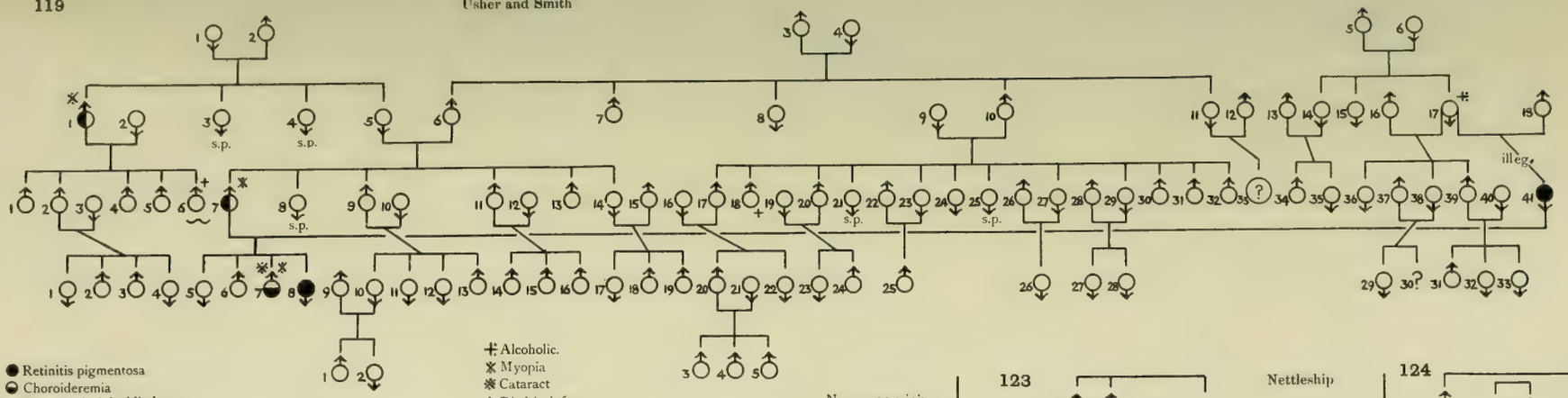

No consanguinity.

120 Nettleship

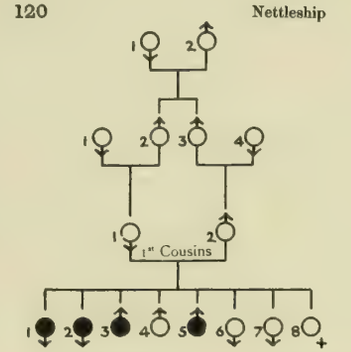

121 La Gleyze

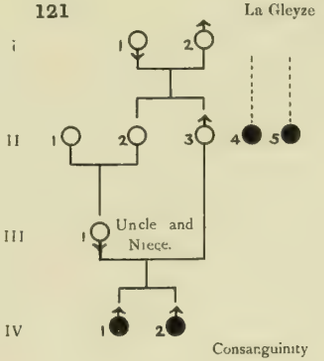

122 Siegheim

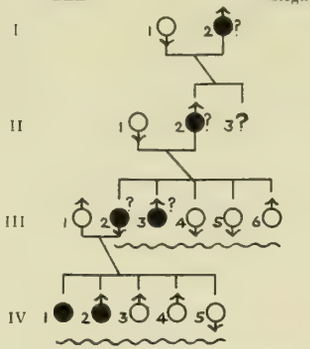

123 Nettleship

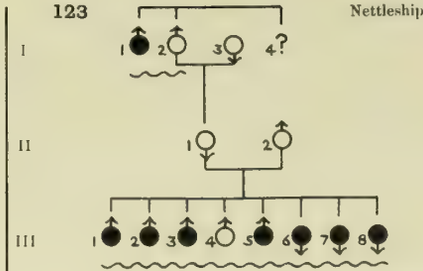

124 Leber

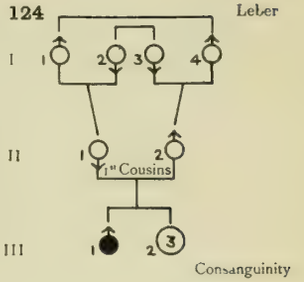

125 Smyth

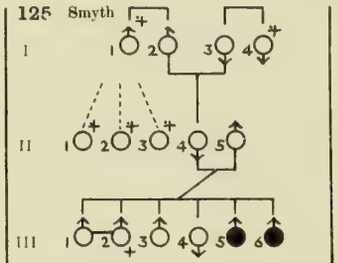

126 Rosenbaum

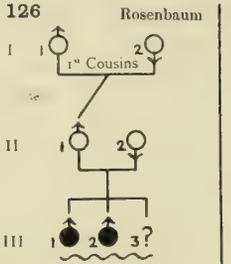

127 Rosenbaum

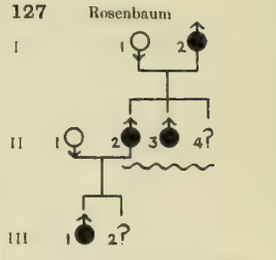

128 Oakley

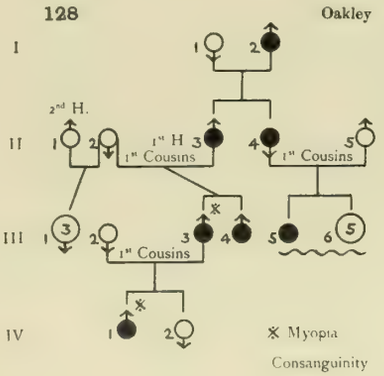

129 Leber

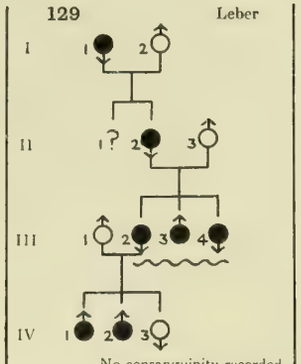

130 Ayres

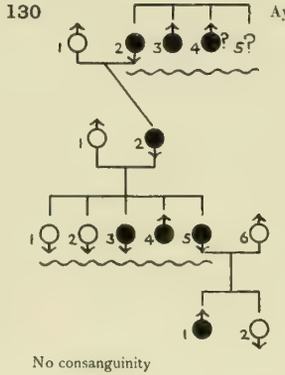

131 Ayres

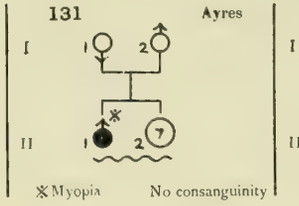

132 E. Schmidt

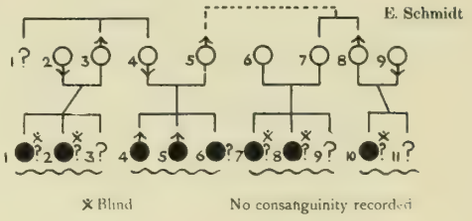

Issued by the Francis Galton Laboratory for National Eugenics.

133 Usher

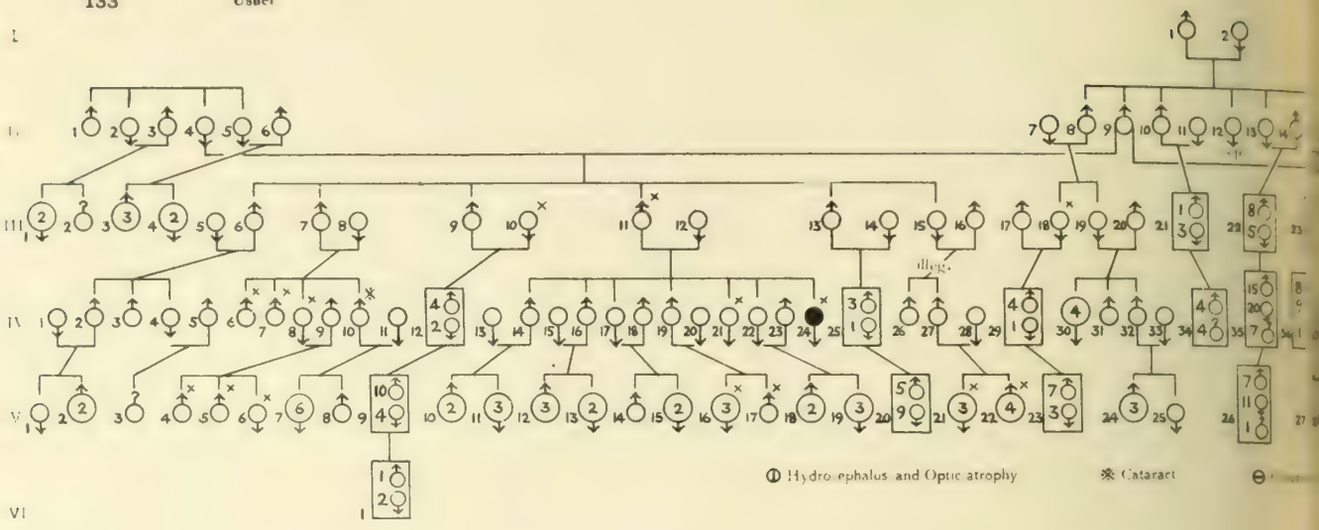

134 Usher

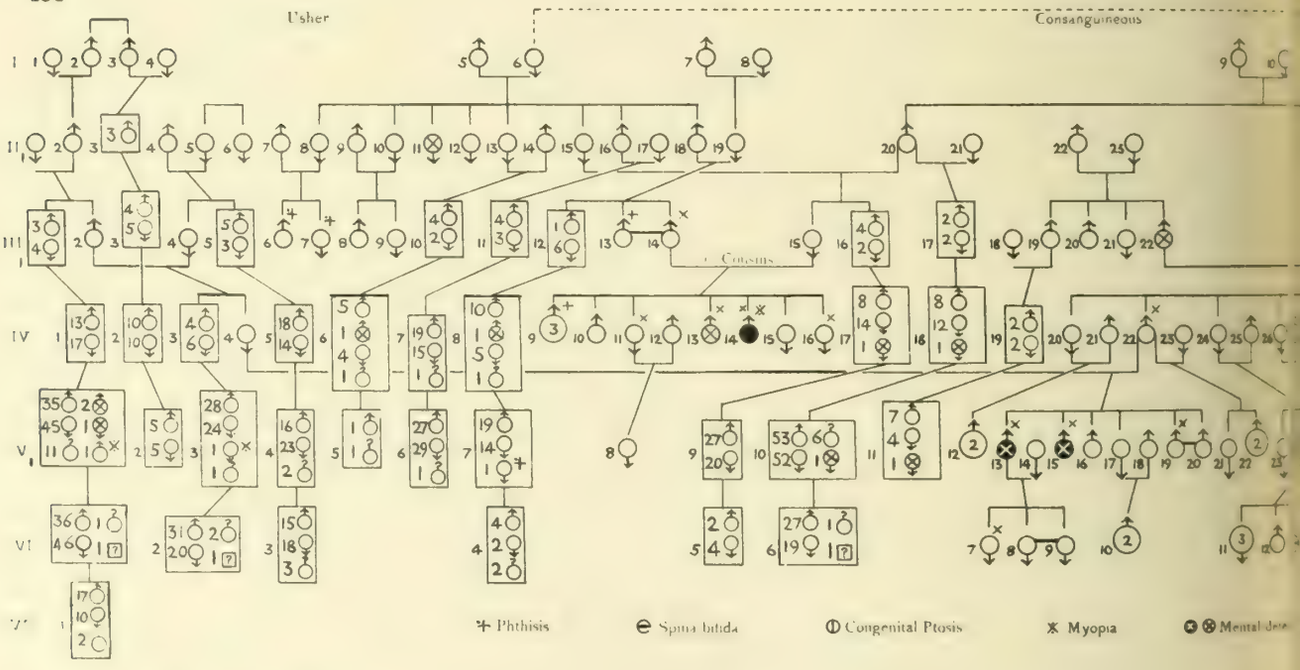

135 Usher

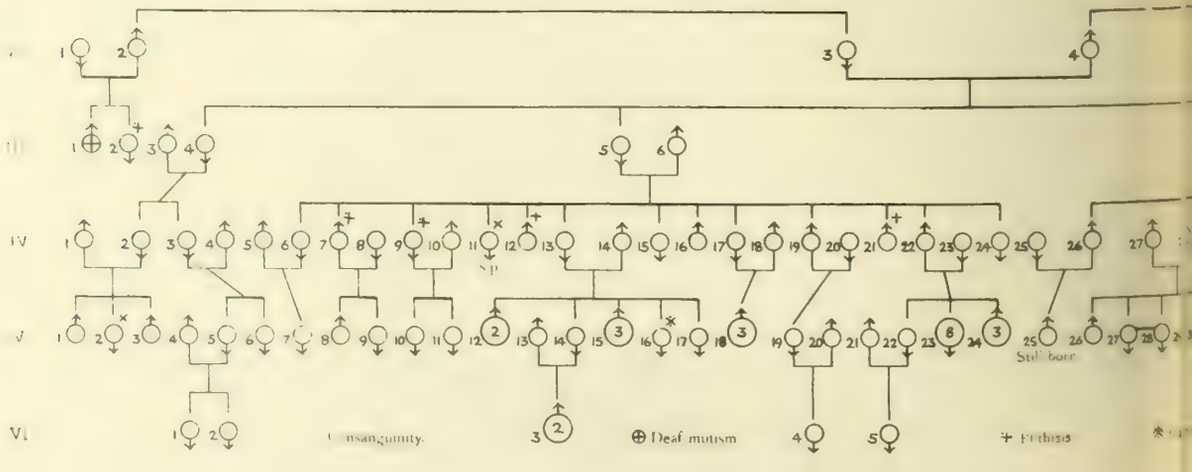

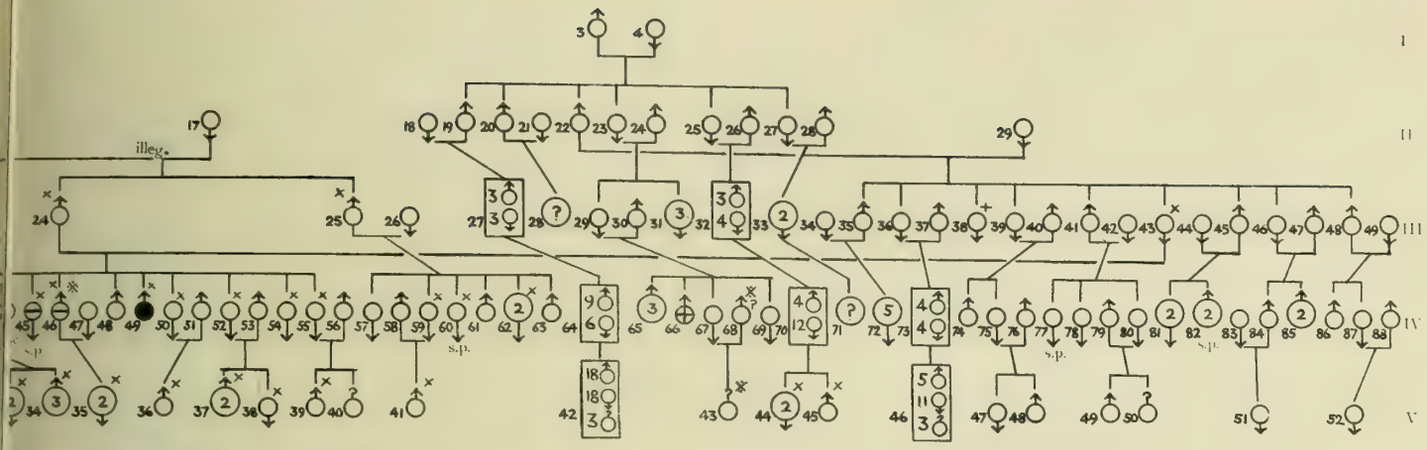

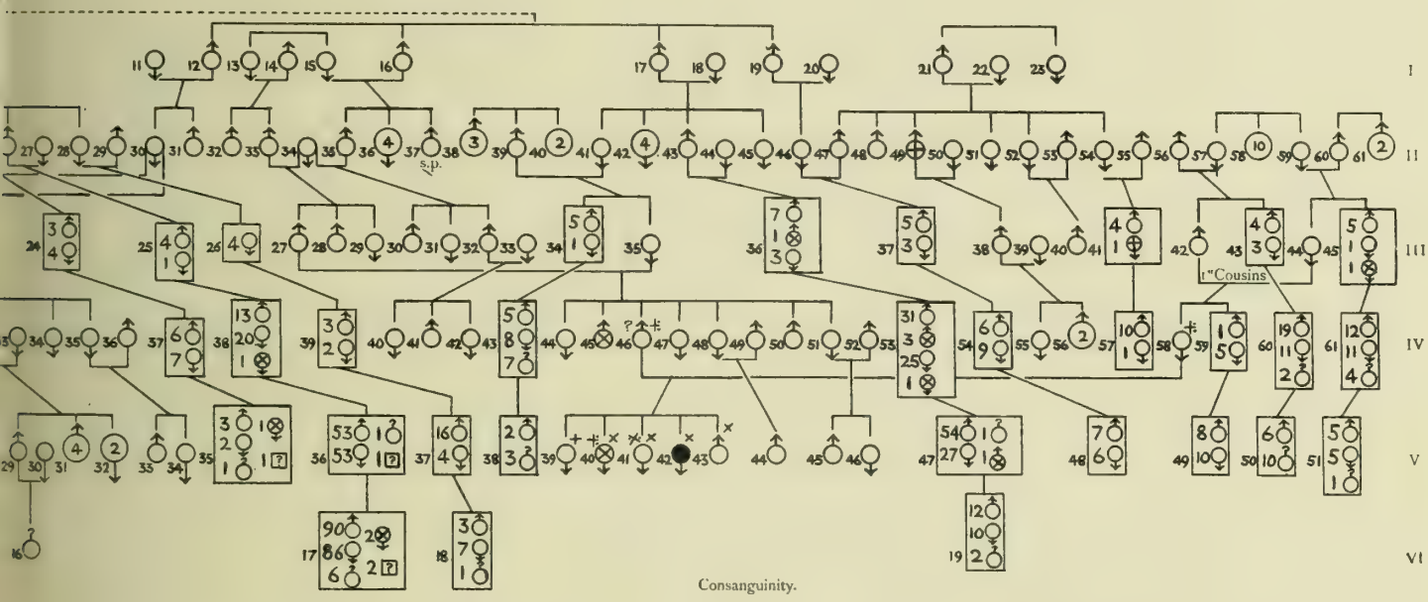

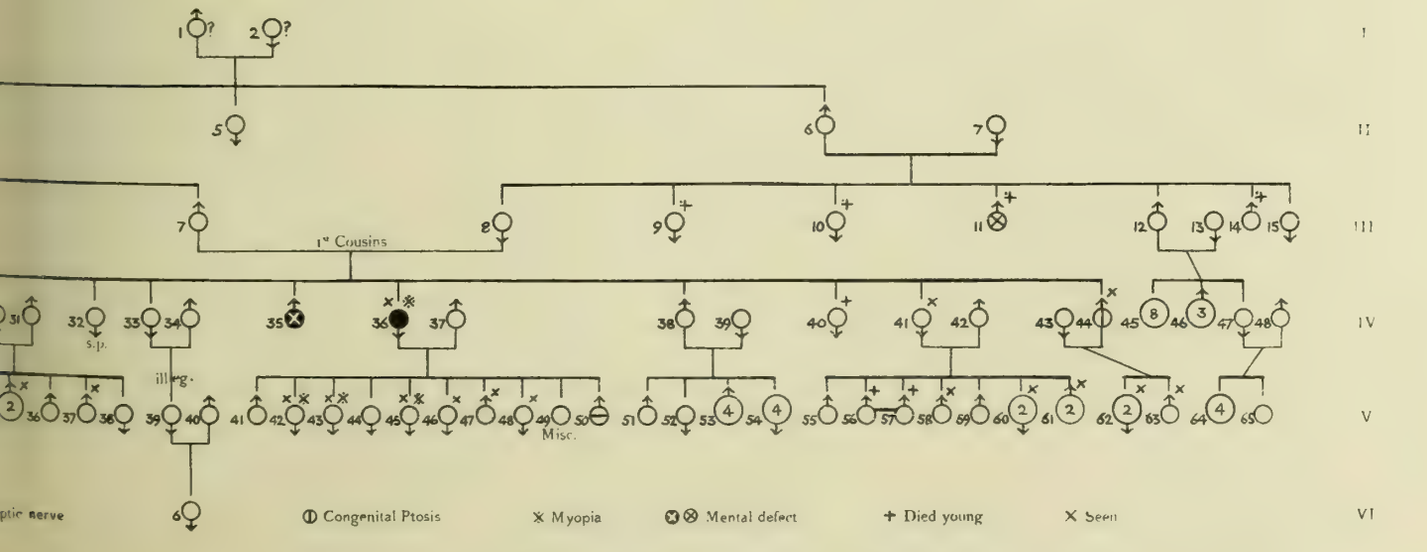

Issued by the Francis Galton Laboratory for National Eugenics.

136 Usher

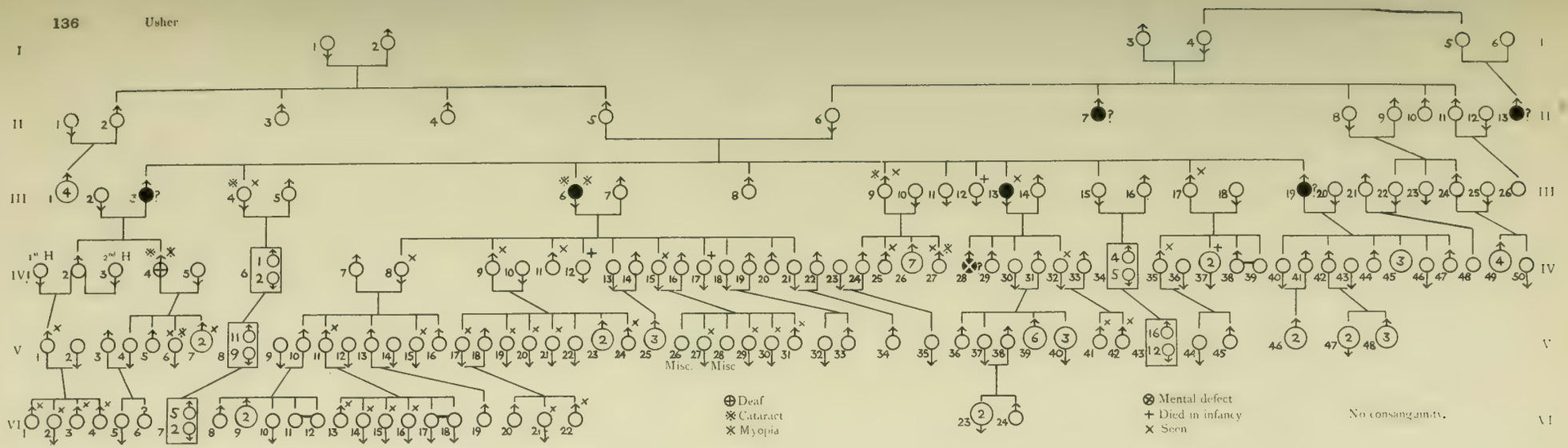

137 Usher

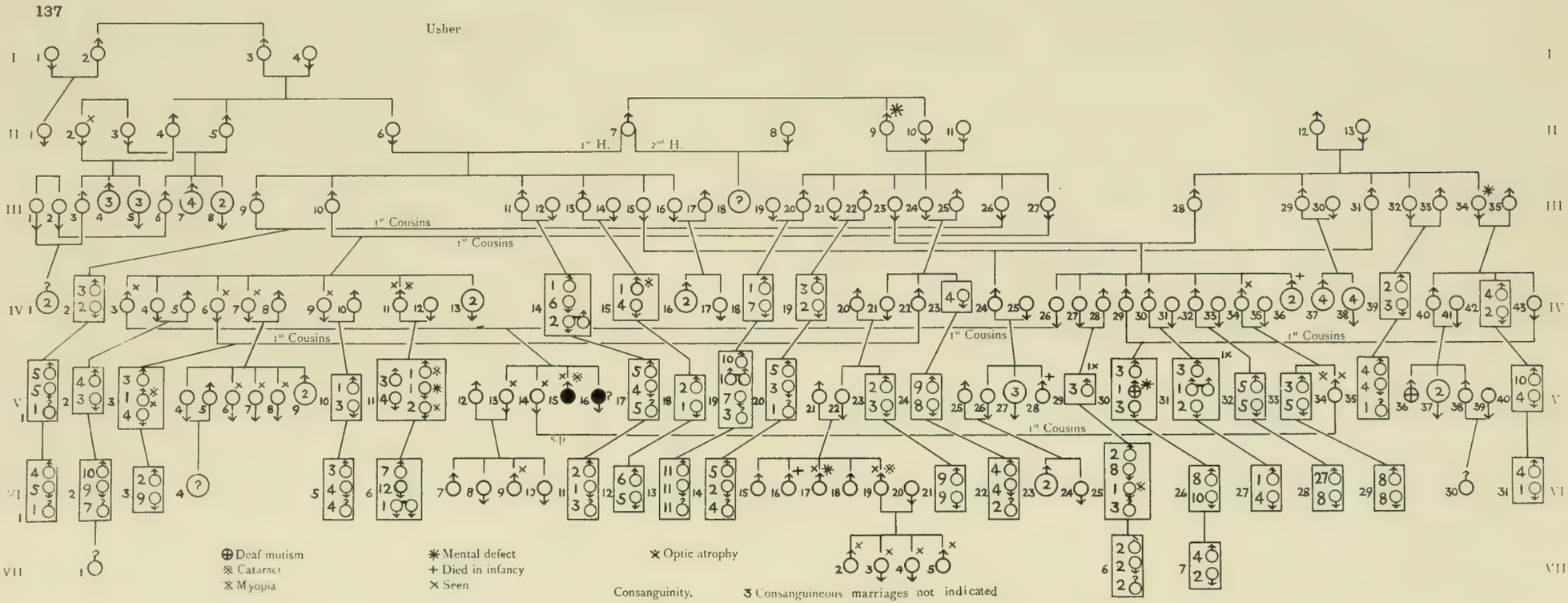

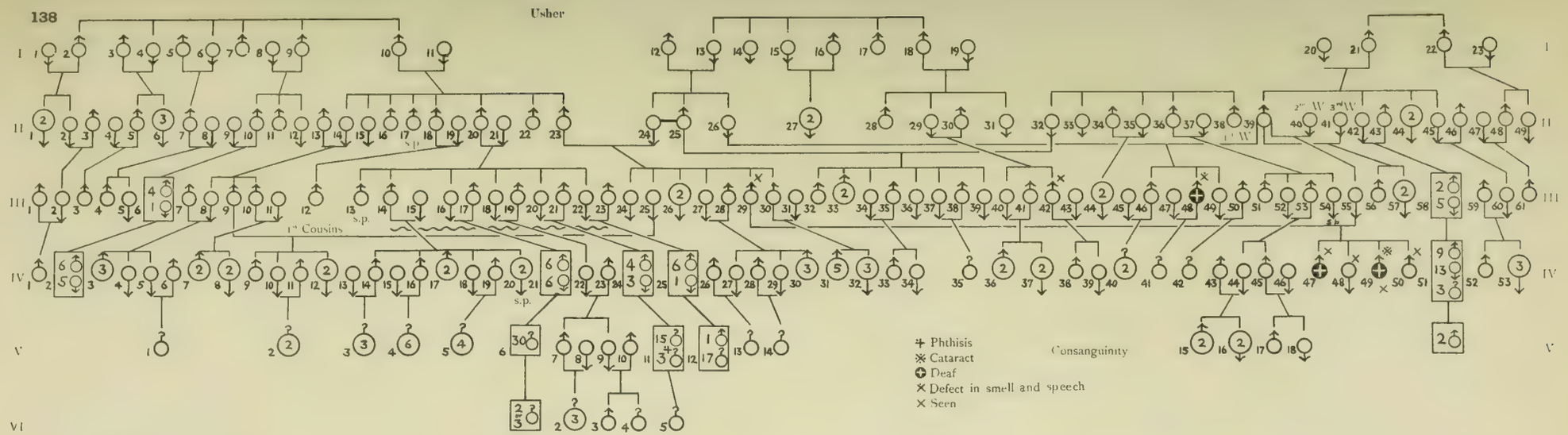
138
Usher
1st Cousins
s.p.
Phthisis
Cataract
Deaf
Defect in smell and speech
Seen
Consanguinity

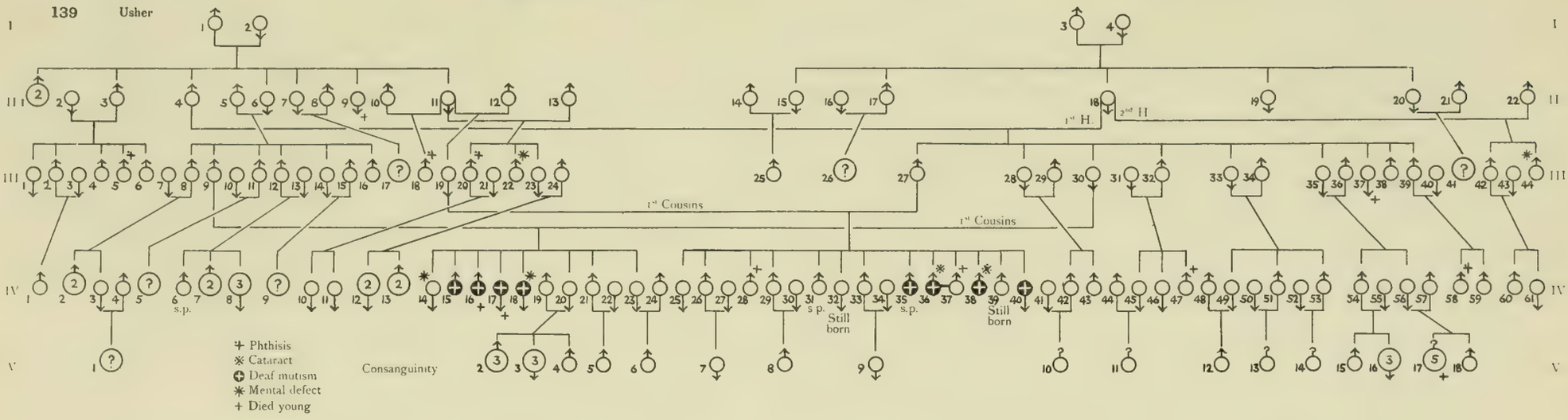
139
Usher
1st H.
2nd H
1st Cousins
1st Cousins
s.p.
Still born
Phthisis
Cataract
Deaf mutism
Mental defect
Died young
Consanguinity

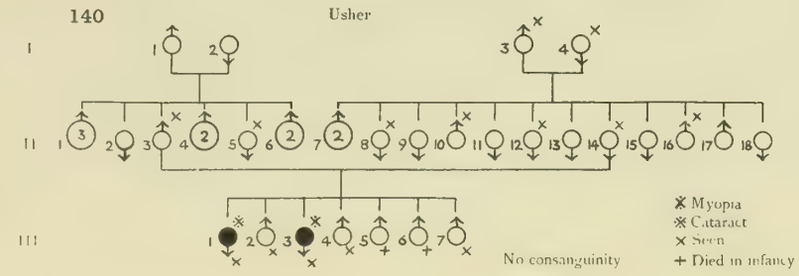
140
Usher
Myopia
Cataract
Seen
Died in infancy
No consanguinity

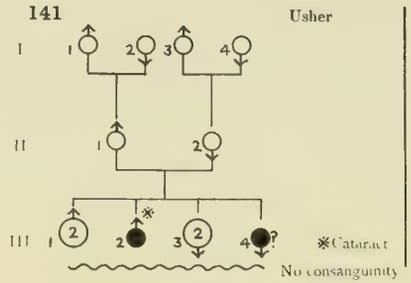
141
Usher
Cataract
No consanguinity

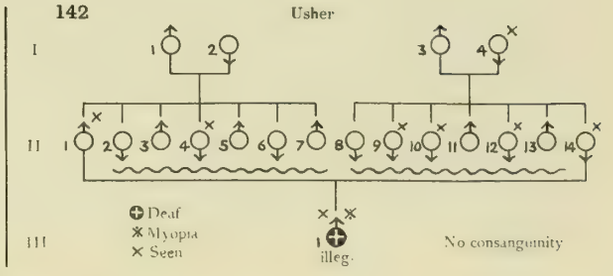
142
Usher
Deaf
Myopia
Seen
illeg.
No consanguinity

143 Usher

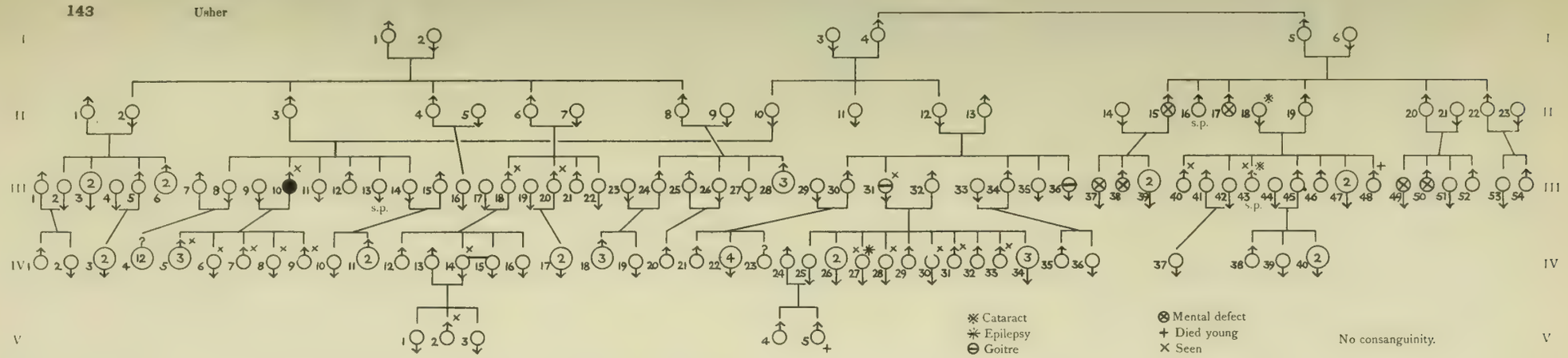

144 Usher

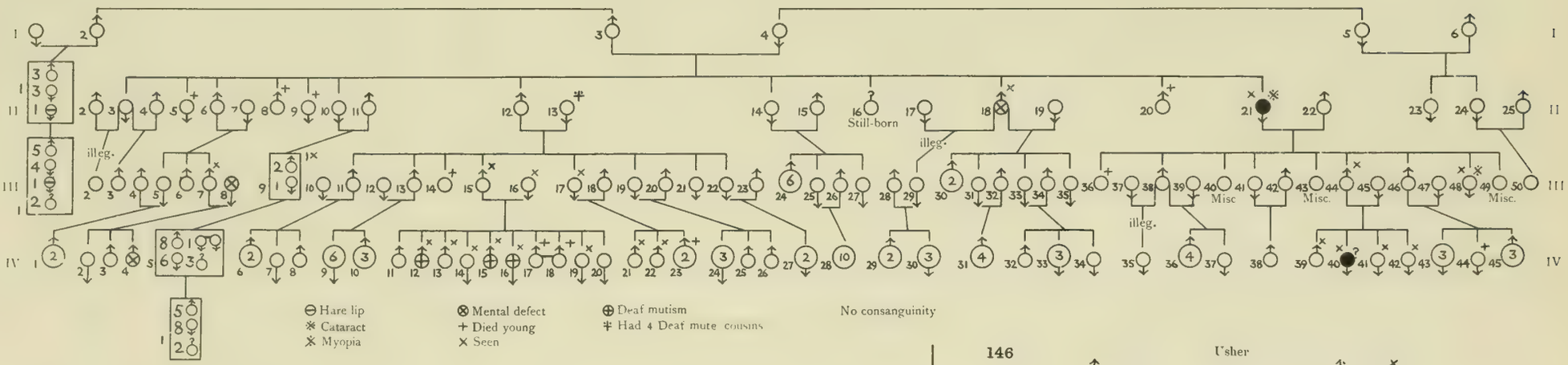

145 Usher

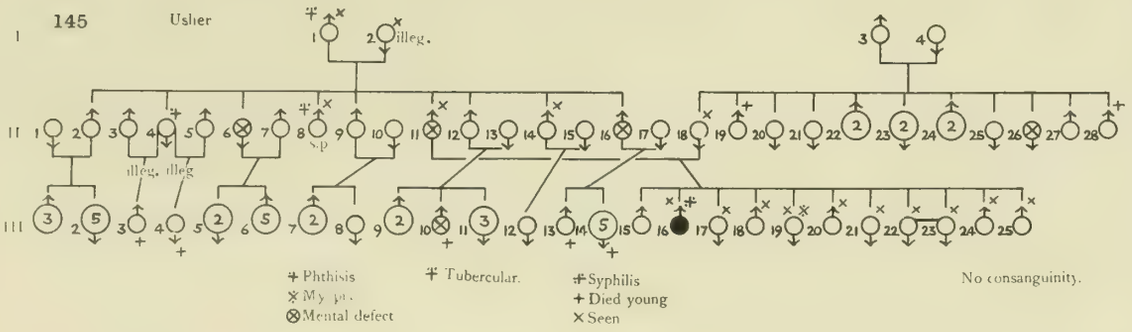

146 Usher

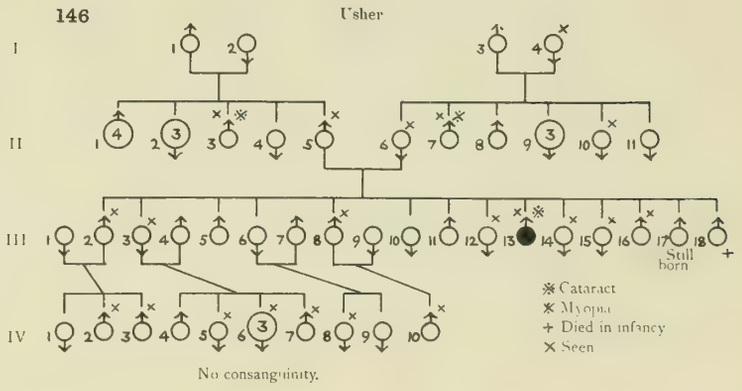

147 Usher

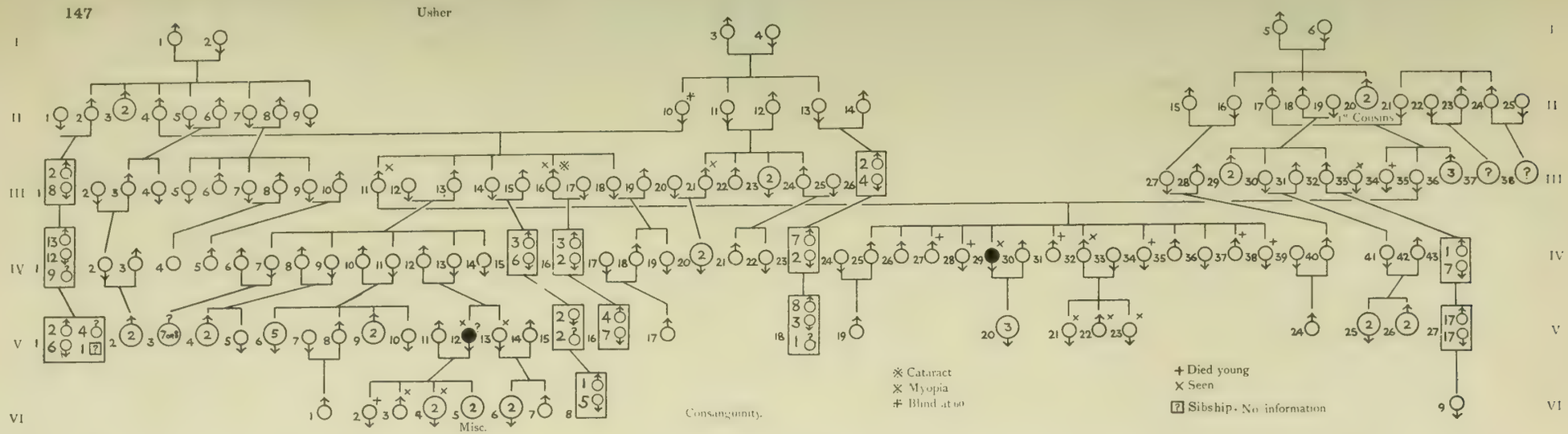

148 Usher

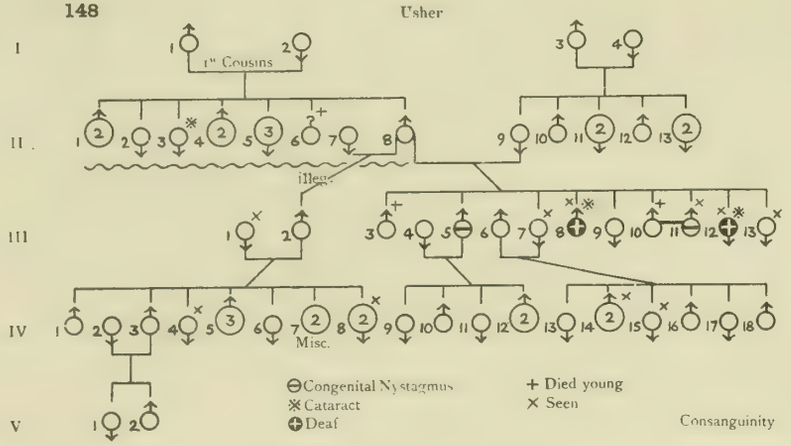

149 Usher

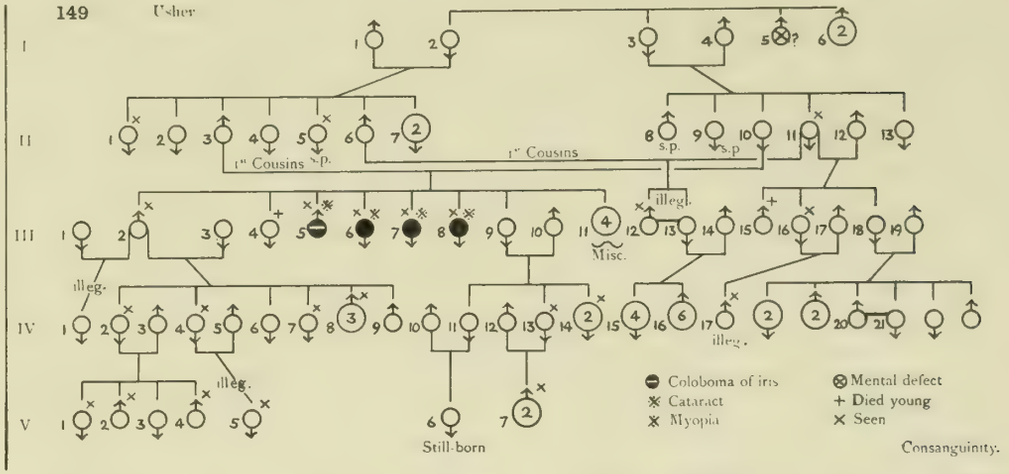

150 Usher

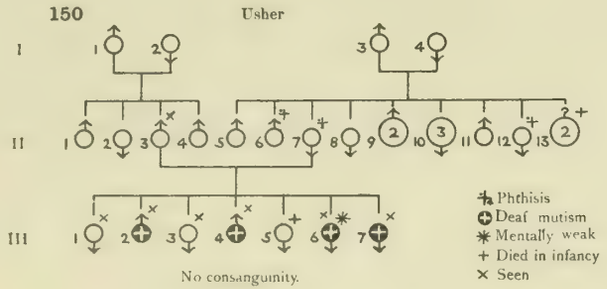

151 Usher

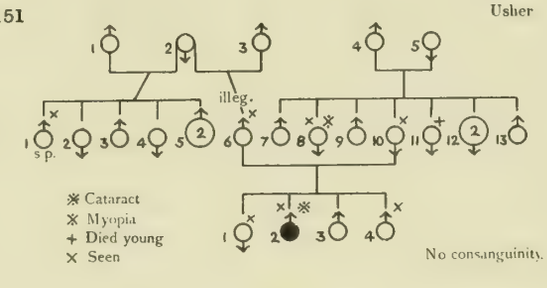

152 Usher

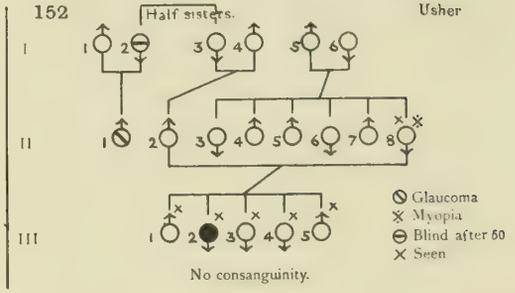

153 Usher

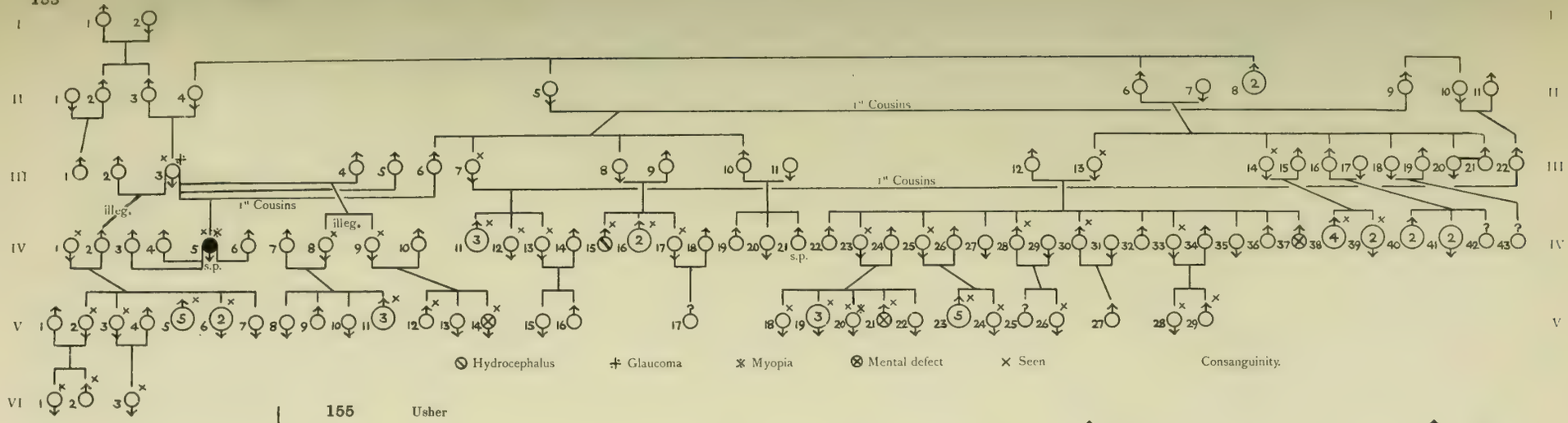

154 Usher

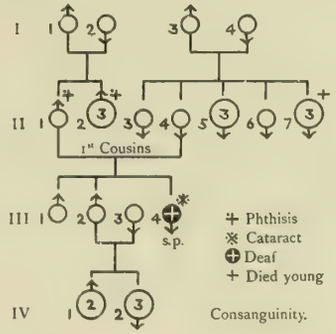

155 Usher

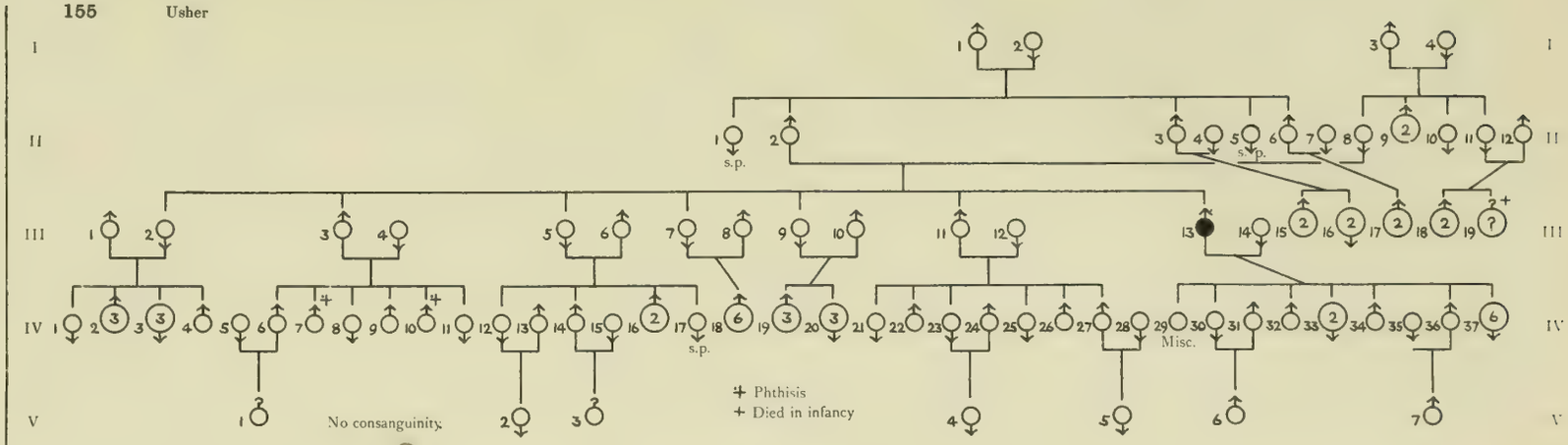

156 Usher

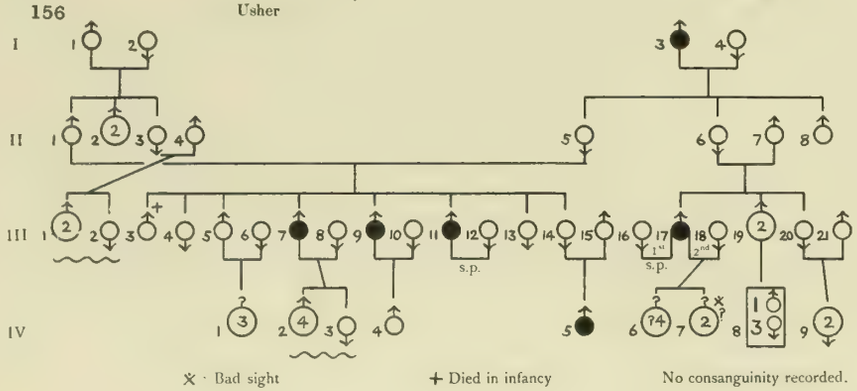

157 Usher

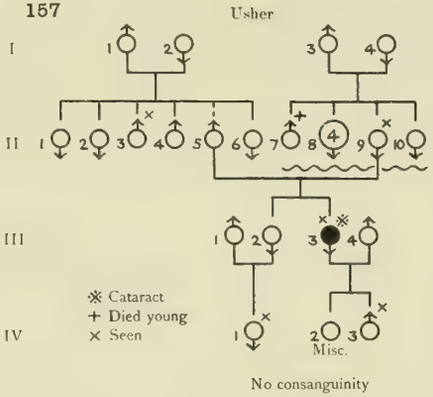

158 Usher

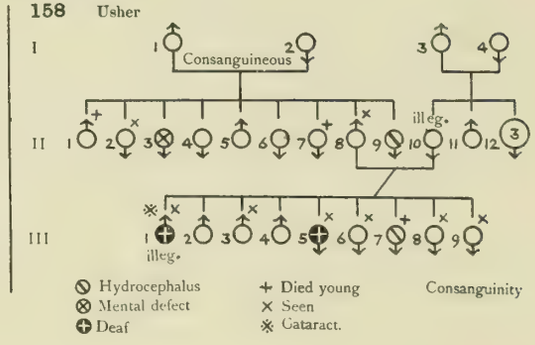

Issued by the Francis Galton Laboratory for National Eugenics.

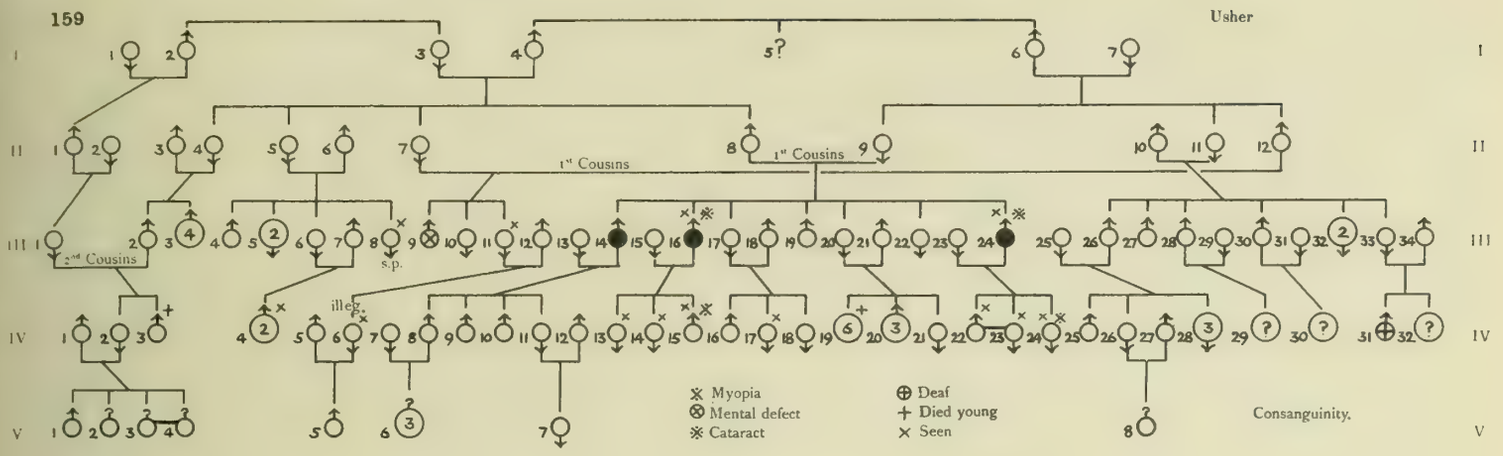

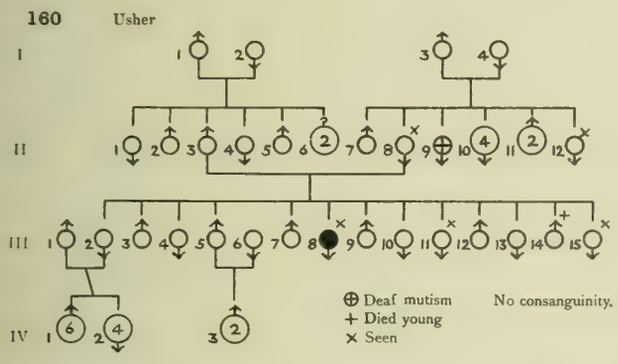

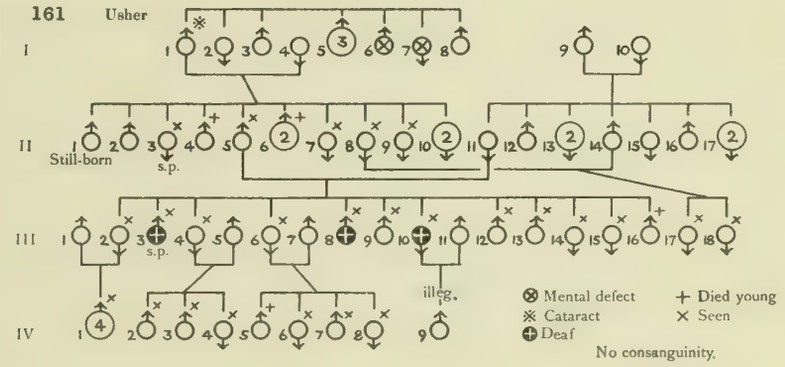

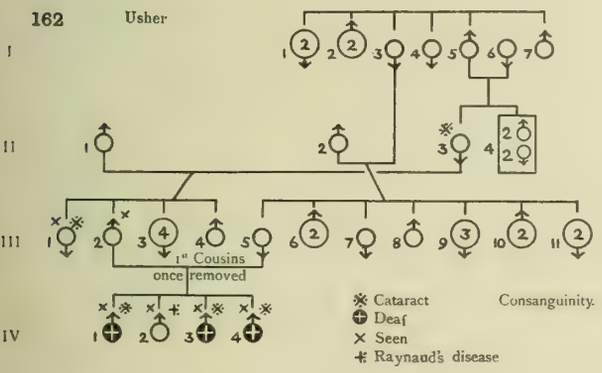

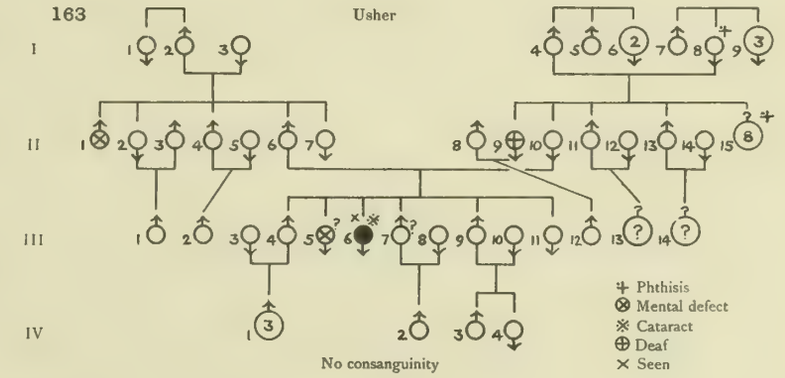

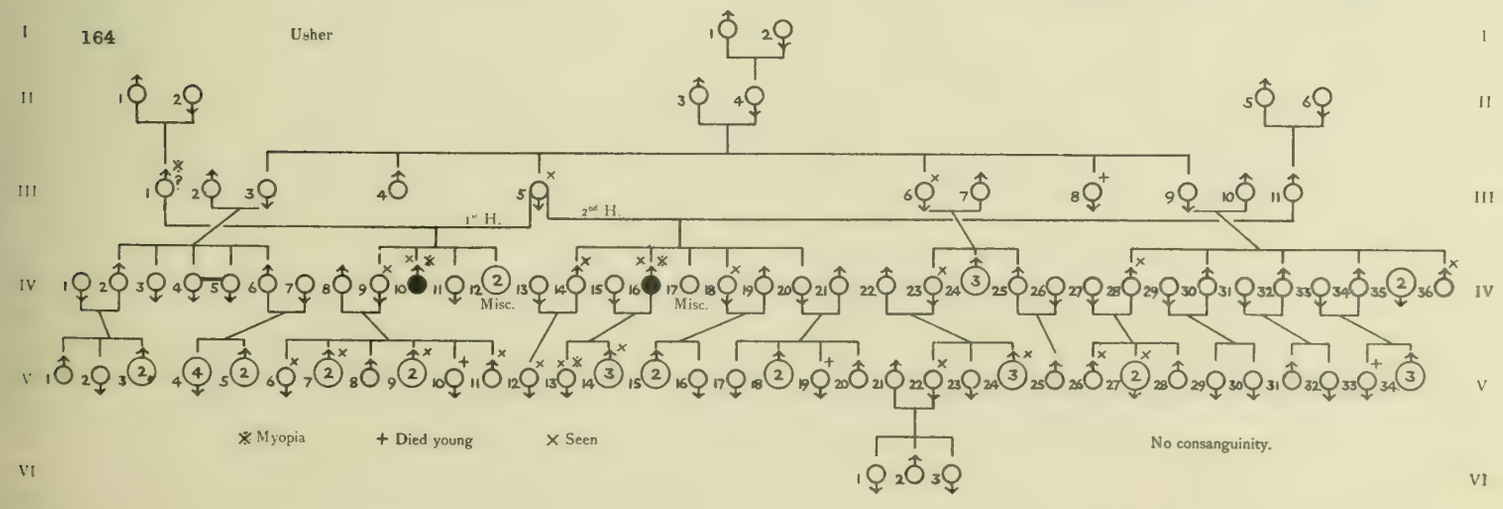

Issued by the Francis Galton Laboratory for National Eugenics.

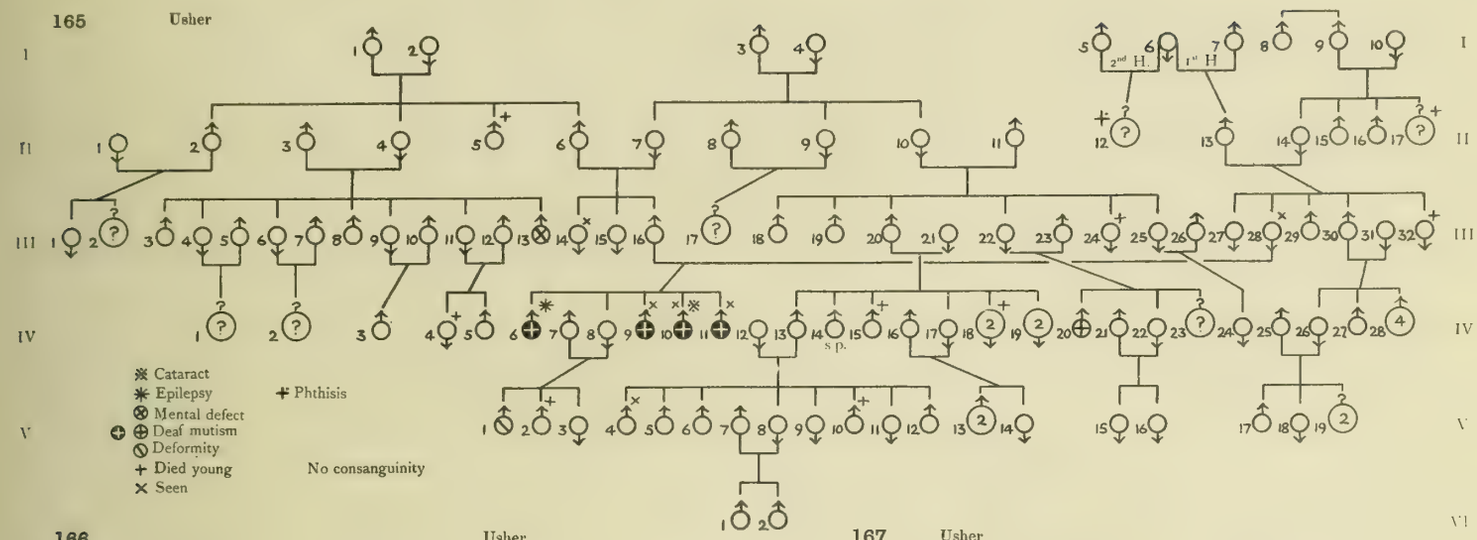
165
Usher
Cataract
Epilepsy
Mental defect
Deaf mutism
Deformity
Died young
Seen
Phthisis
No consanguinity

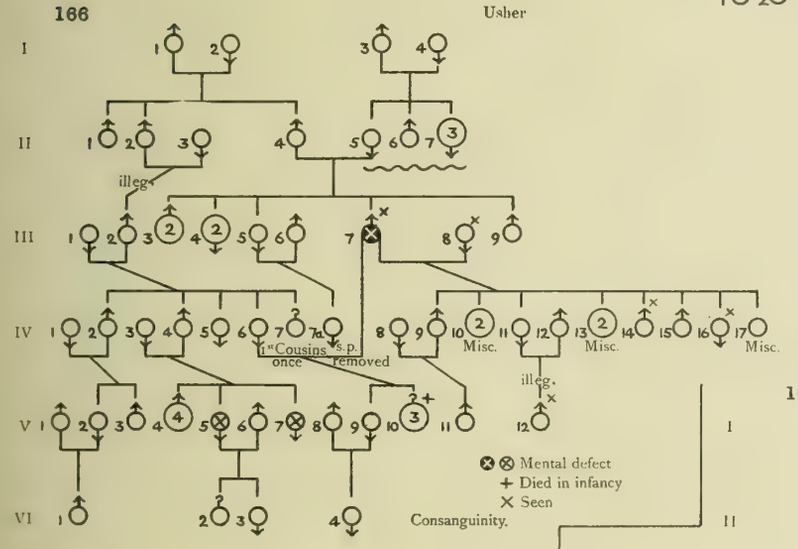
166
Usher
illeg.
1st Cousins once removed
s.p.
Misc.
illeg.
Mental defect
Died in infancy
Seen
Consanguinity.

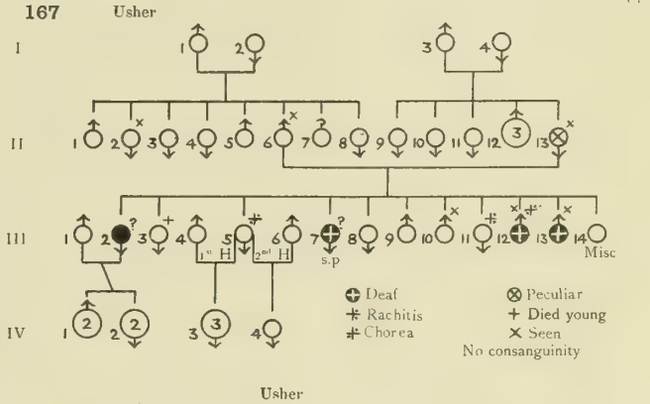
167
Usher
1st H.
2nd H.
s.p
Misc
Deaf
Rachitis
Chorea
Peculiar
Died young
Seen
No consanguinity

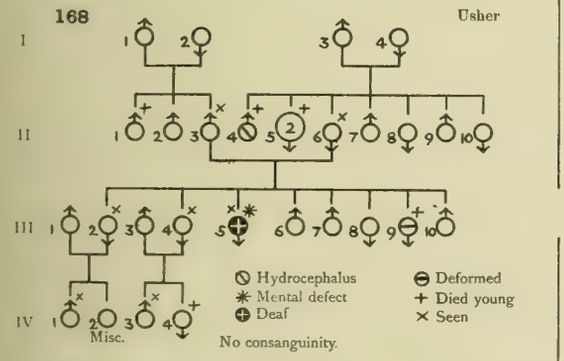
168
Usher
Hydrocephalus
Mental defect
Deaf
Deformed
Died young
Seen
Misc.
No consanguinity.

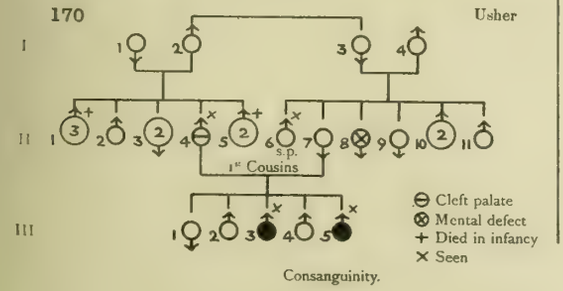
170
Usher
s.p.
1st Cousins
Cleft palate
Mental defect
Died in infancy
Seen
Consanguinity.

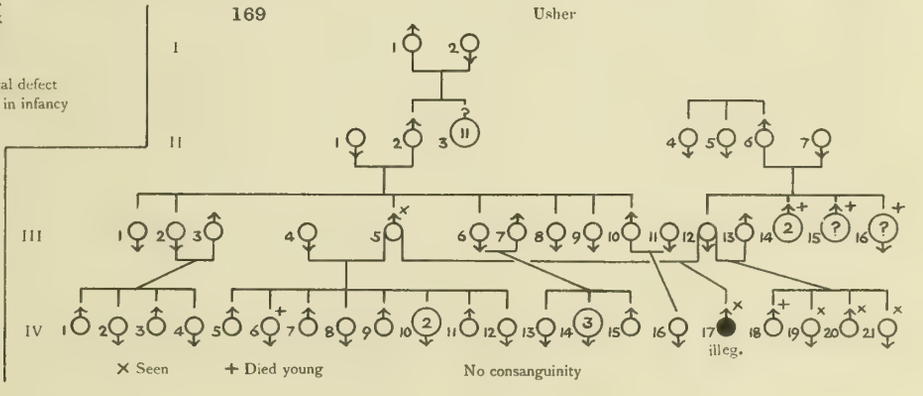
169
Usher
Seen
Died young
No consanguinity
illeg.

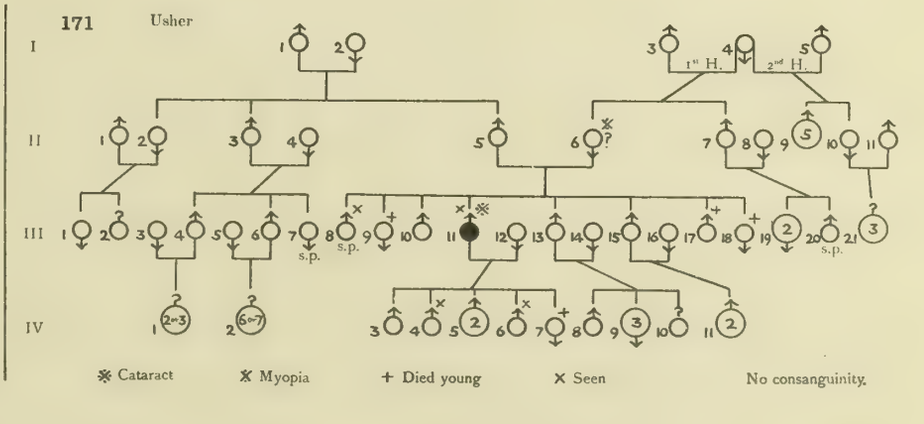
171
Usher
1st H.
2nd H.
s.p.
Cataract
Myopia
Died young
Seen
No consanguinity.

172 Usher

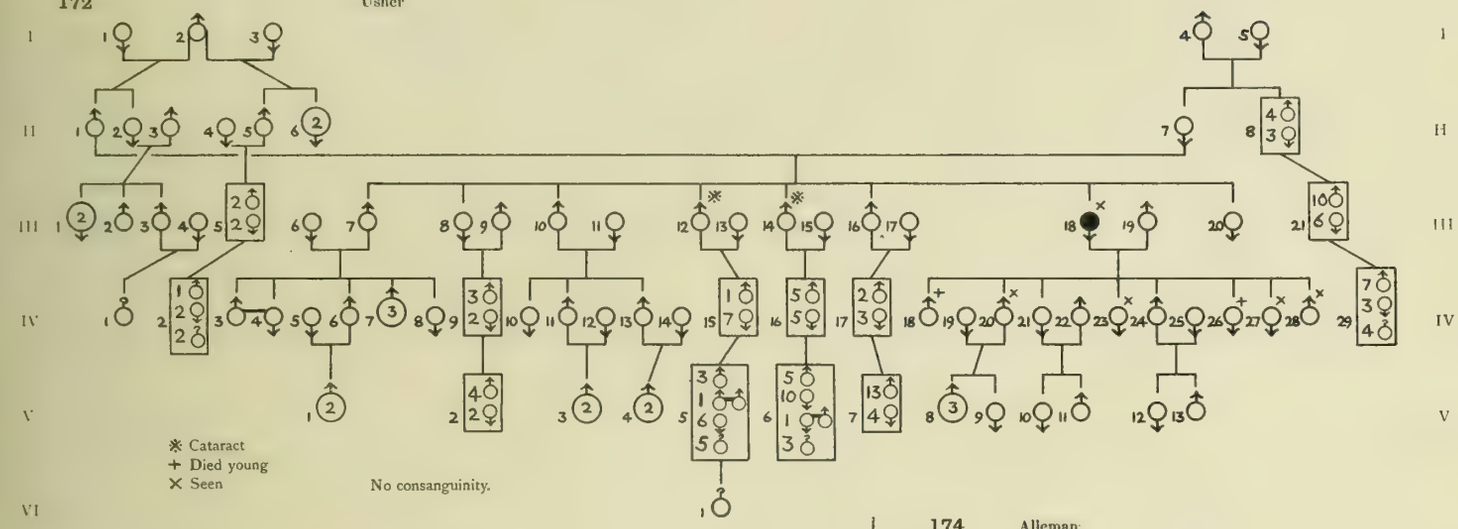

173 Usher

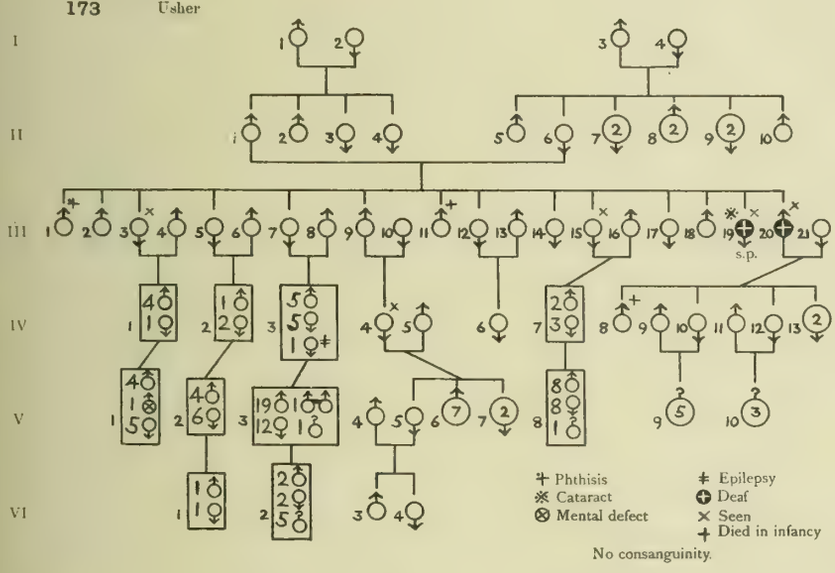

174 Alleman

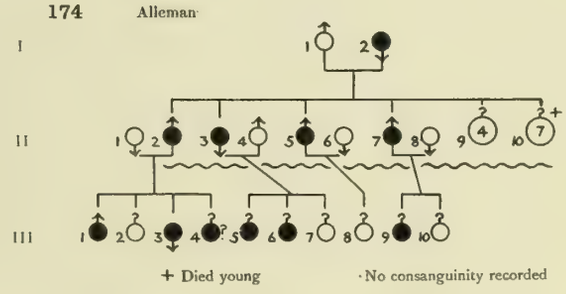

175 Machek

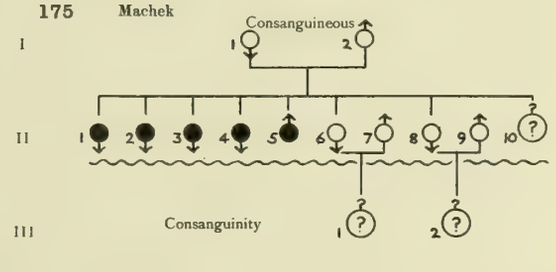

176 Aubineau

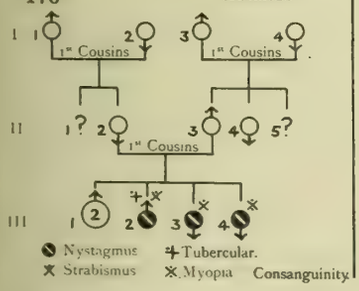

177 Chaillous

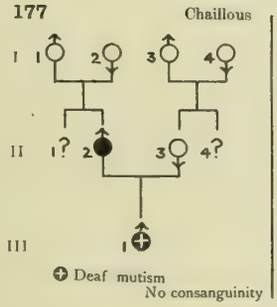

178 Cousins van der Hoeve

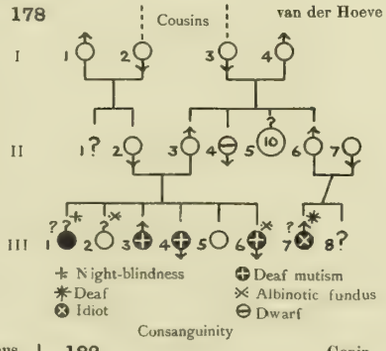

179 Chaillous

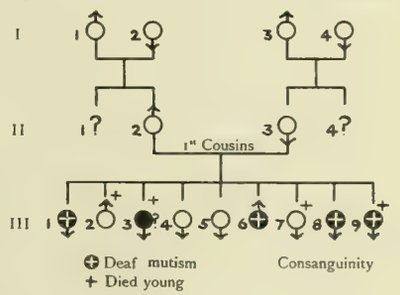

180 Derigs

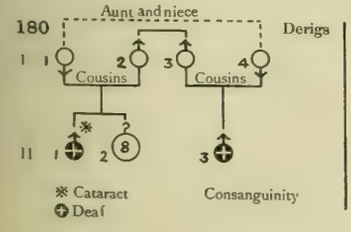

181 Magnus

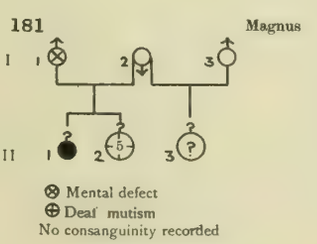

182 Gonin

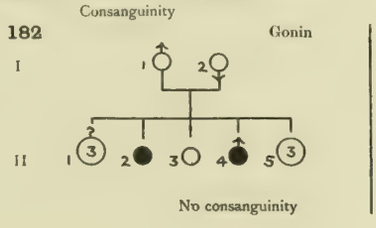

183 Bayer and Derigs

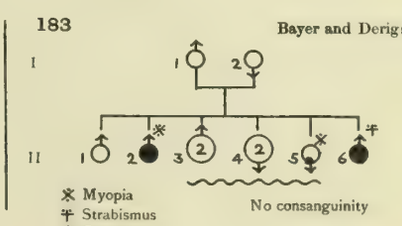

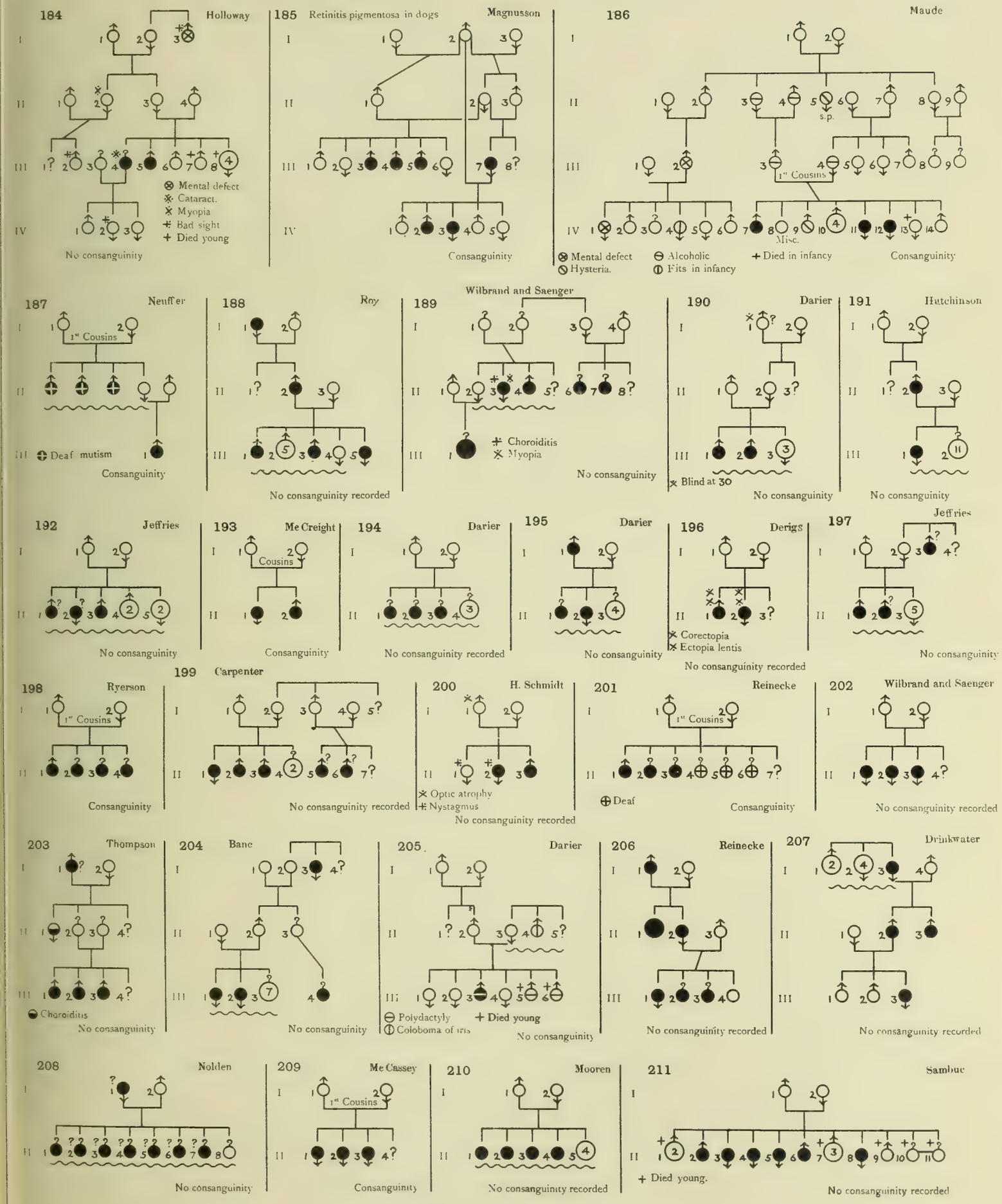
184 Holloway
⊗ Mental defect
✳ Cataract.
✕ Myopia
⫩ Bad sight
+ Died young
No consanguinity
185 Retinitis pigmentosa in dogs Magnusson
Consanguinity
186 Maude
s.p.
1st Cousins
Misc.
⊗ Mental defect
⊖ Alcoholic
+ Died in infancy
⊘ Hysteria.
◐ Fits in infancy
Consanguinity
187 Neuffer
1st Cousins
⊕ Deaf mutism
Consanguinity
188 Roy
No consanguinity recorded
189 Wilbrand and Saenger
⫩ Choroiditis
✕ Myopia
No consanguinity
190 Darier
✕ Blind at 30
No consanguinity
191 Hutchinson
No consanguinity
192 Jeffries
No consanguinity
193 Mc Creight
Cousins
Consanguinity
194 Darier
No consanguinity recorded
195 Darier
No consanguinity
196 Derigs
✕ Corectopia
✕ Ectopia lentis
No consanguinity recorded
197 Jeffries
No consanguinity
198 Ryerson
1st Cousins
Consanguinity
199 Carpenter
No consanguinity recorded
200 H. Schmidt
✕ Optic atrophy
⫩ Nystagmus
No consanguinity recorded
201 Reinecke
1st Cousins
⊕ Deaf
Consanguinity
202 Wilbrand and Saenger
No consanguinity recorded
203 Thompson
◒ Choroiditis
No consanguinity
204 Banc
No consanguinity
205 Darier
⊖ Polydactyly + Died young
◐ Coloboma of iris
No consanguinity
206 Reinecke
No consanguinity recorded
207 Drinkwater
No consanguinity recorded
208 Nolden
No consanguinity
209 Mc Cassey
1st Cousins
Consanguinity
210 Mooren
No consanguinity recorded
211 Sambuc
+ Died young.
No consanguinity recorded

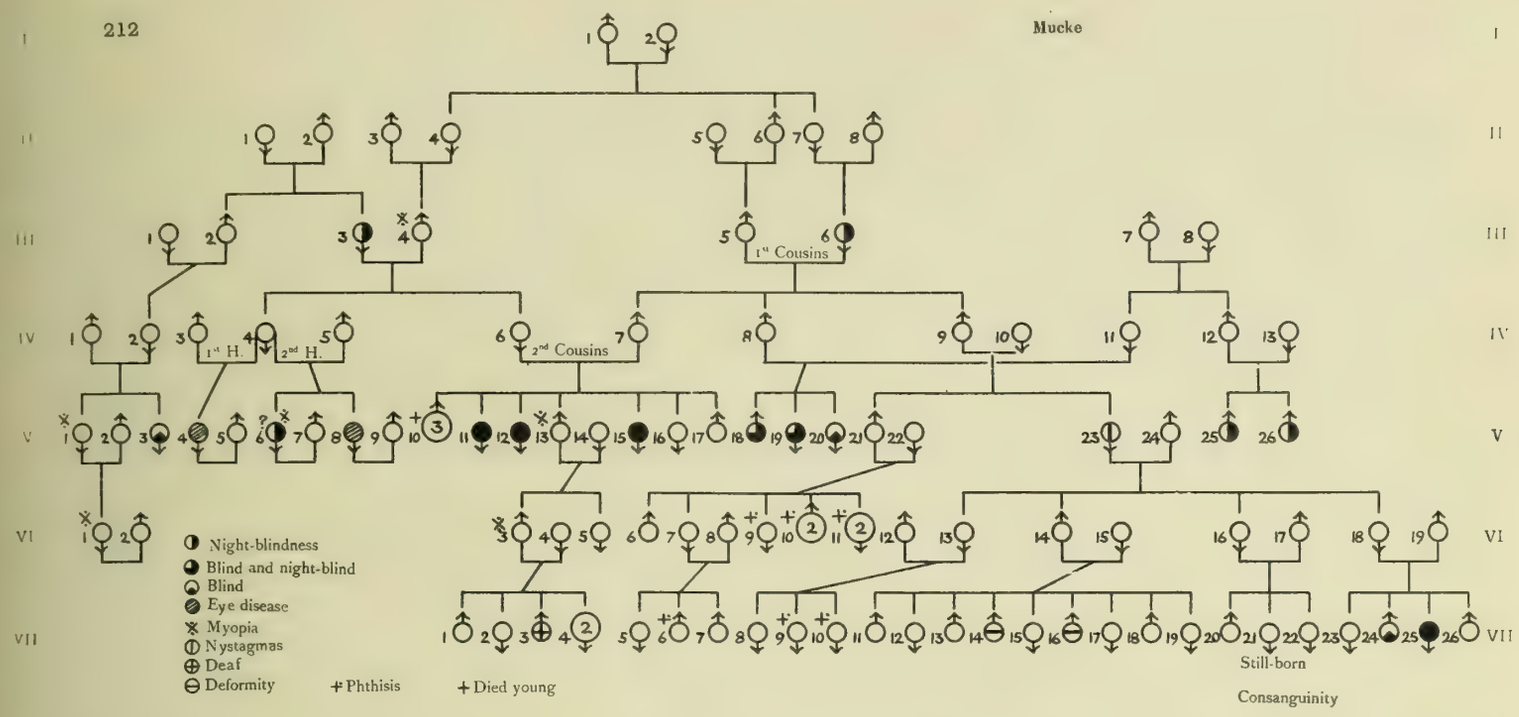
212
Mucke
1st Cousins
1st H.
2nd H.
2nd Cousins
Night-blindness
Blind and night-blind
Blind
Eye disease
Myopia
Nystagmus
Deaf
Deformity
+ Phthisis
+ Died young
Still-born
Consanguinity

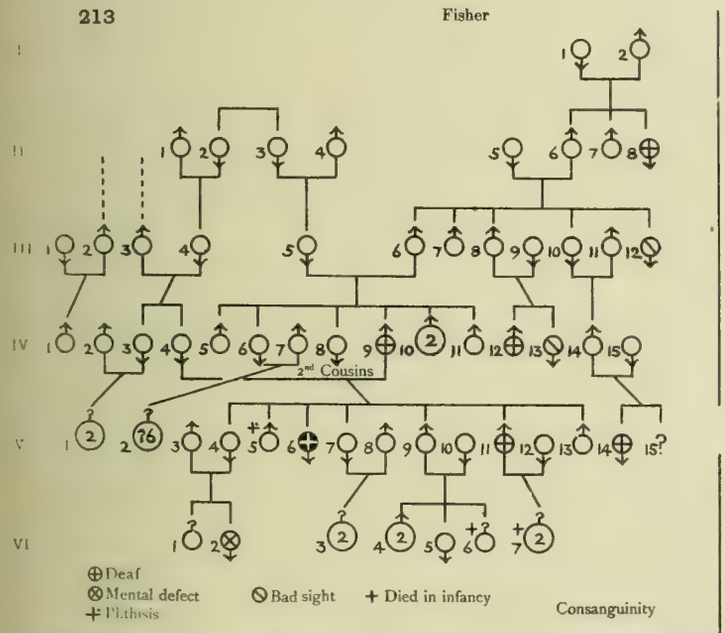
213
Fisher
2nd Cousins
Deaf
Mental defect
Phthisis
Bad sight
+ Died in infancy
Consanguinity

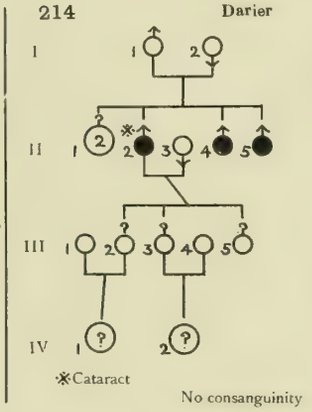
214
Darier
Cataract
No consanguinity

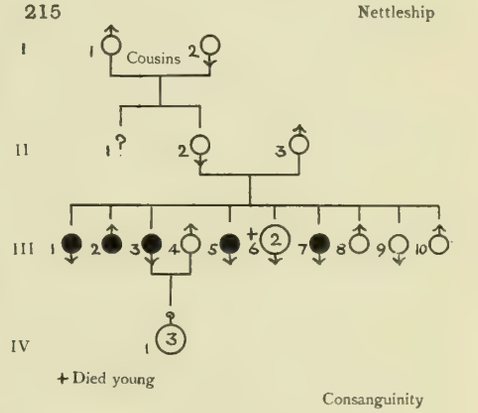
215
Nettleship
Cousins
+ Died young
Consanguinity

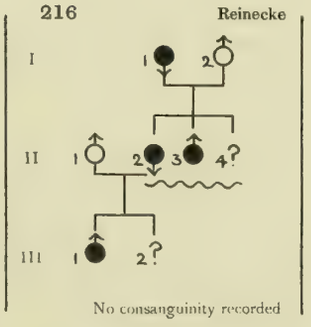
216
Reinecke
No consanguinity recorded

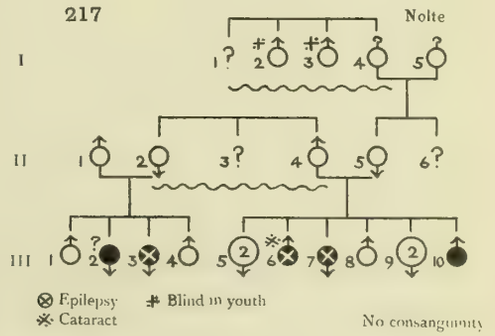
217
Nolte
Epilepsy
Blind in youth
Cataract
No consanguinity

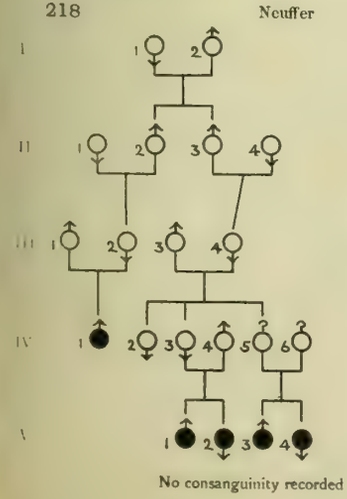
218
Neuffer
No consanguinity recorded

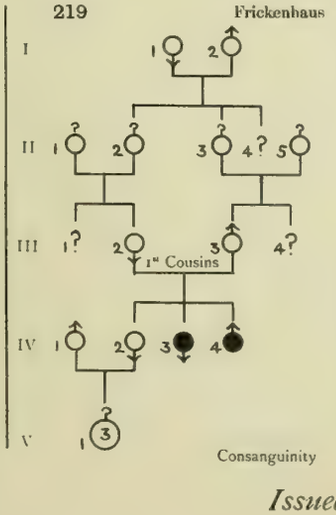
219
Frickenhaus
1st Cousins
Consanguinity

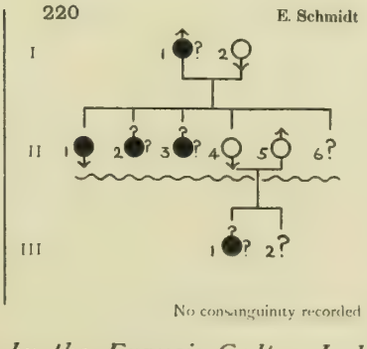
220
E. Schmidt
No consanguinity recorded

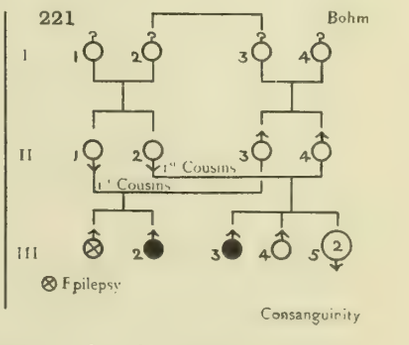
221
Bohm
1st Cousins
1st Cousins
Epilepsy
Consanguinity

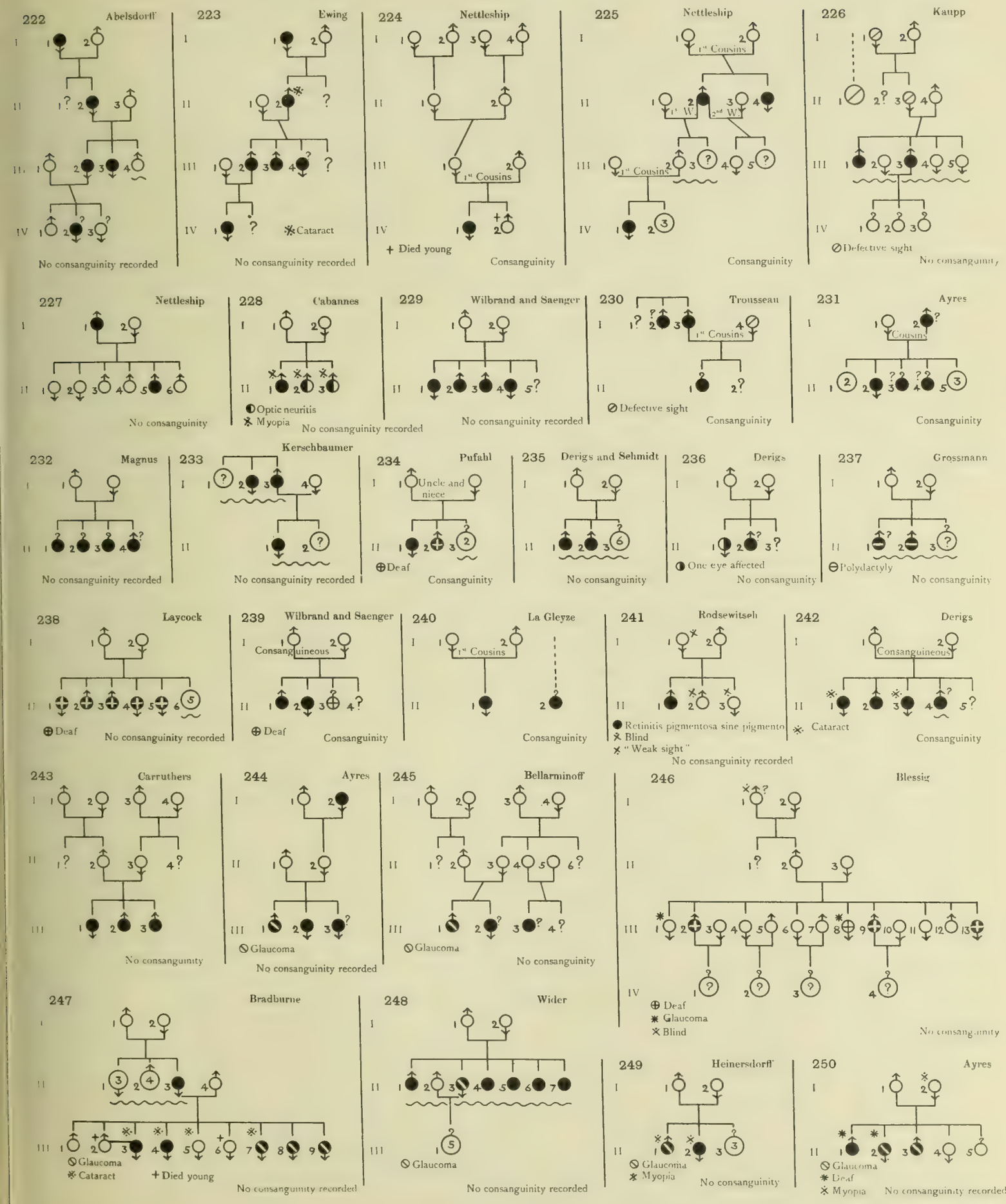

Issued by the Francis Galton Laboratory for National Eugenics.

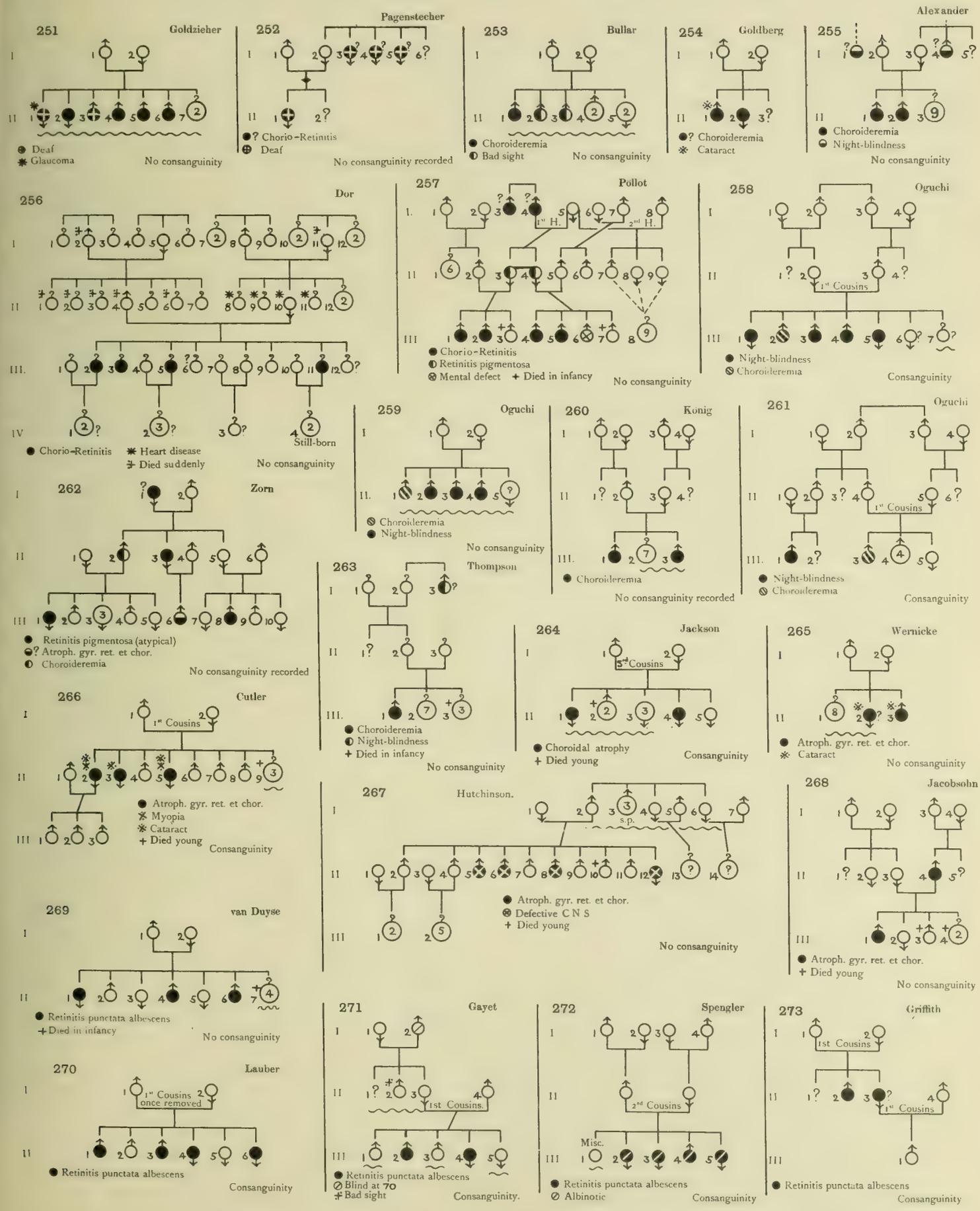
251 Goldzieher
Deaf
Glaucoma
No consanguinity
252 Pagenstecher
? Chorio-Retinitis
Deaf
No consanguinity recorded
253 Bullar
Choroideremia
Bad sight
No consanguinity
254 Goldberg
? Choroideremia
Cataract
255 Alexander
Choroideremia
Night-blindness
No consanguinity
256 Dor
Chorio-Retinitis
Heart disease
Died suddenly
Still-born
No consanguinity
257 Pöllot
1st H.
2nd H.
Chorio-Retinitis
Retinitis pigmentosa
Mental defect
Died in infancy
No consanguinity
258 Oguchi
1st Cousins
Night-blindness
Choroideremia
Consanguinity
259 Oguchi
Choroideremia
Night-blindness
No consanguinity
260 Konig
Choroideremia
No consanguinity recorded
261 Oguchi
1st Cousins
Night-blindness
Choroideremia
Consanguinity
262 Zorn
Retinitis pigmentosa (atypical)
? Atroph. gyr. ret. et chor.
Choroideremia
No consanguinity recorded
263 Thompson
Choroideremia
Night-blindness
Died in infancy
No consanguinity
264 Jackson
5th Cousins
Choroidal atrophy
Died young
Consanguinity
265 Wernicke
Atroph. gyr. ret. et chor.
Cataract
No consanguinity
266 Cutler
1st Cousins
Atroph. gyr. ret. et chor.
Myopia
Cataract
Died young
Consanguinity
267 Hutchinson.
s.p.
Atroph. gyr. ret. et chor.
Defective C N S
Died young
No consanguinity
268 Jacobsohn
Atroph. gyr. ret. et chor.
Died young
No consanguinity
269 van Duyse
Retinitis punctata albescens
Died in infancy
No consanguinity
270 Lauber
1st Cousins once removed
Retinitis punctata albescens
Consanguinity
271 Gayet
1st Cousins.
Retinitis punctata albescens
Blind at 70
Bad sight
Consanguinity.
272 Spengler
2nd Cousins
Misc.
Retinitis punctata albescens
Albinotic
Consanguinity
273 Griffith
1st Cousins
1st Cousins
Retinitis punctata albescens
Consanguinity

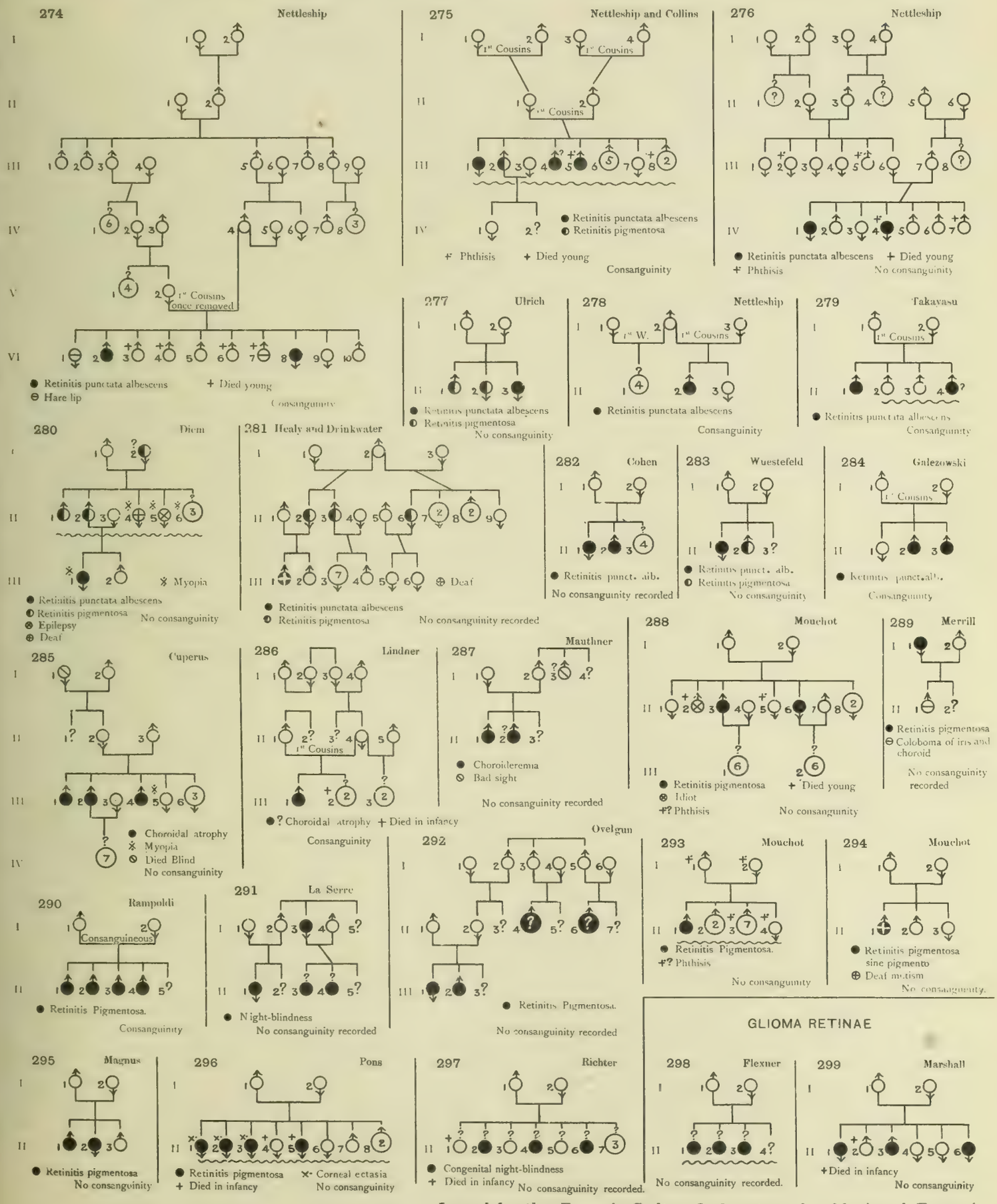

Issued by the Francis Galton Laboratory for National Eugenics.

300 Sinclair

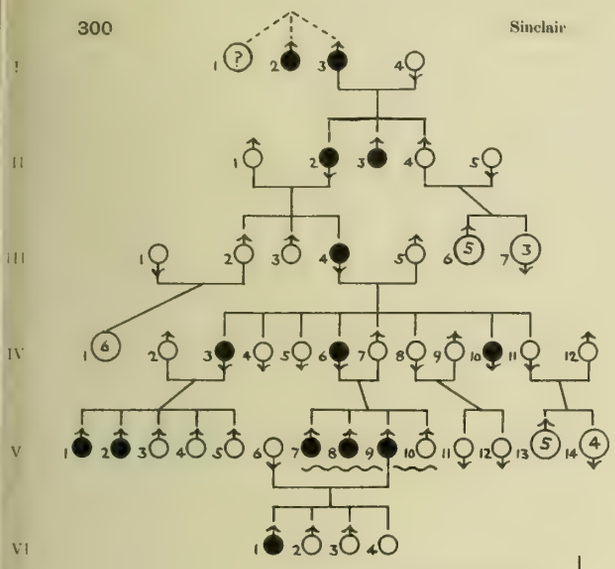

No consanguinity

301 Sedan

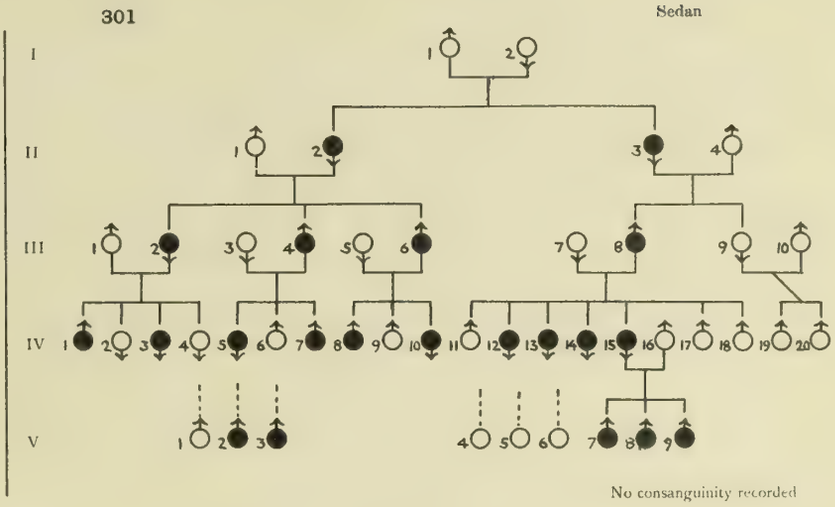

No consanguinity recorded

302 Cutler

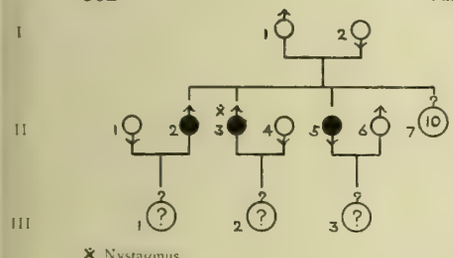

✻ Nystagmus

No consanguinity

303 Fuchs

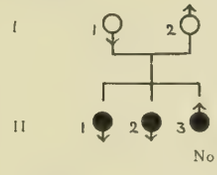

No consanguinity

304 Hudson

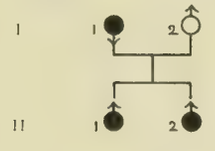

No consanguinity

305 Stiévenart

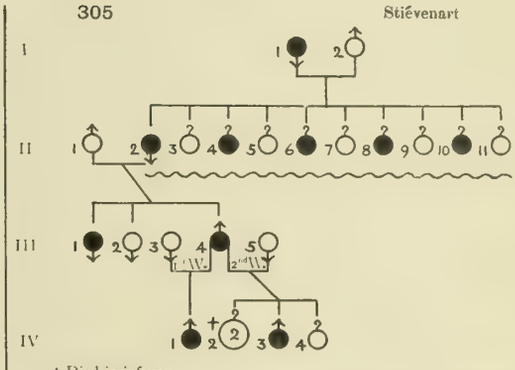

+ Died in infancy

No consanguinity recorded

306 Cutler

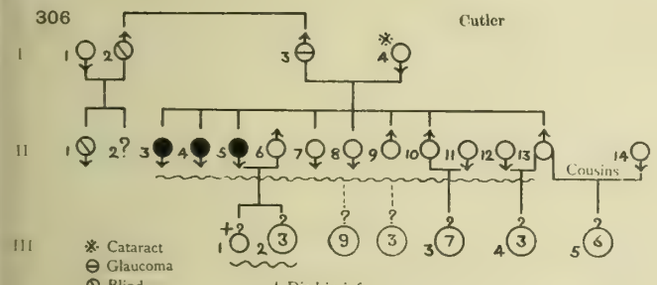

✻ Cataract
⊖ Glaucoma
⊘ Blind
+ Died in infancy

Consanguinity

307 Fuchs

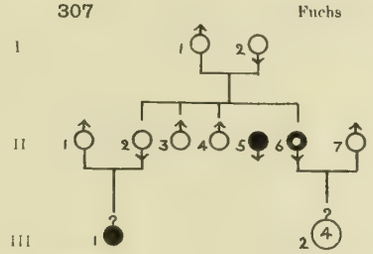

⊙ Myopia

No consanguinity

308 Atwool

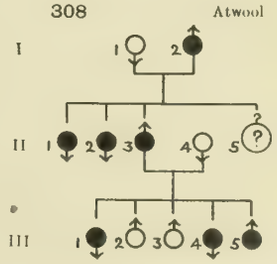

No consanguinity recorded

309 Langdon

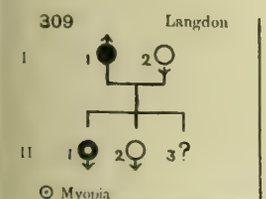

⊙ Myopia

No consanguinity recorded

310 Fitzgerald

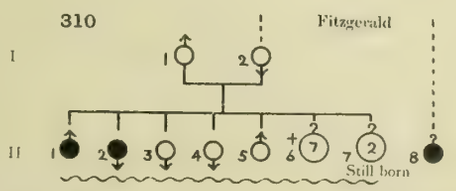

+ Died young

No consanguinity

311 Cant

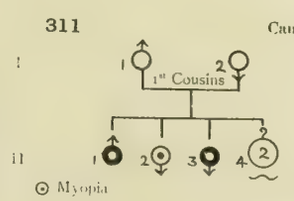

⊙ Myopia

Consanguinity

312 Nettleship

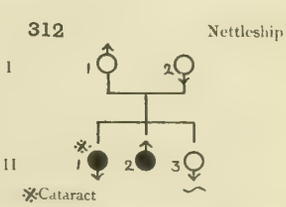

✻ Cataract

No consanguinity recorded

313 Fuchs

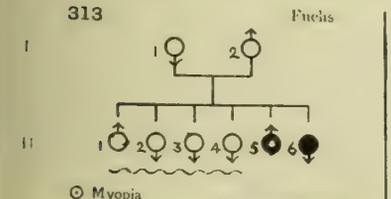

⊙ Myopia

No consanguinity

314 Bessonnet

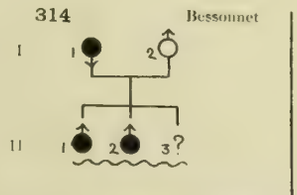

No consanguinity recorded

315 Viensse

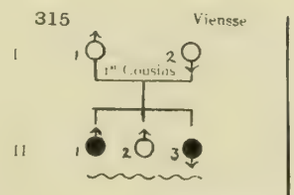

Consanguinity

316 Swanzy

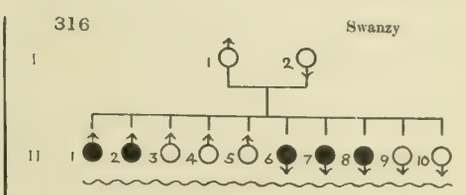

No consanguinity

317

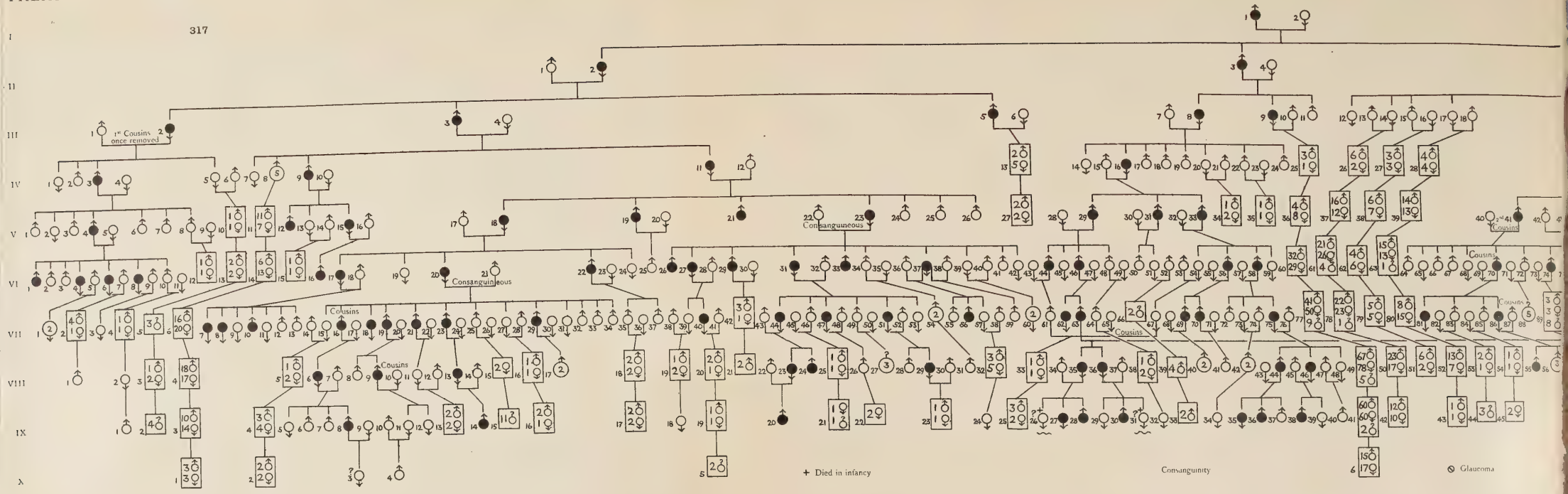

320

Nettleship and Stanford Morton

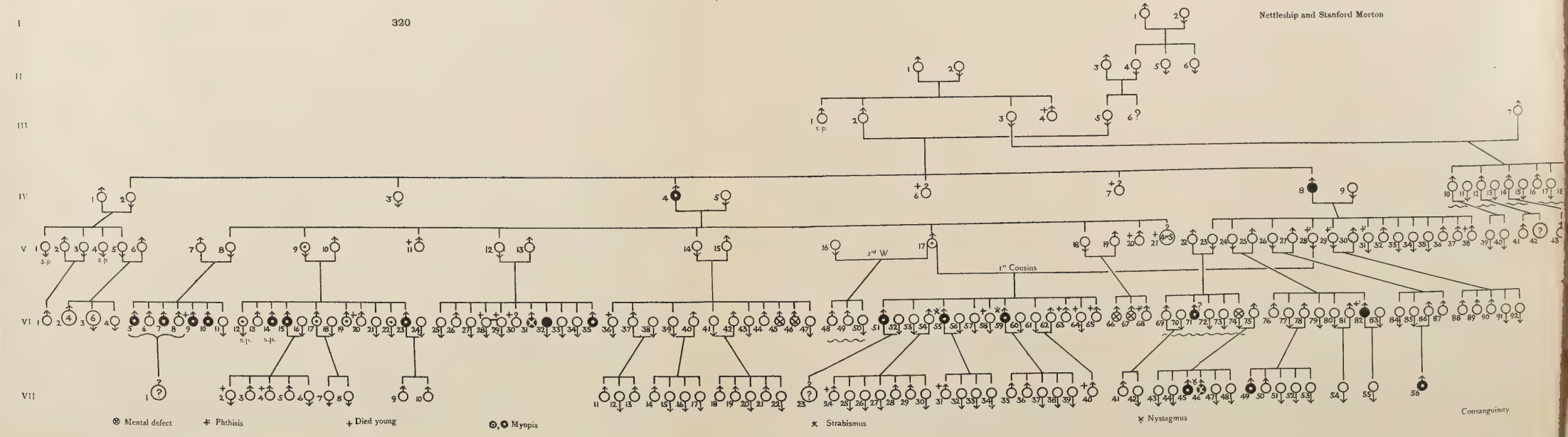

Cunier, True and Nettleship

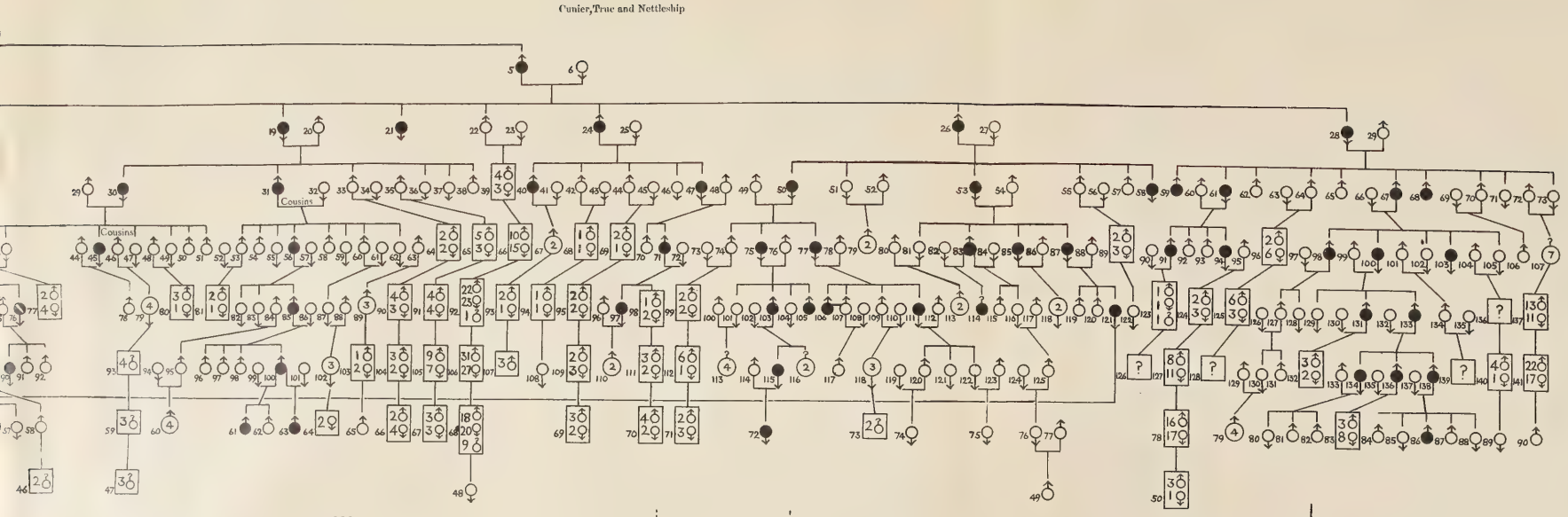

318 Pagenstecher

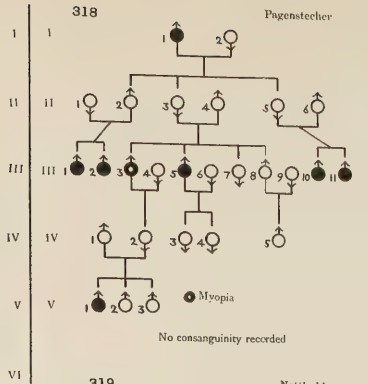

No consanguinity recorded

319 Nettleship

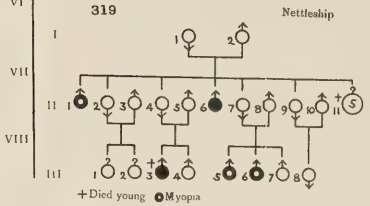

No consanguinity

321 Newman

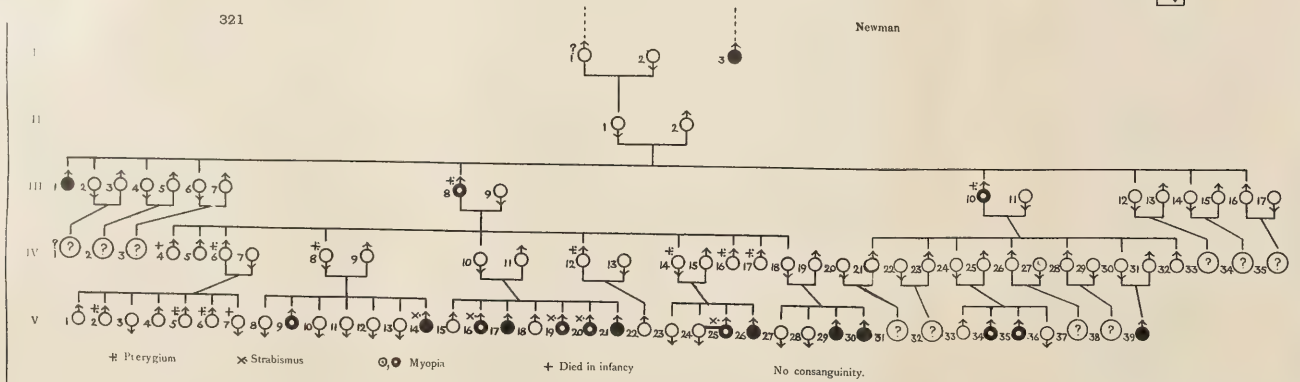

No consanguinity.

322 Caut

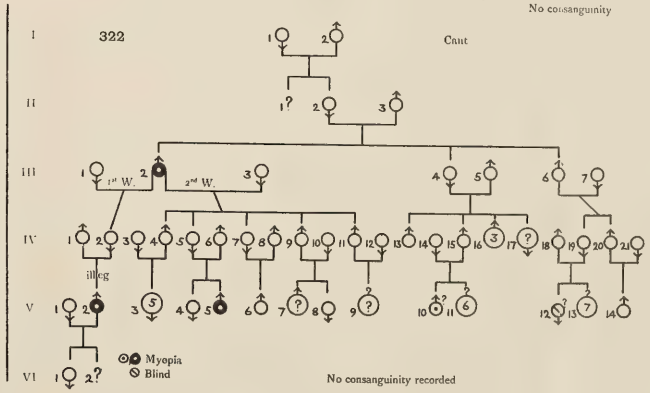

No consanguinity recorded

323 Nettleship

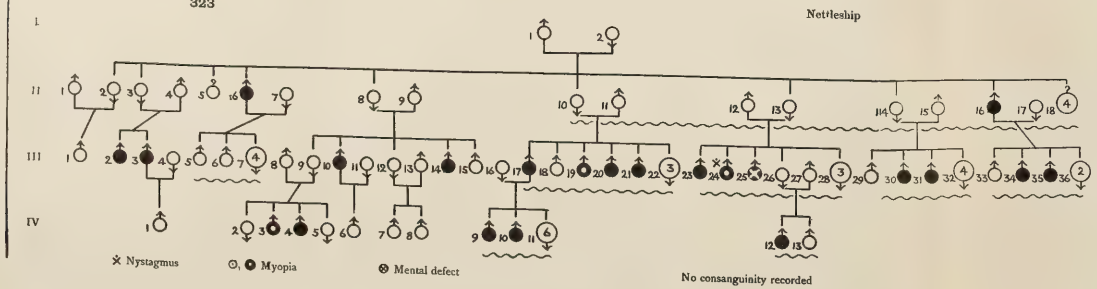

No consanguinity recorded

324 Nettleship

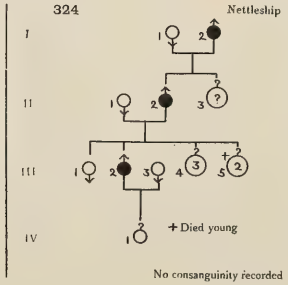

No consanguinity recorded

325 Cutler

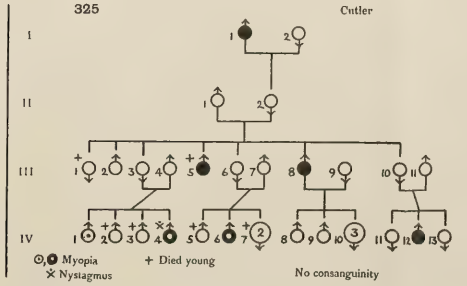

No consanguinity

Issued by the Francis Galton Laboratory for National Eugenics.

326 Pflüger

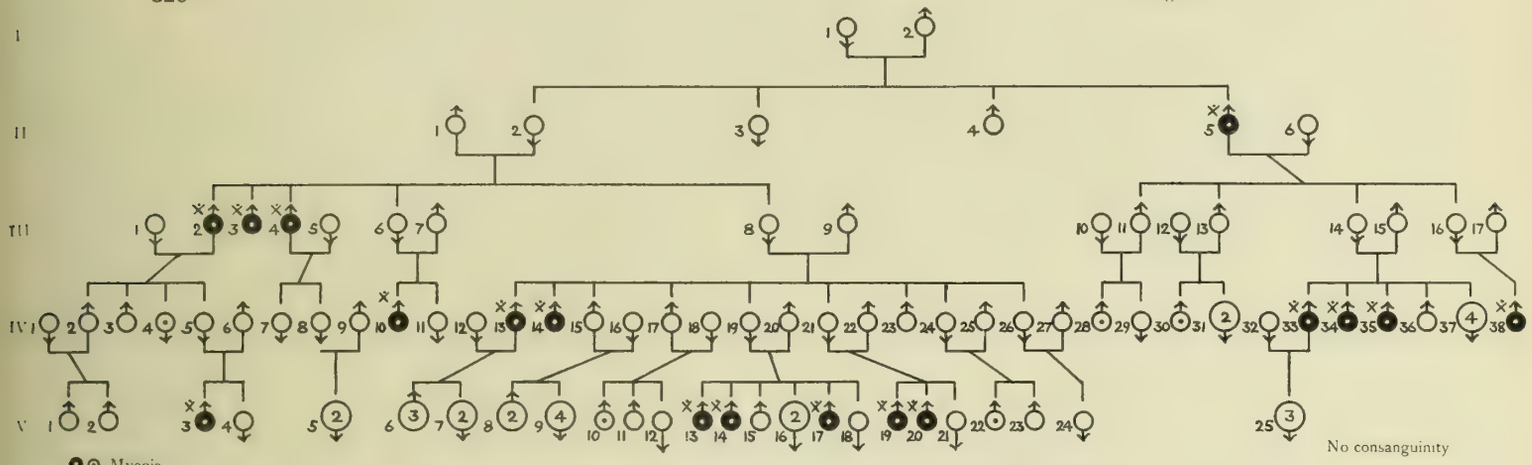

327 Nettleship

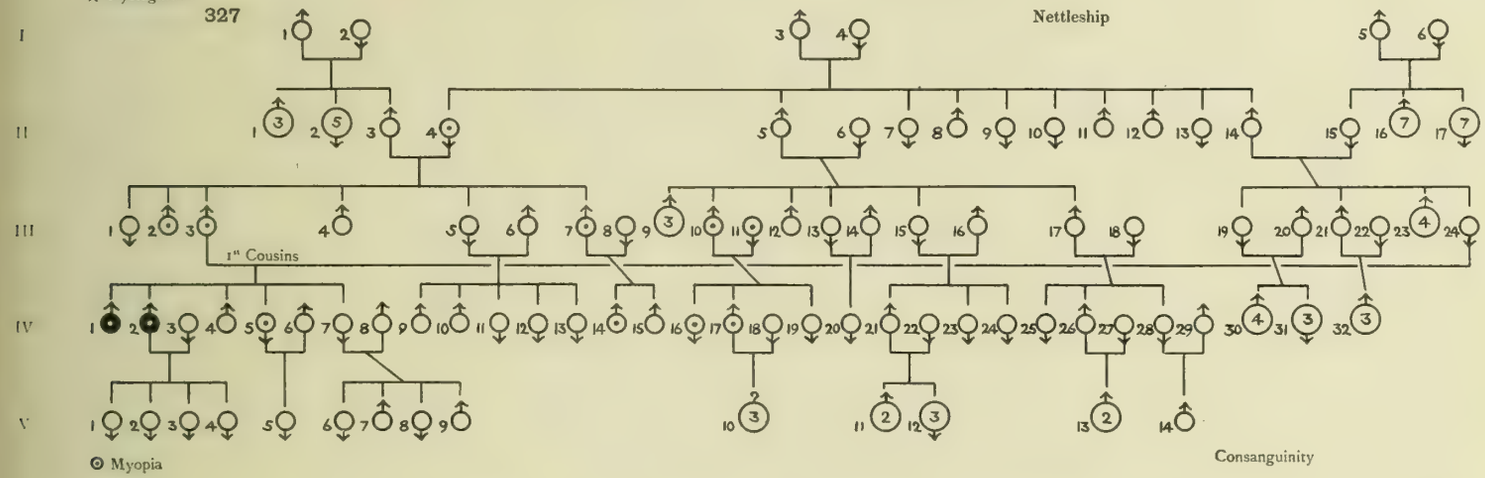

328 Fuchs

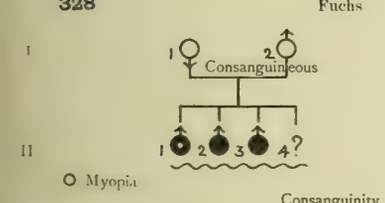

329 Förster

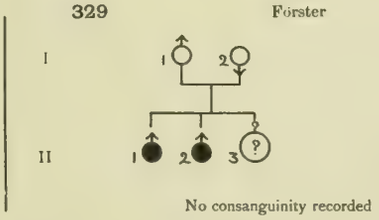

330 Donders and Maes

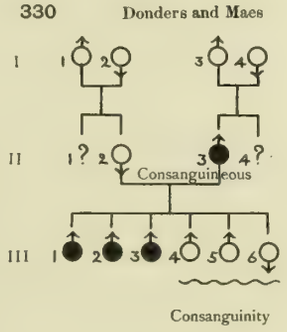

331 Maes

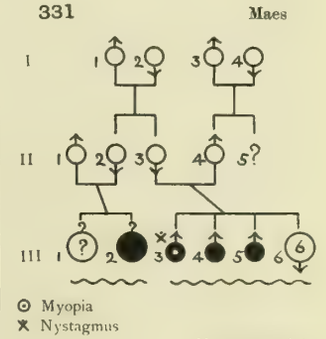

332 Ammann

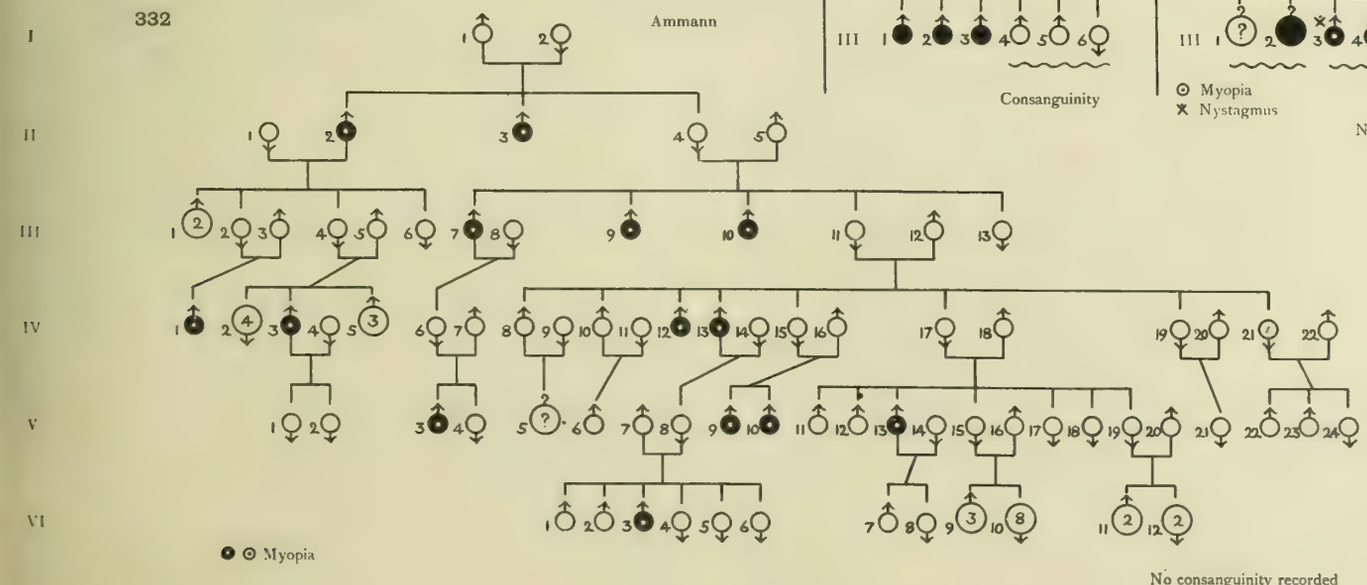

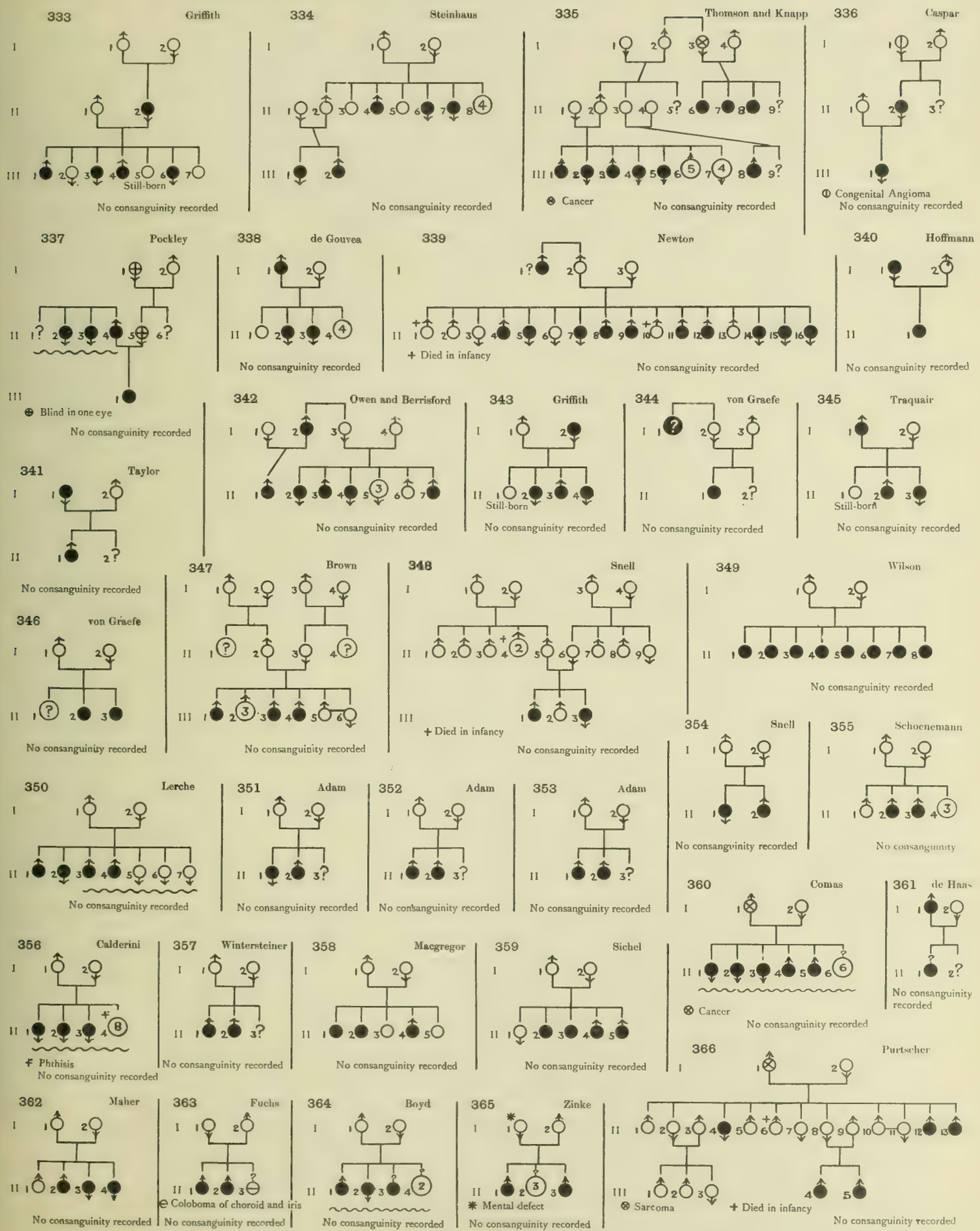
333 Griffith
Still-born
No consanguinity recorded
334 Steinhaus
No consanguinity recorded
335 Thomson and Knapp
⊛ Cancer
No consanguinity recorded
336 Caspar
① Congenital Angioma
No consanguinity recorded
337 Pockley
⊕ Blind in one eye
No consanguinity recorded
338 de Gouvea
No consanguinity recorded
339 Newton
+ Died in infancy
No consanguinity recorded
340 Hoffmann
No consanguinity recorded
341 Taylor
No consanguinity recorded
342 Owen and Berrisford
No consanguinity recorded
343 Griffith
Still-born
No consanguinity recorded
344 von Graefe
No consanguinity recorded
345 Traquair
Still-born
No consanguinity recorded
346 von Graefe
No consanguinity recorded
347 Brown
No consanguinity recorded
348 Snell
+ Died in infancy
No consanguinity recorded
349 Wilson
No consanguinity recorded
350 Lerche
No consanguinity recorded
351 Adam
No consanguinity recorded
352 Adam
No consanguinity recorded
353 Adam
No consanguinity recorded
354 Snell
No consanguinity recorded
355 Schoenemann
No consanguinity
356 Calderini
∓ Phthisis
No consanguinity recorded
357 Wintersteiner
No consanguinity recorded
358 Macgregor
No consanguinity recorded
359 Sichel
No consanguinity recorded
360 Comas
⊗ Cancer
No consanguinity recorded
361 de Haas
No consanguinity recorded
362 Maher
No consanguinity recorded
363 Fuchs
e Coloboma of choroid and iris
No consanguinity recorded
364 Boyd
No consanguinity recorded
365 Zinke
✱ Mental defect
No consanguinity recorded
366 Purtscher
⊗ Sarcoma
+ Died in infancy
No consanguinity recorded

CONGENITAL TOTAL COLOUR-BLINDNESS.

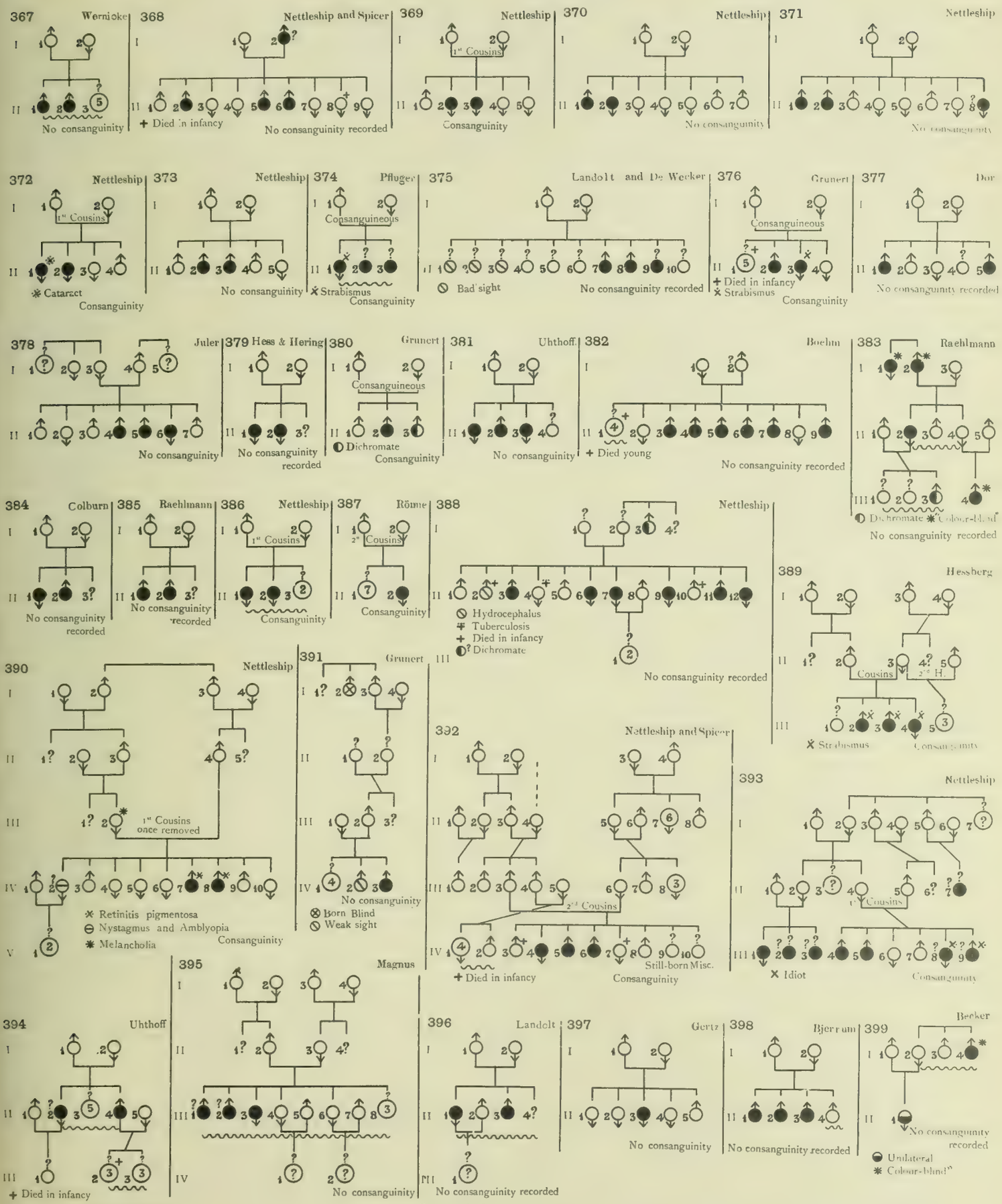

Issued by the Francis Galton Laboratory for National Eugenics.

Total Colour-blindness.

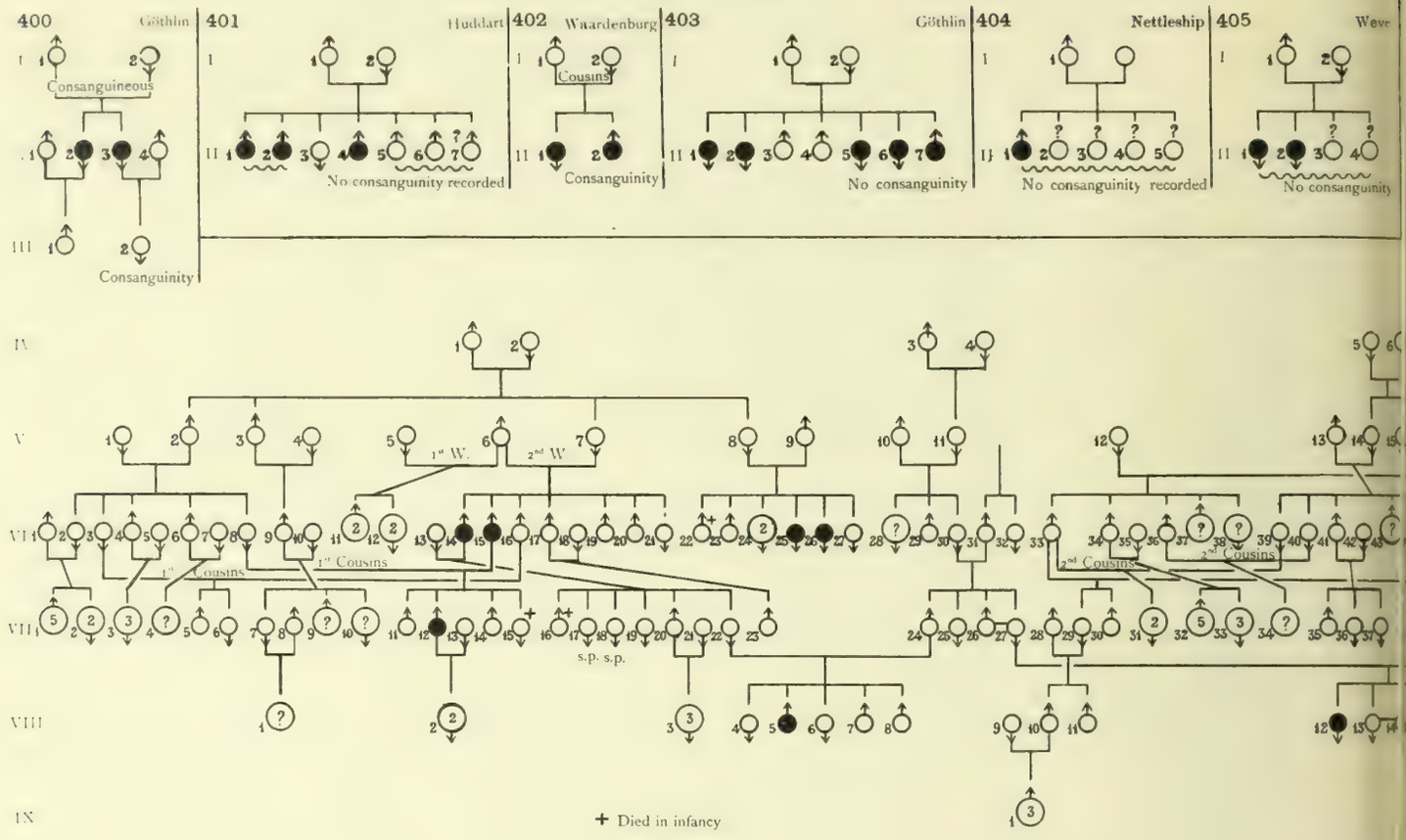

407

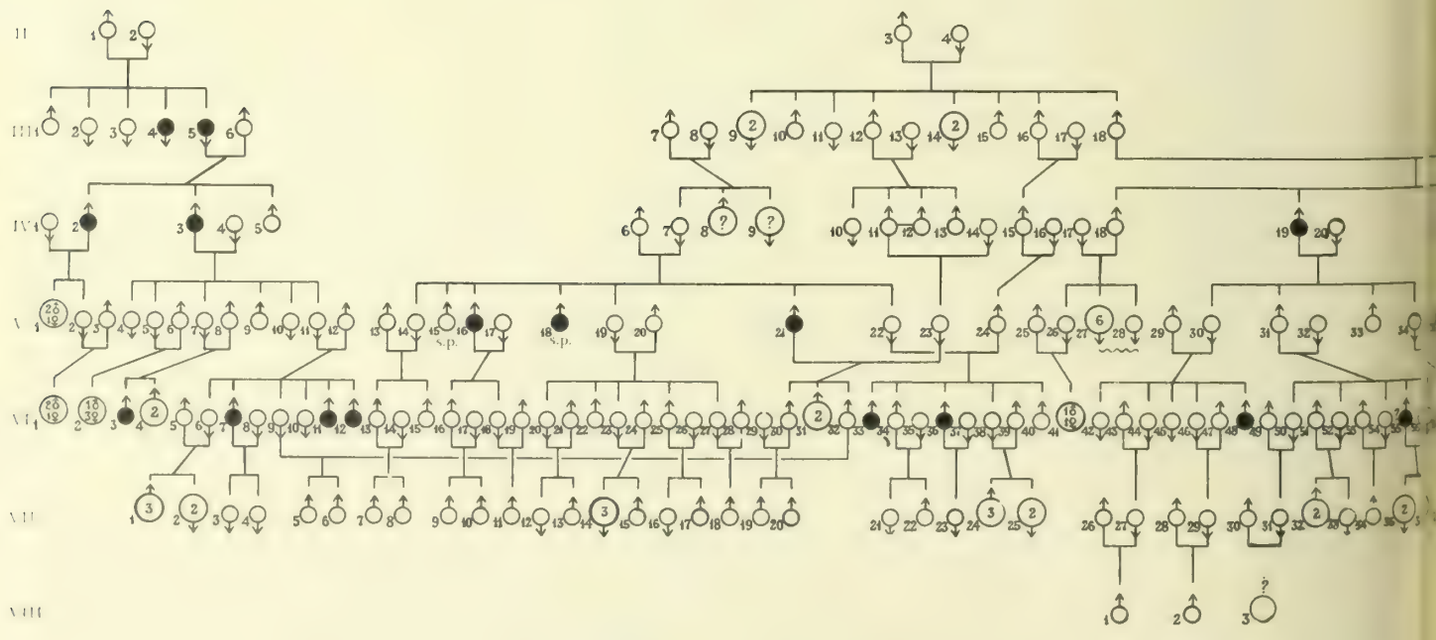

CONGENITAL COLOUR-BLINDNESS.

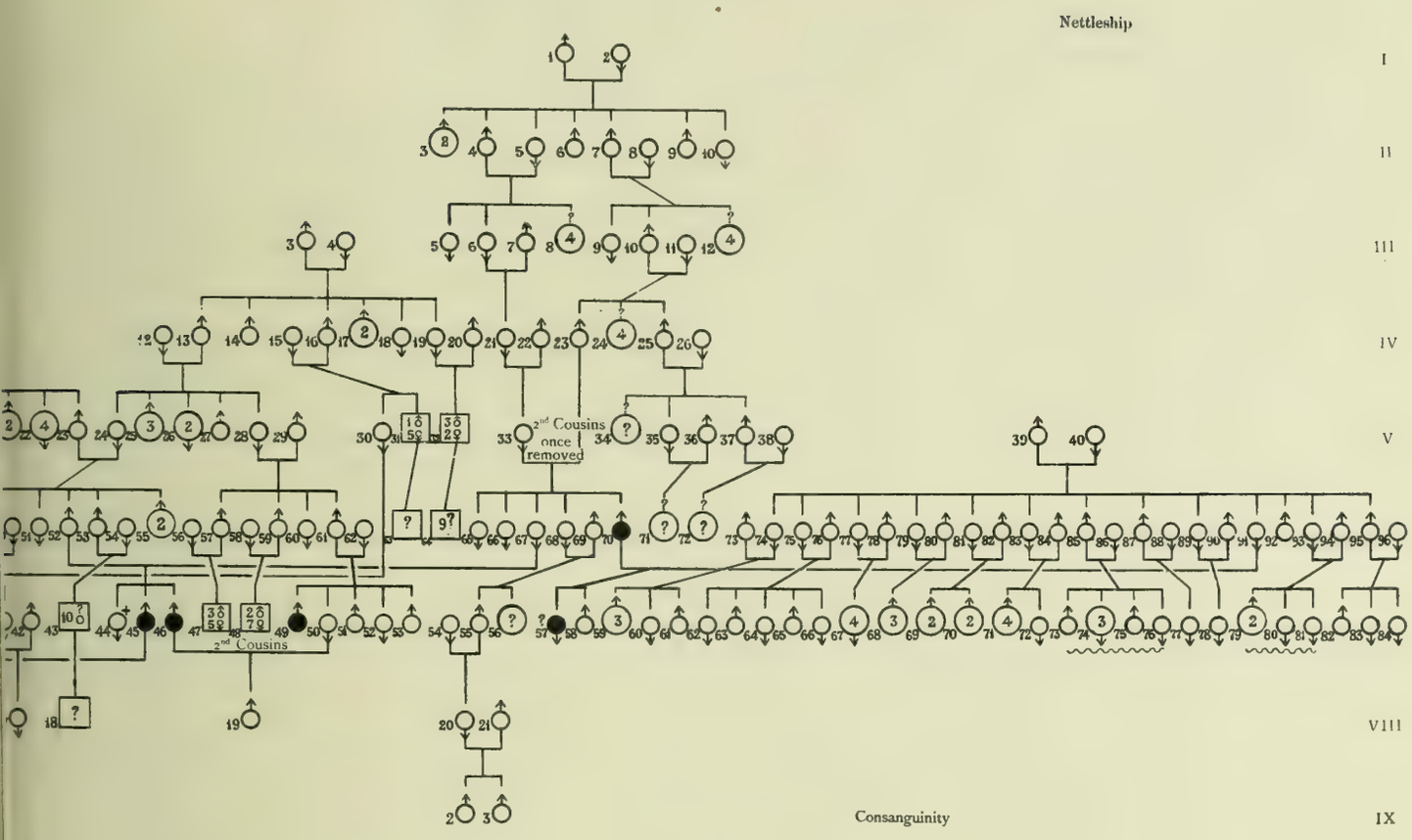

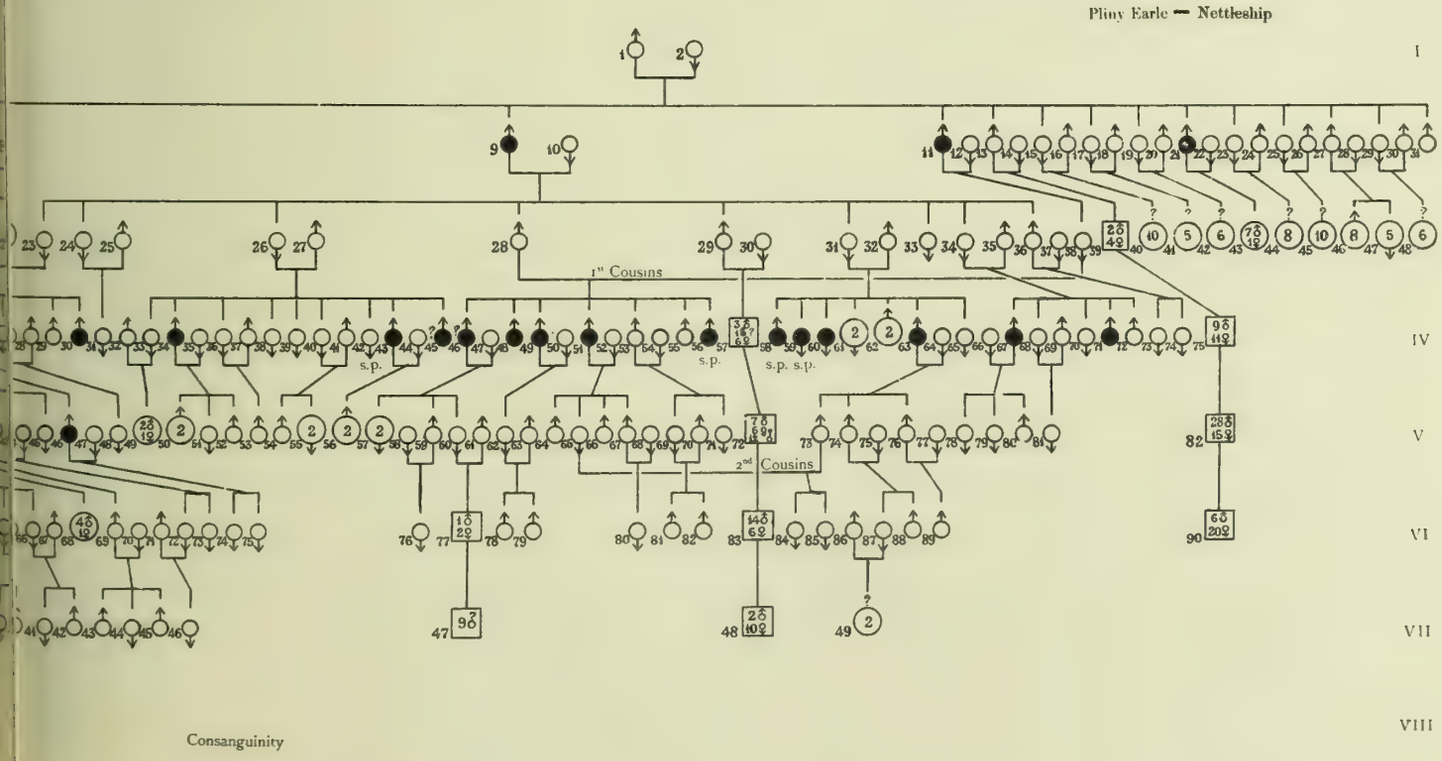

Issued by the Francis Galton Laboratory for National Eugenics.

CONGENITAL COLOUR-BLINDNESS.

408

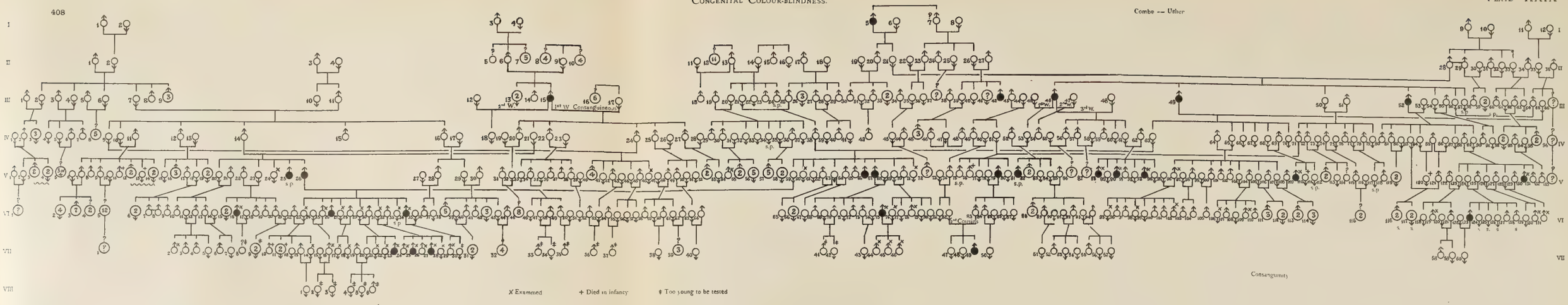

409

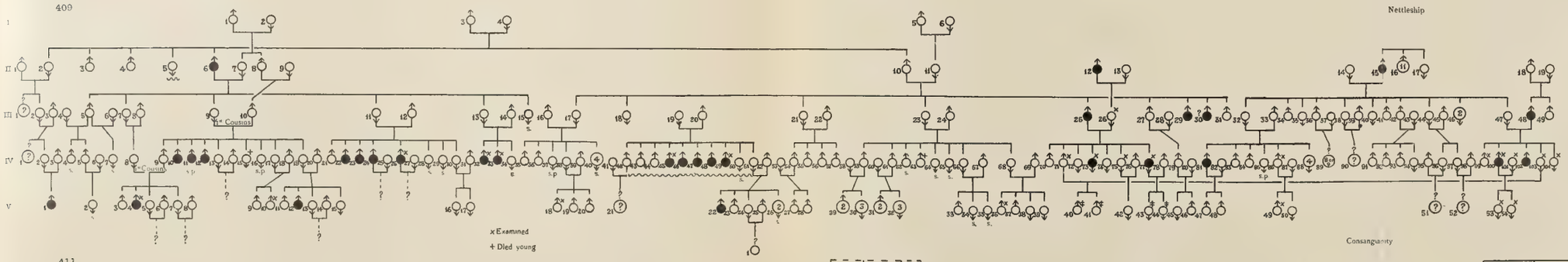

410

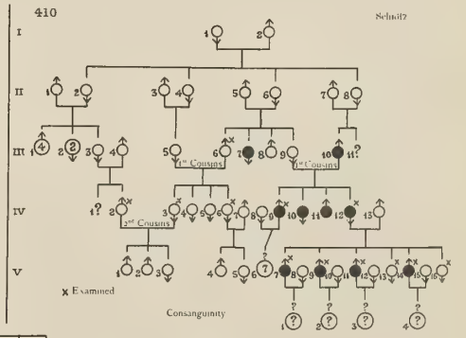

411

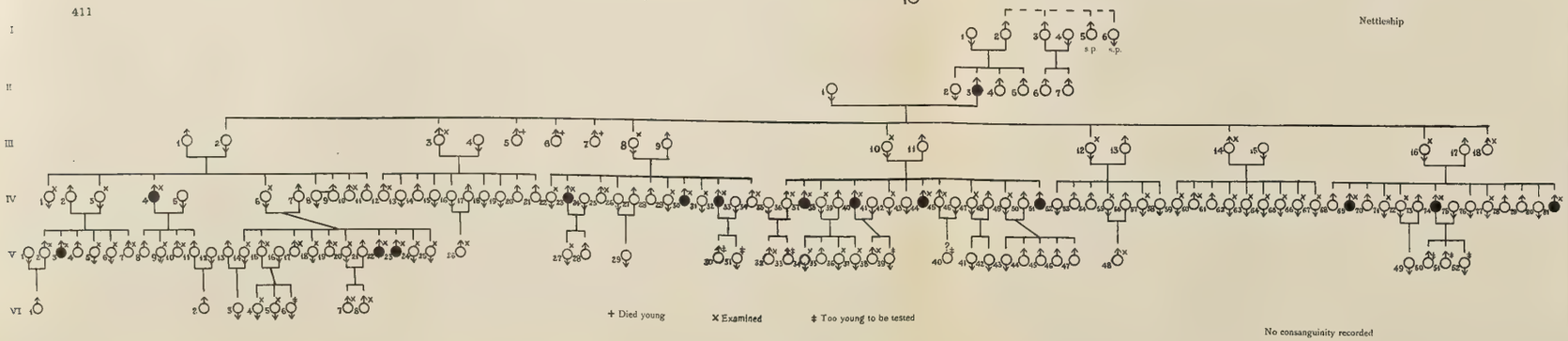

412

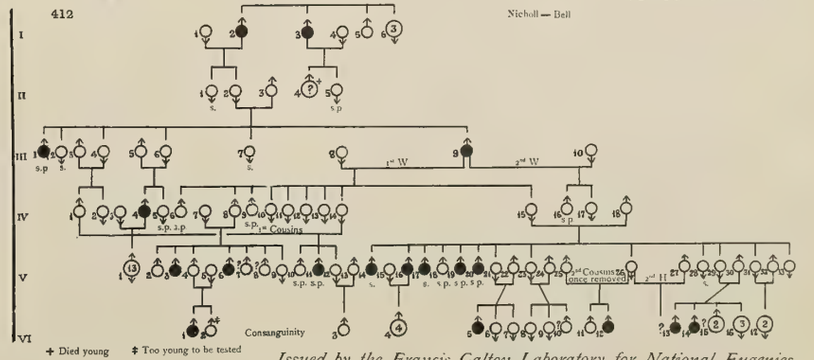

Issued by the Francis Galton Laboratory for National Eugenics.

CONGENITAL COLOUR-BLINDNESS.

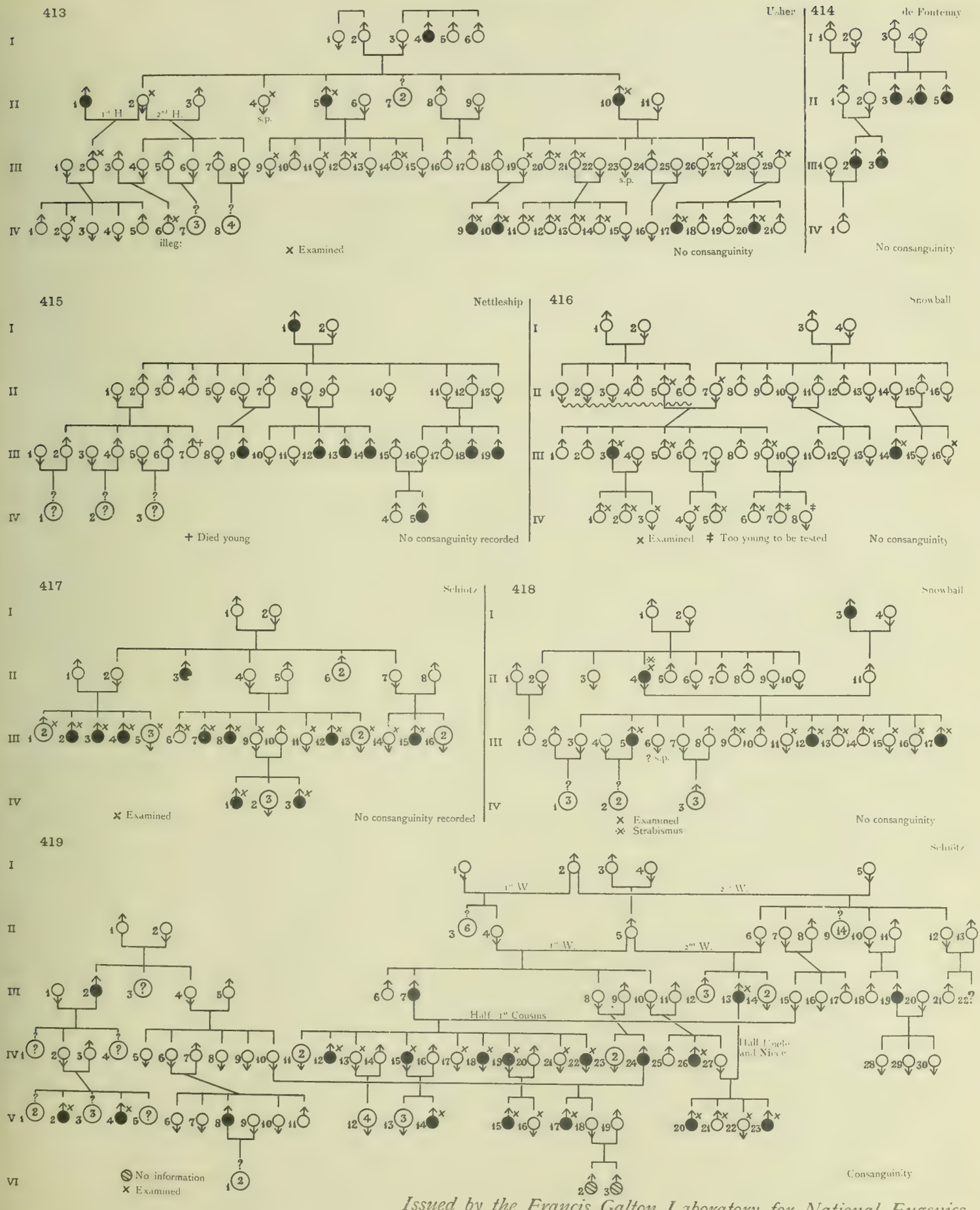

Issued by the Francis Galton Laboratory for National Eugenics.

CONGENITAL COLOUR-BLINDNESS.

420

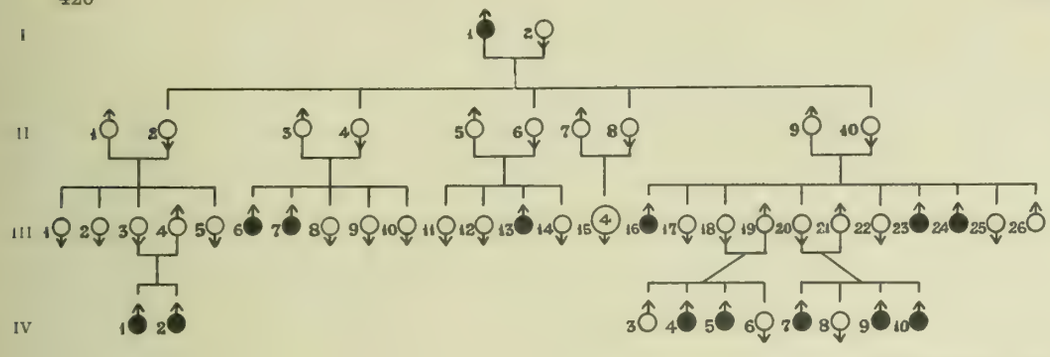

No consanguinity recorded

Horner

421 Nettleship

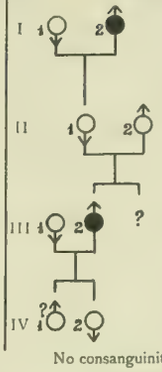

No consanguinity recorded

422 Cohn

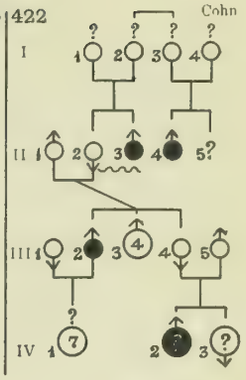

No consanguinity

423 Nettleship

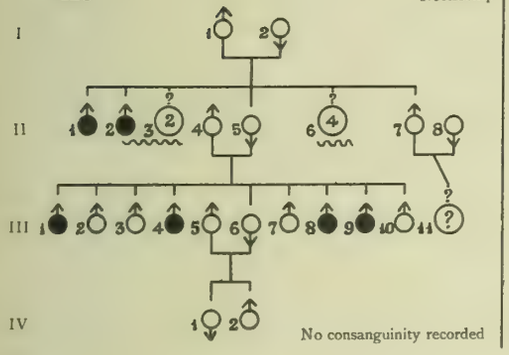

No consanguinity recorded

424 de Fontenay

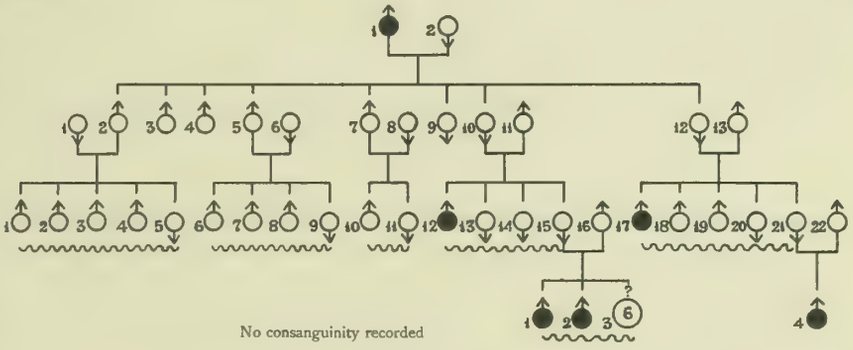

No consanguinity recorded

425 Rivers

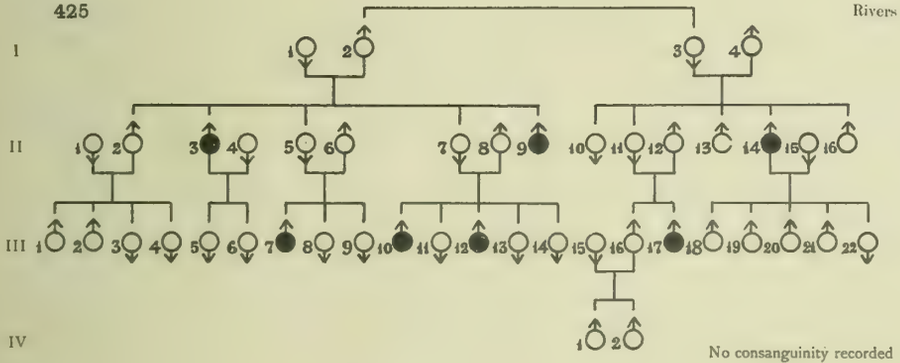

No consanguinity recorded

426 Lutz

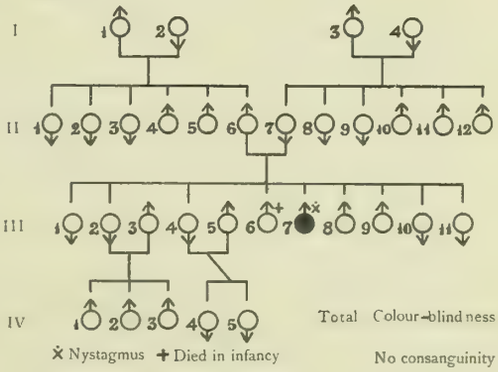

Total Colour-blindness

ẋ Nystagmus + Died in infancy

No consanguinity recorded

427 Burckhardt

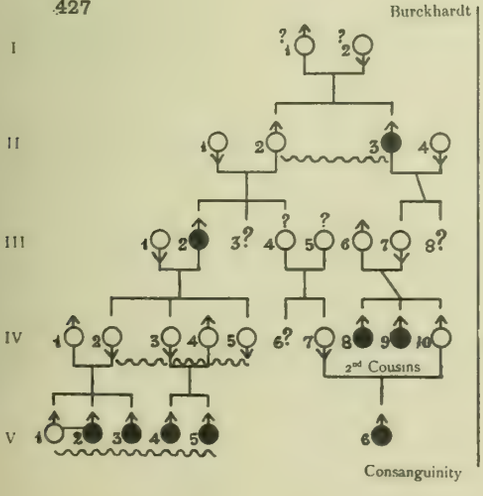

2nd Cousins

Consanguinity

428 Holmgren – Göthlin

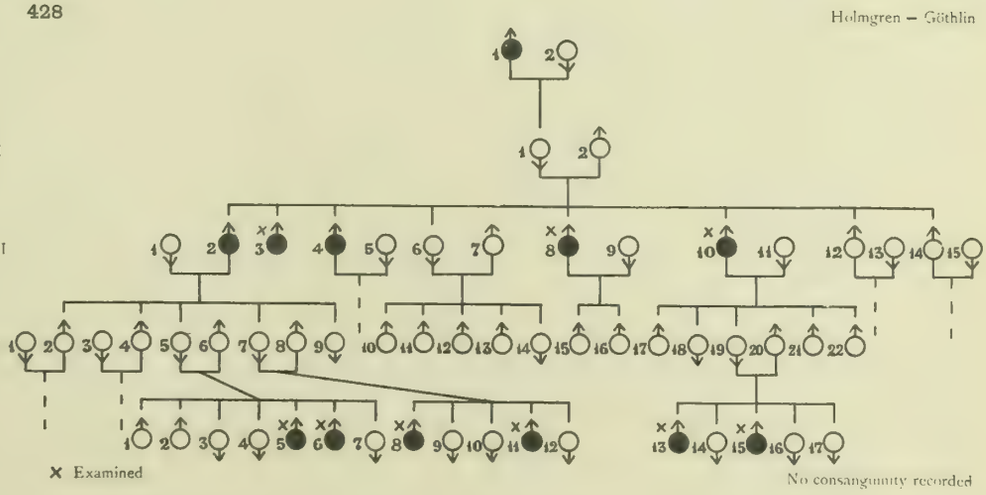

× Examined

No consanguinity recorded

Issued by the Francis Galton Laboratory for National Eugenics.

CONGENITAL COLOUR-BLINDNESS.

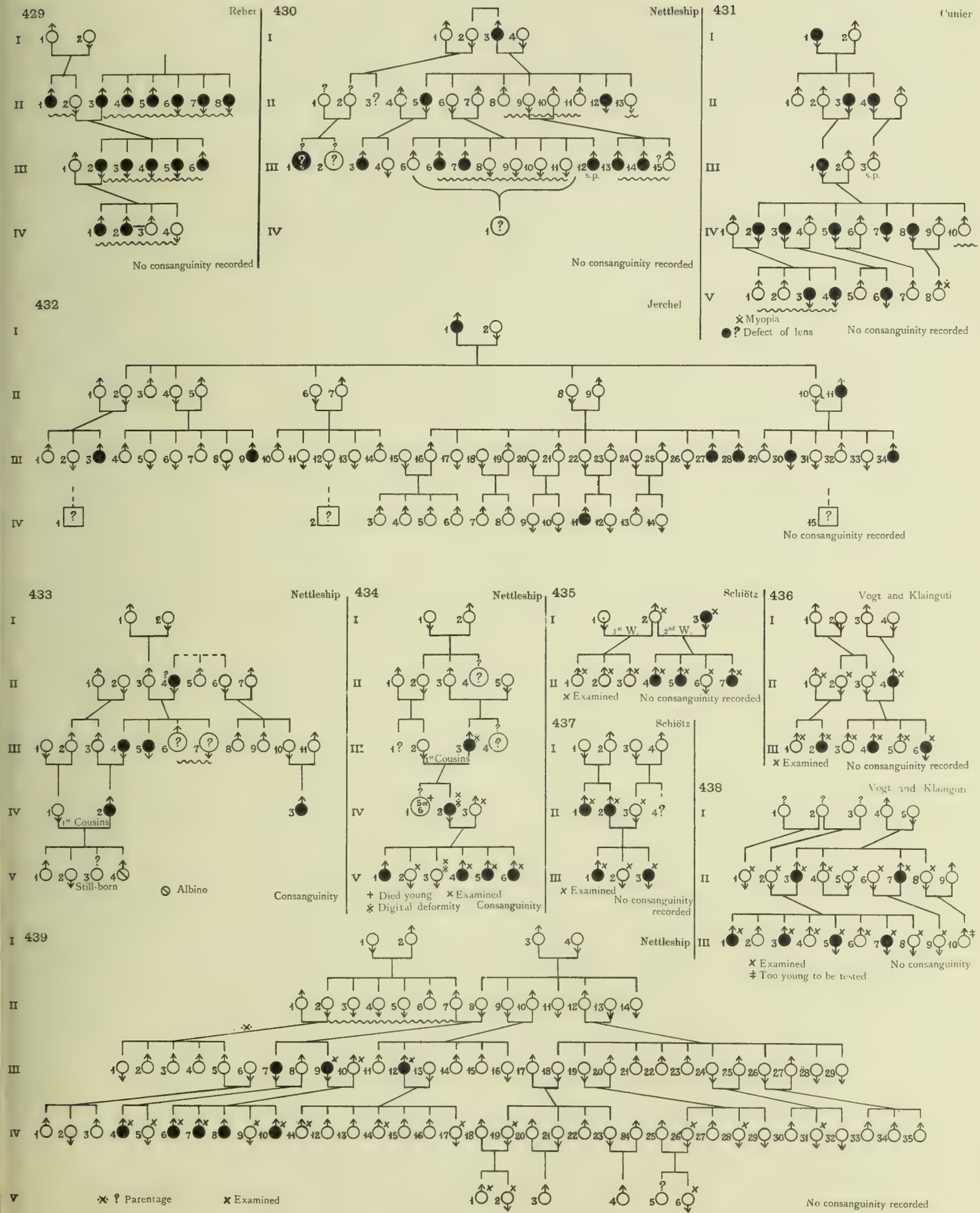

Issued by the Francis Galton Laboratory for National Eugenics.

440

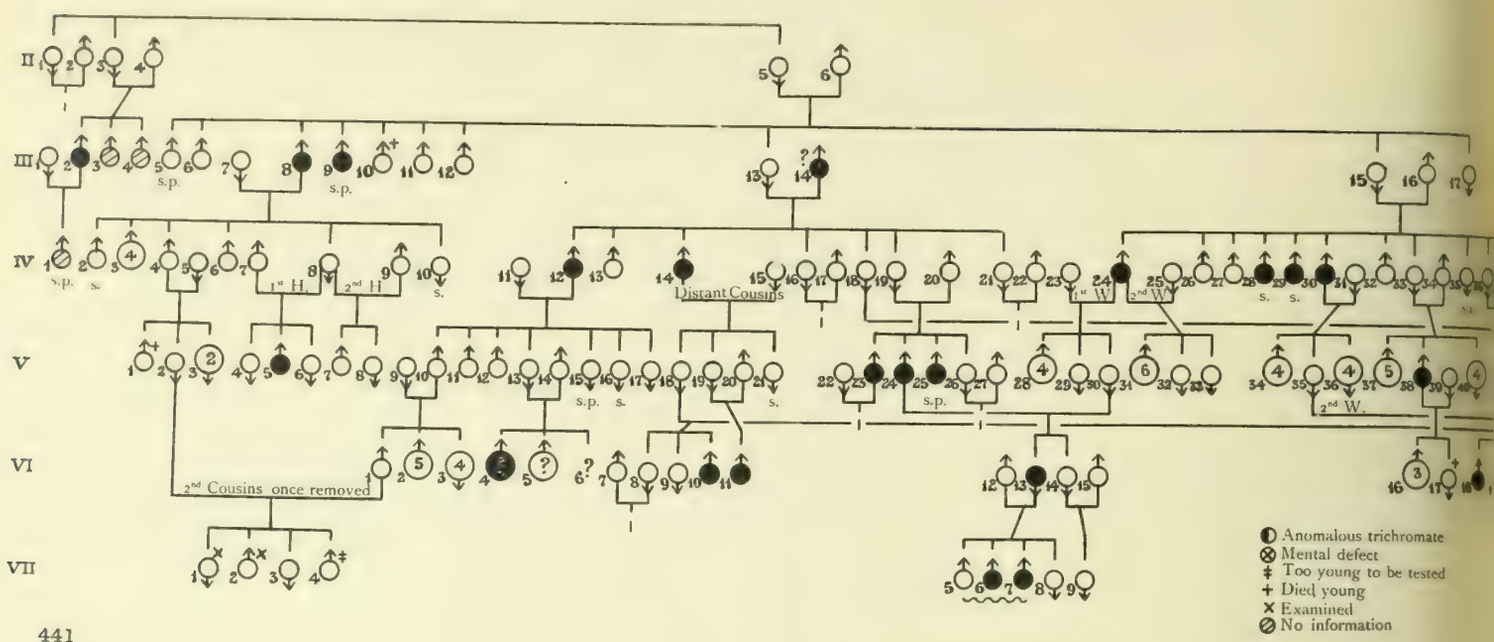
Distant Cousins
2nd Cousins once removed
Anomalous trichromate
Mental defect
Too young to be tested
Died young
Examined
No information

441

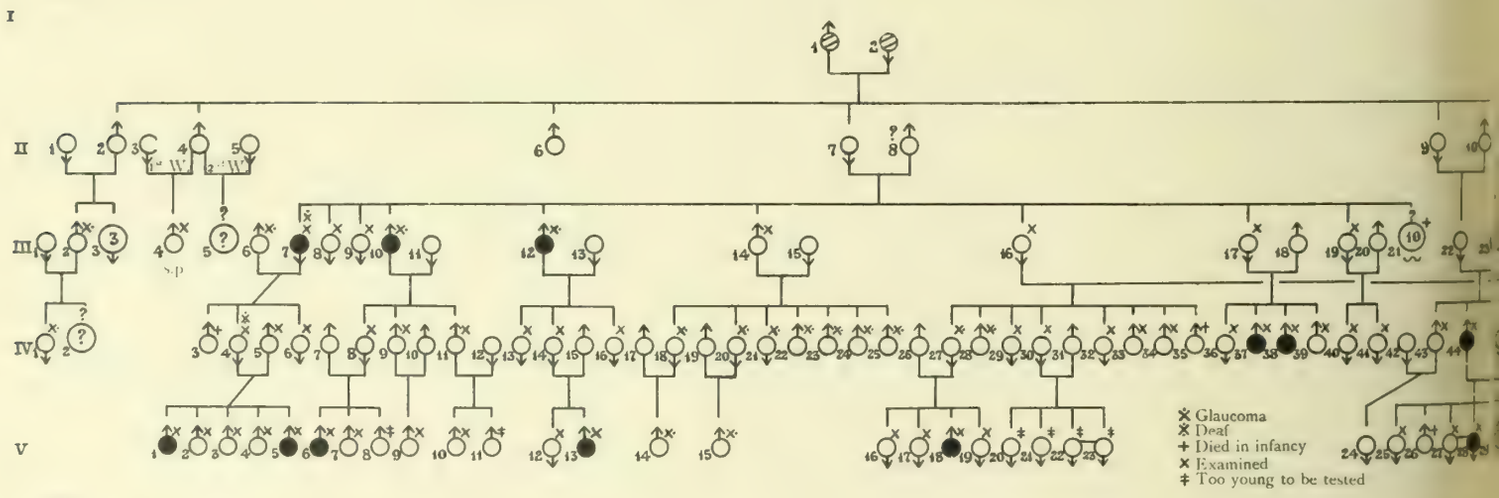
Glaucoma
Deaf
Died in infancy
Examined
Too young to be tested

443

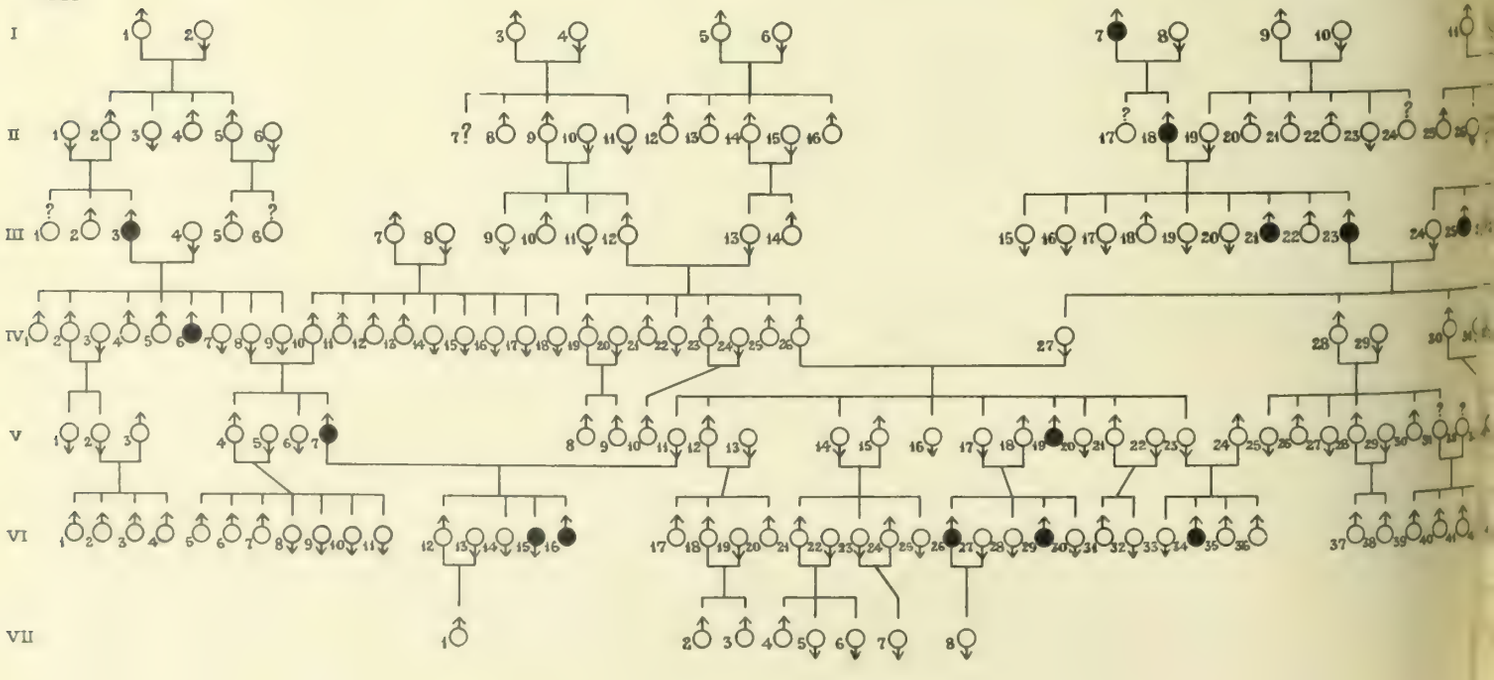

NESS.

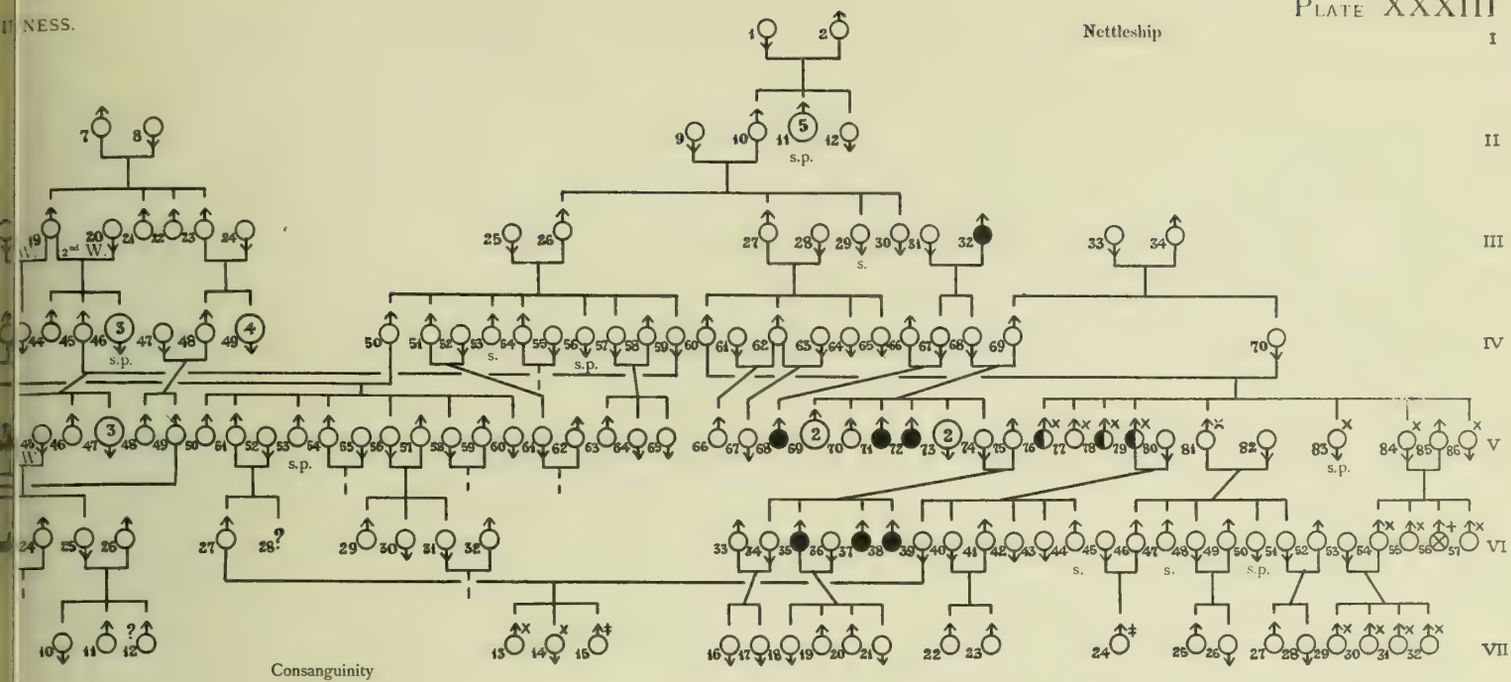
Nettleship
I
II
III
IV
V
VI
VII
s.p.
s.
2nd W.
Consanguinity

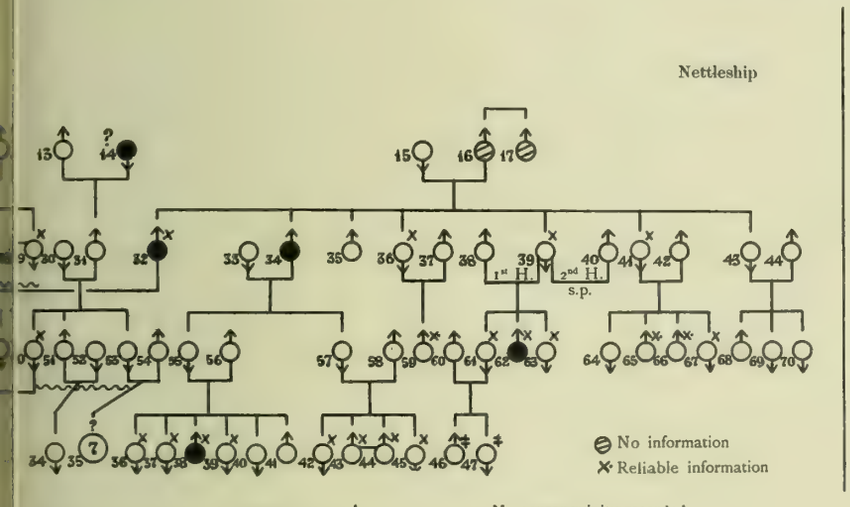
Nettleship
1st H.
2nd H.
s.p.
No information
Reliable information
No consanguinity recorded

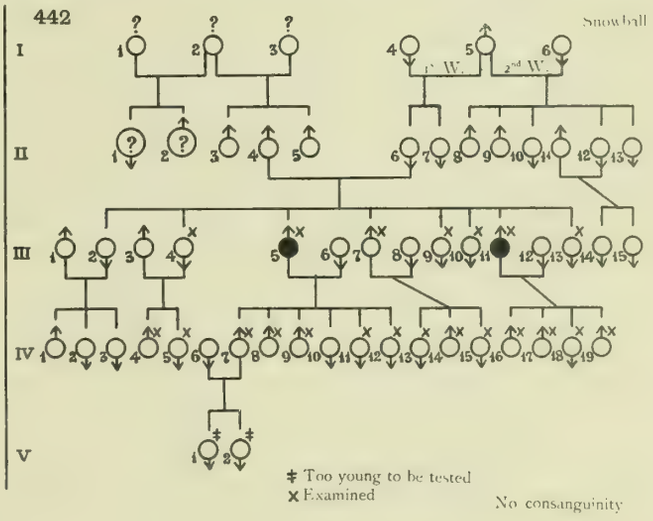
442
Snowball
I
II
III
IV
V
1st W.
2nd W.
‡ Too young to be tested
X Examined
No consanguinity

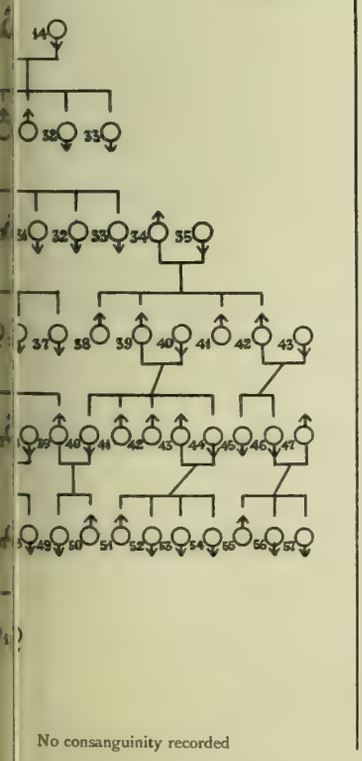
Nabours
No consanguinity recorded

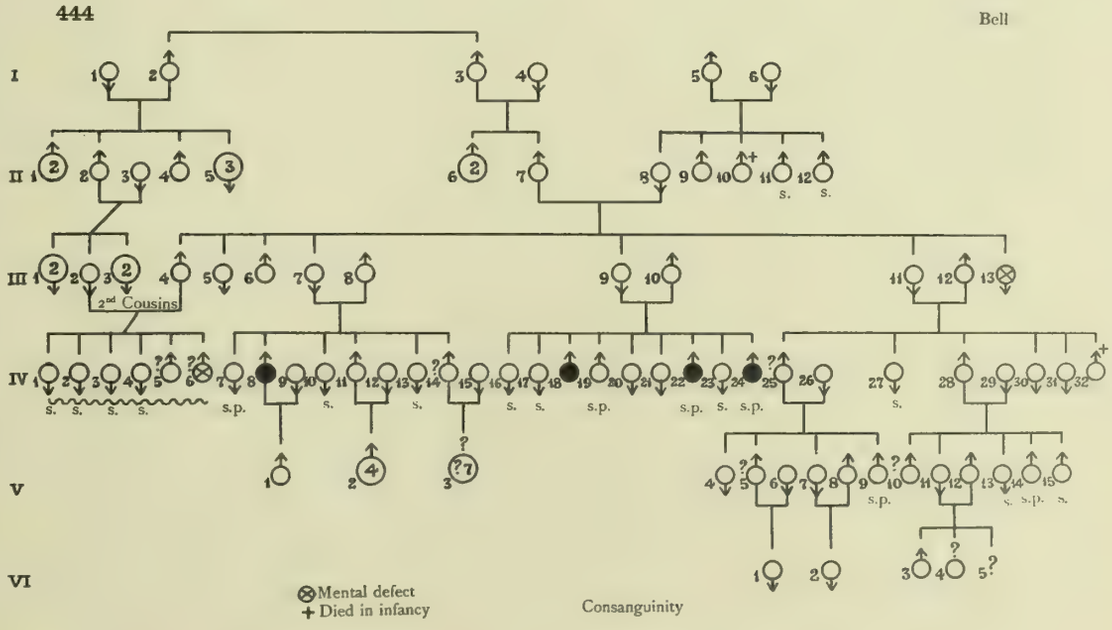
444
Bell
I
II
III
IV
V
VI
2nd Cousins
s.p.
s.
⊗ Mental defect
+ Died in infancy
Consanguinity

CONGENITAL COLOUR-BLINDNESS

445 Bell

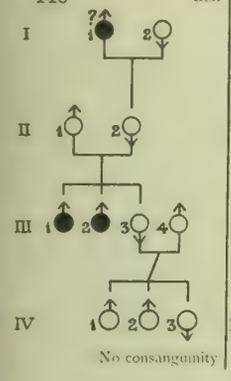

No consanguinity

446 Vogt

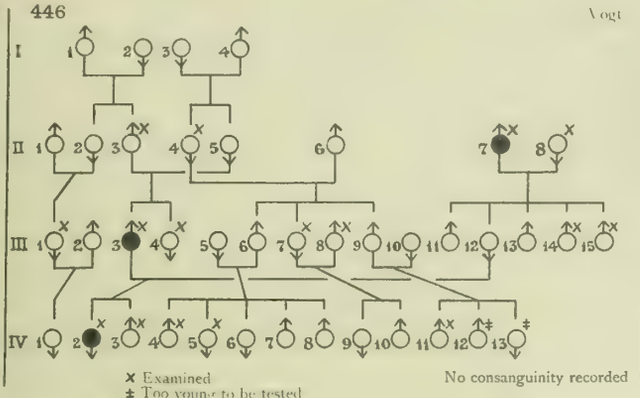

× Examined
‡ Too young to be tested

No consanguinity recorded

447 Nagel

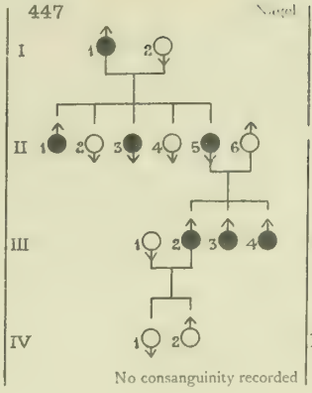

No consanguinity recorded

448 Cuenz

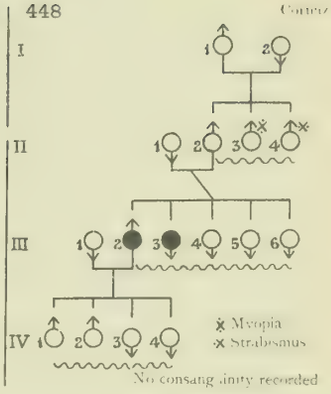

⁂ Myopia
× Strabismus

No consanguinity recorded

449 Pole

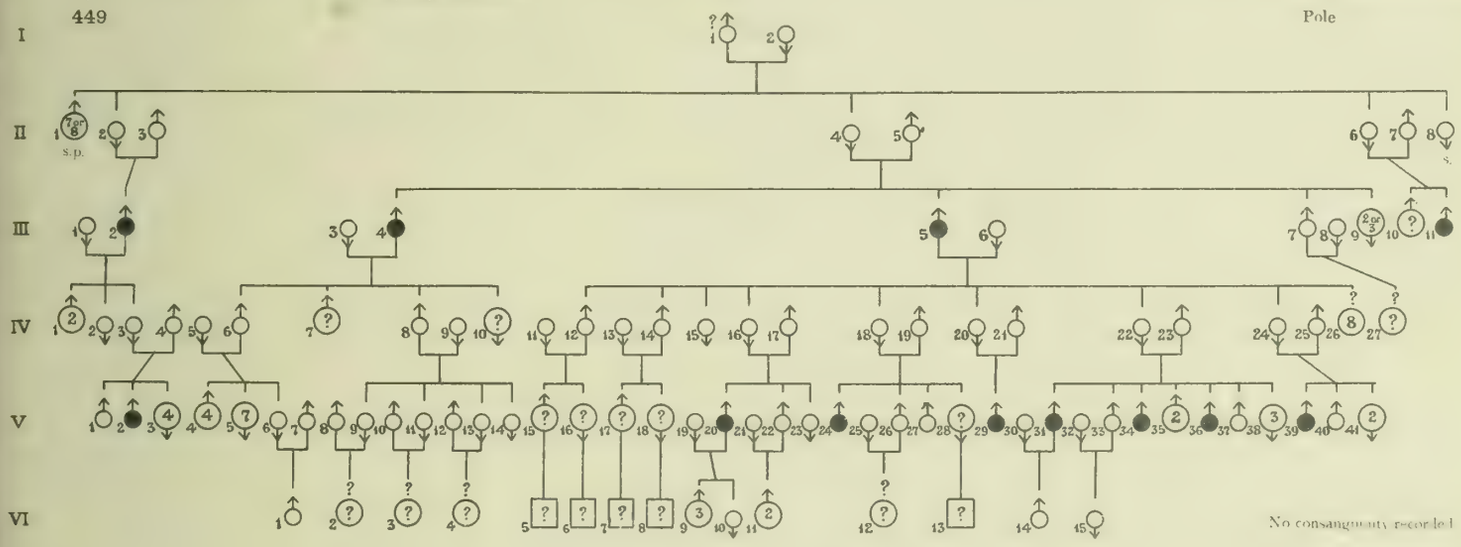

No consanguinity recorded

450 Schlötz

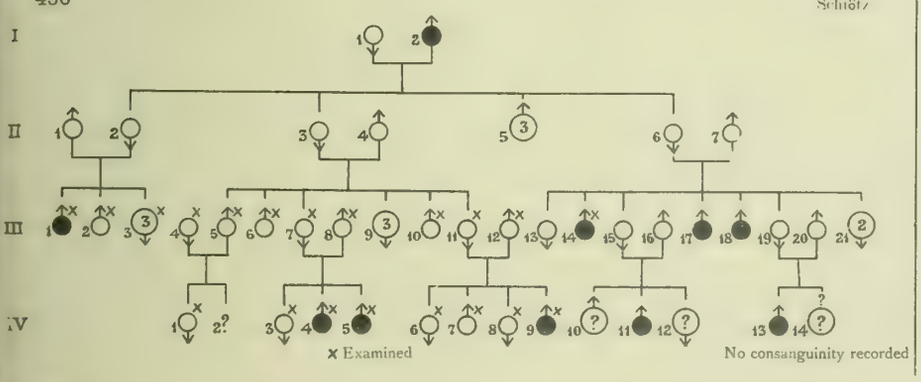

× Examined

No consanguinity recorded

451 Bell

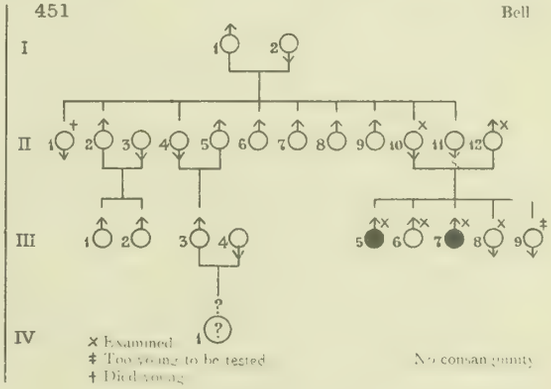

× Examined
‡ Too young to be tested
† Died young

No consanguinity

452 Snowball

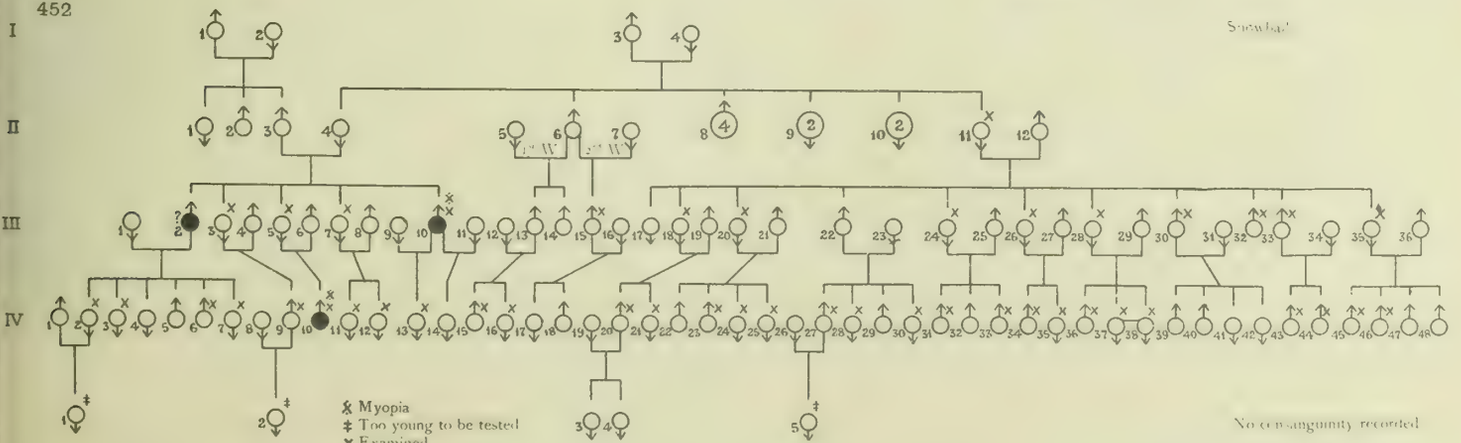

⁂ Myopia
‡ Too young to be tested
× Examined

No consanguinity recorded

Issued by the Francis Galton Laboratory for National Eugenics.

CONGENITAL COLOUR-BLINDNESS.

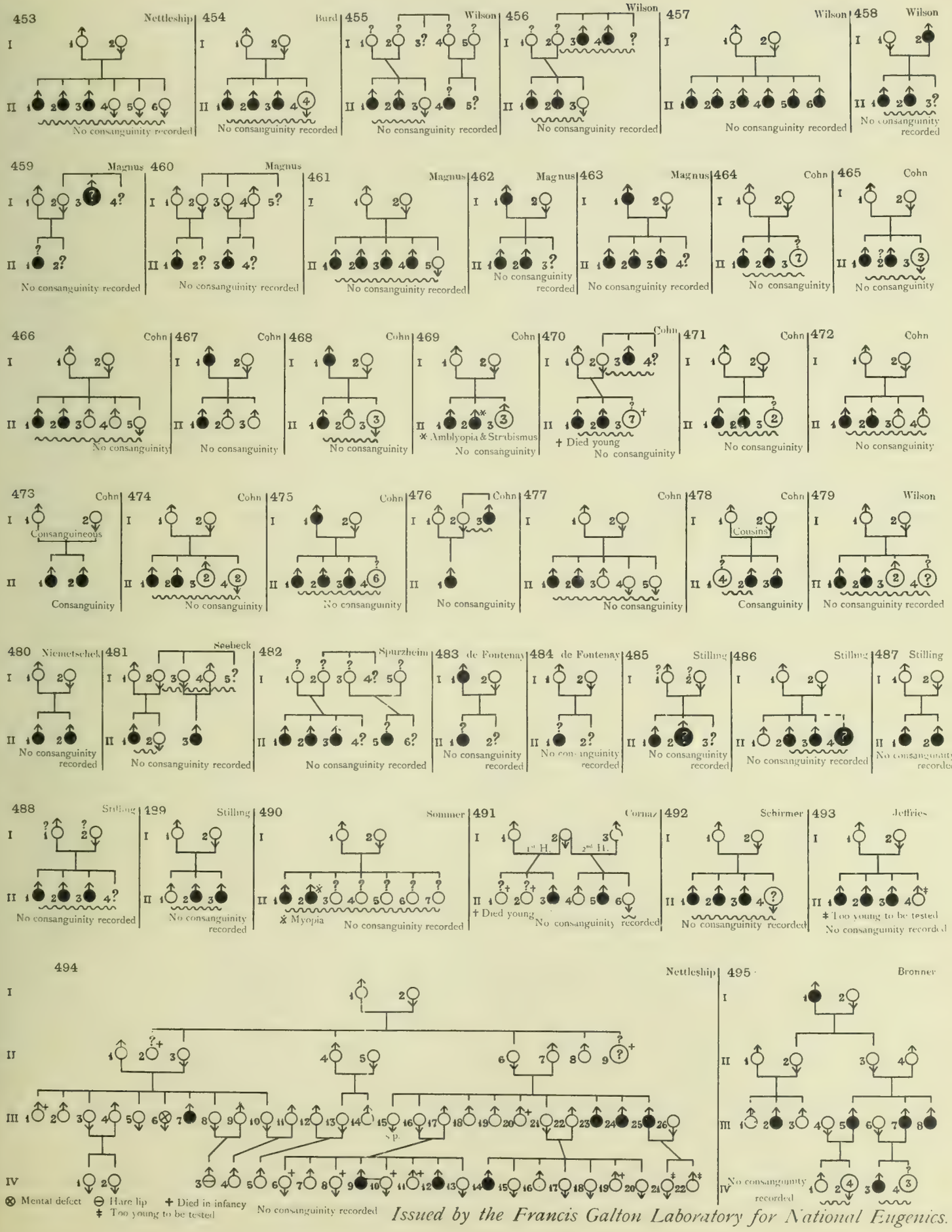

Issued by the Francis Galton Laboratory for National Eugenics.

CONGENITAL COLOUR-BLINDNESS.

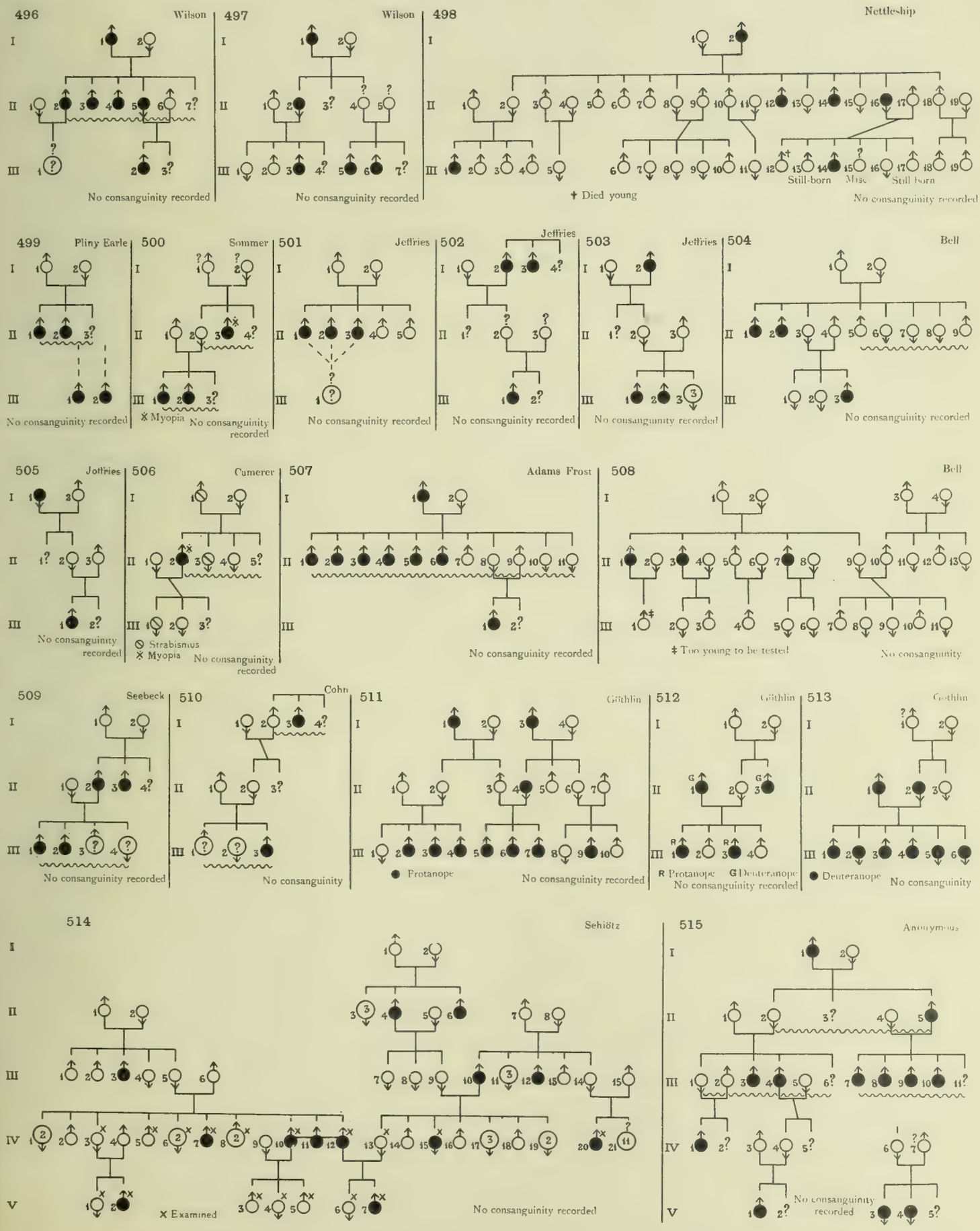

Issued by the Francis Galton Laboratory for National Eugenics.

CONGENITAL COLOUR-BLINDNESS.

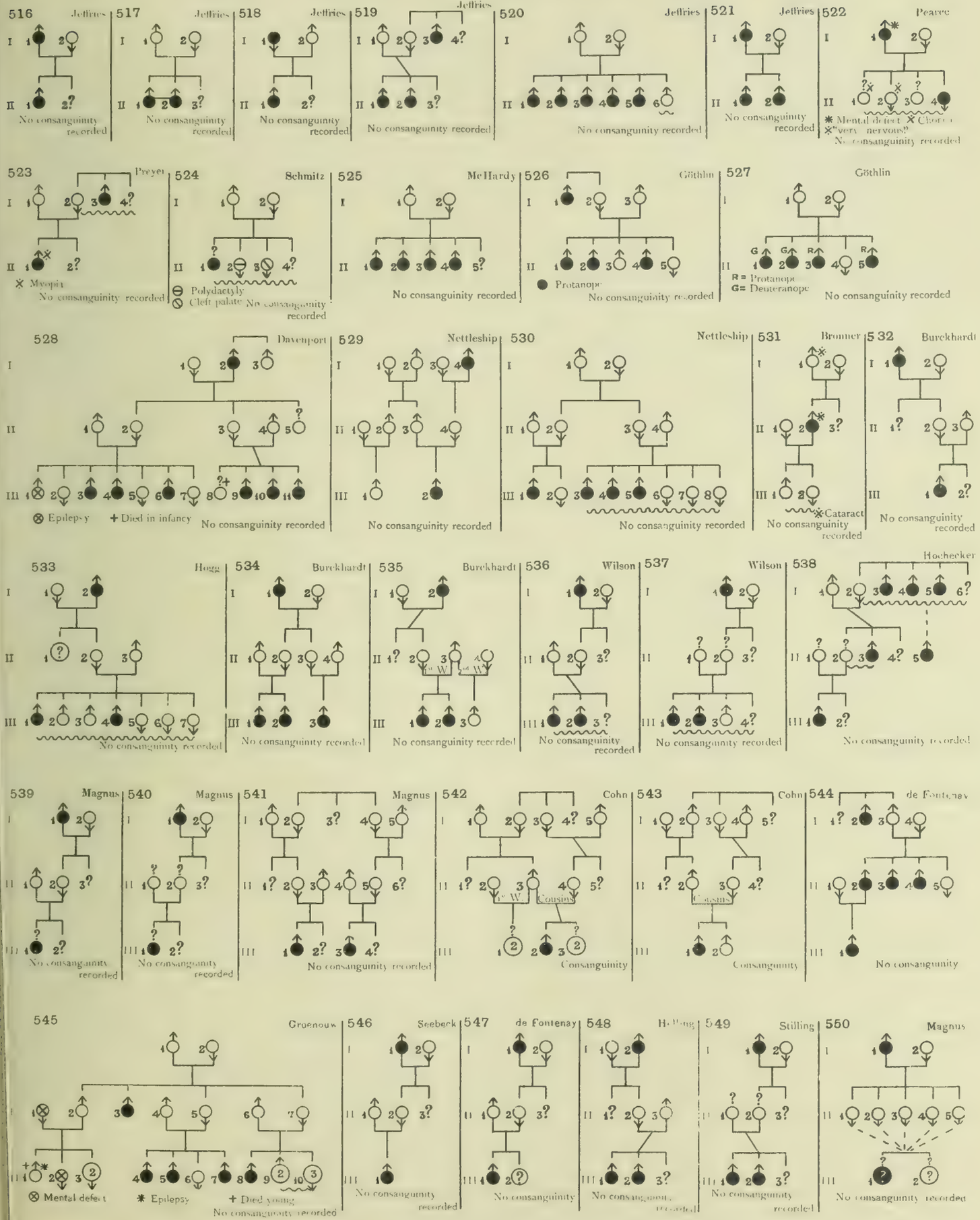

CONGENITAL COLOUR-BLINDNESS.

551 Nagel
R= Protanope
G= Deuteranope
No consanguinity recorded

552 Nagel
No consanguinity recorded

553 Galloway
No consanguinity recorded

554 Wolfe
No consanguinity recorded

555 Wolfe
No consanguinity recorded

556 Wilson
No consanguinity recorded

557 Wilson
No consanguinity recorded

558 Nettleship
No consanguinity recorded

559 Hochecker
No consanguinity recorded

560 Kirschmann
No consanguinity recorded

561 Wartmann
No consanguinity recorded

562 Bickerton
No consanguinity recorded

563 Jeffries
R=Protanope
G=Deuteranope
No consanguinity recorded

564 Kirschmann
◒ Unilateral anomaly
No consanguinity recorded

565 Hess
● Deuteranope
No consanguinity recorded

566 Vogt and Klainguti
×Examined
‡Too young to be tested
No consanguinity recorded

567 Nettleship
× Examined
No consanguinity recorded

568 Nettleship
No consanguinity recorded

569 Nettleship
×Examined
No consanguinity recorded

570 Scott
No consanguinity recorded

571 Nagel
No consanguinity recorded

572 Wolfe
No consanguinity recorded

573 Hogg
No consanguinity recorded

574 Hayes
◒ Unilateral
No consanguinity recorded

575 Schütz
×Examined
No consanguinity recorded

576 Nicholl
No consanguinity recorded

577 Vogt
+ Died young
× Examined
No consanguinity recorded

578 Bell
1st W.
2nd W.
1st Cousins
1st W.
2nd W.
× Left handed
✱ Angio-neurotic oedema
‡ Too young to be tested
Consanguinity

579 Burckhardt
No consanguinity recorded

Issued by the Francis Galton Laboratory for National Eugenics.

CONGENIT

580

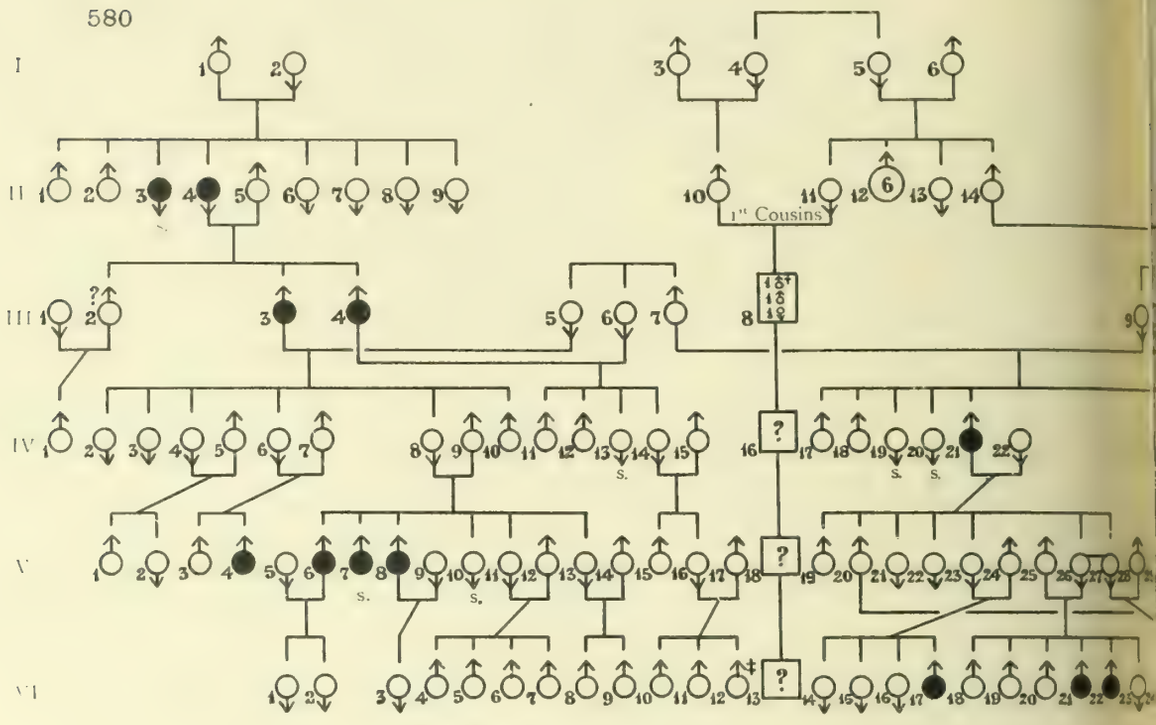

† Died young
‡ Too young to be tested

Order of birth unknown throughout

582

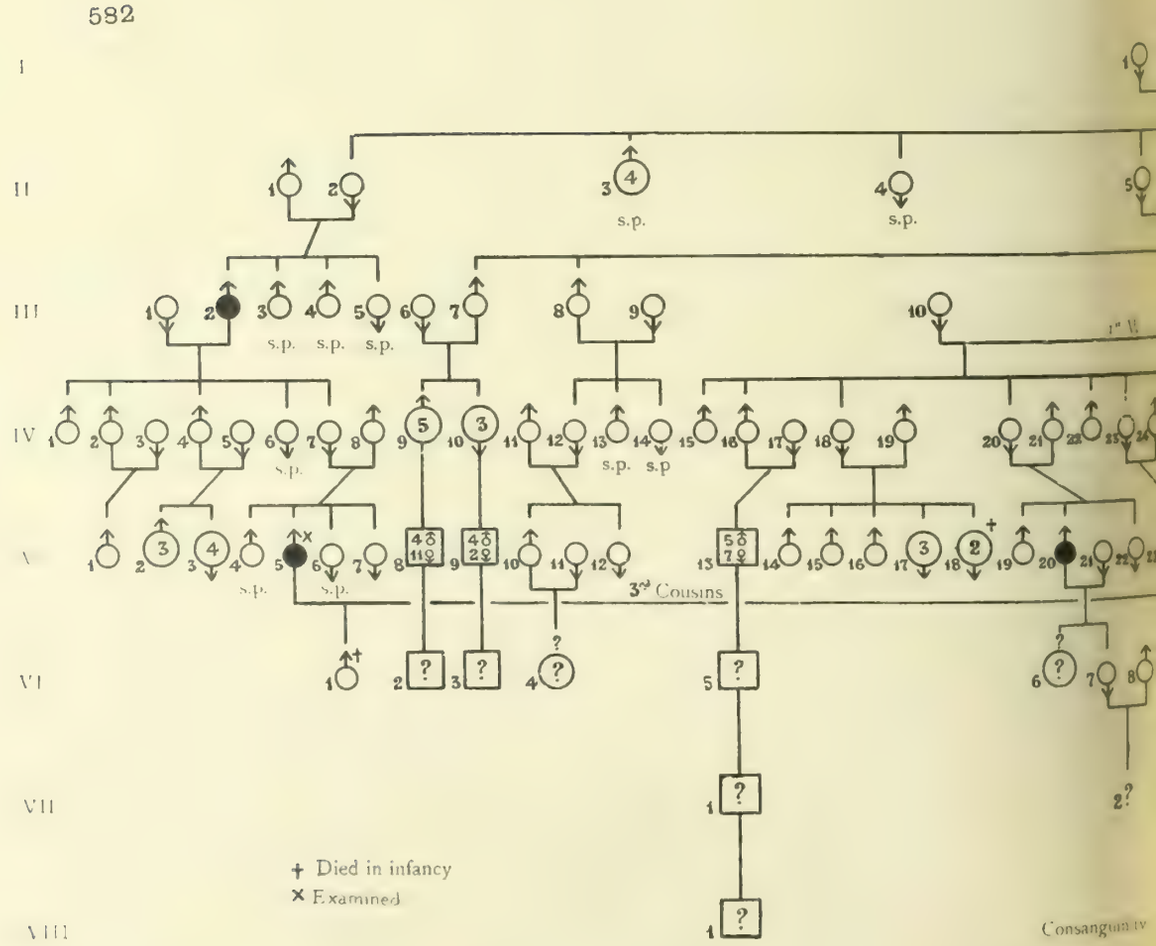

† Died in infancy
× Examined

Consanguinity

DNESS.

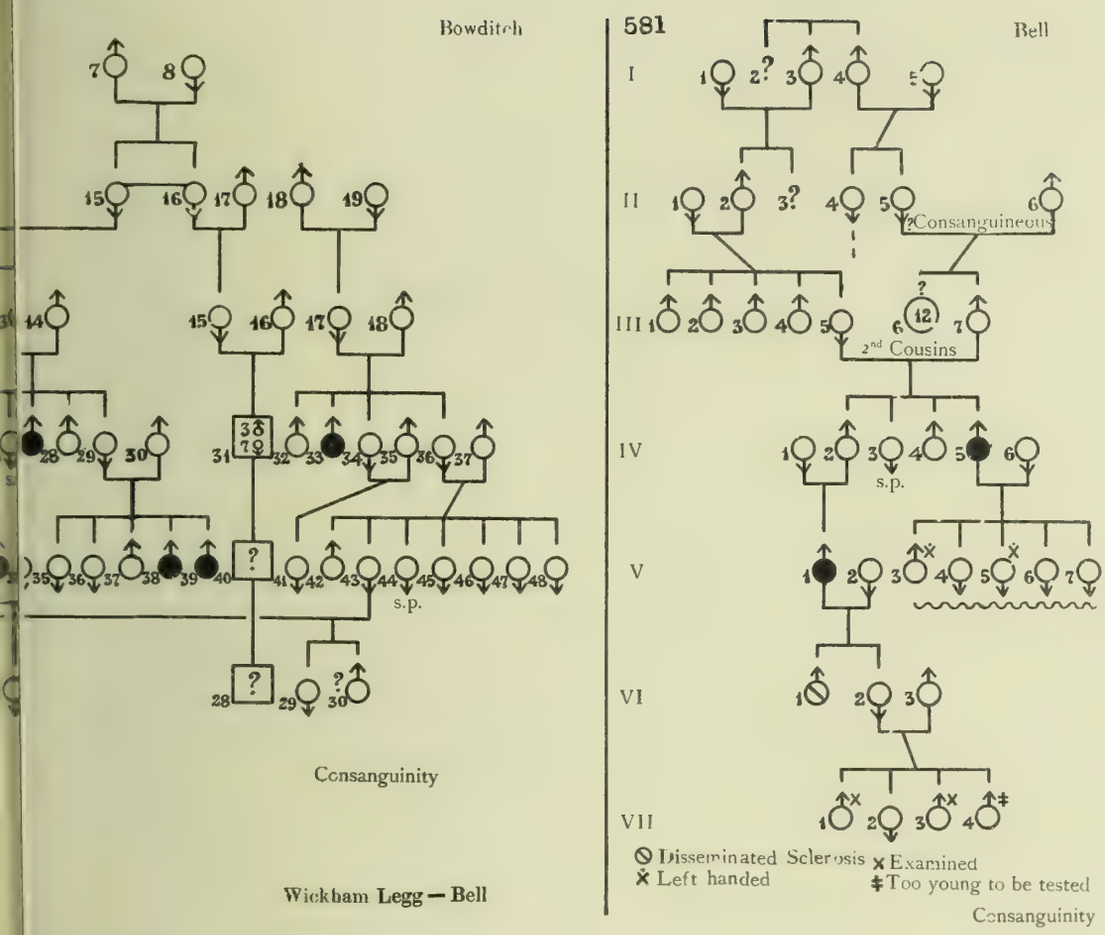

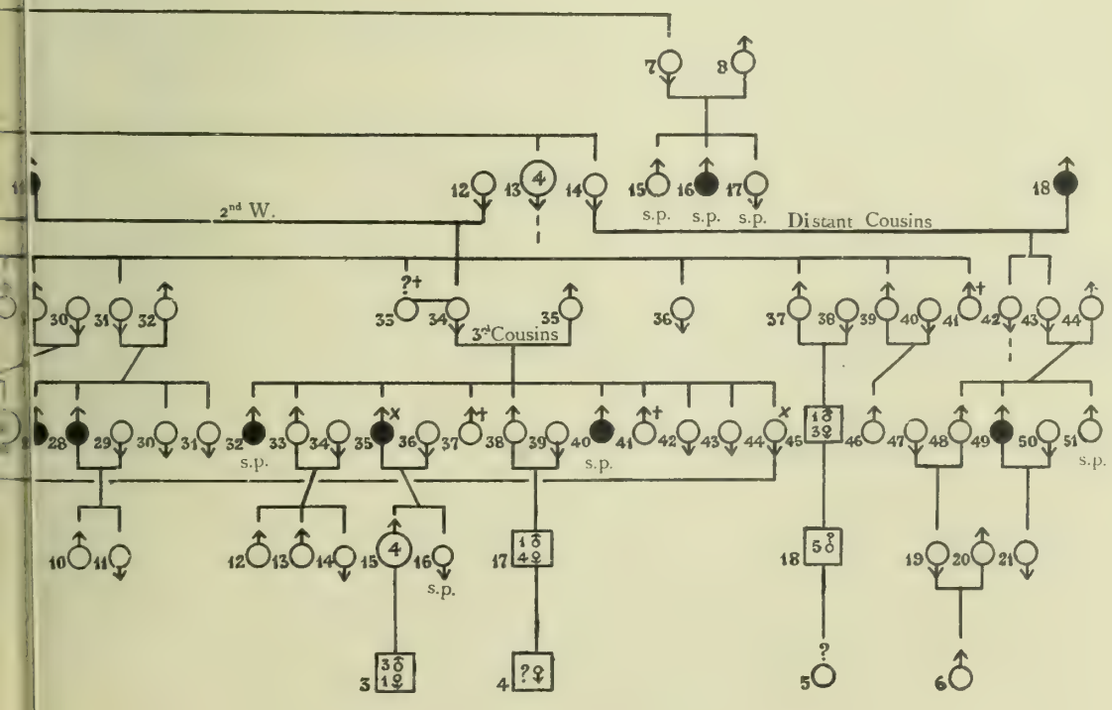

Issued by the Francis Galton Laboratory for National Eugenics.

CONGENITAL COLOUR-BLINDNESS.

583 Bell

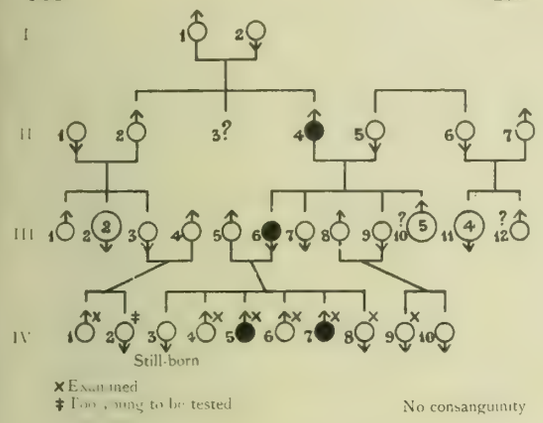

584 Schoeler

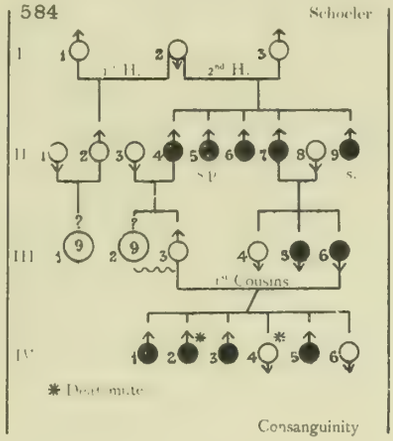

585 Vogt and Klainguti

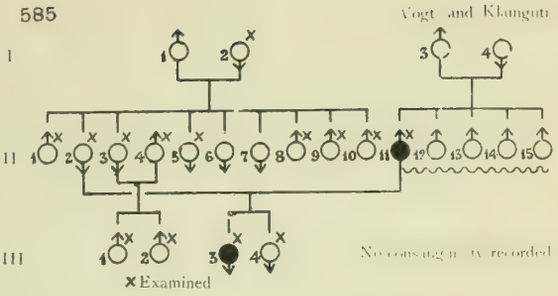

586 Bell

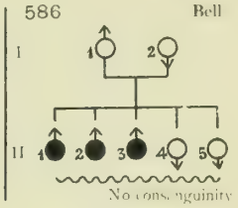

587 Schiötz

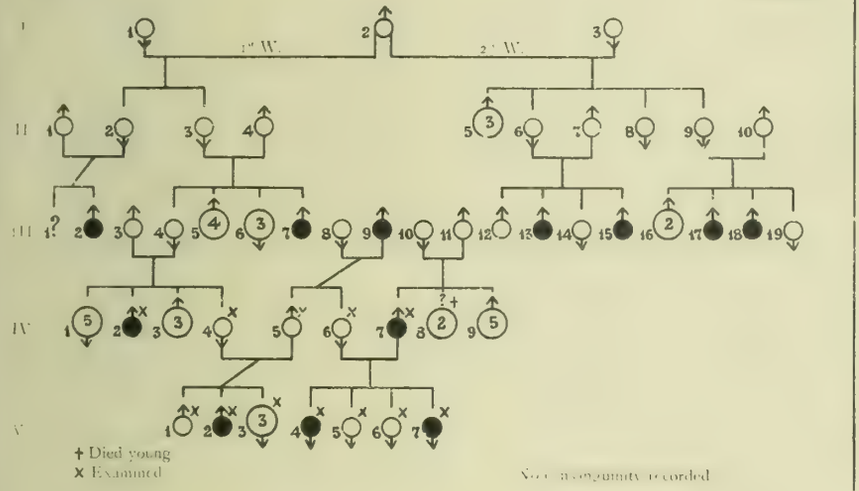

588

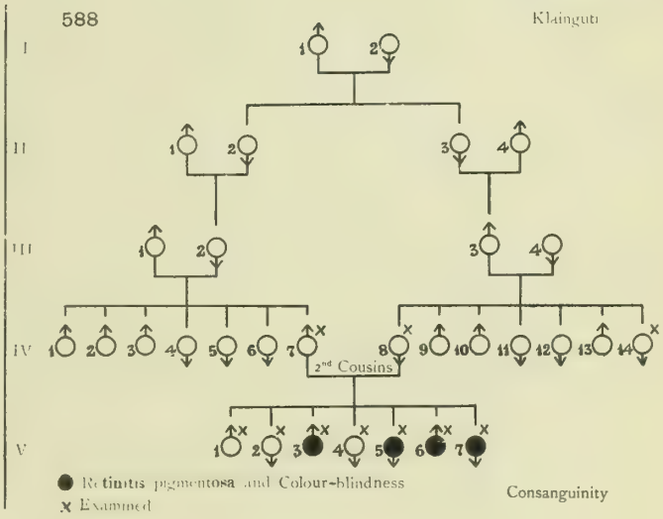

589 Herne

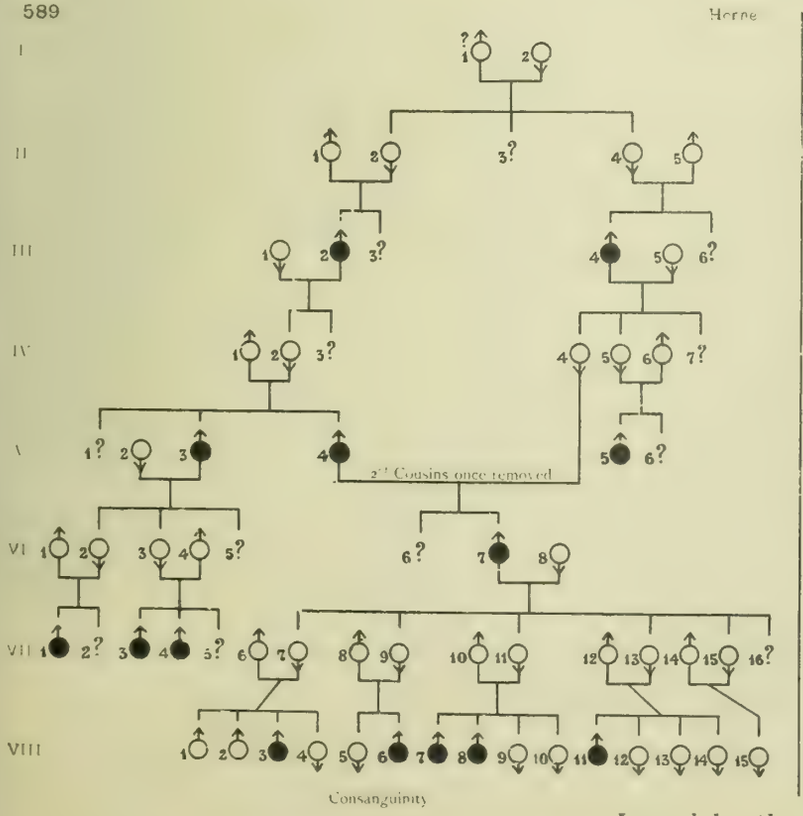

590 Butter and Nettleship

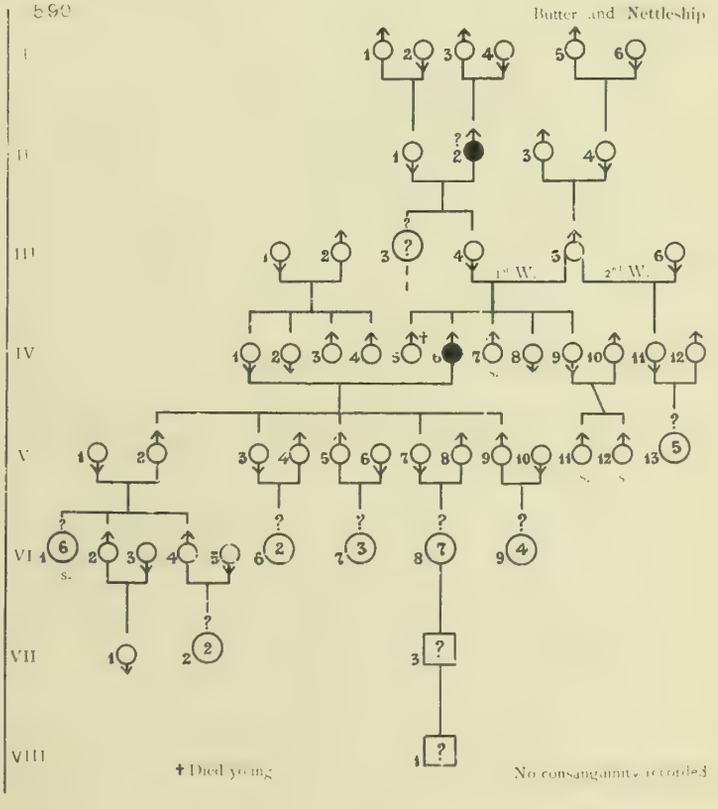

Issued by the Francis Galton Laboratory for National Eugenics.

CONGENITAL COLOUR-BLINDNESS AND ANOMALOUS TRICHROMATISM.

591 Schuster

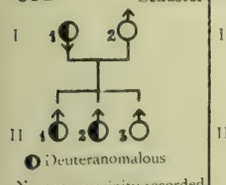

No consanguinity recorded

592 Hess

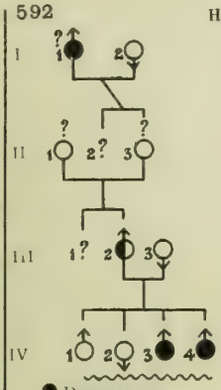

No consanguinity recorded

593 Göthlin

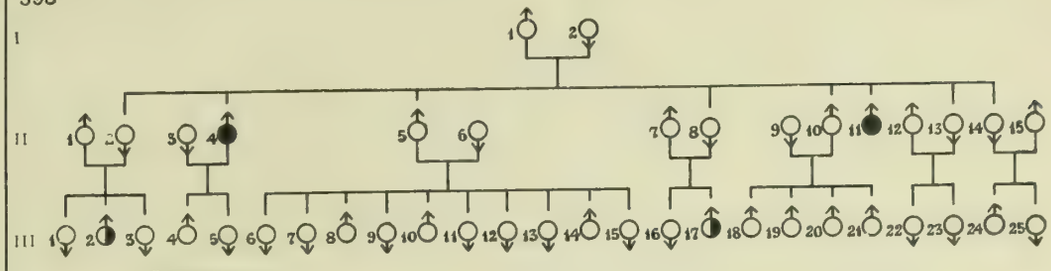

No consanguinity recorded

594 Hess

No consanguinity recorded

595 Hess

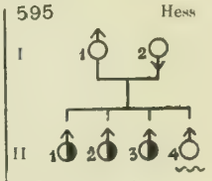

No consanguinity recorded

596 Guttmann

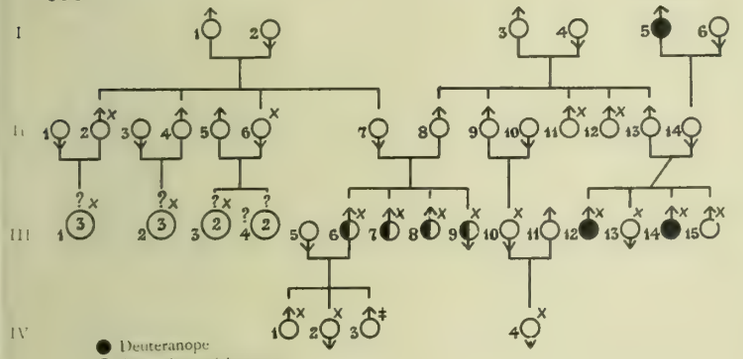

No consanguinity recorded

597 Wölfflin

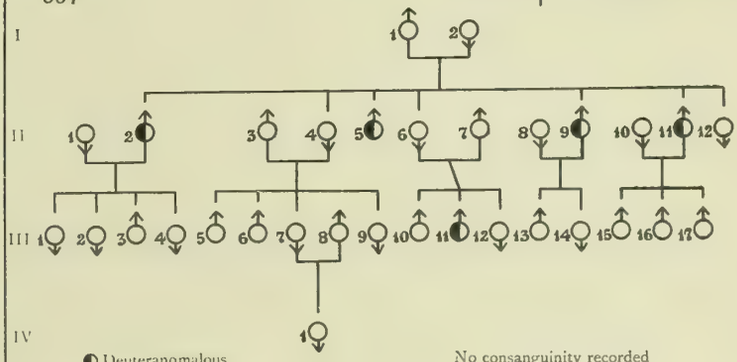

No consanguinity recorded

598 Göthlin

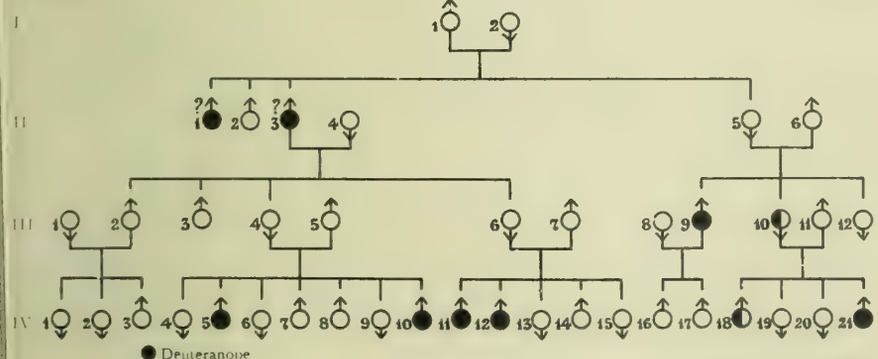

No consanguinity recorded

599 Guttmann

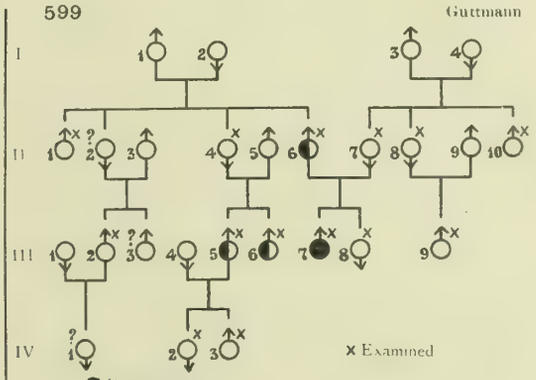

No consanguinity recorded

600 Döderlein

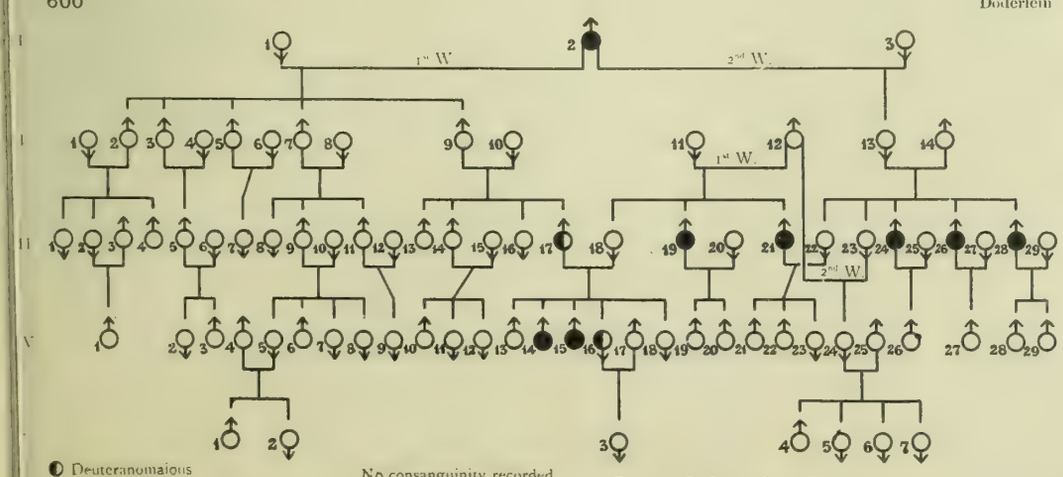

No consanguinity recorded

601 Wölfflin

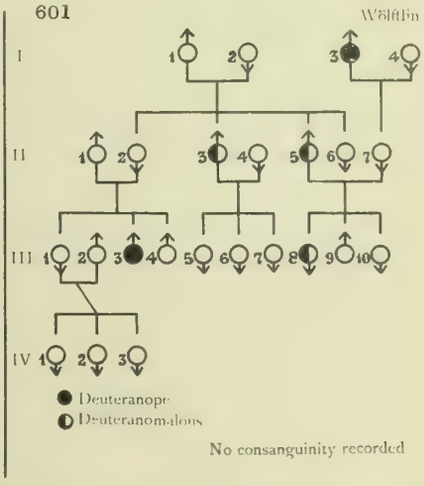

No consanguinity recorded

HEREDITARY BLUE SCLEROTICS

602

Stephenson – Harman – Riddell – Bell

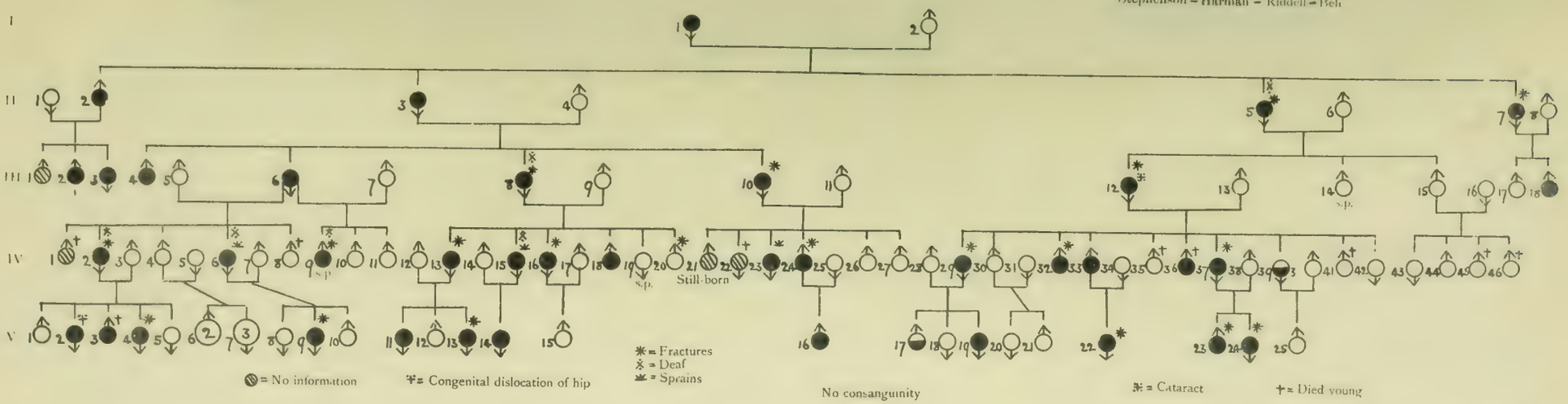

603

Riddell

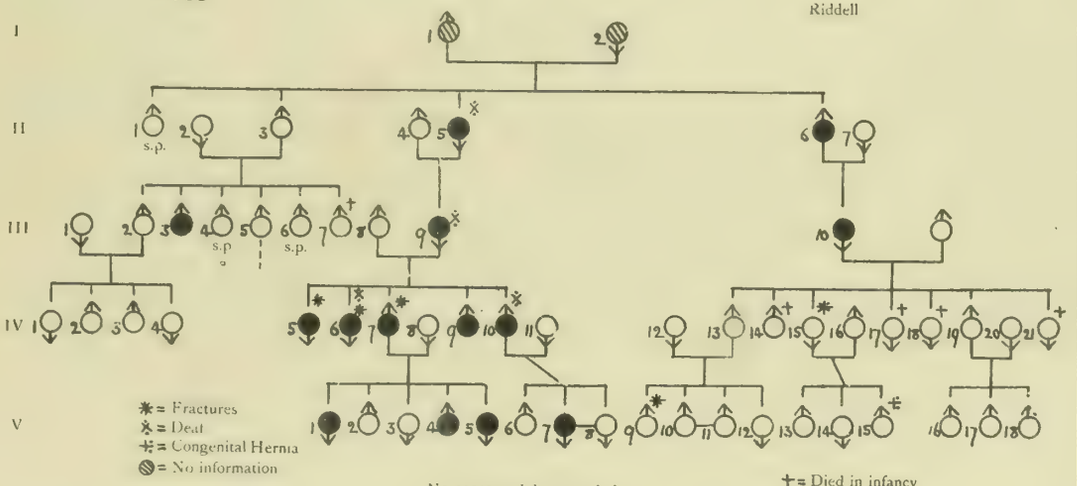

604

Coulon

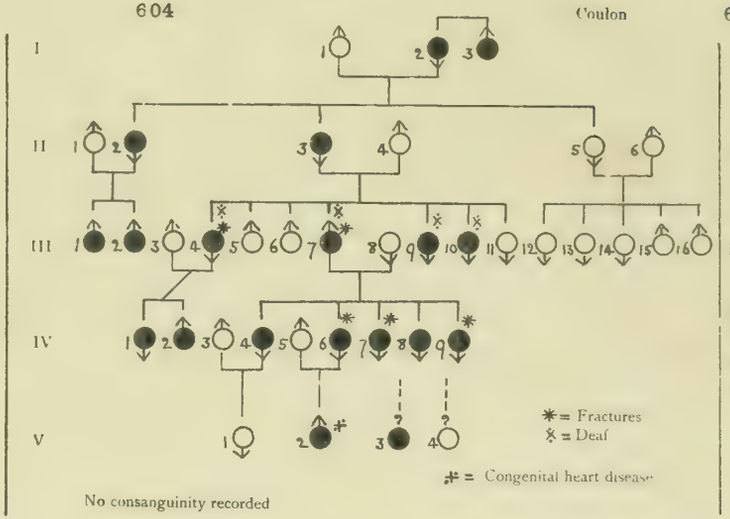

605

Schwarz

606

Cockayne

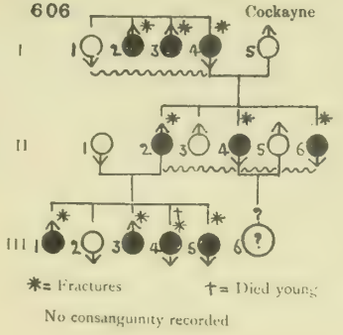

607

Cockayne

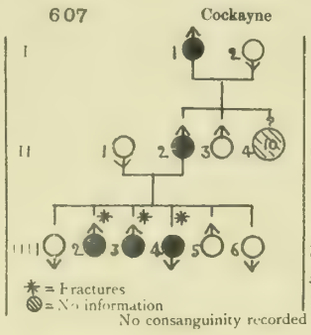

608

Hass

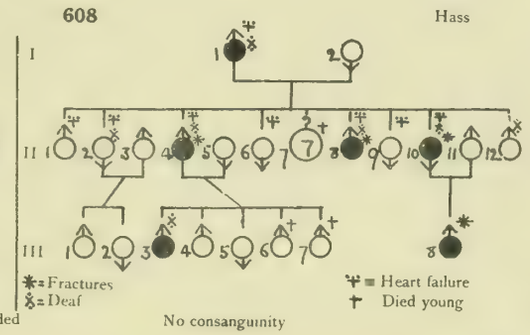

609

Stewart

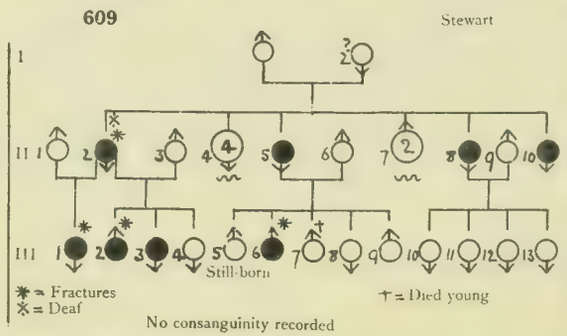

610

van der Hoeve

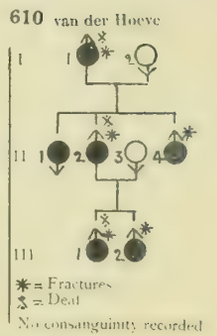

HEREDITARY BLUE SCLEROTICS.

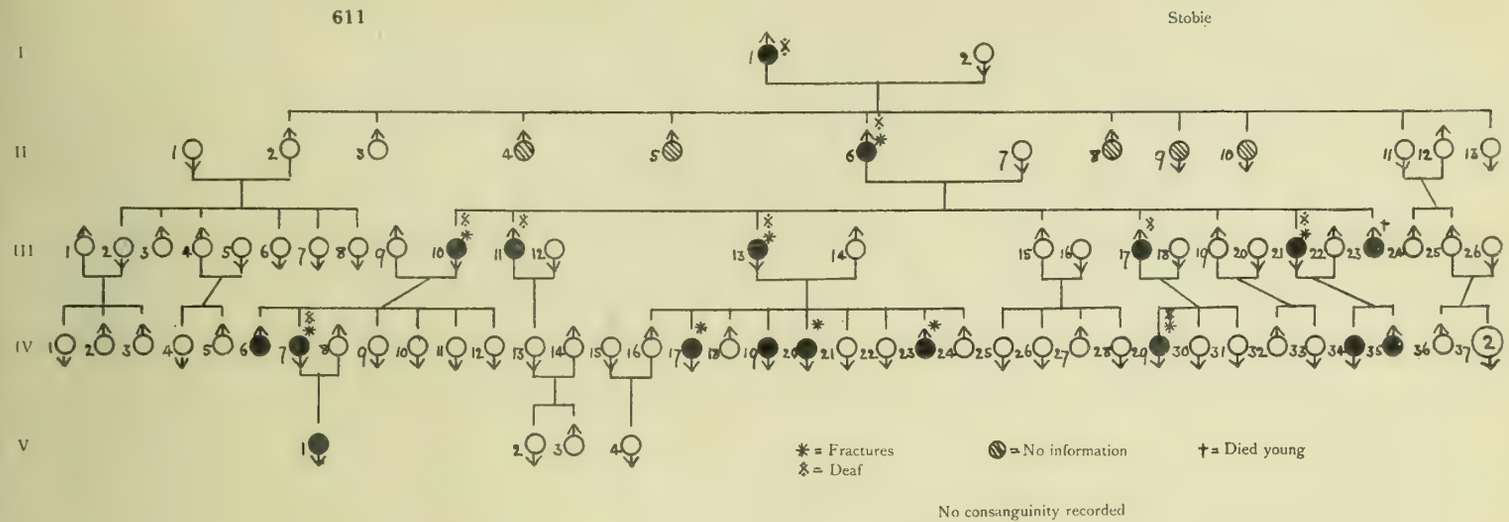

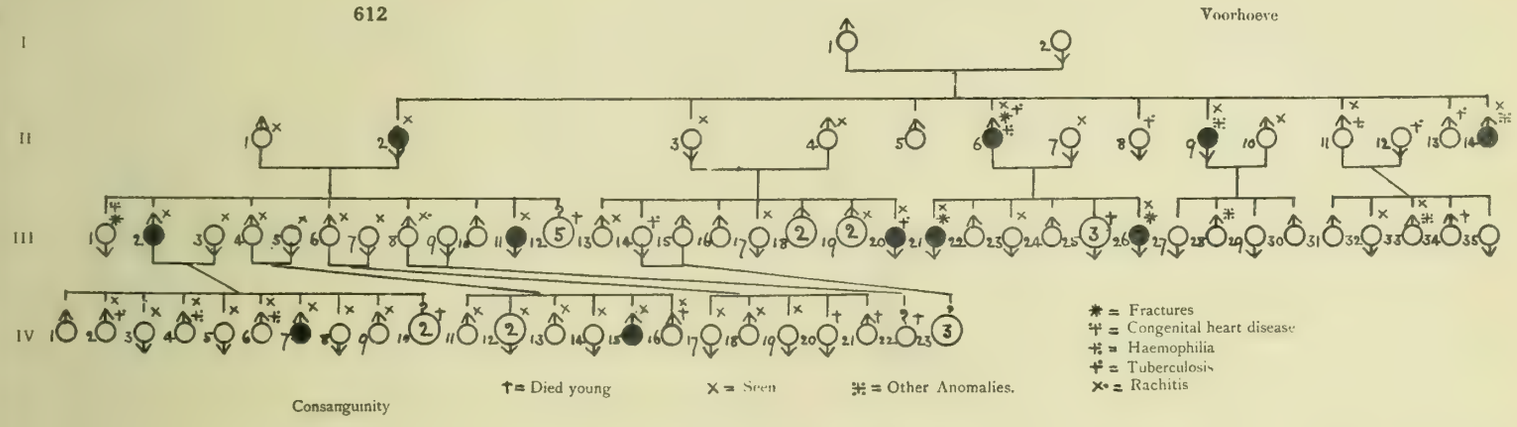

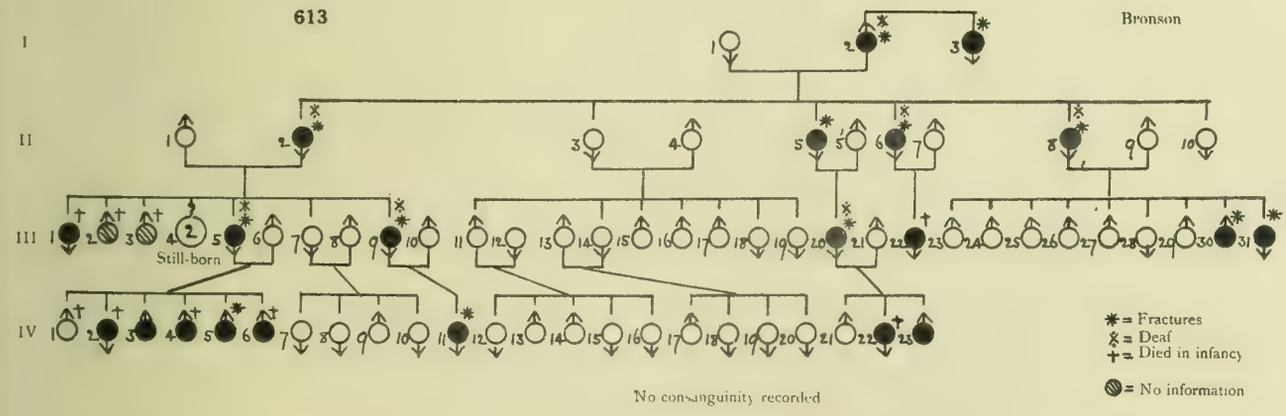

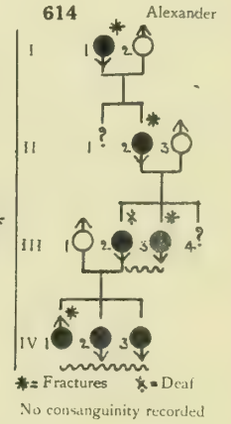

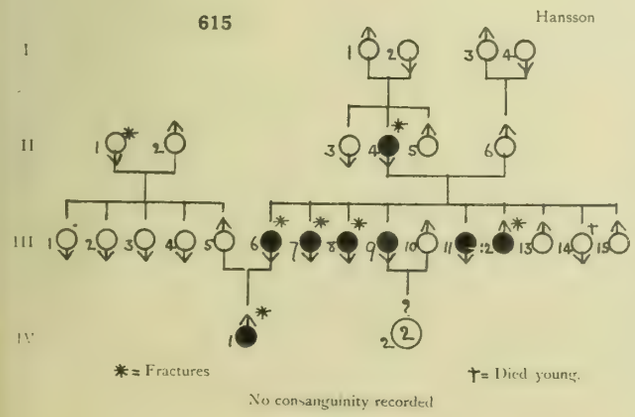

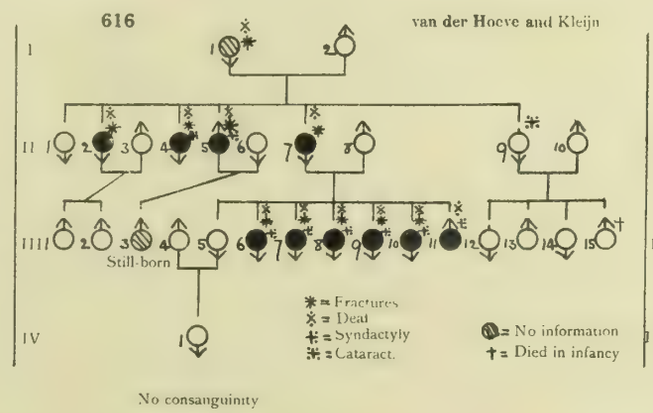

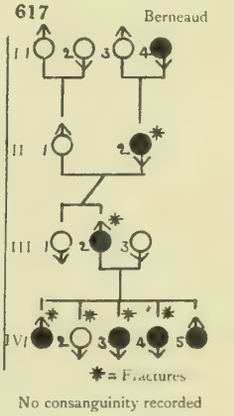

HEREDITARY BLUE SCLEROTICS.

618 Burrows

No consanguinity recorded

✱ = Fractures

619 Adair-Dighton

✱ = Fractures
✱ = Deaf
† = Died young

No consanguinity recorded

620 Peters

✱ = Fractures

No consanguinity recorded

621 Berneaud

1st Wife 2nd Wife

✱ = Fractures

No consanguinity recorded

622 Cockayne

✱ = Fractures
✱ = Sprains

No consanguinity recorded

623 Ruttin

✱ = Fractures
✱ = Deaf
⊘ = No information

No consanguinity recorded

624 Bronson

✱ = Fractures
✱ = Sprains

No consanguinity recorded

625 Blegvad and Haxthausen

✱ = Fractures ✱ = Deaf ✱ = Cataract

No consanguinity recorded

626 Ruttin

✱ = Fractures
✱ = Deaf
‡ = Heart failure
† = Died young
⊘ = No information

No consanguinity recorded

627 Terry

twins

✱ = Fractures
✱ = Deaf

No consanguinity recorded

628 Straat

✱ = Fractures
✱ = Deaf

No consanguinity recorded

629 Ruttin

✱ = Fractures ✱ = Cataract
✱ = Deaf

No consanguinity recorded

630 Bolten

⊘ = Nervous
⊘ = Mental defect
⊘ = No information
✱ = Fractures
✱ = Vaso-motor defect

No consanguinity recorded

631 Apert & Cambessédès

✱ = Fractures
† = Tuberculosis

No consanguinity recorded

632 Wiechmann and Paal.

✱ = Fractures
✱ = Deaf

No consanguinity recorded

633 Aubineau

✱ = Fractures † = Phthisis
✱ = Alcoholic † = Died young

No consanguinity recorded

634 Franke

✱ = Fractures
† = Died in infancy

No consanguinity recorded

635 Elewaut

✱ = Fractures

No consanguinity recorded

636 Franke

✱ = Fractures
⊘ = No information

No consanguinity recorded

HEREDITARY BLUE SCLEROTICS.



HEREDITARY BLUE SCLEROTICS.

659 Usher

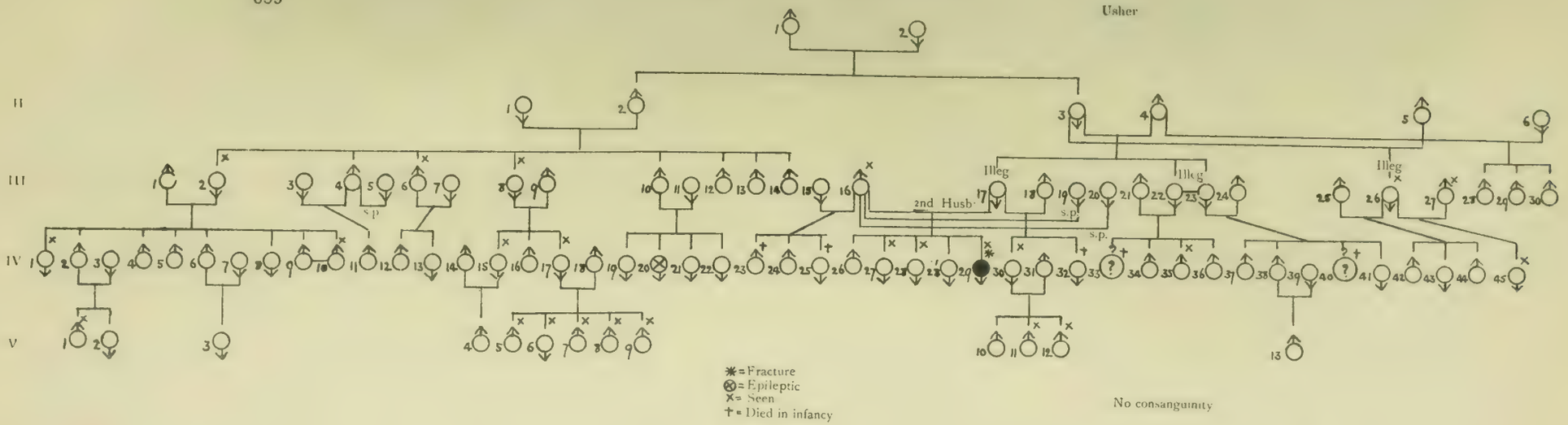

No consanguinity

660 Bolten

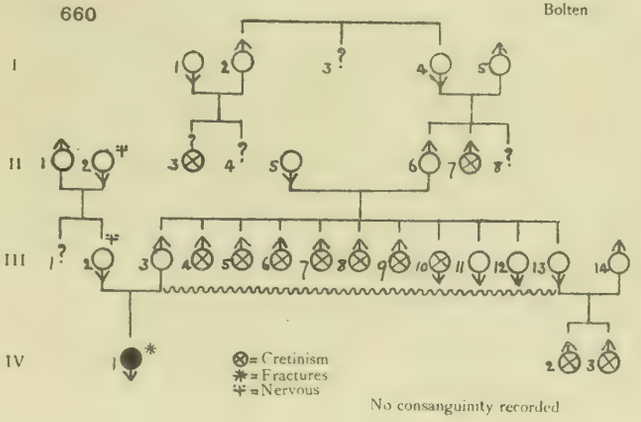

No consanguinity recorded

661 Vanderveer and Dickinson

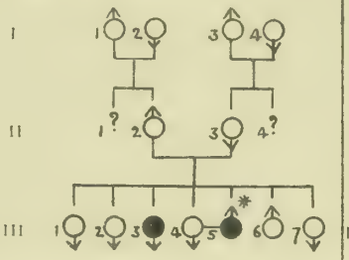

No consanguinity recorded

662 Duggan and Nanavati

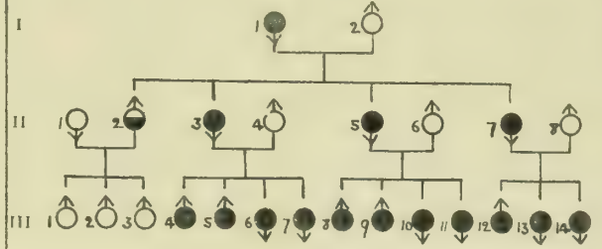

No consanguinity

663 Terrien Sainton and Veil

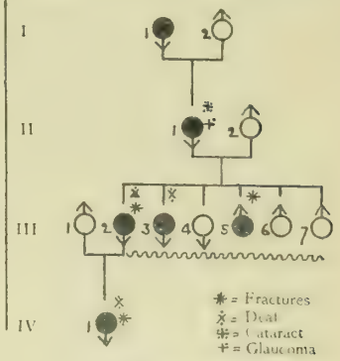

No consanguinity recorded

664 Vallery-Radot and Aris

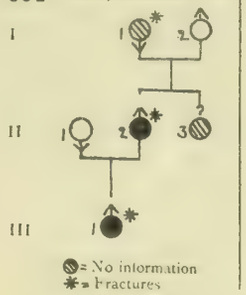

No consanguinity recorded

665 Wise

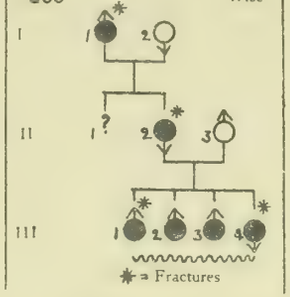

No consanguinity recorded

666 Kropp

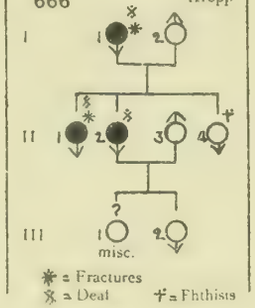

No consanguinity recorded

667 Bolten

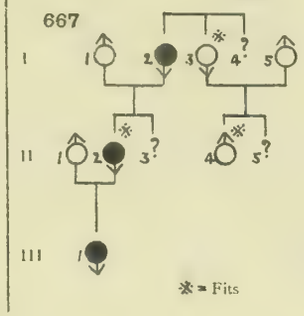

No consanguinity recorded

668 Wirth

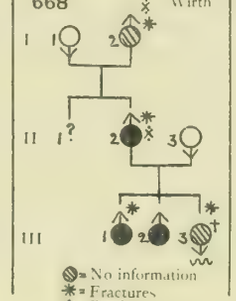

No consanguinity recorded

669 Scheel

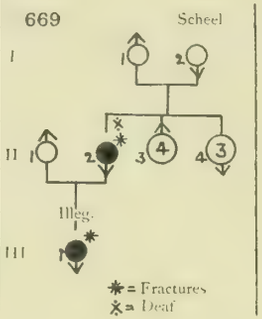

No consanguinity recorded

670 Shugrue, Rockwood and Anderson

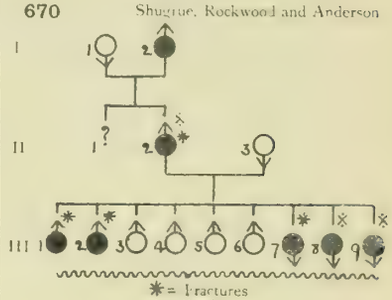

No consanguinity recorded

HEREDITARY BONE FRAGILITY.

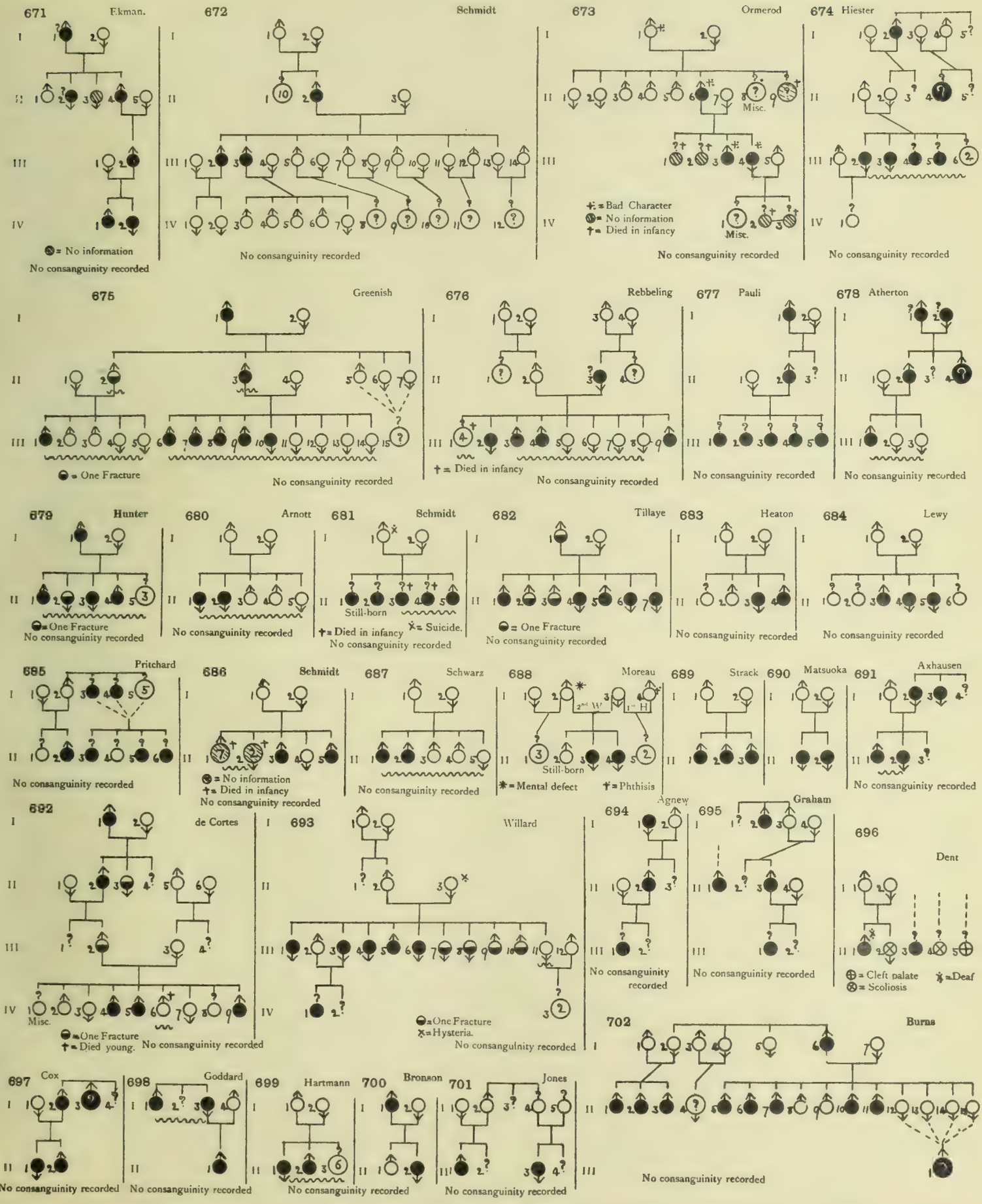

BINDING LIST DEC 15 1948

HQ
750
A1T7
v.2
pt.1-3

Treasury of human inheritance

PLEASE DO NOT REMOVE
CARDS OR SLIPS FROM THIS POCKET

UNIVERSITY OF TORONTO LIBRARY

UTL AT DOWNSVIEW
D RANGE BAY SHLF POS ITEM C
39 13 17 16 04 013 2